website www.jaypeebrothers.com, for detailed information on radiology books, visit our website www.jaypeebrothers.com



HIGH RESOLUTION COMPUTED TOMOGRAPHY *of the* LUNGS

A Practical Guide

SECOND EDITION

D Karthikeyan

Contents

1. Computed Tomography: Techniques and Anatomy **1**

- Indications and Role of Radiologist *2*
- Scan Technique *2*
- Volume HRCT Modifications *4*
- Artifacts on HRCT *4*
- Scan Protocols: Technique Refinements *5*
- Scan Position *5*
- Lateral Decubitus CT *6*
- Low Dose HRCT *7*
- Postprocessing Techniques *9*
- Normal CT Lung Anatomy *10*
- Anatomic Basis of Disease *13*
- Lung Parenchyma *13*
- Secondary Pulmonary Lobule *14*
- Interstitium *16*
- Concept of Cortical and Medullary Lung *17*

2. Overview of Lung Disease **19**

- Linear and Reticular Pattern *20*
- Interlobular Thickening *20*
- Intralobular Interstitium: Reticular Abnormalities *21*
- Peribronchial Interstitial Thickening *21*
- Honeycombing *23*
- Irregular Linear Opacity *24*
- Nodules *24*
- Centrilobular *25*
- Random *27*
- Perilymphatic *28*
- Ground-glass Opacity *29*
- Consolidation *29*
- Lung Calcification and Increased Lung Opacity *30*
- Decreased Lung Attenuation *32*
- Bronchiectasis *32*
- Aging Lung Changes *39*

3. Anatomic Patterns and Pathological Correlates in Parenchymatous Lung Disease: An Overview **40**

- Intra-alveolar Pattern *40*
- Interstitial Pattern *41*
- Combination of Intra-alveolar/Interstitial Pattern *41*

4. Idiopathic Interstitial Pneumonia **45**

- Idiopathic Pulmonary Fibrosis *50*
- Nonspecific Interstitial Pneumonia *50*
- Cryptogenic Organizing Pneumonia *51*
- Respiratory Bronchiolitis-associated Interstitial Lung Disease *52*
- Desquamative Interstitial Pneumonia *53*
- Lymphoid Interstitial Pneumonia *54*
- Acute Interstitial Pneumonia *54*

5. Connective Tissue Disease **56**

- Scleroderma *57*
- Rheumatoid Arthritis *57*
- Systemic Lupus Erythematosus *58*

6. Inhalational Lung Disease **60**

- Hypersensitivity Pneumonitis *60*
- Smoking Related Lung Disease *61*
- Respiratory Bronchiolitis: Interstitial Lung Disease *62*
- Desquamative Interstitial Pneumonitis *62*
- Pneumoconiosis *64*
- Silicosis *64*
- Coal Workers' Pneumoconiosis *65*

7. Eosinophilic Lung Disease **67**

- Classification of Eosinophilic Lung Diseases *67*
- Simple Pulmonary Eosinophilia *67*
- Acute Eosinophilic Pneumonia *68*
- Chronic Eosinophilic Pneumonia *68*
- Allergic Bronchopulmonary Aspergillosis *68*

8. Small Airways Disease **72**

- Direct Signs *72*
- Airtrapping and Mosaic Attenuation *73*
- Bronchiolitis *75*
- High Resolution Computed Tomography of Various Bronchiolitis *76*

9. Pulmonary Vasculitis **78**

- Wegener's Granulomatosis *79*
- Takayasu's Arteritis *79*
- Churg-Strauss Syndrome *80*
- Microscopic Polyangiitis *80*
- Behçet's Disease *81*
- Vasculitis Associated with Collagen Vascular Disease *81*
- Goodpasture Syndrome *81*

10. Infection in Immunocompetent and Immunocompromised **82**

- Role of Imaging in Infectious Disease *82*
- Imaging Patterns in Infection *82*

- Community-acquired Pneumonia *83*
- Hospital-acquired: Nosocomial Pneumonia *84*
- Aspiration Pneumonia *86*
- Atypical Pneumonia Syndrome *87*
- Immunosuppressed Host Pneumonia *87*
- Non-HIV Immunocompromised Patients *87*
- Infections in Transplant Recipients *87*
- Bone Marrow Transplantation *88*
- AIDS *89*
- Bacterial Infection *89*
- *Pneumocystis carinii* Pneumonia *89*
- Tuberculosis *90*
- Aspergillosis *92*
- CD4 Counts and Infections *93*

11. Malignancy **94**

- Solitary Pulmonary Nodule *95*
- Margin *97*
- Attenuation *97*

12. Congenital Disease **100**

- Pulmonary Agenesis *100*
- Bronchial Atresia *100*
- Congenital Lobar Emphysema *101*
- Congenital Cystic Adenomatoid Malformation *101*
- Bronchogenic Cyst *103*
- Sequestration *103*
- Tracheal Bronchus *104*
- Interruption of a Main Pulmonary Artery *105*
- Anomalous Pulmonary Venous Drainage *105*
- Pulmonary Arteriovenous Malformation *105*
- Pulmonary Artery Sling *107*
- Hypogenetic Lung (Scimitar) Syndrome *107*

13. Pulmonary Vascular Disease **109**

- Pulmonary Hypertension *109*
- Acute Pulmonary Thromboembolism *112*

14. Drug-induced Pulmonary Patterns **117**

PRACTICE CASES

Self-Training Module for Approach and Reporting **119**
Training Module **120**

- *Case 1*: Allergic Bronchopulmonary Aspergillosis (ABPA) *120*
- *Case 2*: Pulmonary Abscess *123*
- *Case 3*: Acute Interstitial Pneumonia *125*
- *Case 4*: Airtrapping *127*

- *Case 5*: Pulmonary Alveolar Microlithiasis *129*
- *Case 6*: Pulmonary Alveolar Proteinosis *131*
- *Case 7*: Architectural Distortion *133*
- *Case 8*: Acute Lung Injury [Acute Respiratory Distress Syndrome (ARDS)] *135*
- *Case 9*: Aspergilloma *137*
- *Case 10*: Aspiration Disease *139*
- *Case 11*: Chronic Asthma *141*
- *Case 12*: Azygos Lobe Marked by the Azygos Fissure *143*
- *Case 13*: Bronchioloalveolar Carcinoma (BAC) *145*
- *Case 14*: Basal Reticular Changes with Fibrosis *147*
- *Case 15*: Bronchial Atresia *149*
- *Case 16*: Bronchiectasis *151*
- *Case 17*: Bronchiolectasis *154*
- *Case 18*: Bronchiolitis *156*
- *Case 19*: Bronchogenic Cyst *159*
- *Case 20*: Broncholithiasis *161*
- *Case 21*: Bullous Disease *163*
- *Case 22*: Cavitary Parenchymal Lesions *165*
- *Case 23*: Central Distribution with Peripheral Sparing *167*
- *Case 24*: Churg-Strauss Syndrome *169*
- *Case 25*: Compensatory Hyperinflation *171*
- *Case 26*: Conglomerate Apical Masses *173*
- *Case 27*: Consolidation *175*
- *Case 28*: Pulmonary Cysts *177*
- *Case 29*: Emphysema versus Cystic Lung Disease *179*
- *Case 30*: Cystic Fibrosis *181*
- *Case 31*: Dark Bronchus Sign *183*
- *Case 32*: Desquamative Intestitial Pneumonia *185*
- *Case 33*: Combined Pulmonary Fibrosis and Emphysema *187*
- *Case 34*: Emphysematous Changes *189*
- *Case 35*: End Stage Destroyed Lung *191*
- *Case 36*: Endobronchial Lesions with Atelectasis *193*
- *Case 37*: Tracheoesophageal and Bronchopleural Fistula *195*
- *Case 38*: Pulmonary Hemorrhage *197*
- *Case 39*: CT Halo Sign *199*
- *Case 40*: Pulmonary Langerhans Cell Disease *201*
- *Case 41*: Honeycomb Pattern *203*
- *Case 42*: Paired Inspiratory and Expiratory Images *205*
- *Case 43*: Acute Hypersensitive Pneumonitis *207*
- *Case 44*: Kartagener's Syndrome *209*
- *Case 45*: Pulmonary Contusion—Laceration *211*
- *Case 46*: Lymphangioleiomyomatosis *213*
- *Case 47*: Loeffler's Syndrome or Simple Pulmonary Eosinophilia *215*
- *Case 48*: Lymphangitis Carcinomatosis *217*
- *Case 49*: Pulmonary Metastasis *219*
- *Case 50*: Metastatic Pulmonary Calcification *221*
- *Case 51*: Right Middle Lobe Syndrome *223*
- *Case 52*: Miliary Nodules—Koch's *225*
- *Case 53*: Mosaic Attenuation *227*
- *Case 54*: Nonspecific Interstitial Pneumonia *229*
- *Case 55*: Osteophyte Induced Atelectasis *231*
- *Case 56*: Pneumocystis Pneumonia *233*

- *Case 57*: Peripheral Distribution *235*
- *Case 58*: Pleural Calcification *237*
- *Case 59*: Pneumothorax *239*
- *Case 60*: Pseudotumor *241*
- *Case 61*: Pulmonary Edema *243*
- *Case 62*: Radiation Pneumonitis and Fibrosis *245*
- *Case 63*: Ranke's Complex *247*
- *Case 64*: Rasmussen's Aneurysm *249*
- *Case 65*: Respiratory Bronchiolitis *251*
- *Case 66*: Reticular Fibrotic Changes *253*
- *Case 67*: Reverse Halo Sign *255*
- *Case 68*: Rheumatoid-associated Interstitial Lung Disease *257*
- *Case 69*: Round Atelectasis *259*
- *Case 70*: Sarcoidosis *261*
- *Case 71*: Scleroderma UIP and NSIP Patterns *263*
- *Case 72*: Split Pleura Sign of Empyema *265*
- *Case 73*: Subpleural Line *267*
- *Case 74*: Tuberculous Osteomyelitis (Cold Abscess) *269*
- *Case 75*: Tracheomalacia *271*

Index *273*

Chapter

2

Overview of Lung Disease

INTRODUCTION

A wide range of acute and chronic pulmonary disorders is capable of diffusely affecting the lung parenchyma with variable amounts of inflammation, fibrosis, and architectural distortion. The pathologic features of these diseases, even if originating in the interstitium, regularly include structures that are well beyond it, including the alveolar space, small airways, vessels, and even the pleura.

In essence, without a clinical history, all diffuse lung diseases are of unknown cause and imaging interpretation in isolation is very difficult. For an accurate diagnosis, there is no substitute for a comprehensive clinical work-up. This should be considered the key diagnostic step in the evaluation of the patient who has diffuse lung disease. This includes a thorough history elicitation, with complete evaluation of the chief complaint; a comprehensive review of multiple body systems; identification of all medications or drugs, including over-the-counter and naturopathic medications; and an exhaustive review of past medical, social, family, and occupational histories with an exploration of all potential environmental exposures. Knowledge of the temporal profile of illness helps a lot in formulating an imaging opinion.

An organized approach to HRCT is critical for a reasonable diagnosis. The radiologic diagnosis of many pulmonary abnormalities is based on an assessment of their pattern and distribution (Figures 2-1A and B).

A practical approach to HRCT of the chest for diagnosis of diffuse lung diseases includes recognition of the abnormalities, definition of their distribution within the secondary lobule of the lung, identification of associated findings. When combined with

Temporal Profile of Various Diseases

Acute (Hours to Several Days)	*Subacute (Weeks to Several Months)*	*Chronic (Many Months to Years)*
Infection	Hypersensitivity pneumonitis	Rheumatic disease
Diffuse alveolar damage	Smoking-related disease	Drugs
Acute eosinophilic pneumonia	Sarcoidosis	Pneumoconiosis
Acute injury related to drugs	Rheumatic disease	Smoking-related disease
Acute injury related to fumes and toxins	Drugs	Sarcoidosis
Acute injury related to rheumatic disease	Infection	Alveolar proteinosis
Vasculitis	Alveolar proteinosis	Small-airways disease
Diffuse alveolar hemorrhage	Chronic eosinophilic pneumonia	Amyloidosis
Acute exacerbation to chronic disease	Cryptogenic organising pneumonia	Usual interstitial pneumonia
Acute interstitial pneumonia (idiopathic)	Non-specific interstitial pneumonia	Non-specific interstitial pneumonia
	Lymphoid interstitial pneumonia	

JAYPEE BROTHERS

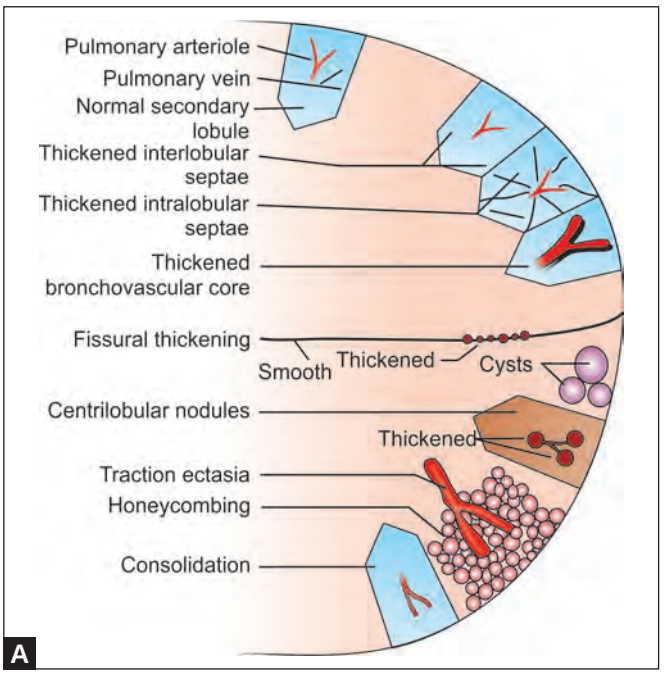

Figures 2-1A and B Patterns of lung disease in HRCT

the patient clinical history, these 3 steps allow to shortening the list of differential diagnoses and may sometimes lead to a specific diagnosis.

HRCT findings can be classified into two broad categories of increased and decreased lung attenuation. Within these categories they are further subclassified to facilitate organization and features like distribution of abnormalities in axial and coronal plane help in differential diagnosis.

Subcategories are:

- Linear and reticular opacities
- Nodules and nodular opacities
- Consolidation and ground-glass opacities
- Areas of decreased attenuation with walls
- Areas of decreased attenuation without walls.

LINEAR AND RETICULAR PATTERN

Thickening of the interstitial network of the lung by fluid, fibrous tissue, or because of interstitial infiltration by cells or other material primarily results in an increase in linear or reticular lung opacities as seen on HRCT. Linear and reticular opacities can be manifested by the interface sign, peribronchovascular interstitial thickening, interlobular septal thickening, intralobular interstitial thickening (reticular pattern), honeycombing, subpleural lines and bands.

INTERLOBULAR THICKENING

Interlobular septa are about 0.1 to 0.2 mm and are just at the level of detection by HRCT (Figures 2-2, 2-4 and 2-5).

Numerous clearly visible interlobular septa almost always indicate the presence of an interstitial abnormality; only a few septa are visible in normal patients usually anteriorly or along the pleural surfaces.

Interlobular septal thickening can be seen in the presence of interstitial fluid, infiltration or fibrosis. Interlobular septal thickening can be smooth, nodular, or irregular in contour in different pathological processes.



Figure 2-2 Axial HRCT showing diffuse interlobular septal prominence highlighting the pulmonary lobules

JAYPEE BROTHERS

Smooth septal thickening is seen in patients with pulmonary edema has also been reported in pulmonary veno-occlusive disease, lymphangitic carcinomatosis, lymphoma, alveolar proteinosis, interstitial infiltration associated with amyloidosis.

Nodular or "beaded" septal thickening is typical of disease that involve pulmonary lymphatics as in lymphangitic carcinomatosis, sarcoidosis, and silicosis or coal worker's pneumoconiosis. (produce architectural distortion).

Irregular interlobular septal thickening is usually seen in fibrosing lung disease.

INTRALOBULAR INTERSTITIUM: RETICULAR ABNORMALITIES

The intralobular interstitium is a fine network of very thin connective tissue fibers that surround small arteries and bronchioles and support the alveolar walls. Thickening of these fibers results in a fine reticular, or net-like appearance on HRCT (Figures 2-3A and B).

Fine reticular pattern typically is distributed in the peripheral parts of the lungs, mainly in the bases. Traction bronchiolectasis and bronchiectasis are often associated because of traction by fibrous tissue on the bronchial walls.

Bronchiectasis and bronchiolectasis are commonly irregular or varicose in contour on HRCT. This pattern is often seen in patients with nonspecific interstitial pneumonia and pulmonary disease associated with collagen vascular disease.

Reticular Pattern—Significance

- Thickening of the interstitial fiber network by fluid, fibrous tissue, other materials.
- Intralobular reticular pattern is characteristic of lung fibrosis.
- Traction bronchiectasis is often accompanied by other signs of lung fibrosis (honeycombing or irregular reticulation).

PERIBRONCHIAL INTERSTITIAL THICKENING

It is seen as an apparent thickening of the bronchial walls and an apparent increase in size of nodular appearance of pulmonary arteries and veins. This feature is most commonly associated with the other components of the reticular pattern. It is suggestive of sarcoidosis, lymphangitic carcinomatosis, lymphoma or Kaposi sarcoma (Figure 2-6).

Subpleural Interstitial Thickening

Thickening of subpleural interstitium is a finding usually seen along with the diseases, which cause septal thickening. Identification of subpleural thickening is usually difficult as the interstitium is usually adjacent to the pleura and chest wall, however along the fissures this abnormality appears more prominent due to the double subpleural layer and the adjacent lung interface.

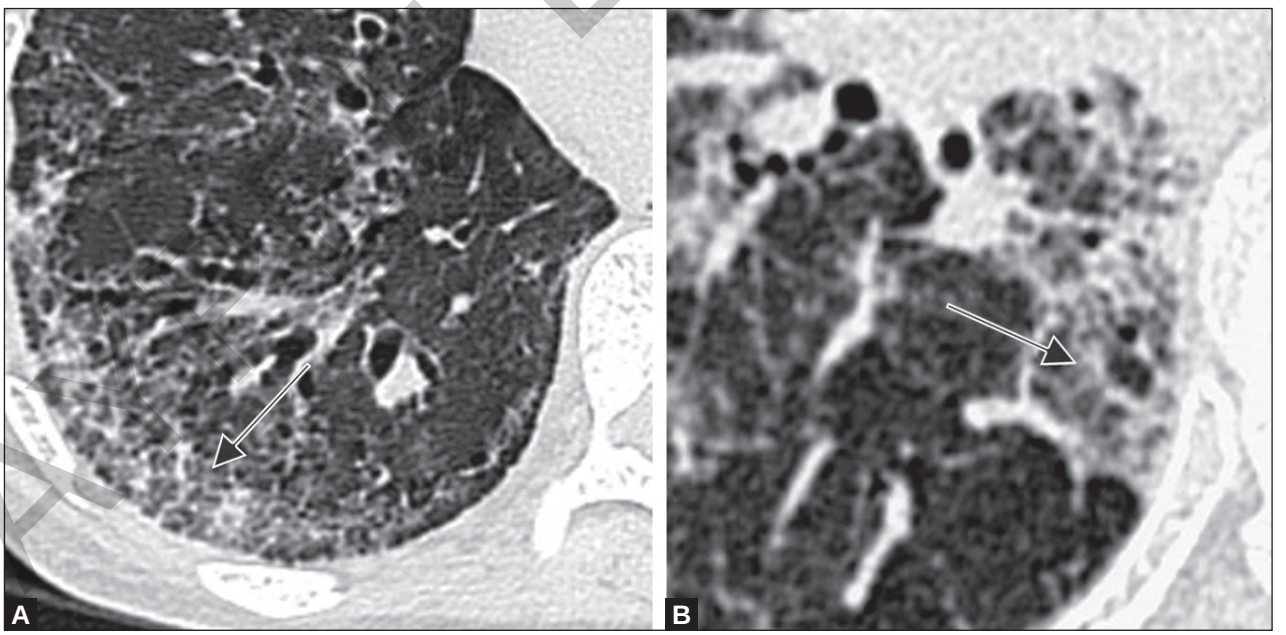

Figures 2-3A and B Axial HRCT sections showing intralobular changes manifested by reticular and ground-glass opacity associated with traction ectatic changes

JAYPEE BROTHERS

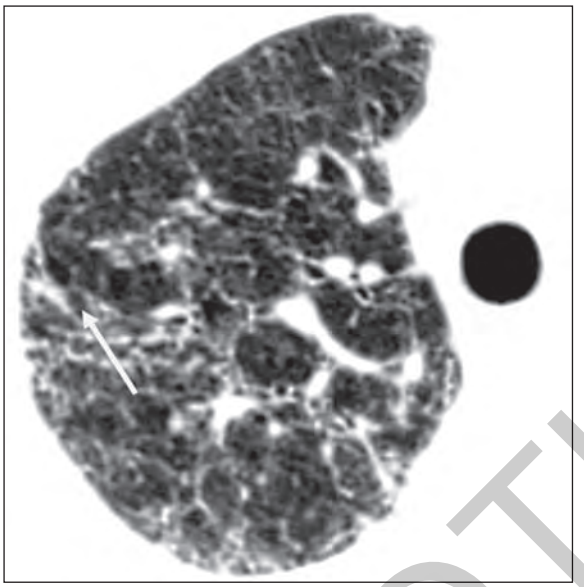

Figure 2-4 Axial HRCT sections highlighting reticular fibrotic changes

Types of Septal Thickening

Smooth	Nodular	Irregular
Pulmonary edema Lymphangitic spread of tumor Erdheim-Chester disease (Non-Langerhans cell histiocytosis)	Sarcoid Lymphangitic spread of tumor Lymphoproliferative disease	Fibrosis (IPF, HP, sarcoid, etc.)

IPF: Idopathic pulmonary fibrosis; and HP: Hypersensitivity pneumonitis

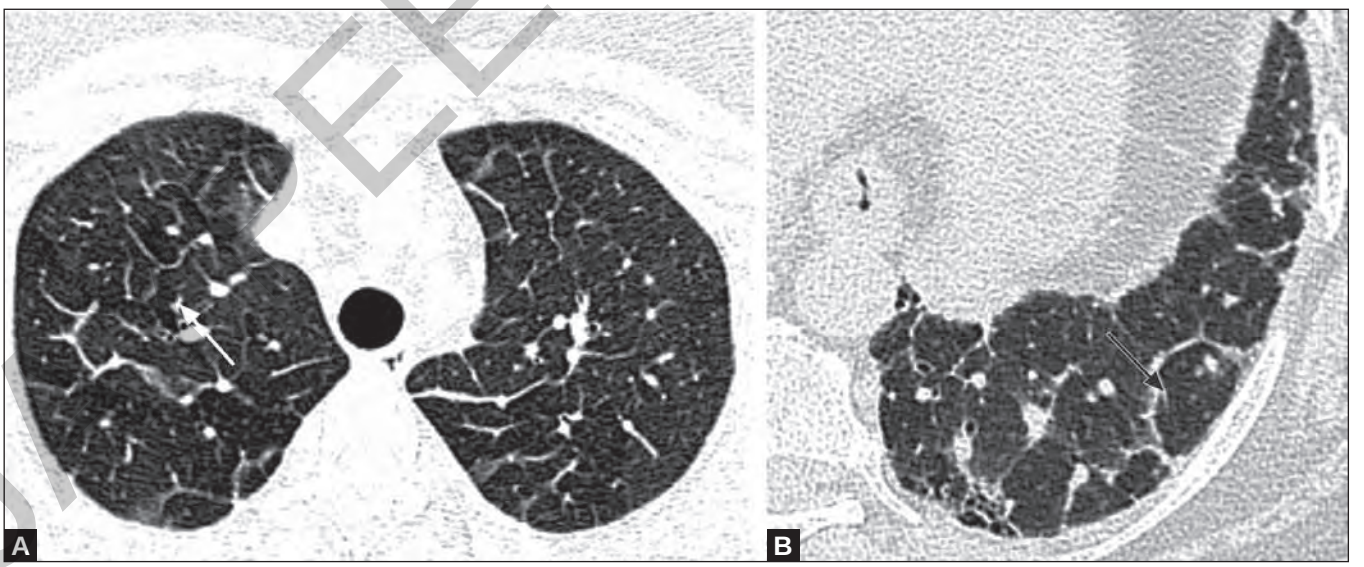

Figures 2-5A and B Axial HRCT image showing interlobular septal prominence with the centrilobular structures

JAYPEE BROTHERS



Figure 2-6 Axial HRCT showing thickening of peribronchial interstitium

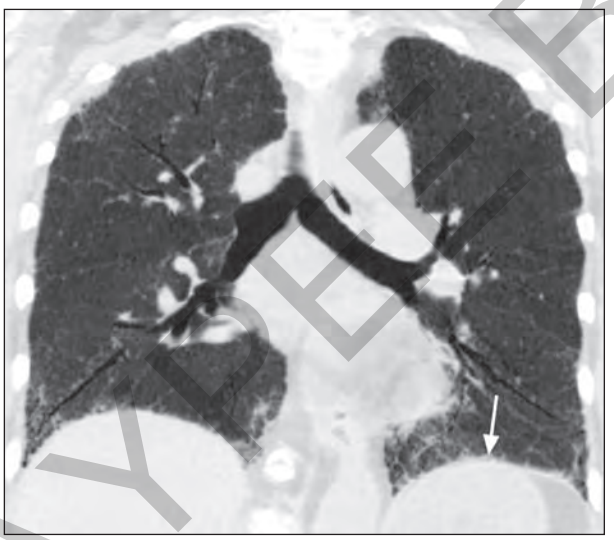

Figure 2-7 Coronal MinIP image showing subpleural reticular changes

In general, the differentials for subpleural interstitial thickening is the same as interlobular septal thickening however it is more commonly seen in patients with idiopathic pulmonary fibrosis and pulmonary fibrosis of any cause. It is also seen in collagen vascular disease and drug reaction (Figure 2-7).

Nodular thickening of subpleural interstitium is seen in patients with lymphangitis carcinomatosa, sarcoidosis and silicosis.

HONEYCOMBING

Honeycombing reflects the end stage of a number of diseases that cause parenchymal destruction with walls lined by bronchiolar epithelium and fibrous tissue. It presents a characteristic HRCT pattern, with subpleural, thick-walled cysts that share walls and, when advanced, are stacked in multiple layers (Figures 2-8A and B).

- Honeycombing
  - Usual interstitial pneumonia
    - Idiopathic pulmonary fibrosis (most common: 60–70%)
    - Collagen vascular disease (rheumatoid, scleroderma)
- Hypersensitivity pneumonitis
  - Nonspecific interstitial pneumonia
- Asbestosis
- Drug toxicity
- Reticulation associated with traction bronchiectasis
  - Usual interstitial pneumonia (usually associated with honeycombing)
  - More common when honeycombing absent
    - Hypersensitivity pneumonitis
    - Sarcoidosis
    - Nonspecific interstitial pneumonia

Parenchymal Band

The term parenchymal band has been used to describe non-tapering, reticular opacities, from 2 to 5 cm in length that can be seen in patients with pulmonary fibrosis or other causes of interstitial thickening. These lines are usually peripheral and contact the pleura. Parenchymal bands are more commonly a result of contiguous septal lines or occasionally a result of peribroncho vascular fibrosis,

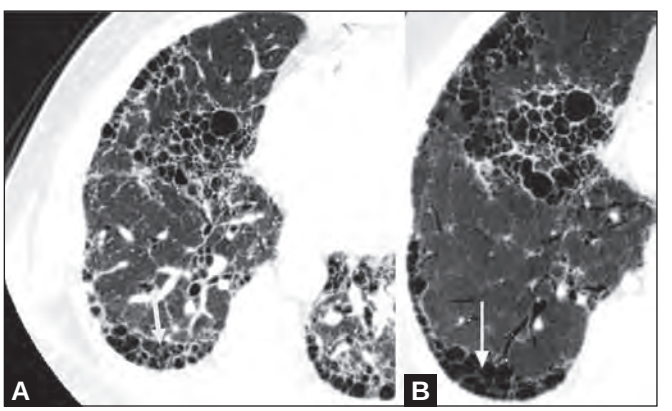

Figures 2-8A and B Axial HRCT with MinIP projections showing honeycombing

JAYPEE BROTHERS



Figure 2-9 Axial HRCT showing parenchymal band

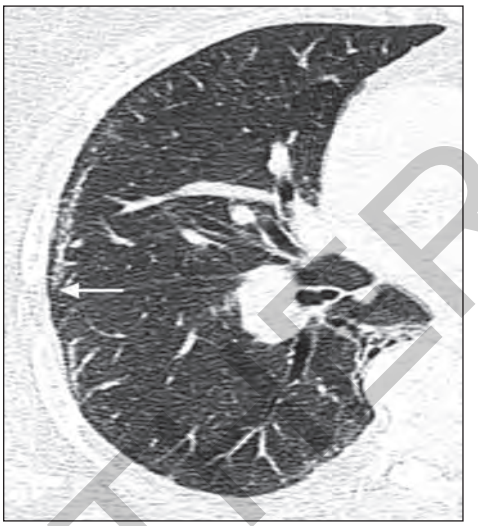

Figure 2-10 Axial HRCT showing subpleural line

coarse scars or atelectasis associated with lung or pleural fibrosis (Figure 2-9).

Parenchymal bands have been reported most commonly in patients with asbestos related lung (upto 60%) in association with pleural thickening, sarcoidosis with interstitial fibrosis, silicosis associated with progressive massive fibrosis and conglomerate masses, and tuberculosis.

Subpleural Lines

A curvilinear opacity a few mm thick, less than 1 cm from the pleural surface, and paralleling the pleura is described as subpleural lines (Figure 2-10).

Subpleural lines are a result of confluence of peribronchiolar interstitial abnormalities in patients with asbestosis, which represent early fibrosis with associated alveolar flattening and collapse. Subpleural lines are seen primarily in asbestosis, scleroderma and at times in normal patients which are the result of dependent density.

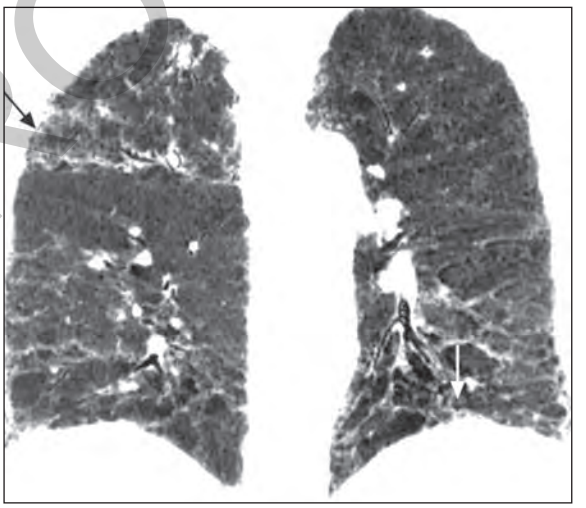

Figure 2-11 Coronal HRCT in MinIP projection showing irregular fibrotic changes

IRREGULAR LINEAR OPACITY

These opacities are nonspecific linear structures that cannot be classified as parenchymal band, subpleural line or interlobular septae. They range in thickness from 1 to 3 mm and are most commonly seen in fibrotic diseases (Figure 2-11).

Interface Sign

The presence of irregular interfaces between the aerated lung parenchyma and bronchi, vessels or the visceral pleural surface, has been termed interface sign by Zerhouni et al (Figure 2-11).

This sign is seen in patients with interstitial abnormalities regardless of cause. It is associated with increased lung reticulation. These linear opacities generally represent thickened inter and intralobular interstitial fibers. This sign is frequently seen in patients with fibrotic lung disease.

NODULES

Pulmonary nodule may be defined as any relatively sharp, discrete nearly circular opacity ranging in size from 2 to 30 mm. Micronodule is also used when describing HRCT findings usually referring to nodules less than 3 to 7 mm.

JAYPEE BROTHERS

Nodules can be further divided based on their size, border, density, number and location such as well-defined vs poorly-defined; upper vs lower lobe distribution; and relationship to the secondary pulmonary lobule. The last is the most useful characteristic, since it provides a focused differential diagnosis and is reflective of the underlying disease pathophysiology.

The assessment of nodule characteristics is predominantly based on the borders (sharp or blurred) and the density (solid or groundglass) of these nodules. Using these characteristics, lung nodules can often be divided into interstitial nodules and airspace nodules.

Histopathologically, atleast 4 nodule distributions within the secondary pulmonary lobule are recognized: 1. Bronchiolocentric, 2. Angiocentric, 3. Lymphatic, 4. Random.

Nodules that are bronchiolocentric in distribution are related to the centrilobular and lobular bronchi and angiocentric nodules are related to the pulmonary arteries within the secondary lobule. As both the nodule types are located in or very near the center of secondary lobules they are not distinguished from one another in HRCT and are grouped as centrilobular nodules.

There are three possible HRCT distributions of nodules: centrilobular, perilymphatic, random.

CENTRILOBULAR

These are distributed primary in the center of the secondary pulmonary lobule, therefore these can result from bronchiolar,

Pathophysiology Features of Common Abnormalities

Intralobular	*Centrilobular*	*Septal Line*
The development of the intralobular reticular pattern is predominantly related to: Interstitial lung disease	The development of centrilobular branching lines is predominantly related to: Thickening of the distal peribronchovascular interstitium	The development of septal lines can be related to: The presence of interstitial lung disease. Disease in and around the lymphatics
Airspace disease predominantly located in the periphery of the acini	Disease in and around the centrilobular lymphatics	Venous congestion. Airspace disease predominantly located in the periphery of the secondary pulmonary lobule (perilobular location)
The intralobular reticular pattern may be seen in association with ground-glass opacity creating the crazy-paving pattern.	Disease affecting the centrilobular bronchioles and arterioles.	Smooth septal thickening is often seen in association with ground-glass opacity, creating the crazy paving pattern
When fibrosis is present, very small honeycomb cysts measuring about 1 mm in diameter can become visible	Centrilobular branching lines caused by bronchiolar disease are mostly associated with the presence of centrilobular nodules creating the *tree-in-bud* pattern	Irregular septal thickening may indicate the development of fibrosis
	When fibrosis is present, intralobular bronchioles can become visible (bronchiolectasis)	

Pathology of Nodules

Airspace Nodules	*Interstitial Nodules*
Airspace nodules are usually caused by a replacement of alveolar air by fluid and/or cells	Interstitial nodules are usually caused by a nodular cellular proliferation in the interstitium
Usually ill-defined	Interstitial nodules are mostly sharply defined and have in most cases a soft-tissue attenuation
Airspace nodules are mostly located near the center of the secondary pulmonary lobule but can, when disease progresses, involve the entire lobule	Most interstitial nodules are related to diseases that show a vascular or a perilymphatic distribution
Airspace nodules can be grouped in a cluster or rosette and when associated with the presence of intralobular branching lines can create the *tree-in-bud* pattern	Conglomeration of interstitial nodules can cause larger nodules and masses
Merging of airspace nodules can be responsible for the development of larger nodules and areas of ground-glass opacity and lung consolidation	

JAYPEE BROTHERS

peribrochiolar as well as vascular and perivascular disease. These range in size from few mm to slightly more than 10 mm they may be well or ill-defined and may or may not be associated with a *tree-in-bud* pattern.

This pattern may be recognized when the nodules are evenly spaced from one another and do not contact the visceral pleural surfaces (Figures 2-12 and 2-13). The nodules are usually positioned about 5 to 10 mm from the visceral pleural surface (Figures 2-14 and 2-15).

Tree-in-bud pattern reflects the presence of impaction of centrilobular bronchus with mucus, pus or fluid resulting in dilatation of bronchus associated with peribronchiolar infection. May be associated with Y and V-shaped structures on HRCT and likened to a budding tree in spring. This morphology is usually seen in infections (Figure 2-16).

When *tree-in-bud* morphology is absent apart from infectious process other non infectious and vascular lesions have to be considered.

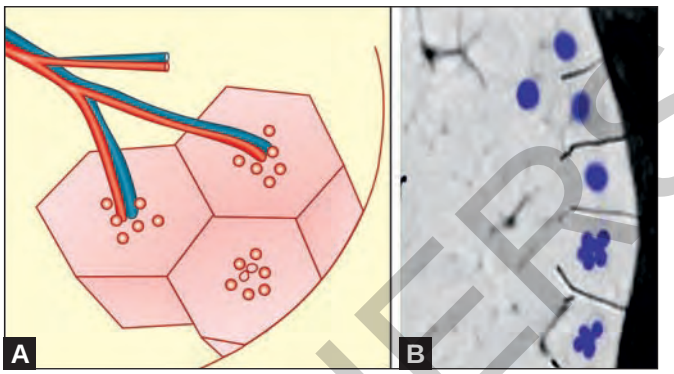

Figures 2-14A and B Schematic diagram of centrilobular pattern

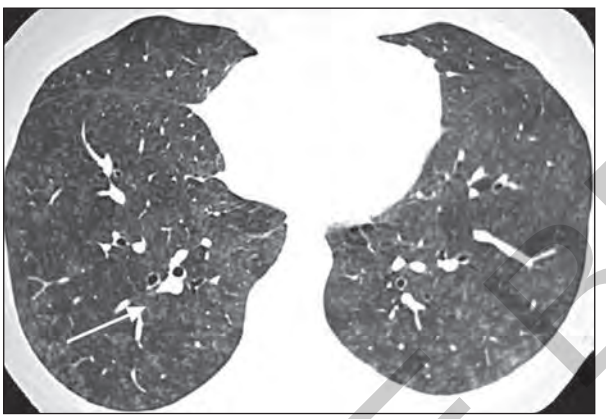

Figure 2-12 Axial HRCT image highlighting the marginated centrilobular nodes in hypersensitive pneumonitium



Figure 2-15 Axial HRCT image showing a mixture of *tree-in-bud* and centrilobular nodules

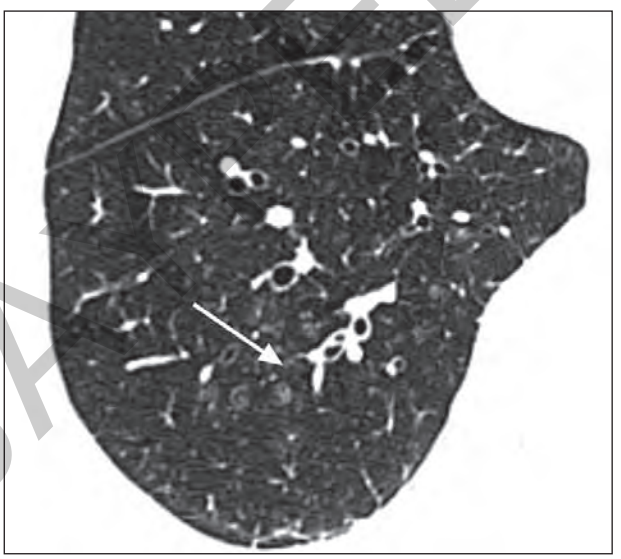

Figure 2-13 Magnified HRCT image of centrilobular nodule

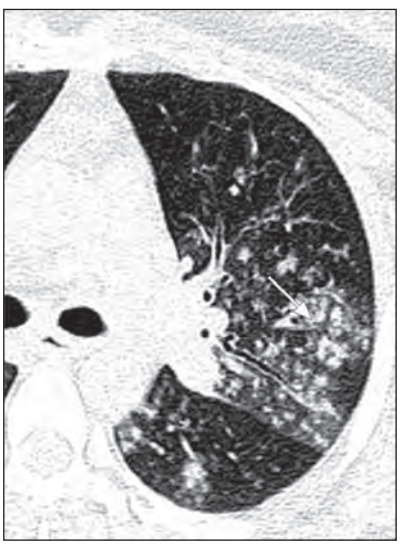

Figure 2-16 Coronal HRCT image showing *tree-in-bud* pattern

JAYPEE BROTHERS

Well-defined nodules in the posterior upper lobes associated with subpleural nodules—silicosis.

Poorly defined nodules distributed evenly from apex to base are characteristic of subacute HP.

Well-defined nodules associated with Bizarre cysts in upper lobe in smokers characterize histiocytosis.

Centrilobular Nodules

- Small airways or vascular disease
- Most peripheral nodules spaced 5 to 10 mm from pleura
- Evenly distributed
- Diffuse or patchy
- Differential diagnoses
  - Well-defined nodules
    - Endobronchial infection (e.g. bronchopneumonia)
    - Endobronchial tumor (e.g. bronchioloalveolar cell carcinoma)
    - Aspiration
  - Ill-defined ground-glass nodules
    - Hypersensitivity pneumonitis
    - Respiratory bronchiolitis
    - Follicular bronchiolitis
    - Langerhans cell histiocytosis
    - Vascular causes (e.g. edema and hemorrhage)

Tree-in-Bud Pattern

- Infection
  - Bronchopneumonia
  - Tuberculous and nontuberculous mycobacteria
  - Fungal infection
  - Viral
- Infectious variants
  - Cystic fibrosis
  - Allergic bronchopulmonary disease (ABPA)
- Noninfectious causes
  - Bronchioloalveolar carcinoma
  - follicular bronchiolitis
  - Intravascular metastases

RANDOM

Random nodules are defined by their seemingly haphazard occurrence in peribronchovascular regions, interlobular septa, and pleura, without a consistent perilymphatic pattern and absence of a consistent relationship with the secondary pulmonary lobule. Usually they show bilateral and relatively symmetrical distribution (Figures 2-17A and B).

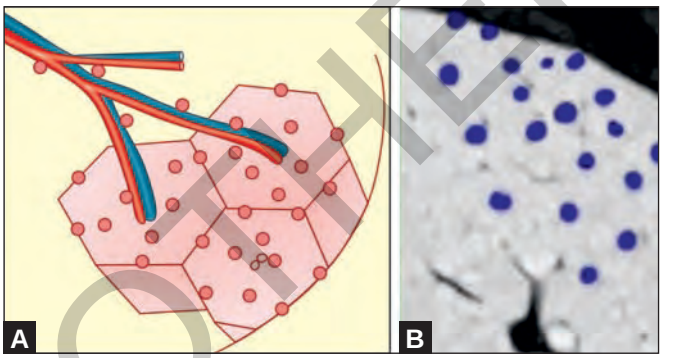

Figures 2-17A and B (A) Schematic diagram highlighting random nodular; (B) Pattern

Random Pattern

- Hematogenously spread diseases
- Rarely lymphatic disease can appear random
- Uniform, symmetric distribution

Differential diagnoses

- Miliary tuberculosis
- Miliary fungal infection (e.g. histoplasmosis, coccidiodomycosis) (Figures 2-18A and B)
- Hematogenous metastases

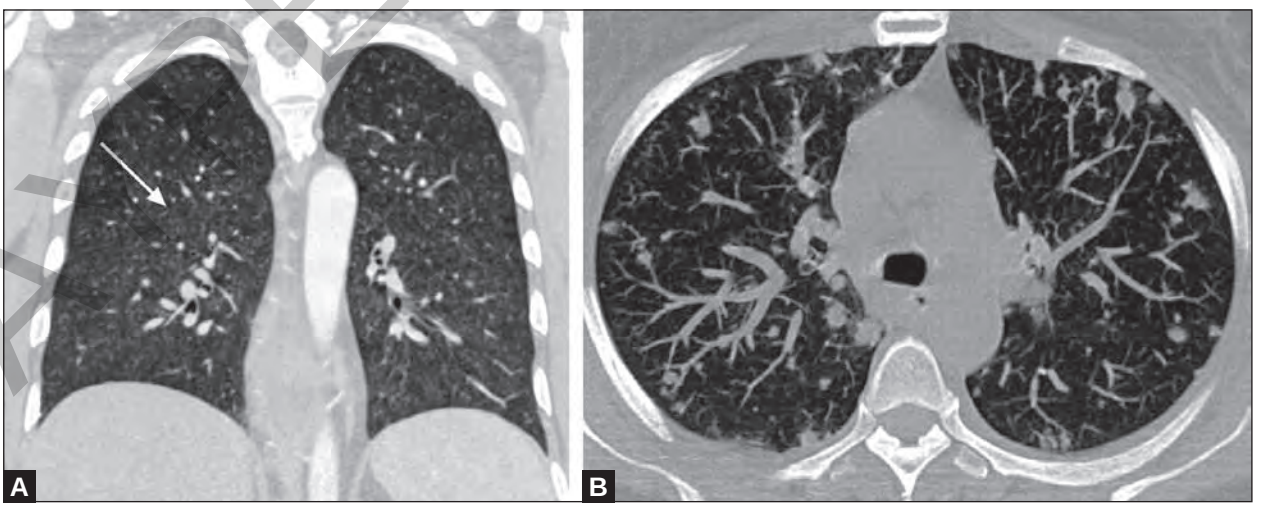

Figures 2-18A and B (A) Coronal HRCT imaging in case of miliary TB; (B) Axial MIP images in case of metastasis

JAYPEE BROTHERS

PERILYMPHATIC

- Primary lymphatic disease or disease involving lymphatics
- Well-defined nodules
- Patchy, clustered abnormalities
- Affected structures
  - Bronchovascular interstitium
  - Centrilobular region
  - Interlobular septa
  - Subpleural region
- Differential diagnosis
  - Sarcoidosis
  - Lymphangitic spread of tumor (Figure 2-21)
  - Silicosis (uncommon)
  - Lymphoid interstitial pneumonia (rare)

Pulmonary lymphatics are normally found within the visceral pleura, interlobular septae and along the veins and bronchovascular bundles so diseases involving the lymphatics such as lymphangitic carcinomatosis, sarcoidosis, lymphoproliferative disorders produce nodules in these structures (Figure 2-19).

These nodules are seen in HRCT as nodules that abut costal and fissural pleural surfaces in a patchy distribution. Some overlaps are seen with centrilobular nodules as lymphatics are seen along the bronchovascular bundle, however they are found along the visceral pleura and interlobular septum and not within the center of pulmonary lobule (Figures 2-20A and B).

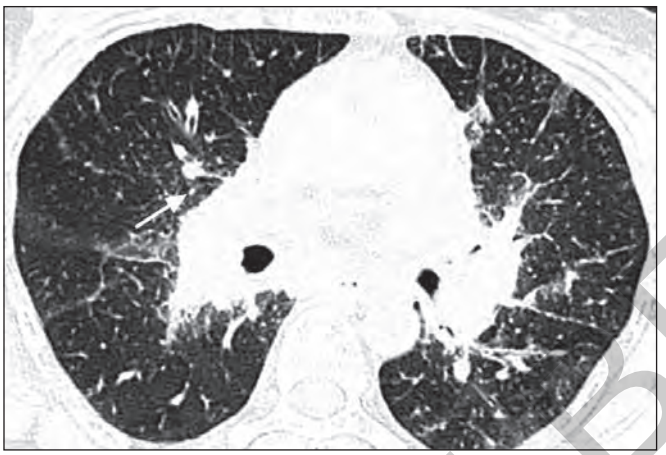

Figure 2-19 Axial HRCT showing central perilymphatic nodules in a case of sarcoidosis

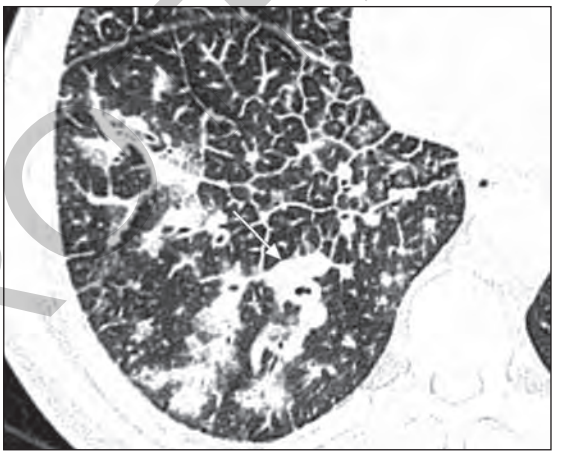

Figure 2-21 Septal thickening with associated nodular infiltrates in lymphangitis

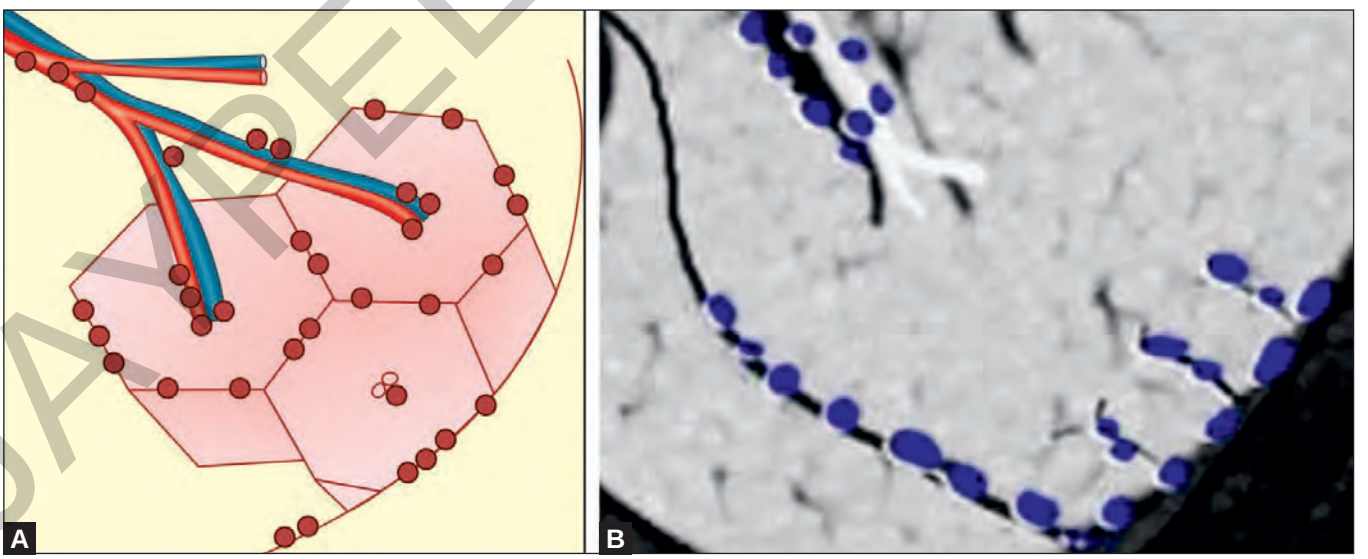

Figures 2-20A and B Schematic diagram showing perilymphatic pattern

JAYPEE BROTHERS

Large Nodules

These include nodules of more than 1 cm in diameter. The term mass is used for nodules of more than 3 cm in diameter. Many conditions that cause small nodules may progress to develop large nodules. Nodules may coalesce with each other forming conglomerate masses or nodules.

In 50% of patients with sarcoidosis confluent nodules are seen. These are usually peribronchovascular, irregular and associated with traction bronchiectasis.

In progressive fibrotic lung disease, large masses of fibrous tissue surround the bronchi within the central and perihilar lung. The bronchi may show collapse as a result of mass effect or dilatation due to traction bronchiectasis. Similar findings can be seen in post treatment tuberculosis.

Patients with silicosis and coal workers' pneumoconiosis which have developed progressive massive fibrosis show evidence of conglomerate mass typically in the upper lobe with absence of traction bronchiectasis, however, areas of emphysema adjacent to the conglomerate mass is common.

Focal fibrotic masses as a result of asbestos exposure are considered to be a result of round atelectasis or fibrotic scarring. Round atelectasis occurs most commonly in posterior lung or paravertebral region. It is associated with folding of lung and volume loss with traction of bronchi and vessels towards it giving an appearance of 'comet tail.' Round atelectasis may show an air bronchogram.

GROUND-GLASS OPACITY

Ground-glass opacity (GGO) is defined as hazy increased attenuation that does not obscure visibility of underlying vasculature (Figure 2-22A).

Ground-glass opacity reflects minimal thickening of the septal or alveolar interstitium, thickening of alveolar walls, or the presence of cells or fluid partially filling the alveolar spaces. Ground-glass opacities can be geographic involving only a certain segment of the lung, or it can involve the entire lobule or at times it may involve the centrilobular region, giving the appearance of ill-defined centrilobular nodules. The presence of air-filled bronchus that appears too black within an area of lung can also be a clue as to the presence of ground-glass opacities (black bronchus sign) (Figure 2-22B). Ground-glass opacity is highly a significant finding and it often indicates the presence of an ongoing, active and potentially a treatable process. At times ground-glass opacity may suggest the presence of fibrosis.

- Ground-glass opacity is defined as a hazy increase in lung density with preservation of airway and vessel margins.
- Ground-glass opacity occurs when there is a mild decrease in the amount of air in the airspaces and when there is a mild increase in size and/or amount of the soft tissue structures, two phenomena that often occur simultaneously.
- Both acute and subacute or chronic lung diseases can be responsible for the appearance of ground-glass opacity, although the presence of traction bronchiectasis and honeycombing suggest chronic disease as a cause.

CONSOLIDATION

Increased lung attenuation with obscuration of underlying pulmonary vessel is referred to as consolidation. Air bronchograms may be present (Figure 2-23).

- Consolidation is defined as an increase in lung density with obscuration of the underlying vessels and airway walls; an air bronchogram may be present.
- Replacement of the alveolar air by fluid, cells, tissue or some other substances is the most frequent cause of consolidation.

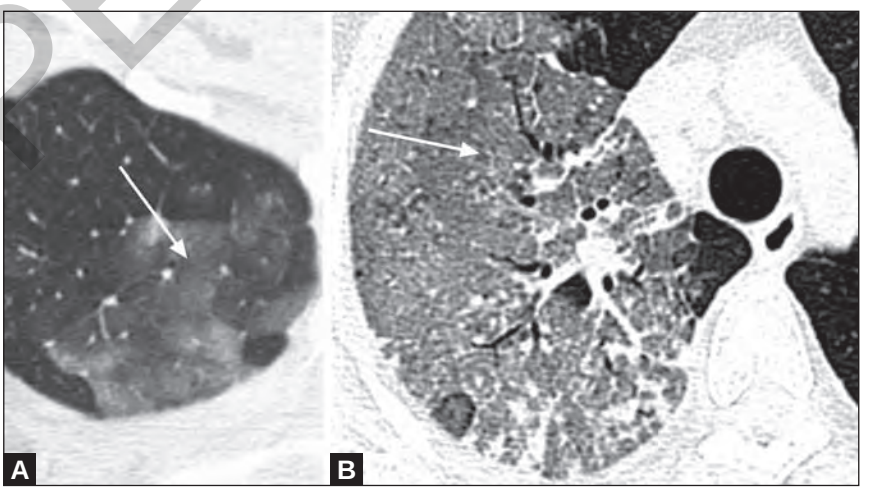

Figures 2-22A and B (A) Axial HRCT image showing classical ground-glass opacity; (B) Axial HRCT showing black bronchus sign in diffuse ground-glass opacity

JAYPEE BROTHERS

Patterns of Ground-Glass Opacity	
Acute	*Chronic*
• Edema	• Hypersensitivity pneumonitis
• DAD/ARDS/AIP	• Smoking-related interstitial lung disease (RB-ILD, DIP)
• Infections (bacterial, viral, *Pneumocystis jiroveci*, *Mycoplasma pneumoniae*)	• Interstitial pneumonia (NSIP, rarely UIP)
• Hemorrhage	• Bronchioloalveolar carcinoma
• Hypersensitivity pneumonitis	• Organizing pneumonia
• Eosinophilic pneumonia (acute)	• Lymphoid interstitial pneumonia
• Radiation pneumonitis (acute)	• Eosinophilic pneumonia (chronic)
	• Exogenous lipoid pneumonia
	• Alveolar proteinosis
	• Sarcoidosis

DAD: Diffuse alveolar damage; ARDS: Acute respiratory distress syndrome; AIP: Acute interstitial pneumonia; RB-ILD: Respiratory bronchiolitis-associated interstitial lung disease; DIP: Desquamative interstitial pneumonia; NSIP: Nonspecific interstitial pneumonia; UIP: Usual interstitial pneumonia

Distribution of Ground-Glass Opacity		
Focal	*Diffuse/Symmetric*	*Patchy*
Infection	Edema	Infection
Aspiration	DAD/ARDS/AIP	Sarcoid
Hemorrhage	Infections (viral, atypical)	Hypersensitivity pneumonitis
Bronchoalveolar cell carcinoma	Interstitial pneumonias	Organizing pneumonia
Infarct	Hemorrhage	Bronchoalveolar cell carcinoma
	Bronchoalveolar cell carcinoma	Hemorrhage
	Alveolar proteinosis	Eosinophilic pneumonia

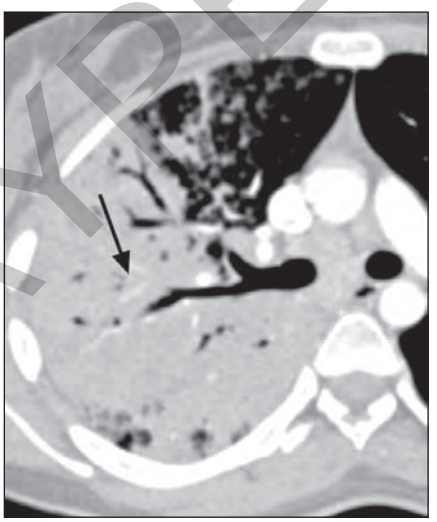

Figure 2-23 Axial HRCT showing consolidation—air bronchograms

Consolidation is seen in diseases that replaces the alveolar air by fluid, cells, tissue or other material but diseases that produce extensive, confluent interstitial abnormalities such as usual interstitial pneumonia and sarcoidosis can also produce consolidation pattern.

The differential diagnosis of ground-glass and consolidation opacities should be based upon the host immune status and duration of symptoms. The presence of connective tissue diseases, environmental inhalants, and drug use also should be considered when increased diffuse lung opacity is present.

Significance of these lesions will depend on the temporal line of illness (acute, subacute, chronic).

LUNG CALCIFICATION AND INCREASED LUNG OPACITY

Multifocal lung calcification, often associated with lung nodules has been reported in association with infectious granulomatous

JAYPEE BROTHERS

diseases such as tuberculosis, sarcoidosis, silicosis, talcosis, amyloidosis, and fat embolism associated with ARDS.

Diffuse and dense lung calcification can be seen in presence of metastatic calcification, disseminated pulmonary ossification, or alveolar microlithiasis. Diffuse and increased lung attenuation in the absence of calcification can be seen as a result of amiodarone lung toxicity (Figures 2-25A and B).

An entity called metastatic calcification is referred to deposition of calcium within lung parenchyma which can occur due to hypercalcemia in patients with abnormal calcium and phosphate metabolism and is the most common in patients with chronic renal failure and secondary hyperparathyroidism. Metastatic calcification is typically interstitial and can be associated with secondary lung fibrosis (Figure 2-26).

Alveolar microlithiasis is a term used for widespread intra-alveolar calcification so-called microlith or calcisphere. These microliths have a posterior and lower lobe preponderance with a high concentration in subpleural, parenchymal, intralobular and centrilobular interstitium (Figure 2-27).

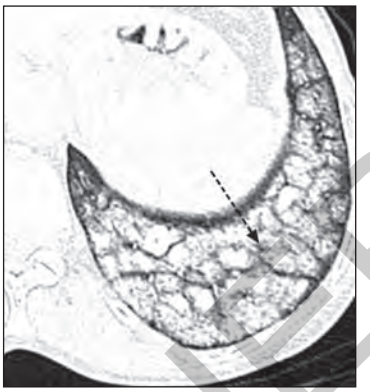

Figure 2-26 Axial HRCT showing high attenuation alveolar opacities in patient with metastatic pulmonary calcification

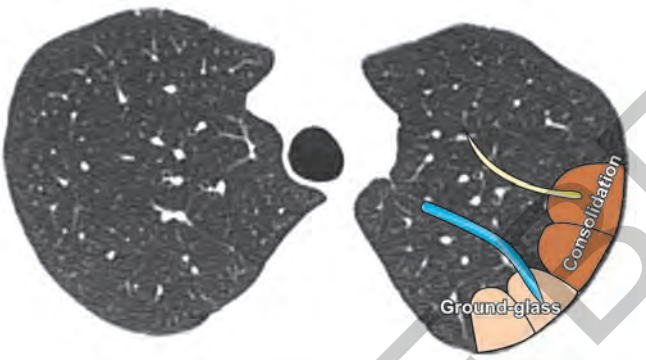

Figure 2-24 Schematic diagram differentiating ground-glass opacity and consolidation

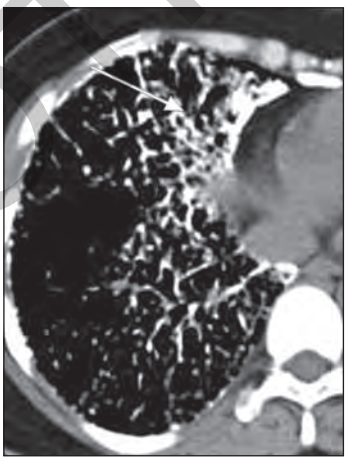

Figure 2-27 Axial HRCT showing high attenuation parenchyma in mediastinal window

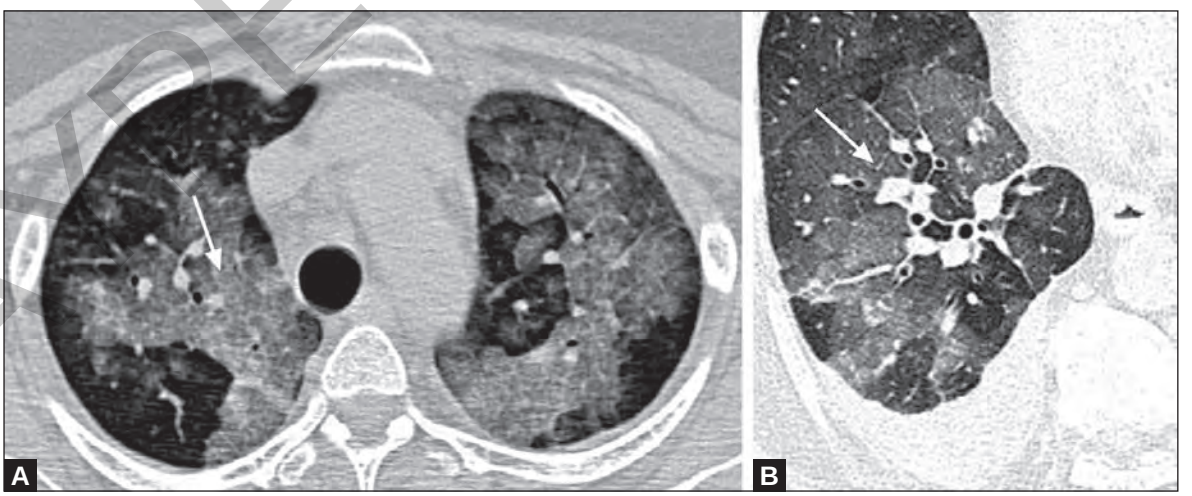

Figures 2-25A and B Axial HRCT images showing ground-glass opacity producing mosaic attenuation

JAYPEE BROTHERS

for detailed information on radiology books, visit our website www.jaypeebrothers.com, for detailed information on radiolo

HIGH RESOLUTION COMPUTED TOMOGRAPHY *of the* LUNGS

A Practical Guide

Salient Features

- Provides a good visual guidance for pattern reading with more than 400 High Resolution Computed Tomography (HRCT) and Volume HRCT images
- To know and learn different appearances and distribution patterns of lung disease
- Concise overview for daily clinical reporting
- Ideal for residents, trainee radiologists, pulmonologists and physicians associated with diffuse lung disease.



D Karthikeyan is a Senior Consultant Radiologist with special interests in the field of pulmonary and cardiovascular imaging. Computed Tomography (CT) has assumed a central position in the modern management of both focal and diffuse airway diseases. Conventional and multidetector HRCTs have become commonly requested techniques in present scenario. Multidetector CT provides high resolution volumetric datasets that allow the generation of high-quality multiplanar and three-dimensional images of the airways and lung parenchyma, familiarity with these techniques, is critical for the radiologists and pulmonologists for accurate diagnosis.

Available at all medical book stores
or buy directly from Jaypee Brothers through online shopping
at www.jaypeebrothers.com

JAYPEE BROTHERS
Medical Publishers (P) Ltd.
www.jaypeebrothers.com

Join us on facebook.com/jaypeebrothers

Shelving Recommendations
PULMONOLOGY, RADIOLOGY

ISBN 978-93-5090-408-4