etailed information on urology books, visit our website www.jaypeebrothers.com, for detailed information on urology books, visit our website www.jaypeebrothers.com

Atlas of UROTHROPLASTY

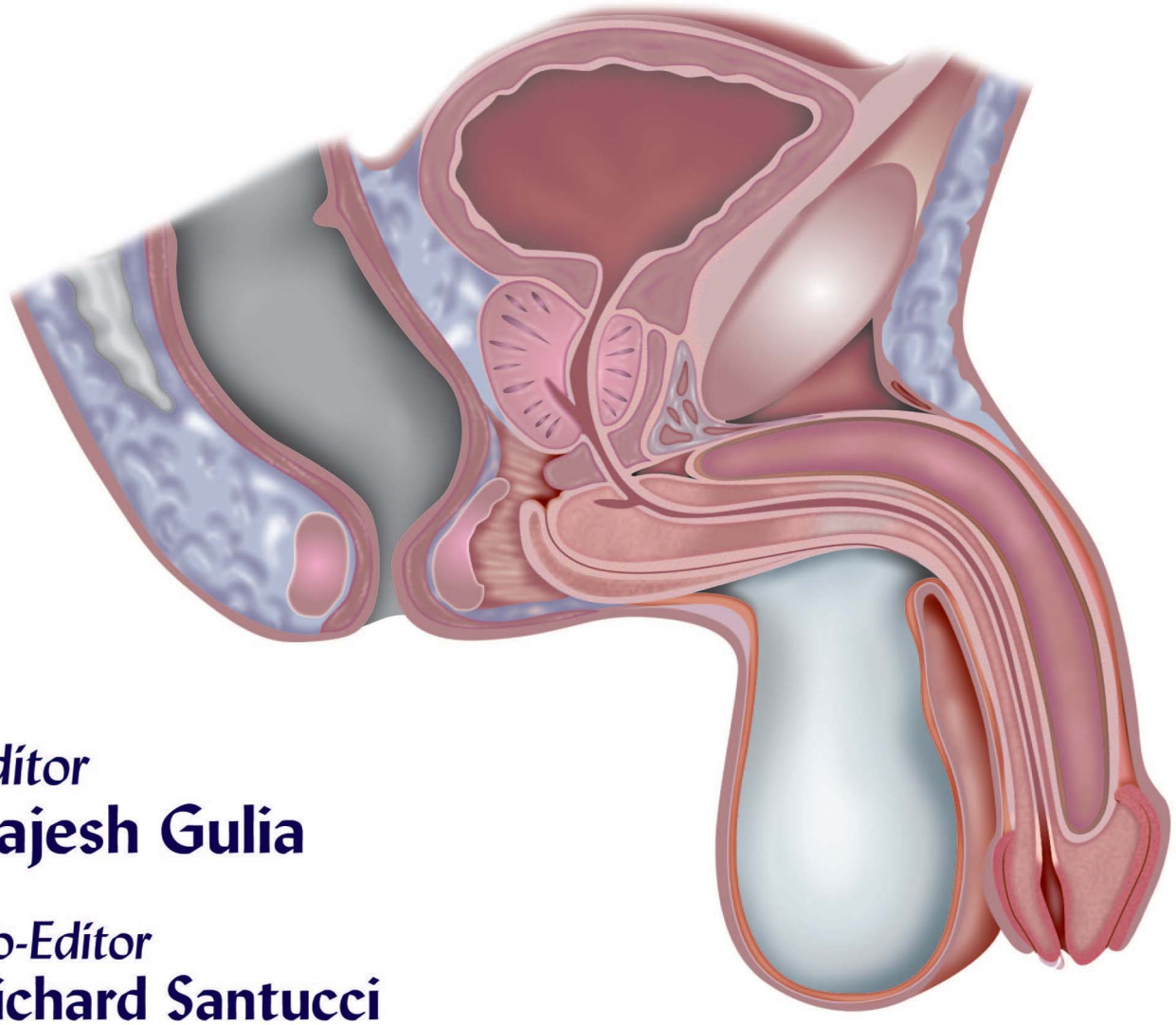

Editor
Rajesh Gulia

Co-Editor
Richard Santucci



Includes 2
Interactive DVD-ROMs
Containing 10 Videos
Duration 5 hours (approx)

Foreword
Sanjay B Kulkarni

JAYPEE

Contents

1. Back to the Basics: Penoscrotal Anatomy **1**
Steven B Brandes, Lucas R Wiegand

Genital Flap Selection 1
Penoscrotal Fascial Anatomy 1
Penile Vascular Anatomy 2
Scrotal Vascular Anatomy 4
Surgical Pearls 5

2. Urethral Stricture Disease: Etiology, Pathophysiology and its Economic Impact **11**
Sean P Elliott, Rodrigo A Campos

Incidence 11
Etiology 11
Histology 13
Pathophysiology of Stricture Urethra 13
Economic Impact 15
Editorial Comments 16

3. Imaging in Stricture Urethra **19**
Sanjay B Kulkarni, Pankaj M Joshi

X-Ray Kidney, Ureter, Bladder 19
Retrograde Urethrogram 19
Micturating Cystourethrogram 20
Up and Downogram 21
Pericatheter Urethrogram 22
Normal Anatomy of the Urethra on Urethrogram 22
Ultrasonography 23
Magnetic Resonance Imaging 24
Conclusion 24
Editorial Comments 24

4. The Role of Urethrotomy and Other Minimally Invasive Interventions **28**
Richard Santucci, Mang L Chen

Urethral Dilation and Direct Visual Internal Urethrotomy 29
Stents 30
Endoscopic Realignment of PFUDD 30
Endoscopic Urethroplasty 33
Conclusion 34

5. Fossa Navicularis and Meatal Strictures **36**
Geoffrey R Nuss, Chris M Gonzalez

History 36
Technique 37
Editorial Comments 43

6. Anastomotic Urethroplasty **44**
Sanjay B Kulkarni

Indications 45
Investigations 45
Preoperative Preparation and Anesthesia 45
Operative Steps 46
Anastomotic Urethroplasty: Concepts 50
Complications of Anastomotic Urethroplasty 51
Outcomes of Anastomotic Urethroplasty 52
Anastomotic Urethroplasty in Nontraumatic Bulbar Urethral Strictures (Especially the Very Short Segment Ones) 52
Editorial Comments 53

7. Bulbar Oral Graft: Buccal Mucosal Graft, Urethroplasty **55**
Guido Barbagli, Salvatore Sansalone, Giuseppe Romano, Massimo Lazzeri

Preoperative Investigations 56
Patient Preparation 56
Ventral Oral Mucosal Graft Urethroplasty 57
Dorsal Oral Mucosal Graft Urethroplasty 63
Augmented Anastomotic Repair Using Oral Graft 69
Postoperative Care after Bulbar Urethroplasty Using an Oral Graft 74

8. Free Graft Urethroplasty by Ventral Sagittal Urethrotomy Approach **76**
HS Asopa, AL Vyas, GG Singhal

Preoperative Evaluation 76
Surgical Techniques 77
Results of Ventral Sagittal Urethrotomy Approach 82
Comments 82
Editorial Comments 86

9. Penile Fasciocutaneous Flap: McAninch Procedure **88**
BA Erickson, JW McAninch

Flap Anatomy 88
Patient Selection 89
Surgical Technique 89
Outcomes 93
Complications 93
Alternatives to the McAninch Flap 94

10. Staged Urethral Reconstruction **95**
Ramón Virasoro, Gerald H Jordan

Staged Reconstruction of the Fossa Navicularis 95
Anterior Panurethral Staged Buccal Mucosa Graft Reconstruction 103
Complications 107
Editorial Comments 109

11. Perineal Urethrostomy **111**
Jeremy B Myers, William O Brant

Background 112
Indications and Contraindications 113
Surgery 113
Outcomes 117

Surgical Pearls 117
Editorial Comments 117

12. Female Urethroplasty **119**
Allen McNeil Haraway, Anne Pelletier-Cameron

Female Urethral Anatomy 119
Urethral Dilation and Urethrotomy 120
Female Urethroplasty Techniques 120
Postoperative Care 124
Complications 125
Editorial Comments 125

13. Stricture after Transurethral Resection of the Prostate, Radical Retropubic Prostatectomy and Radiation Therapy **126**
Daniel D Dugi III, Allen F Morey

Stricture after Radiation Therapy for Prostate Cancer 126
Urethroplasty for Radiation-induced Strictures of the Bulbomembranous Urethra 127
Stricture after Treatment for Benign Prostatic Disease 130
Open Surgery for Bladder Neck Contracture: Anterior Bladder Flap 131
Stricture after Radical Prostatectomy 133
Vesicourethroplasty after Radical Prostatectomy 134

14. Tissue Engineering in the Management of Urethral Strictures **137**
Ryan P Terlecki, Anthony Atala

Biomaterials and Wound Healing 137
Choosing a Biomaterial 138
Classes of Biomaterials 138
Synthetic Biomaterials in Urethral Reconstruction 139
Natural Biomaterials in Urethral Reconstruction 139
Future Directions 141

15. From the Patients' Perspective **146**
Rajesh Gulia

Patient 146
Doctor 146
What and How to Counsel 147

Index *149*

3

CHAPTER

Imaging in Stricture Urethra



Pankaj M Joshi

Sanjay B Kulkarni, Pankaj M Joshi

Chapter Outline

- X-ray Kidney, Ureter, Bladder
- Retrograde Urethrogram
  - Technique
  - Position
  - Materials
  - Films
- Micturating Cystourethrogram
- Up and Downogram
  - Steps
  - Features to be Seen in a Urethrogram
- Pericatheter Urethrogram
- Normal Anatomy of the Urethra on Urethrogram
  - Complications of Urethrogram
  - Pitfalls in Urethrogram
- Ultrasonography
  - Abdominal Ultrasound
  - Color Doppler of the Penis
  - Urethrosonography
- Magnetic Resonance Imaging
- Editorial Comments
  - Decoding Erectile Dysfunction in PFUDD

Abstract

Imaging in stricture urethra is of utmost importance. Retrograde urethrogram is the basic and most important investigation. It is essential that a urologist does the retrograde urethrogram under fluoroscopy, rather than leave it to radiologists, judgment. It should be done in aseptic precautions. Sonourethrography is helpful in assessing stones, diverticulum, severity of spongiofibrosis and length of stricture. A well done combined antegrade and retrograde urethrogram in pelvic fracture urethral disruption defect (PFUDD) gives a fair idea about the length of gap. MRI should be performed in complex and redo PFUDD related posterior urethral strictures. Penile Doppler in PFUDD is essential for understanding vasculogenic impotence. It should be performed in all patients with PFUDD.

Keywords

Retrograde urethrogram (RGU), Antegrade urethrogram, Micturating cystourethrogram (MCU), Up and downogram, Pericatheter urethrogram, Color Doppler of penis, Urethrosonography, Spongiofibrosis, MR urethrography, Neurogenic impotence.

INTRODUCTION

Stricture of the urethra causes obstruction to the flow of urine. Stricture is a local disease of the urethra but can become systemic in cases where it leads to urinary retention and back pressure changes. Imaging in stricture depends upon the site and suspected causes of stricture. In this review, we will take you through the various modalities of radiological importance which help us in diagnosis and management of stricture. We would start from simple to more complex investigations.

X-RAY KIDNEY, URETER, BLADDER

A patient of stricture disease, which is long standing may have development of urinary calculi. They may be present in the bladder or the kidneys. While the bladder calculi are due to obstruction, stricture can cause recurrent urinary tract infections and possibility of kidney stone formation.

RETROGRADE URETHROGRAM

This is the basic and most important investigation in evaluation of the stricture disease. It simply means

JAYPEE BROTHERS

opacification of the urethra by means of a radiocontrast agent with subsequent photography. Urethrogram can be classified into various categories:

- Elective versus emergency
- Antegrade versus retrograde
- Combined up and downogram.

While elective urethrogram is carried in cases of suspected stricture, emergency urethrograms are done in the casualty trauma departments in cases of suspected urethral injuries after pelvic trauma or perineal trauma.

Technique

Urethrogram is an invasive procedure which needs to be done by taking utmost care and precautions. It is essential to have the patient well informed about the procedure and the complications. Usually urethrogram is best avoided in presence of infections as it may cause intravasation of bacteria and bacteremia. However, routine examination of urine is not required, and good clinical judgment is fair enough for the procedure.

It is always recommended that the urethrogram should be performed by the treating urologist or a urology trainee rather than leaving it upon the radiologist's judgment. Performing retrograde urethrogram (RGU) under fluoroscopy guidance gives accurate information about the distensibility of urethra which may not be seen in static images.

Utmost care must be taken to use all aseptic technique while performing the urethrogram. The patient should be placed supine and the genitals should be painted with antiseptic solution, povidone-iodine being authors' choice.

Position

Urethra is a tubular structure which lies in the midline. However, it has its natural curvature along the bulbar region with two dilated parts, the bulb and the fossa navicularis. Obtaining the urethrogram in supine position will cause overlapping of the bulbar and penile urethra and will not give the correct diagnosis. In order to straighten the urethra, two steps are crucial:

1. *Positioning the patient in oblique position at approximately 20°*: The question is right oblique or left oblique. In the radiology suites where the fluoroscopy machine is organized, usually the screening arm is placed on left of the patient or on the opposite side of table. It is clumsy to stand on the side of machine and do the urethrogram. Right-handed surgeons would always prefer the right oblique position, while left-handed surgeons may prefer to use the left oblique position.
2. *Straighten the penis*: In order to get a good representation of the urethra, the penis needs to be straightened. This can be done by using hand; however, it may cause the hand shadow on the urethrogram and there is a risk of radiation exposure. Hence various techniques can be used as using a gauze piece around the glans and stretching the penis, using Foley's catheter with balloon inflated with 2 cc of saline placed in navicularis fossa with a pull applied to the Foley's or by using the Brodney's clamp.

Materials

We can use a simple Foley's catheter adaptor to cannulate the meatus, some authors recommend Foley's catheter to be inflated in the fossa navicularis. Problem comes in patients of severe lichen sclerosus where there is meatal stenosis and difficulty in cannulating the meatus. Here we can use the inner sheath of intravenous catheter routinely used for gaining access to a vein or a small 6 French infant feeding tube which is cut at approximately 2.5 cm distance from the hub.

Contrast: Diluted diatrizoate meglumine is widely used. It has been proved beyond doubts that nonionic contrast had less complication when given intravenously as compared to the ionic contrasts. Same may be applied in case of urethrograms.

Films

Scout film: Before doing a urethrogram, it is essential to take a plain X-ray of the desired region to rule out presence of calculi and calcifications as they may cause confusion in interpreting the urethrogram.

Patient is placed in oblique position and contrast is injected into the urethra with continuous fluoroscopic monitoring. Excessive pressure is avoided while injecting, so as to prevent intravasation and extravasation. The stricture is visualized, the site identified and the contrast would be seen passing beyond the stricture into the proximal urethra and bladder. If the patient has a suprapubic catheter, then antegrade urethrogram could be done so as to get a clear picture of full length of the stricture. In a classical case of panurethral stricture due to lichen sclerosis, a well done RGU will show irregular urethral mucosa with contrast entering the glands of Littre **(Figs 3.1A and B)**.

MICTURATING CYSTOURETHROGRAM

Having diagnosed a stricture in the urethra, efforts should not be made to insert a feeding tube in the bladder to get a micturating film as it may cause false passage and damage

JAYPEE BROTHERS

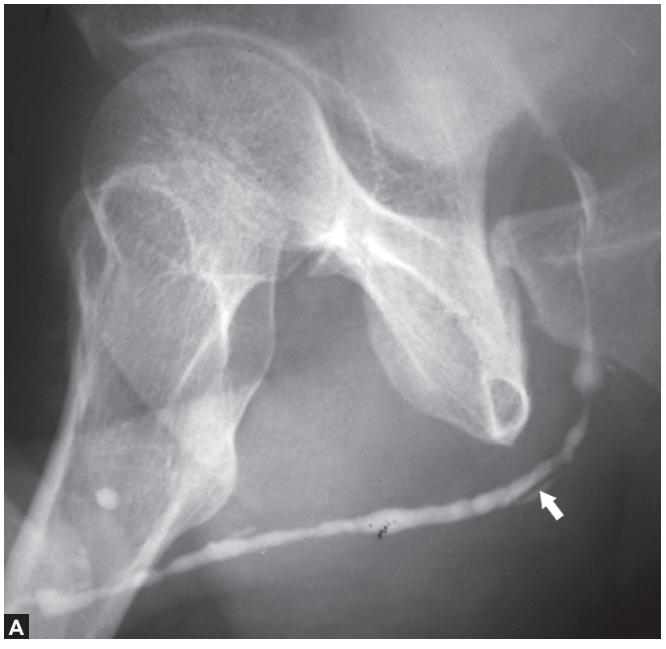

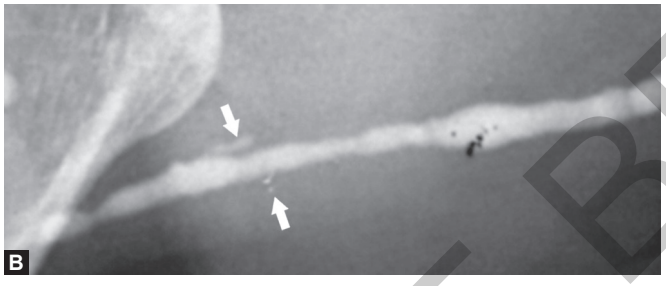

Figs 3.1A and B: Panurethral stricture involving whole of the anterior urethra, usually seen in lichen sclerosus. Note the irregular urethral mucosa and contrast entering the glands of Littre all along the urethra (arrow heads)

to the urethra. In case the patient has a suprapubic catheter or if the bladder can be filled easily from below just by injecting contrast, micturating film can be obtained **(Fig. 3.2)**. It helps in highlighting proximal extent of the stricture, nature of bladder as to presence of reflux or diverticulum. It helps if the patient is given an alpha-blocker 30 minutes prior, as it helps the bladder neck to open. Also sometimes a suprapubic puncture is resorted to, to fill the bladder in case of failure of access from below and in the absence of a suprapubic catheter.

UP AND DOWNOGRAM

In cases of pelvic fracture with urethral distraction defects (PFUDDs), patients who are referred ones usually have a suprapubic catheter. A plain X-ray reveals healing fracture of the pelvis.

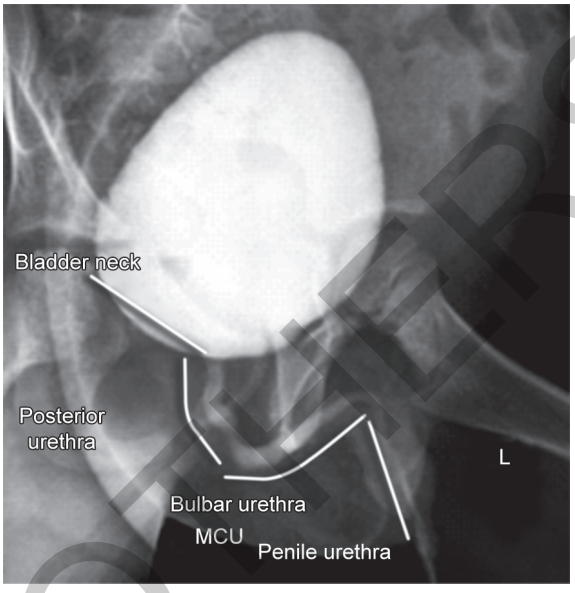

Fig. 3.2: Micturating cystourethrogram (MCU) showing the parts of urethra and bladder neck

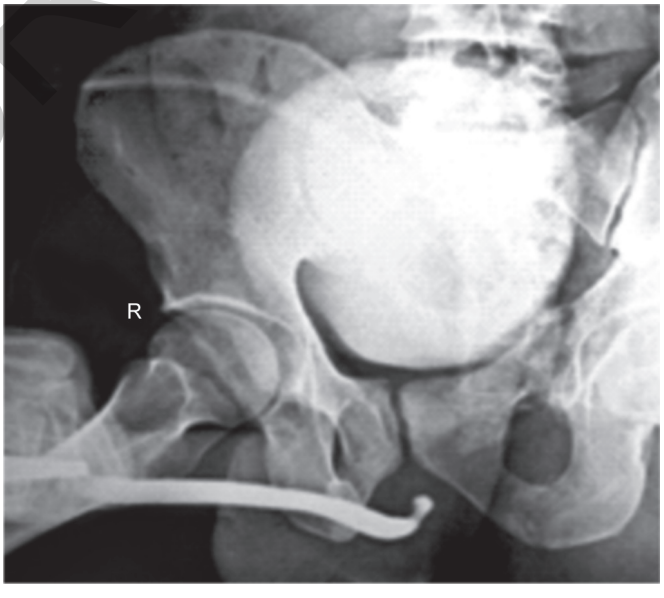

Fig. 3.3: Ascending and descending urethrogram in pelvic fracture urethral distraction defect

Steps

Urethrogram in such scenario is often labeled as up and downogram **(Fig. 3.3)**. Patient is placed in supine position. Parts are painted with povidone-iodine. It is important to fill the bladder slowly. Hence, 500 ml of sterilized normal saline connected to an intravenous infusion set

JAYPEE BROTHERS

is connected to the suprapubic catheter with contrast added to the normal saline. It is allowed to flow slowly and bladder examined periodically under fluoroscopy.

Once the bladder is full, bladder neck is assessed. Contrast is seen flowing in the posterior urethra. Patient is then given an oblique position and contrast injected through the urethra. Fluoroscopic image then shows gap between the proximal and distal ends of urethra.

Issue arises when bladder neck does not open. In such cases we could resort to the use of alpha blockers and repeat the urethrogram or rather as a routine give an alpha blocker before a micturating cystourethrogram (MCU).

Features to be Seen in a Urethrogram

- To assess the continuity of urethra
- The length of gap between the proximal and distal ends
- State of bladder, presence of diverticulum, stones, bladder capacity
- Bladder neck—open or closed.

PERICATHETER URETHROGRAM

This is a procedure which is done in follow-up period of patients who undergo complex urethral reconstruction or after redo surgeries. All aseptic precautions are taken. There are two ways of doing this procedure:

1. Use an infant feeding tube or cannula of an intravenous access sheath and inject contrast around the catheter from the meatus.
2. If the patient has suprapubic catheter, then we could fill the bladder with contrast and ask the patient to void. The contrast usually highlights the urethra around per urethral catheter.

The purpose of this procedure is to look for any leaks from the urethra.

NORMAL ANATOMY OF THE URETHRA ON URETHROGRAM

Urethra in an adult male is approximately 17–20 cm in length. Urethra is divided into two parts: anterior urethra and posterior urethra **(Fig. 3.4)**.

Anterior urethra is divided into.

- *Penile urethra*: It extends from fossa navicularis to penoscrotal junction **(Fig. 3.5)**
- *Bulbar urethra*: It is from penoscrotal junction to membranous urethra **(Fig. 3.6)**

Posterior urethra is divided into:

- *Membranous urethra*: It is approximately 1 cm in length, sphincteric area.
- *Prostatic urethra*: It is part of the urethra within the prostate.

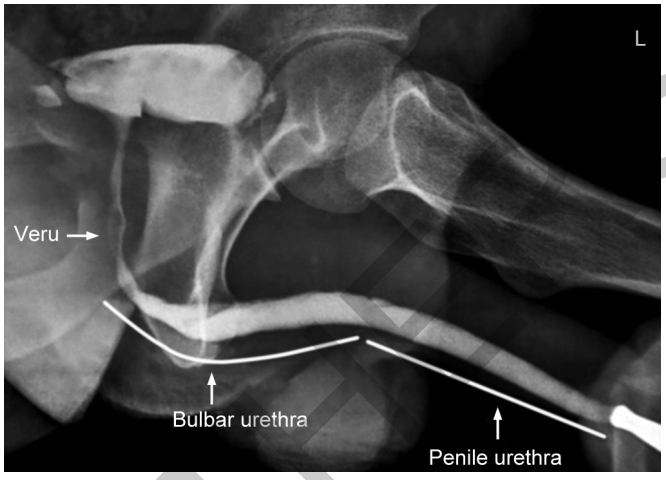

Fig. 3.4: A normal retrograde urethrogram showing parts of urethra and verumontanum. Starting at this landmark extending distally for about 1–1.5 cm, shows position of the external urethral sphincter, the membranous urethra

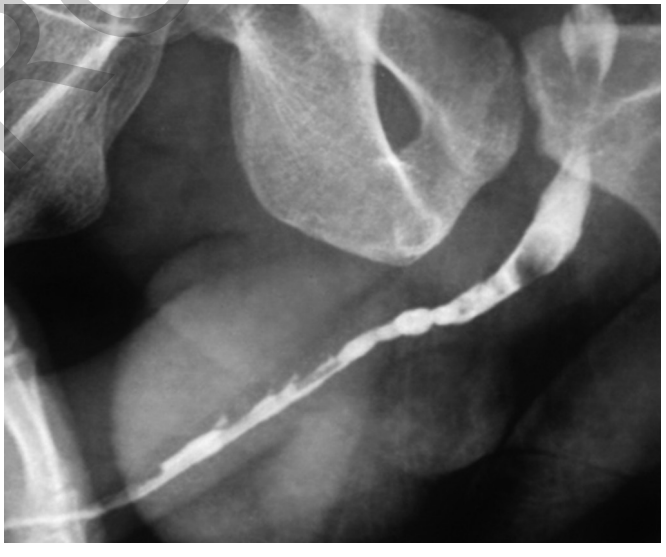

Fig. 3.5: Stricture involving the penile and distal bulbar urethra

Complications of Urethrogram

- Excessive use of force may cause urethral bleeding
- Extravasation
- Venous intravasation
- Vasovagal reaction due to pain.

Pitfalls in Urethrogram

- In case of lichen sclerosus where there is a stricture from fossa navicularis itself, by using an infant feeding tube, the initial stricture may be missed.

JAYPEE BROTHERS



Fig. 3.6: Proximal bulbar urethral stricture

- Extravasation may blur the image and may make interpretation difficult.
- Failure to take a plain X-ray prior may make subsequent interpretation difficult in case of calcification or calculi.
- Failure to straighten the penis may cause overlapping of the curvature and false interpretation.

ULTRASONOGRAPHY

There are three ways in which ultrasound is useful in stricture disease:

1. Ultrasound of the kidney, ureter and bladder (KUB).
2. Color Doppler of penis.
3. Sonourethrography in anterior strictures.

Abdominal Ultrasound

Sonography of the abdomen and pelvis is necessary to check the back pressure changes in the upper tracts like bilateral hydroureteronephrosis.

Significant postvoid residual urine volume indicates significant obstruction and/or decompensated detrusor. Bladder wall thickness is also an important measurement.

Color Doppler of the Penis

Color Doppler of penis is performed in all patients of pelvic fracture urethral injury. Color Doppler is done to measure flow and velocities in cavernosal arteries pre- and postpapaverine injections. Patients with pelvic fracture may have arteriogenic insufficiency leading to impotence. Patients with bilateral affection need revascularization procedure prior to urethroplasty. Otherwise, they may land with bulbar urethral necrosis following mobilization and proximal transection of the bulbar urethra as this part gets its blood supply in a retrograde fashion through corpora cavernosa into glans and penile urethra. As this retrograde blood supply is inadequate, the bulbar urethra undergoes necrosis or stenosis.

Normally the systolic velocity in the cavernosal artery should be 30–35 cm/sec. A difference of more than 10 cm/sec indicates presence of arterial stenosis.

Penile Doppler in cases of pelvic fracture injury also has medicolegal implications. Impotence in cases of pelvic fracture is due to the initial injury itself. Hence, documenting the arteriogenic impotence is necessary preoperatively. It also helps in patient counseling.

Thus, penile Doppler is useful to identify patients at risk of bulbar urethral necrosis and impotence. It is an essential tool in patient counseling. Thus, a patient of arteriogenic impotence is informed that he will have to first undergo urethral reconstruction, and may subsequently require penile prosthesis after successful urethral surgery. He needs to be informed that as per literature, impotence is related to the initial injury and not as a result of surgery.

Urethrosonography

The use of ultrasonography to evaluate anterior urethral strictures was first reported by McAninch et al. in 1988. He suggested that sonourethrography was consistently more accurate in estimating stricture length than urethrography **(Figs 3.7A and B)**. It is a dynamic three-dimensional study and can be repeated without risk of radiation exposure. Sonourethrography is preferable to radiographic RGU to evaluate patients with suspected anterior urethral strictures. Initially using a 5 MHz linear-array transducer applied over dorsum of the penis, the contemporary technique involves use of a 7.5 MHz linear-array transducer applied directly to ventrum of the penis, scrotum and perineum. Initial studies suggested injecting saline in urethra. Recent literature suggests use of lignocaine jelly in the urethra.

Morey AF and McAninch JW et al.[1,2] in their prospective study in 1997 and review article in 2000 concluded that sonographic staging of anterior urethral strictures offers clinically important information that may be useful in guiding reconstructive therapy, and also suggested excisional therapy for strictures appearing sonographically to be 25 mm or less, and substitution urethroplasty for longer strictures.

Advantages of Sonourethrography

- Accurate length of stricture
- Length of spongiofibrosis

JAYPEE BROTHERS

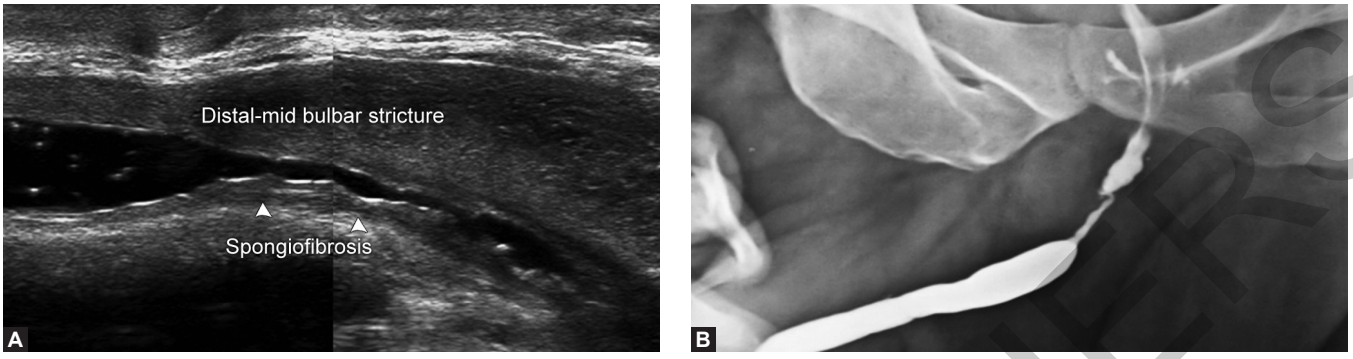

Figs 3.7A and B: Bulbar urethral stricture—sonourethrogram and retrograde urethrogram (RGU). Point to note is the spongiofibrosis extends well beyond the measured length of stricture on RGU

- Depth of spongiofibrosis
- Associated abnormalities like diverticulum, stones
- No radiation exposure.

Disadvantages of Sonourethrography

- Operator dependent
- As of now it had limited role in evaluation of posterior strictures.

MAGNETIC RESONANCE IMAGING

Magnetic resonance imaging (MRI) can be used in two ways as far as stricture disease is concerned. There are papers regarding magnetic resonance urethrography. The current use of MRI is in cases of posterior strictures after pelvic trauma and complex redo surgeries of PFUDDs **(Fig. 3.8)**. Preoperative MRI can provide useful information that might help to determine the appropriate surgical repair. It has the following advantages:[3]

- It correctly estimates length of the urethral defect
- Type and degree of prostatic displacement
- Precisely delineates the site and density of scar tissue
- Reveals the presence of paraurethral false tracks
- MRI can identify cause of post-traumatic impotence such as avulsion of the corpus.

To authors' understanding of stricture disease, routinely MRI is required in few selected cases. A good reconstructive urethral surgeon has all the tools in his armamentarium by which he can perform from simple to advanced procedures such as transpubic urethroplasty. This is a part of progressive perineal approach. Truly authors use MRI only in complex redo cases or in patients who are operated outside their set-up and they suspect that the posterior urethra was directly anastomosed to bladder bypassing the prostatic urethra.

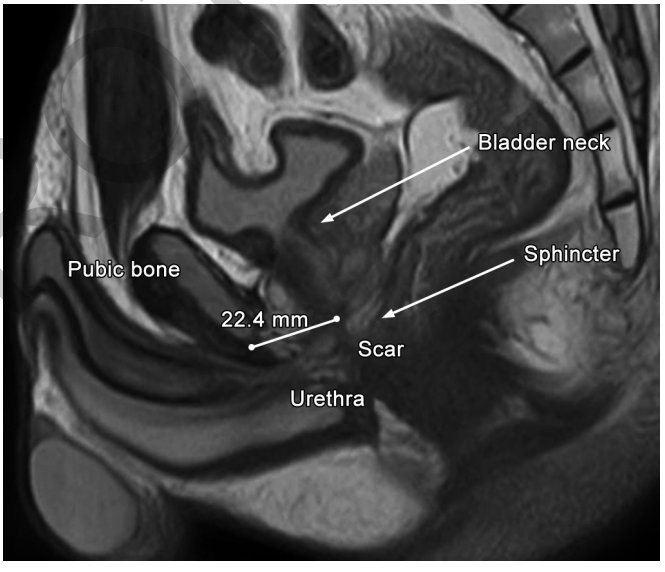

Fig. 3.8: An MRI done in a complex redo case

CONCLUSION

So to conclude, imaging forms an important part in evaluation and decision making in stricture urethra. Ascending urethrogram remains an indispensable, simple, affordable and reproducible investigation that forms the cornerstone of stricture disease evaluation.

EDITORIAL COMMENTS

Dr Rajesh Gulia

Decoding Erectile Dysfunction in PFUDD

As a urethral reconstructive surgeon, one should have the basic knowledge of how to interpret a well done penile

JAYPEE BROTHERS

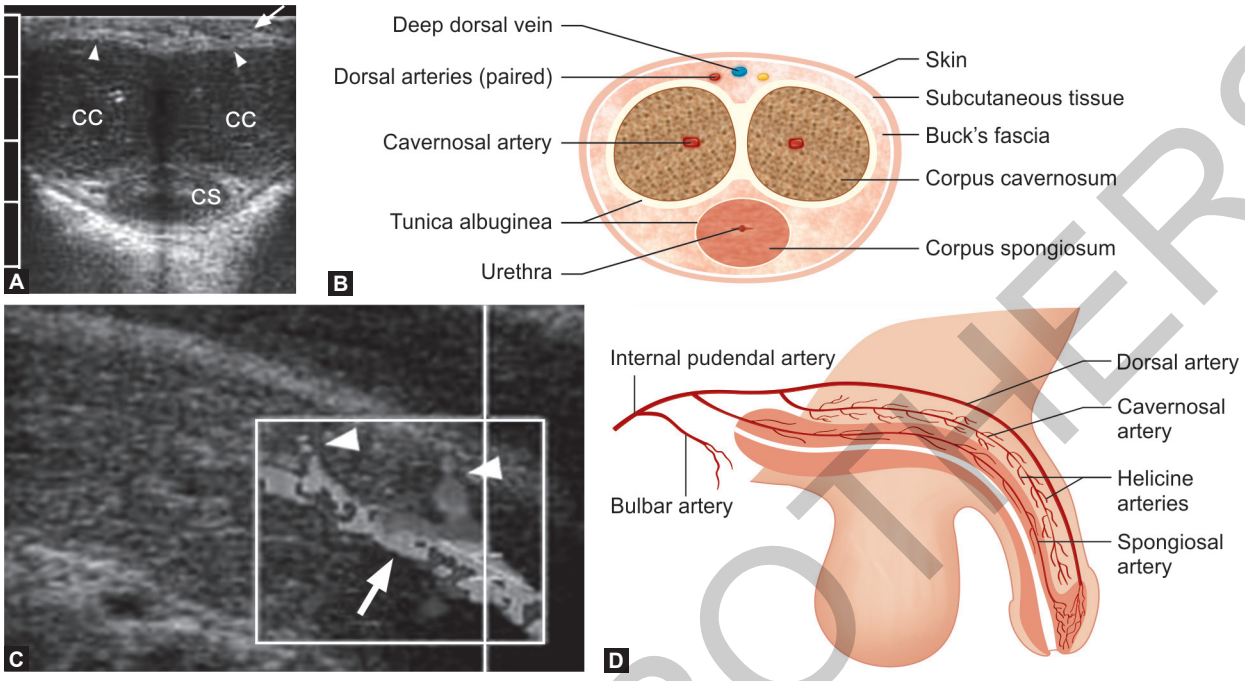

Figs 3.9A to D: Normal sonogram of penis. (A) Transverse gray-scale ultrasound of the penis demonstrates the two corpora cavernosa (CC) surrounded by the tunica albuginea (arrowhead). The corpus spongiosum (CS) is seen inferior to the corpora cavernosa. All three corpora are surrounded by the Buck's fascia (arrow); (B) The corresponding line diagram; (C) Longitudinal color flow Doppler ultrasound of normal cavernosal bodies and flow through cavernosal artery (arrow) and the helicine branches (arrowheads); (D) The corresponding line diagram of blood supply to the penis

Doppler study and to extract the required information. One cannot underestimate its importance in prognosticating the outcomes in PFUDD cases, especially so in patients with decreased erections, (or a cold or insensate glans), failed prior urethroplasty and the elderly.

Normal Sonogram of the Penis

Below is shown how a *normal sonogram of the penis* looks like **(Figs 3.9A to D)**.

Doppler Findings in Various Phases of Erection

Also important is to understand the *Doppler findings in various phases of erection,* as illustrated in **Figures 3.10A to D**.

Certain Points in Interpretation of Penile Doppler

Peak flow rates less than 25 cm/sec are abnormally low, and peak flow rates greater than 35 cm/sec are normal, but the range of 25–35 cm/sec is equivocal. The parameters that indicate the presence of arterial disease are:

- A subnormal clinical response to vasoactive agents
- A less than 60% increase in diameter of the cavernosal artery
- A peak systolic velocity of the cavernosal arteries less than 25 cm/sec
- Recently, Speel et al.[4] reported that acceleration time was the most valid parameter to detect cavernous atherosclerotic pathology. Blood flow velocity in the cavernous artery following pharmacostimulation was determined with duplex ultrasonography in 106 patients with erectile dysfunction (ED). The cutoff point for acceleration time to discriminate between atherosclerotic and nonatherosclerotic ED was determined at acceleration time 100 milliseconds or greater. Sensitivity was 66% and specificity was 71%.

In the presence of normal arterial function, Doppler findings suggestive of an abnormal venous leak are:

- Persistent end diastolic velocity of the cavernosal artery greater than 5 cm/sec
- Demonstration of flow in the deep dorsal vein
- The development of diastolic flow reversal after an injection has been found to be a reliable indicator of venous competence.

Although the accurate diagnostic procedure for venous leak diagnosis is infusion cavernosometry after maximal vasodilatation, this is rarely employed owing to poor surgical results of venous leak repair.

JAYPEE BROTHERS

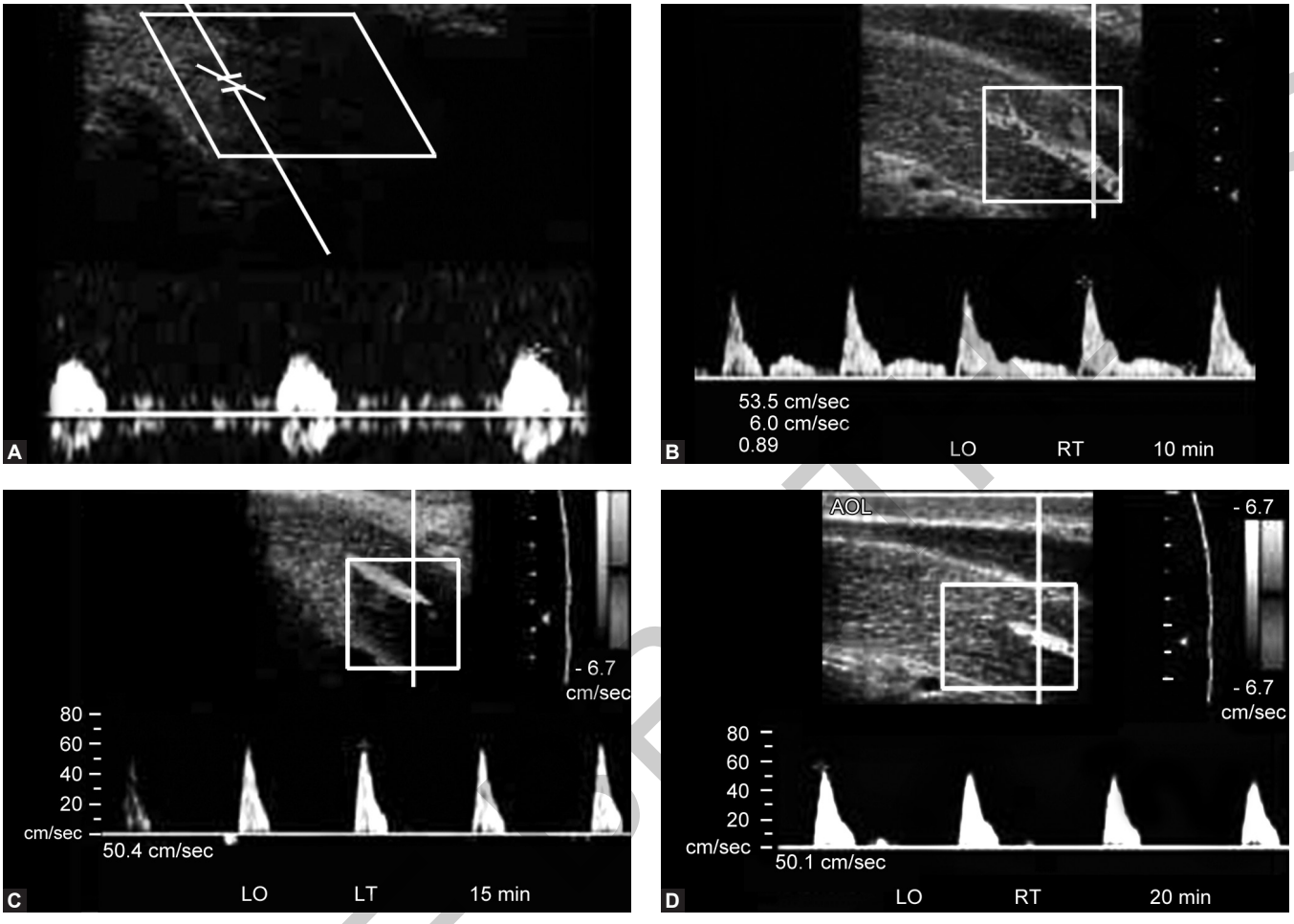

Figs 3.10A to D: Phases of erection. (A) Flaccid phase—spectral Doppler waveform demonstrates high resistance waveform. Velocities are in the range of 5–15 cm/sec; (B) Filling phase—spectral Doppler waveform demonstrates increased systolic velocity and increased diastolic flow; (C) Tumescent phase—the systolic velocities stabilize, diastolic flow decreases or becomes reversed; (D) Rigid phase—spectral Doppler waveform demonstrates very high resistance waveform with no diastolic flow and minimal systolic flow. The peak systolic velocities decrease

Procedure of Penile Doppler (Steps)

High-frequency (7.5–14 MHz) linear-array transducers are used to obtain high-resolution images of the penis. The cavernosal artery is visualized on the medial portion of the corpora cavernosa. Owing to the variation in peak systolic velocity (PSV) of the cavernosal artery at different locations across shaft of the penis (PSV is higher proximally), PSV should be consistently measured at junction of the proximal one-third and distal two-thirds of the penile shaft. Cavernosal artery velocities in healthy volunteers measure 10–15 cm/sec in the nonerect condition. Cavernous arteries should be identified and their action potential dimension is measured. When pharmacological testing is required, papaverine injection 30–60 µg (1–2 ml) is injected to one of the corpora cavernosa laterally in distal part of the penis with a 30-gauge needle. Injection should always be made in the distal two-thirds part of the penis on one side only because of the presence of a septum in between the two corpora cavernosa in proximal part of the penis, which is deficient distally, thus allowing bilateral perfusion of the injected vasoactive substance. Besides papaverine, other vasoactive agents used are prostaglandin E1, 10–20 mg and trimix (combination of papaverine, phentolamine and prostaglandin E1). Trimix is reserved for those patients who do not respond to prostaglandin.

Neurogenic Impotence

Having stressed the importance of vascular work-up in PFUDD, the majority of patients after the primary injury

JAYPEE BROTHERS

have neurogenic impotence (in some series up to 90%). These are the patients more likely to respond to sildenafil/self-injection therapy with vasoactive agents, than those with arterial damage. A favorable response to these may predict spontaneous resumption of normal erectile function over time. Though it is stressed that first surgery does not contribute to any potent person becoming impotent, in a redo urethroplasty, the chances of fresh ED are higher. Bilateral pubic rami fracture was also associated with a high incidence of impotence.

Disruption of the cavernosal nerves lateral to the prostatomembranous urethra behind the symphysis pubis is the most likely cause of impotence in this injury. The cavernosal nerves are a part of the autonomic nervous system and incorporate both sympathetic and parasympathetic fibers. They regulate blood flow during erection and detumescence. The dorsal somatic nerves are branches of the pudendal nerves. They are primarily responsible for penile sensation.

Acknowledgments

To all the patients with stricture urethra.
Yogesh Sovani for images of sonourethrography.

REFERENCES

1. Morey AF, McAninch JW. Role of preoperative sonourethrography in bulbar urethral reconstruction. J Urol. 1997;158(4):1376-9.
2. Morey AF, McAninch JW. Sonographic staging of anterior urethral strictures. Review article. J Urol. 2000; 163(4):1070-5.
3. Mamdouh M, Koraitim, Ihab SR. Role of magnetic resonance imaging in assessment of posterior urethral distraction defects. Urology. 2007;70(3):403-6.
4. Speel TG, van Langen H, Wijkstra H, et al. Penile duplex pharmacoultrasonography revisited: revalidation of the parameters of the cavernous arterial response. J Urol 2003;169(1):216-20.

JAYPEE BROTHERS

for detailed information on urology books, visit our website www.jaypeebrothers.com, for detailed information on urology books, visit our website www.jaypeebrothers

Atlas of URETHROPLASTY

Salient Features

- Describes the best urethroplasty techniques from across the globe
- The book is a comprehensive text
- Provides high-quality collection of step-by-step instructions relating to the main procedures in urethroplasty
- Each procedure is explained in detail and in a step-wise manner, well supported by figures
- Includes how urethral surgeons should counsel patients of urethral stricture disease
- This textbook is a 'must have' collection for any urologist who has even a little interest in urethral stricture disease.



Rajesh Gulia is the Director of Kidney Centre, Sector 34A, Chandigarh and Head, the Unit of Reconstructive Urology, Chandigarh, India. He has been in Clinical Practice for last 15 years. Apart from being an experienced Endourologist, his interest lies in Reconstructive Urology especially 'Stricture Urethra'. He is active in Urological training and surgical camps in various parts of India and centers in Africa, especially Rwanda and Addis Ababa. He is the creator of the only available patient-oriented interactive web portal on 'Stricture Urethra', *www.stricturecure.com*

He is the Founding Member of the Indian Continence Foundation, which was formally launched during the workshop organized jointly by Asia-Pacific Continence Advisory Board and Asian Society for Female Urology in November 2003, at Bengaluru, Karnataka, India. He is also the Specialty (Urology) Expert in the IMS—The Chandigarh Chapter of the Indian Menopause Society, since 2005 and on the Reviewer Board of 'Journal of Mid Life Health'. He is an Executive Council Member in the Chandigarh Surgical Society elected in 2010. He is also the Chairman of Academic Committee of 'Kidney Center' since 2008.

He has done his basic medical and surgical training from one of the best institutes in Asia—The All India Institute of Medical Sciences (AIIMS), New Delhi, India. After MS, he was awarded the 'Young Surgeons Travel Fellowship' by the Japan Surgical Society in April 1997, and also awarded Membership of the National Academy of Medical Sciences (MNAMS) in Urology in January 2001. He worked in Sri Sathya Sai Institute of Higher Medical Sciences at Puttaparthi, Andhra Pradesh, India, for 4 years where he also got his basic training in Urology under Late Professor HS Bhat. Apart from being an active member of various National Urological Societies. He is also an active Member of Société Internationale d' Urologie. He has presented a number of award winning papers at various national and international fora.



Richard Santucci is the Director of the Center for Urologic Reconstruction™ and Specialist-in-Chief, Department of Urology, the 9-hospital Detroit Medical Center, Detroit. He runs the Urology Residency Training Program Centered at the Michigan State University College of Osteopathic Medicine, Detroit, MI, USA, and is a full clinical professor.

Dr Santucci's clinical practice focuses on urologic reconstruction and trauma, including urethral stricture disease, ureteral injury, spinal cord injury and urinary fistula. He has a keen interest in surgical education, and has been active in lecturing and demonstrating surgeries at training centers in the United States, Europe, South America and Africa. He has published more than 100 scientific articles, and has served on the editorial boards of twelve journals. He is the co-editor of the *Emergencies in Urology, the Atlas of Urethroplasty*, and *Penile Reconstructive Surgery*. He is the founding Editor-in-Chief of the online open-access urology journal *Advances in Urology*, and co-creator of the world's first high definition surgical video website, www.iclinics.org

He is a graduate of the American Urological Association (AUA) Leadership Program Class of 2009, was a member of the AUA Urotrauma Guidelines Panel, the AUA Urotrauma Legislation Task Force, the WHO International Consultation on Urologic Diseases (ICUD-urethra), and is an advisor to the US Marines Dismounted Blast Injuries Task Force. He is currently the Co-Chairman of the AUA Urethroplasty Guidelines panel. He sat on the Board of Chairman of the Société Internationale d'Urologie (SIU) and the Executive Committee of the Michigan Urologic Association (MUS).

Available at all medical book stores
or buy directly from Jaypee Brothers through online shopping
at www.jaypeebrothers.com

JAYPEE BROTHERS
Medical Publishers (P) Ltd.
www.jaypeebrothers.com

Join us on facebook.com/jaypeebrothers

Shelving Recommendation
UROLOGY

ISBN 978-93-5090-651-4