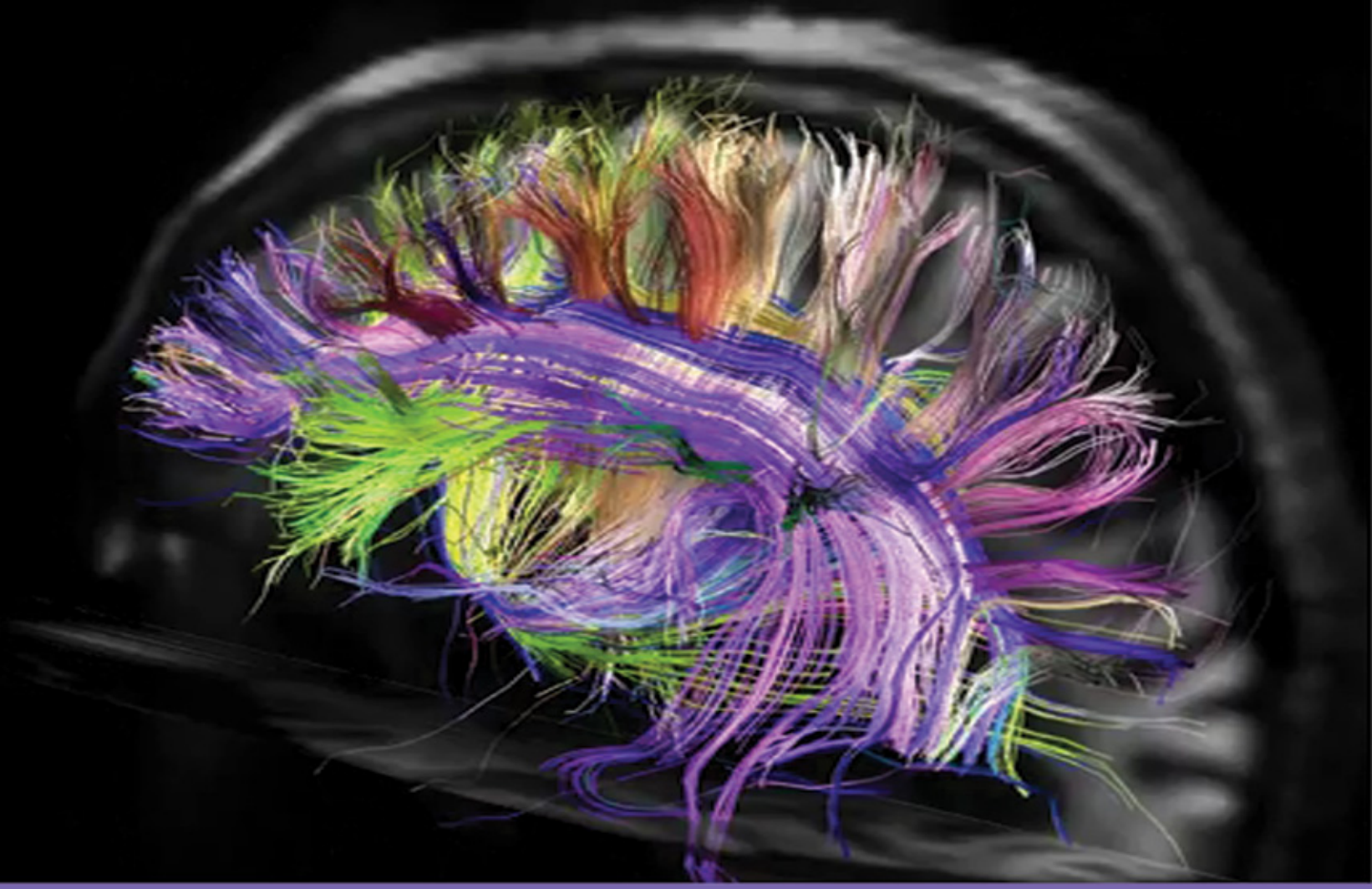

Easy & Interesting Approach to

HUMAN NEUROANATOMY

(Clinically Oriented)

Samar Deb

JAYPEE

CONTENTS

Chapter 1.
Introduction to Human Neuroanatomy **1**
- Principles of Functions of Nervous System 1

Chapter 2.
Nervous System in Brief **20**
- Central Nervous System 20
- Brainstem 26
- Cerebellum 28
- Peripheral Nervous System 35

Chapter 3.
Peripheral End Organs **44**
- Receptors 44
- Receptors – Other Ways of Classification 51
- Motor End Organs (Effectors) 51
- Motor Unit 53
- Nerve Ending Related to Exocrine Gland Acini 56

Chapter 4.
Spinal Cord **57**
- Definition and Situation 57
- Role of Spinal Cord as a Part of Central Nervous System 57
- Extent 57
- Important Notes in Connection with Termination 57
- Parameters of Spinal Cord 57
- Regional Classification of Spinal Cord Segments 58
- Exit of Spinal Nerves from Vertebral Foramen 59
- Correlation of Spinal Cord Segments with Vertebral Level 60
- Enlargement 60
- Surface Features 60
- Coverings (Meninges) and Spaces Around the Spinal Cord 61
- Internal Structure of Spinal Cord 63
- Formation of Different Zones of Spinal Cord 64
- Formation of Different Functional Cell Groups 65
- Peripheral Outflow of Spinal Cord 66
- Internal Structure of Spinal Cord 66
- Internal Structure of Spinal Gray Matter 69
- Various Cell Groups of Spinal Gray Matter 69
- Cell Groups in Posterior Gray Column 69
- Cell Groups in Intermediate Area of Spinal Gray Matter 70
- Cell Groups in Anterior Gray Column 70
- Cell Groups Around Central Canal 71
- Rexed's Lamination of Spinal Gray Matter 71
- Internal Structure of Spinal White Matter 72
- Rubrospinal Tract 80
- Tectospinal Tract 81
- Vestibulospinal Tracts 82
- Reticulospinal Tract 83
- Olivospinal Tract 83
- Hypothalamospinal Tract 83
- Solitariospinal Tract 83

Chapter 5.
Brainstem **94**
- Medulla Oblongata 124
- Pons 125
- Midbrain 126
- Traumatic Lesion 126

Chapter 6.
Cerebellum **128**
- Introduction 128
- Position and Relations 128
- Principle of Functions 129
- Gross Anatomy 129
- Primary Fissure and Lobes of Cerebellum 130
- Phylogenetic Classification of Cerebellum 131
- Internal Structure of Cerebellum 132
- Structural detail of Cerebellar Cortex 134
- Mechanism of Cerebellar Cortical Circuit 134
- White Matter of Cerebellum 135
- Nuclei of Cerebellum 135
- Relationship Between Cerebellar Nuclei and Mediolateral Subdivisions of Cerebellar Cortex 136
- Cerebellar Peduncles 136
- Impaired Function of Paleocerebellum 138
- Impaired Function of Neocerebellum 138

Chapter 7.
Fourth Ventricle of Brain **139**

Chapter 8.
Cerebrum—Cortical Gray Matter **144**
- Introduction 144
- Cerebral Hemispheres 145
- Medial Surface 153
- Tentorial Surface 155
- Orbital Surface 155
- Some Important Points about Cerebral Cortex 155
- Types of Neurons in Cerebral Cortex 155
- Layer of Cerebral Cortex 156
- Functional Areas of Cerebral Cortex 157
- Functional Areas in Frontal Lobe 157
- Functional Areas in Parietal Lobe 160
- Functional Areas in Occipital Lobe 161
- Functional Areas in Temporal Lobe 162

Chapter 9.
Cerebrum— White Matter **163**
- Classification 163
- Internal Capsule 172

Chapter 10.
Basal Ganglia **176**
- Chorea 183
- Ballismus 183
- Athetosis 183
- Parkinson Disease 183

Chapter 11.
Lateral Ventricle of Brain **185**

Chapter 12.
Diencephalon **192**
- Thalamus 193
- Metathalamus 198
- Epithalamus 200
- Paraventricular Nuclei of Epithalamus 202
- Habenular Nucleus and Habenular Commissure (Consult Figures of Commissure in Chapter of White Matter of Brain) 202
- Subthalamus 203

Chapter 13.
Third Ventricle of Brain **211**
- Tela Choroidea and Choroid Plexus 214

Chapter 14.
Meninges of Brain and Cerebrospinal Fluid **215**
- Dura Mater 215
- Arachnoid Mater 221
- Pia Mater 223
- Cerebrospinal Fluid 224

Chapter 15.
Blood Supply of Brain and Spinal Cord **228**
- Blood Supply of Brain 228
- Variations of Circle of Willis 232
- Cortical Branches Supplying Different Surfaces of Cerebral Hemisphere 234
- Venous Drainage of Brain 236
- Blood Supply of Spinal Cord 237
- Venous Drainage of Spinal Cord 239
- Blood-brain Barrier 240

Chapter 16.
Reticular Formation **245**

Chapter 17.
Limbic System **253**

Chapter 18.
Autonomic Nervous System **260**
- A component – Parallel to Somatic Nervous System 260
- Autonomic Nervous System and Endocrine system – Jointly Maintain Internal Environment of body 260
- Composition of Autonomic Nervous System 260
- Subdivision of Autonomic Nervous System – Sympathetic and Parasympathetic 261
- Sympathetic Part of Autonomic Nervous System 264
- Parasympathetic Part of Autonomic Nervous System 274
- Injuries to Autonomic Nervous System 282
- Diseases Involving Autonomic Nervous System 283
- Combined Sympathetic and Parasympathetic Lesion Causing Urinary Bladder Dysfunction in Spinal Cord Injury 284
- Disrupted Motor Functions of Bladder 284
- Visceral Pain 285
- Stomach Pain 286
- Appendicular Pain 286
- Renal Pain 286
- Ureteric Pain 287

Chapter 19.
Cranial Nerves **288**

- Olfactory Nerve and Olfactory Pathway 288
- Optic Nerve and Visual Pathway 291
- Optic Nerve 293
- Optic Chiasma 293
- Optic Tract 293
- Lateral Geniculate Body (Third of Neurons) 294
- Macular Vision 294
- Clinical Examination of Retina 296
- Detachment of Retina 297
- Various Kinds of Loss of Visual Field 297
- Argyll Robertson Pupil 298
- Cranial Nerves — Arising From Brainstem 299
- Oculomotor Nerve 299
- Postganglionic Branches of Ciliary Ganglion 302
- Roots of Communication to Ciliary Ganglion 303
- Trochlear Nerve 304
- Trigeminal Nerve 305
- Ophthalmic Nerve 308
- Maxillary Nerve 311
- Sphenopalatine Ganglion 312
- Mandibular Nerve 313
- Lingual Nerve 315
- Inferior Alveolar Nerve 315
- Auriculotemporal Nerve 316
- Abducent Nerve 317
- Facial Nerve 319
- Vestibulocochlear Nerve 326
- Vestibular Pathways 326
- Cochlear Component of Vestibulocochlear Nerve 330
- Last Four Cranial Nerves 334
- Glossopharyngeal Nerve 334
- Vagus Nerve 337
- Accessory Nerve 343
- Hypoglossal Nerve 347

Index *349*

4 Spinal Cord

DEFINITION AND SITUATION

Spinal cord is the distal, narrow, cylindrical and elongated part of central nervous system which is situated in upper two-thirds of vertebral canal as a continuation of medulla oblongata of hindbrain (Fig. 4.1).

ROLE OF SPINAL CORD AS A PART OF CENTRAL NERVOUS SYSTEM

1. It provides innervation (nerve impulse) to the trunk and limbs through its peripheral outflow known as spinal nerves.
2. It receives sensory information from the receptors distributed peripherally in the trunk and limbs and transmits to the brain.
3. It contains cell groups at some levels (not throughout whole length of spinal cord) which form spinal autonomic centers (sympathetic and parasympathetic) to send impulses to the autonomic effector organs (smooth muscles and exocrine glands) and to receive sensory information from the visceral wall.
4. It forms local circuit (at its segmental level) known as reflex arc which regulates some bodily functions at unconscious level.

EXTENT

■ **Beginning**: Spinal cord begins as continuation of medulla oblongata beyond foramen magnum at the level of upper border of 1st cervical vertebra (atlas).

■ **Termination**: Spinal cord terminates as a conical end known as *conus medullaris* at the level of intervertebral disk between first and second lumbar vertebrae. A connective tissue filaments known as *Filum terminale* extends from conus medullaris downwards to be attached to the back of first piece of coccyx.

IMPORTANT NOTES IN CONNECTION WITH TERMINATION

Upto third month of intrauterine life, rate of growth of body wall so also the vertebral column is *coextensive* with that of spinal cord. Subsequently vertebral column with the trunk grows at a rapid rate than spinal cord, when appears the disparity in length of the two. *At birth* spinal cord is found to extend upto lower border of body of *third lumbar vertebra*.

In 40% cases of adult, spinal cord extends upto the level of lower border of second lumbar vertebra or the disk between second and third lumbar vertebra. On rare occasions, spinal cord terminates at the level of lower border of twelfth thoracic vertebra.

The knowledge of termination of spinal cord is important for the clinicians to avoid injury to the spinal cord during lumbar puncture to take out cerebrospinal fluid.

PARAMETERS OF SPINAL CORD

- *Length*: 45 cm
- *Weight*: 30 gm

JAYPEE BROTHERS

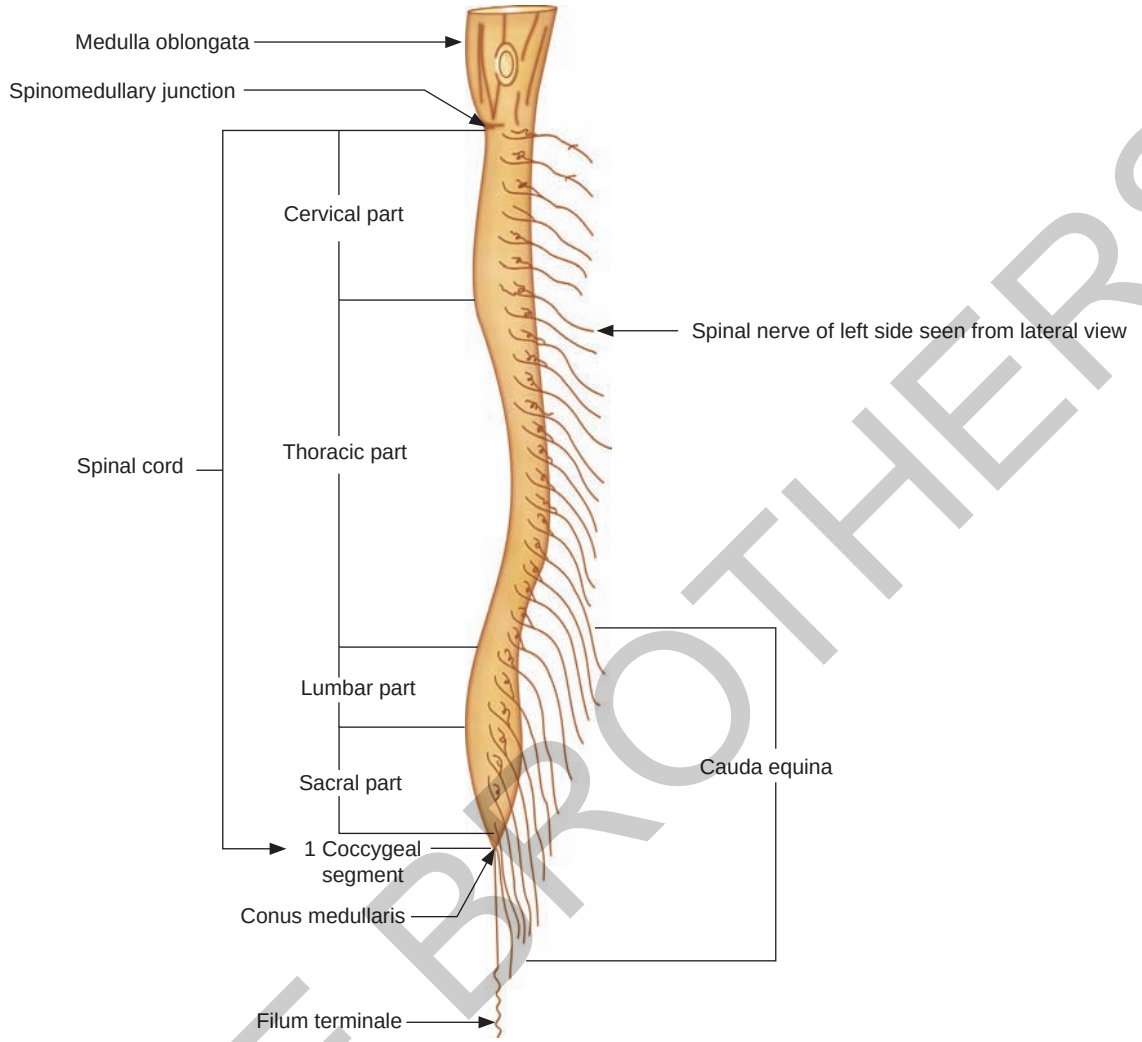

Fig. 4.1 Spinal cord (lateral view)—the distal, narrow, elongated and tubular part of central nervous system

- *Segments*: Spinal cord is made up of 31 numbers of units known as segments of spinal cord. Adjacent segments cannot be demarcated on the surface. Each of the segments gives rise to one pair of spinal nerves (right and left). Each of the spinal nerves shows surface attachment of one ventral (motor or efferent) and one dorsal (sensory or afferent) nerve root. The two roots unite within the vertebral canal to form a mixed spinal nerve which finally comes out through intervertebral foramen.

Therefore, an universal truth is learnt that ventral root of a spinal nerve is made up motor fibers and its dorsal root is composed of sensory fibers only. This is known as Bell-Magendie's law.

It is important to note at this stage that all the spinal nerve (31 pairs) are mixed in nature, composed of motor as well as sensory components. But a cranial nerve (out of total 12 pairs) may be mixed, purely motor or purely sensory.

REGIONAL CLASSIFICATION OF SPINAL CORD SEGMENTS (FIG. 4.1)

31 segments of spinal cord are regionally classified as follows:

Cervical – 8
Thoracic – 12
Lumbar – 5
Sacral – 5
Coccygeal – 1

It is to be noted here that number of cervical vertebrae are 7 and coccygeal pieces are 4. But the numbers of thoracic (12), lumbar (5) and sacral (5) cord segments correspond with the same number of respective regional vertebrae.

Each of the spinal cord segments gives rise to a pair of spinal nerve of corresponding name and number. Each spinal nerve, as already mentioned is formed by a ventral motor (efferent) and a dorsal sensory

JAYPEE BROTHERS

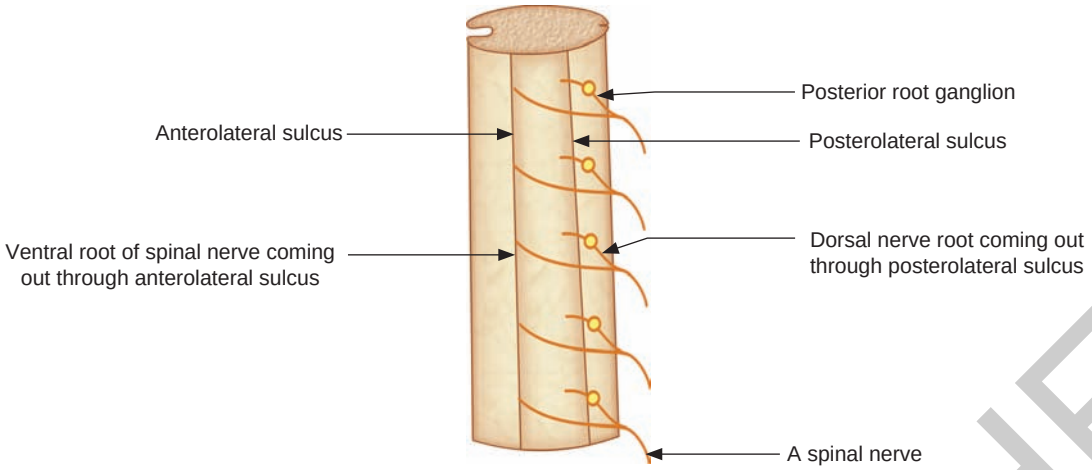

Fig. 4.2 Segments of spinal cord (left lateral view) showing ventral and dorsal roots of spinal nerves coming out through corresponding sulcus

(afferent) root. Attachment of ventral roots forms a fine and shallow anterolateral sulcus and similarly posterolateral sulcus is defined along the line of attachment of dorsal nerve roots. Dorsal nerve roots, close to the site of surface attachment present a small enlargement known as posterior root ganglion which contains the cell bodies of first order of sensory neurons located outside the central nervous systems (Fig. 4.2).

EXIT OF SPINAL NERVES FROM VERTEBRAL FORAMEN

All the spinal nerves come out of vertebral canal through the corresponding intervertebral foramina except fifth sacral nerve and coccygeal nerve which come out through sacral hiatus. To adjust the disparity of numbers of cervical spinal cord segments (8) and cervical vertebra (7), cervical spinal nerves (1st to 7th) come out above the pedicles of corresponding vertebra and 8th cervical nerve comes out below the pedicle of 7th cervical vertebra, through the intervertebral foramen between 7th cervical and 1st thoracic vertebra.

As the spinal cord is shorter in length than the vertebral column, lower spinal nerves (lumbar, sacral and coccygeal) are to descend through the vertebral canal in the form of a bunch to reach corresponding intervertebral foramen. These bunch of nerves are known as *cauda equina* as they look like a horse's tail (Fig. 4.3).

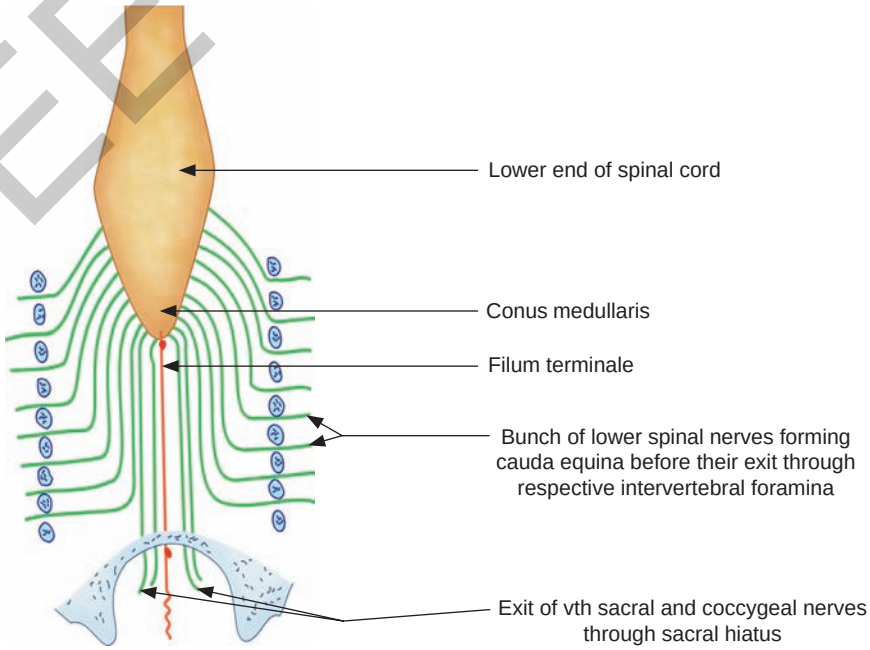

Fig. 4.3 Lower spinal nerves form cauda equina before they come out through corresponding intervertebral foramina at a lower level

JAYPEE BROTHERS

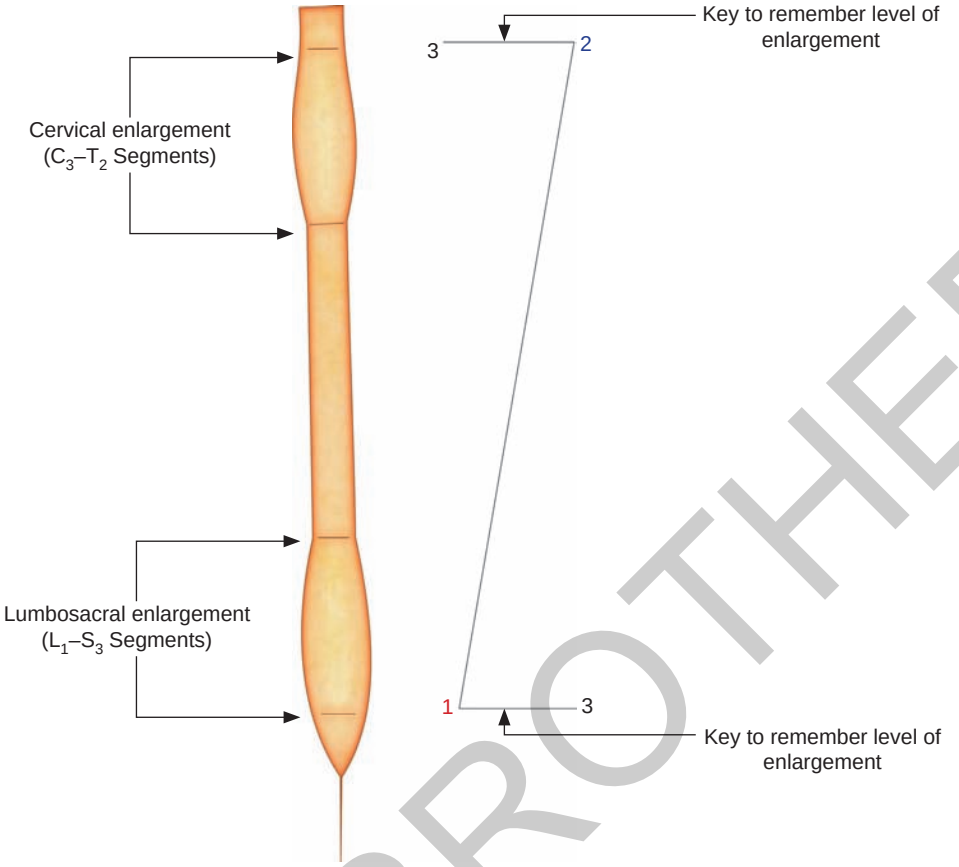

Fig. 4.4 Enlargements of spinal cord

CORRELATION OF SPINAL CORD SEGMENTS WITH VERTEBRAL LEVEL

More lower is the segment of spinal cord, its distance from corresponding intervertebral foramen so also the corresponding vertebra is more. Interrelations of their levels are as follows:

	Spinal cord segments	Vertebral level
Upper cervical	C_3	same level = C_3
Lower carnival	C_7	- 1 = C_6
Upper thoracic	T_5	- 2 = T_3
Lower thoracic	T_8	- 3 = T_5
Lumbar (upper)	L_3	- 4/5 = T_{11}
Lumbar (lower)	L_5	- 4/5 = T_{12}
Sacral /coccygeal	S_1	- 6/10 = T_{12}
	S_5	- 6/10 = L_1

Clinical Importance of Correlation of Levels

In case of spinal injury, fracture dislocation of vertebra may cause lesion of spinal cord segment of the same level. A clinician will be able to judge of level of spinal segment affected in spinal injury from the above mentioned guidelines. Level of fracture dislocation of vertebra is counted through identification of vertebral landmark.

ENLARGEMENT (FIG. 4.4)

The spinal cord is almost cylindrical althrough its length. However, it presents two expansions as enlargements. These are at the cervicothoracic (C_3 – T_2 segments) and lumbosacral (L_1–S_3 segments) levels (Fig. 4.4). These enlargements appear in fetal life with the formation of upper and lower limb buds, because of more amount of motor neurons in these segments to supply limb musculature and stretching of nerve fibers arising from the plexuses for upper and lower limbs.

SURFACE FEATURES (FIG. 4.5)

Linear depression along the anterior and posterior median line of spinal cord are known as anterior median fissure and posterior median sulcus respectively. Anterior (ventral) median fissure is 3mm deep, but posterior (dorsal) median sulcus is comparatively shallower. Besides, linear depressions along the lines of attachment of ventral (motor) and dorsal (sensory) nerve roots are respectively known as anterolateral and posterolateral sulcus. Spinal arteries and venous tributaries run along the sulci and fissure. Single unpaired anterior spinal artery

JAYPEE BROTHERS

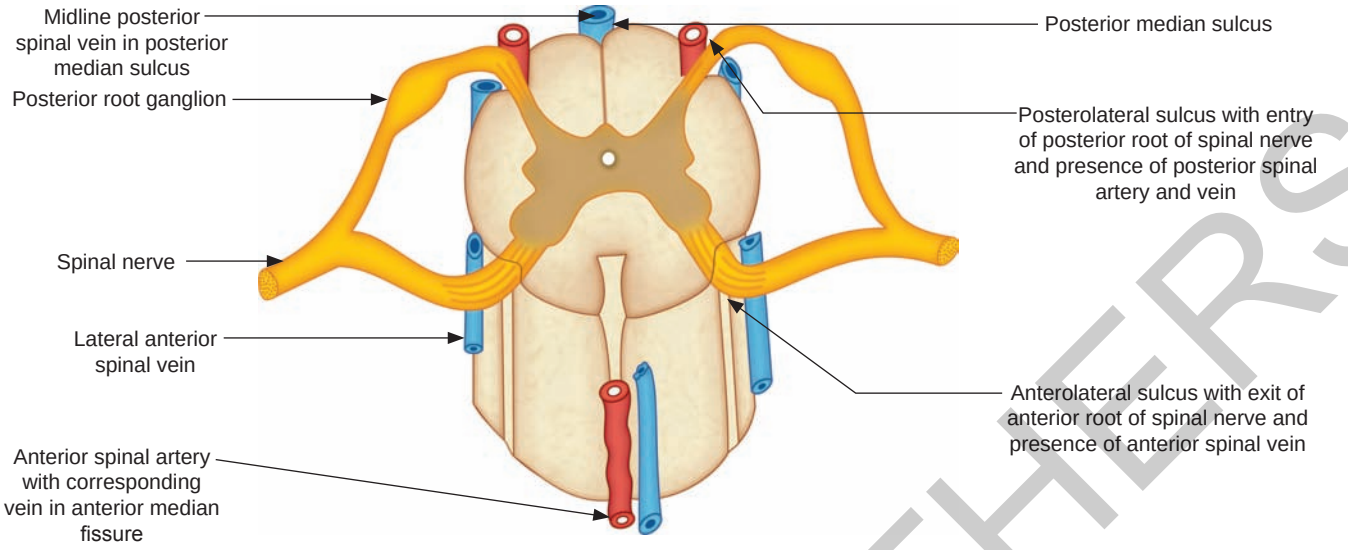

Fig. 4.5 Surface features of spinal cord

runs down along anterior median fissure, whereas paired bilateral posterior spinal arteries descend along posterolateral sulci. Each of the fissure and sulci are occupied by one of six (3 anterior and 3 posterior) spinal veins.

COVERINGS (MENINGES) AND SPACES AROUND THE SPINAL CORD (FIG. 4.6)

Coverings (meninges) of spinal cord are the following from outside inwards.

1. Dura mater
2. Arachnoid mater
3. Pia mater.

These superimposed coverings are either in close contact to each other (dura and arachnoid) or separated by a space (arachnoid and pia).

Dura Mater

This is tough and dense fibrous membrane made up of connective tissue which contains abundant collagen fibers. It encloses spinal cord as well as cauda equina. Proximally dura mater of spinal cord extends upto

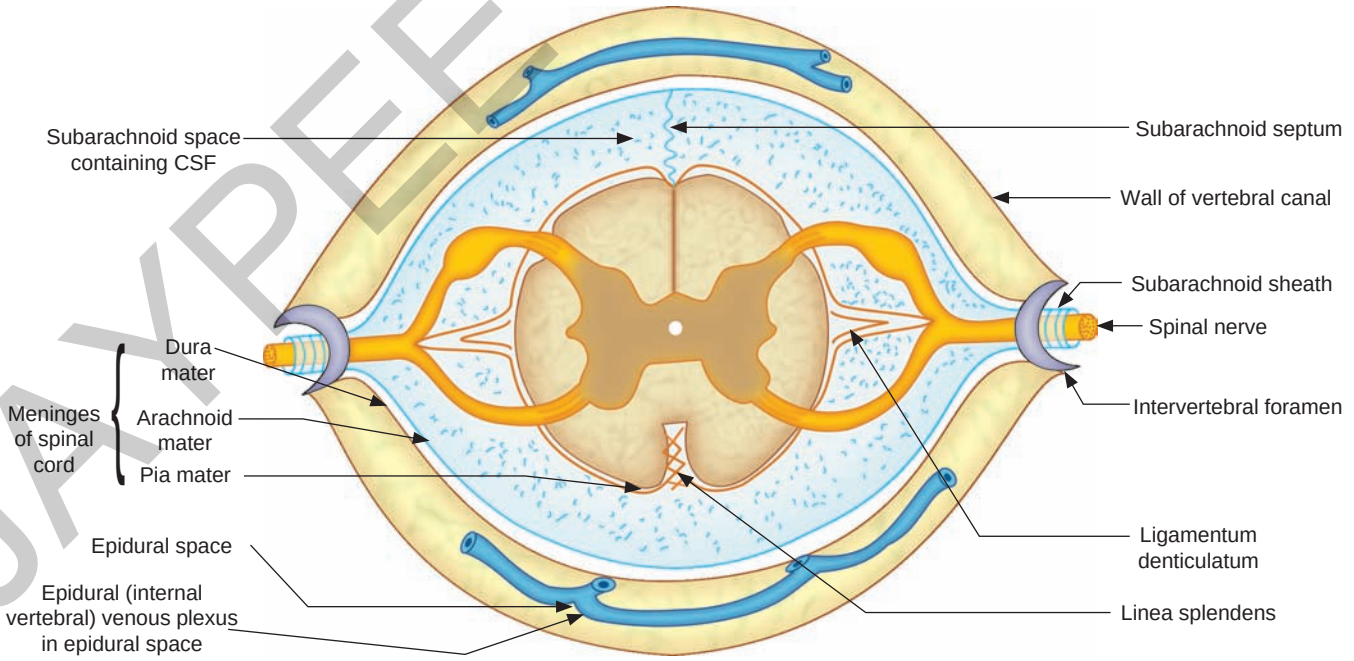

Fig. 4.6 Coverings (meninges) and spaces around spinal cord

JAYPEE BROTHERS

foramen magnum of cranium above which it is continuous with inner (meningeal) layer of dura mater of brain. Below, dura mater extends upto lower border of body of second sacral vertebra beyond lower end of spinal cord to enclose cauda equina and upper larger part of filum terminale. Beyond that level, dura mater is continued downward enwrapping external part of filum terminale to blend with periosteum of first piece of coccyx. At the level of each segment of spinal cord dura mater is prolonged outwards around the spinal nerve to be attached to the margin of intervertebral foramen. Inner surface of spinal dura is in close contact with arachnoid mater. But outer surface of dura is separated from vertebral canal by a space known as epidural space. This space contains loose areolar tissue containing fat in semiliquid state. The epidural space also contains plexus of veins known as epidural venous plexus or internal vertebral venous plexus.

Clinical Importance of Epidural (Internal-vertebral) Venous Plexus

This venous plexus extends throughout whole length of vertebral canal and it is proximally connected to the veins of skull. In the vertebral canal it receives basivertebral veins and also veins from the viscera (e.g. prostate). These communications may be hazardous to cause spread of cancer cells (metastasis) from viscera like prostate to vertebral bodies and even cranial bones.

Arachnoid Mater

Arachnoid mater is a thin transparent membrane covering the spinal cord. It extends upwards beyond foramen magnum to be continuous with arachnoid of brain and below extends like dura mater up to second sacral vertebra. Unlike dura mater, arachnoid is prolonged for a short distance around spinal nerves beyond intervertebral foramen. Arachnoid is separated from pia mater with spinal cord by a space known as subarachnoid space, which is continuous above with the same space around brain. The subarachnoid space (of spinal cord as well as brain) contains a thin watery fluid known as cerebrospinal fluid. Subarachnoid space containing cerebrospinal fluid is more prominent below lower end of spinal cord (L_2–S_2).

Spinal Subarachnoid Space and Clinical Anatomy of Lumbar Puncture (Fig. 4.7)

Spinal subarachnoid space is the space beneath the arachnoid mater covering the spinal cord. It is continuous with the subarachnoid space over the brain and contains cerebrospinal fluid. The subarachnoid space around the spinal cord becomes more spacious below the termination of spinal cord (L_2) upto its lower limit (S_2), which contains cerebrospinal fluid of considerable amount and is known as *lumbar cistern*.

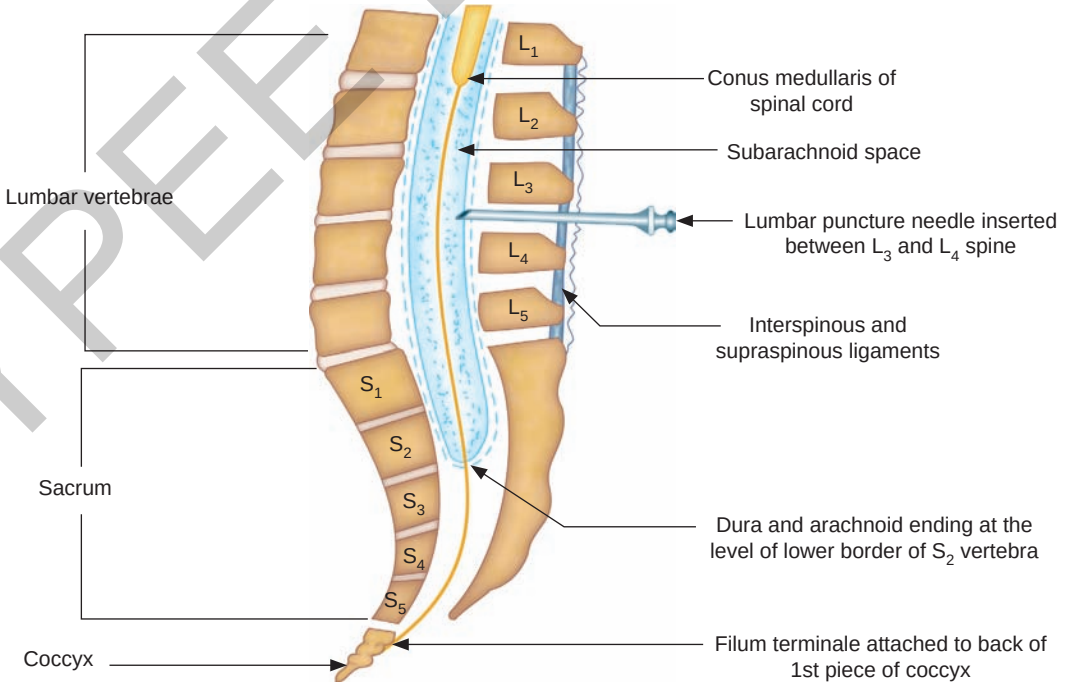

Fig. 4.7 Distal part of vertebral canal in sagittal section and prominent spinal subarachnoid space with illustration for site of lumbar puncture

JAYPEE BROTHERS

Lumbar Puncture (Spinal Tap)

Various diseases of spinal cord so also whole central nervous system may cause abnormal increase in normally freely flowing quantity of cerebrospinal fluid or may cause change of physical, biochemical or microscopical characteristics of cerebrospinal fluid. In these cases for diagnosis and treatment of the disease, cerebrospinal fluid (CSF) may be required to be drawn out from lumbar cistern below the termination of spinal cord. Again some drugs may be required to be injected into the spinal subarachnoid space (lumbar cistern) for treatment of some neurological disease or for induction of (spinal) anesthesia. This procedure is known as lumbar puncture (spinal tap).

Anatomical Guidelines for Lumbar Puncture (Fig. 4.7)

- *Site*: Puncture (introduction of needle cannula to draw fluid) is done through the interspinous space of vertebral column.
- *Level*: Spinal cord normally extends upto the level of intervertebral disk between 1st and 2nd lumbar vertebrae. On rare occasion it may extend lower down upto 2nd lumbar vertebra. Ideal level for puncture is the space between 3rd and 4th lumbar spines.
- *How to locate the levels of lumbar spines*: Transcristal line is the line passing through the level of highest point of both iliac crests. It passes through the level of 4th lumbar spine which will help to locate the interspinous space between 3rd and 4th lumbar spines.
- *Position of body*: Trunk of the body so also the vertebral column must be ventrally flexed either in lateral lying down position in bed or in sitting position to achieve two advantages.
  i. Interspinous space becomes wider.
  ii. Lower end of spinal cord is raised slightly upwards.

Knowledge of Planes of Puncture

During introduction of the needle-cannula, gentle and uniform (sustained) pressure is to be applied. After supraspinous and interspinous ligaments, and tough layer of dura mater are penetrated, suddenly a loss of resistance is felt. It confirms that needle has reached the subarachnoid space. At this stage patient may feel tingling root pain as nerve of cauda equina is touched by the tip of needle. But it is just for a while as it floats away in the cerebrospinal fluid.

Pia Mater

Pia mater is a thin delicate membrane which closely invests the surface of spinal cord. It is made up of fine layer of fibroreticular tissue into which is embedded network of fine blood vessels. Spinal pia mater presents following special features.

■ **Filum terminale**: It is a thin, white, delicate and shining thread-like structure which extends vertically downwards from conus medullaris of spinal cord. Its lower end is attached to the dorsal aspect of first piece of coccyx.

Length – 20cm

Structural composition: It is mainly composed of nonnervous pial connective tissue. But its upper end also contains nervous element. It is supposed to be rudiments of 2nd, 3rd and 4th coccygeal nerve.

Central canal of spinal cord extends beyond conus medullaris for about 5mm in the upper end of filum terminale, which is called *terminal ventricle*.

Parts: Spinal dura and arachnoid end at the level of 2nd sacral vertebra. But filum terminale extends from L_1/L_2 vertebra to 1st piece of coccyx. That is why it is divided into following two parts.

1. *Filum terminale internum*: It is proximal 15cm lying inside subarachnoid space.
2. *Filum terminale externum*: It is distal 5mm which is beyond S_2 vertebra.

■ **Linea splendens**: It is condensation of pia mater along the anterior median line of spinal cord, where it dips into anterior median fissure.

■ **Subarachnoid septum**: It is a thin fenestrated pial septum along the posterior median line of spinal cord extending from posterior median sulcus to deep surface of arachnoid mater.

■ **Ligamentum denticulatum**: This is a bilateral pial septum extending throughout whole length of spinal cord in between lines of attachment of ventral and dorsal nerve roots. Lateral margin of ligamentum denticulatum is ragged and presents 21 tooth like pointed projections. First pair is situated above the margin of foramen magnum of skull. Last pair is longer and oblique. It is attached at the level of conus medullaris and descends obliquerly downwards and laterally between twelfth thoracic and first lumbar nerves.

INTERNAL STRUCTURE OF SPINAL CORD

■ **Embryological background**: Knowledge of internal structure of spinal cord is based on fundamental concept of its embryological background. Spinal cord is developed from caudal elongated narrow tubular portion of neural tube which is ectodermal in origin. At 4th week of intrauterine life surface ectoderm along the midline gets condensed anteroposteriorly known as neural plate (Fig. 4.8). Neural plate lies dorsal to notocord which is related on either side to

JAYPEE BROTHERS

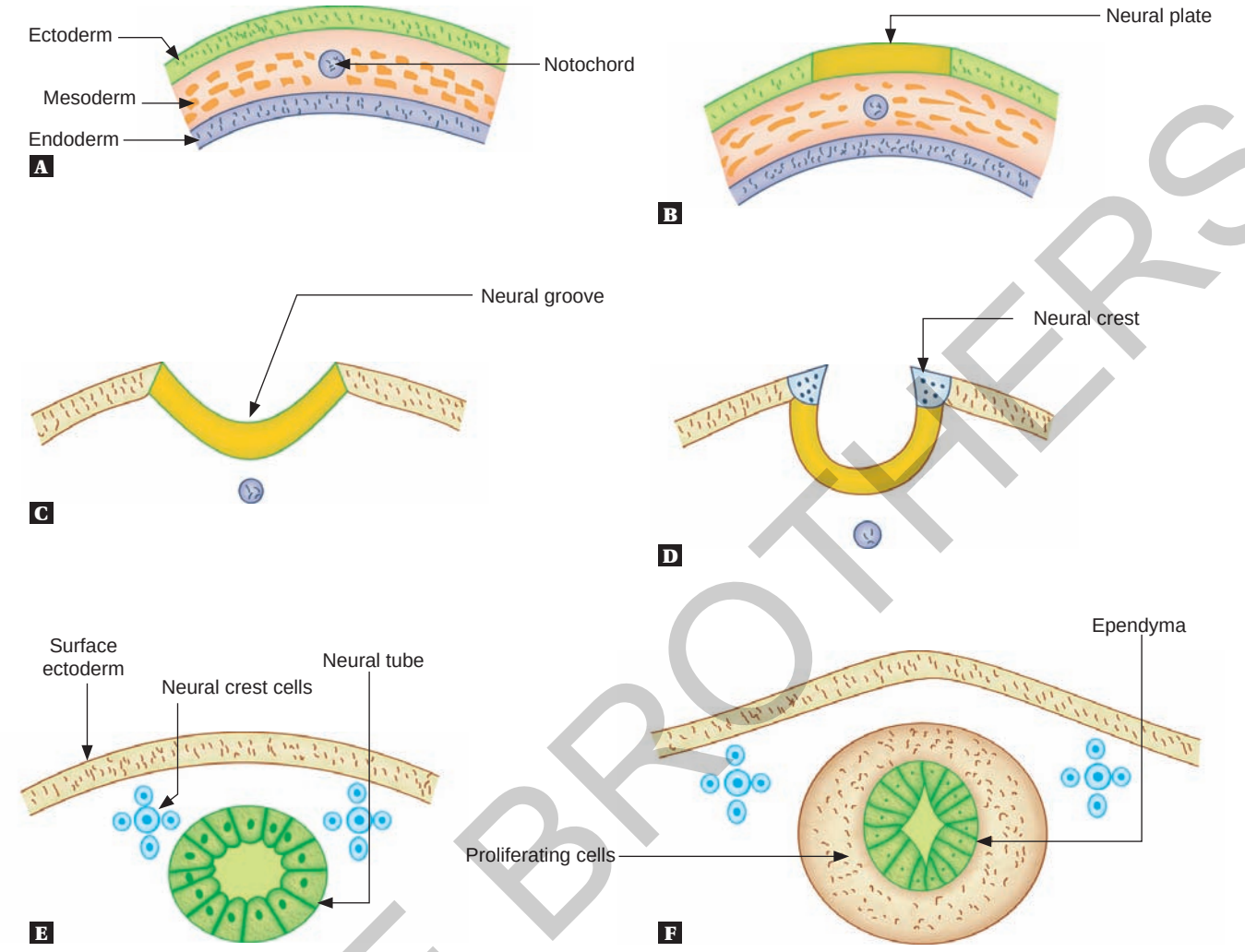

Figs 4.8A to F Illustrating development of spinal cord. A. Embryonic disk (Sectional view), B. Formation of neural plate, C. Formation of neural groove, D. Formation of neural crest, E. Neural tube lined by single layer neuroectodermal cells, F. Proliferation of neural tube cells

secondary mesoderm. The neural plate gradually becomes grooved or folded cephalocaudally along its long axis to form neural groove. This causes elevation of two parallel ridges known as neural crests. It is followed by two changes. Some cells of neural crest get detached and migrate ventrally on either side of midline beneath surface ectoderm. These are named neural crest cells. Secondly, the neural groove gradually deepens more and more with prominence of both sided neural crests which finally fuse to form neural tube. Fusion starts from the middle and proceed toward both cephalic and caudal ends. Just before 6th week of intrauterine life, when closed neural tube is formed, cephalic and caudal ends present openings known as anterior and posterior neuropores. Cephalic end of neural tube shows three dilatations known as forebrain, midbrain and hindbrain vesicles which will from brain. Caudal narrow, elongated tubular part of neural tube forms spinal cord.

FORMATION OF DIFFERENT ZONES OF SPINAL CORD (FIG. 4.9A)

The whole neural tube is initially lined by single layer of ectodermal cells known as neuroectoderm. Part of the tube giving rise to spinal cord, shows proliferation of cells same as proximal part. The canal of neural tube becomes a narrow cleft and shows thickening of lateral wall. Its thin dorsal and ventral walls are known as roof plate and floor plate. The original inner lining is known as ependymal layer or matrix cell layer. This layer of cells ultimately forms columnar epithelium lining the central canal of spinal cord known as *ependymal cells*. Free surface of these cells shows presence of ultramicroscopic finger-like, nonmotile processes known as *stereocillia*. Proliferated daughter cells, pushed to the periphery, form *mantle layer*. Cells of this layer shows differentiation into two types which are called *neuroblasts* and *spongioblasts*. Neuroblasts

JAYPEE BROTHERS

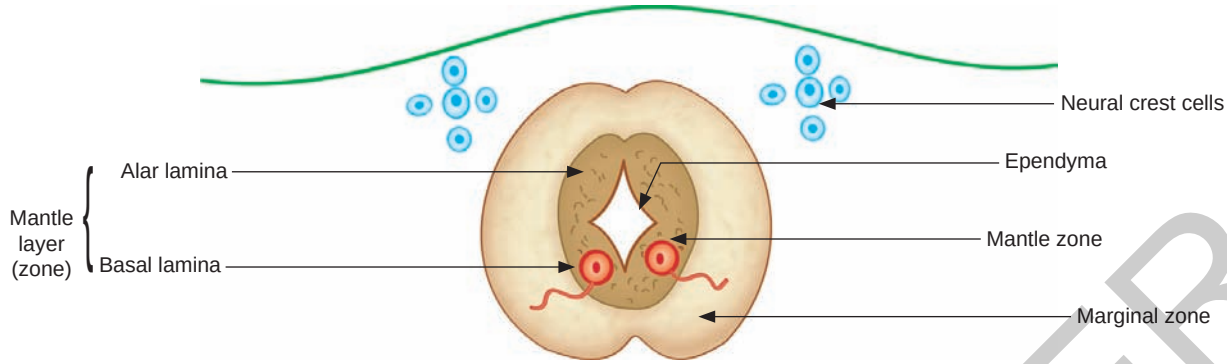

Fig. 4.9A Differentiation of mantle and marginal zones

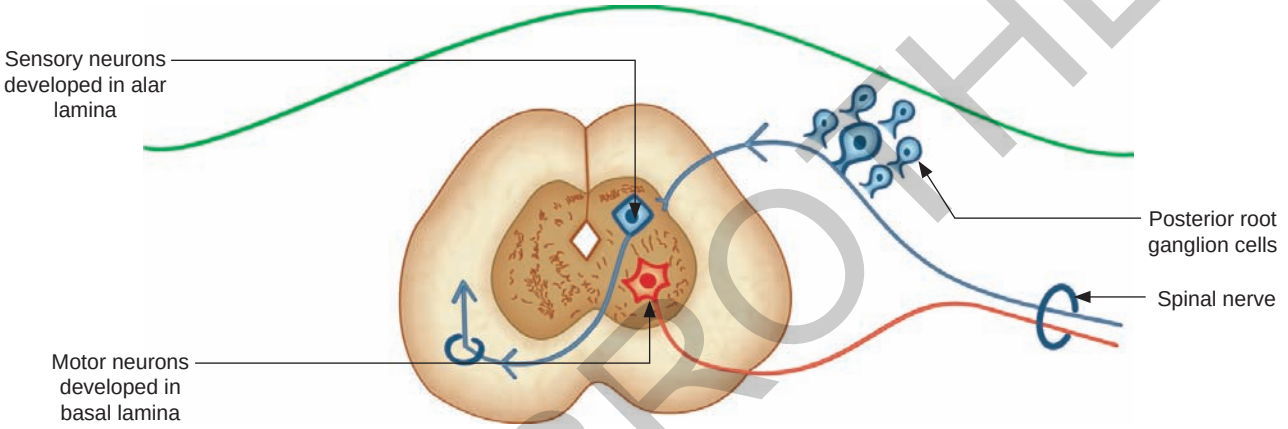

Fig. 4.9B Formation of different fundamental cells of spinal cord

will form *neurons* of spinal cord whose processes will be elongated to be pushed to the periphery to form more peripheral *marginal zone*. Spongioblasts will form supporting cells (neuroglia) of larger size known as *macroglia (astrocytes and oligodendrocytes)*. The most of the glial cells are pushed to the peripheral marginal zone. Cells bodies of neurons present in the mantle zone showing grayish appearance will form *central gray matter* of spinal cord. Processes of neurons (nerve fibers) located in peripheral marginal zone will be *myelinated by oligodendrocyte* group of cells of macroglia. This myelination will give whitish appearance of marginal zone of spinal cord for which it is called *white matter*.

FORMATION OF DIFFERENT FUNCTIONAL CELL GROUPS (FIG. 4.9B)

1. **Cells of ependymal (matrix) layer**: As already stated, these are original cell layer lining central canal of spinal cord called ependymal cells. The cells lined by stereocilia posses absorptive function.
2. **Cells of mantle zone**: On either side of midline the neurons developed from neuroblasts are divided into dorsal and ventral groups by two parallel cephalocaudal linear grooves on lateral wall of ependymal lining called sulcus limitans. Ventral and dorsal groups of neurons are known as Basal and Alar lamina respectively. Neurons of **basal lamina** will be *motor neurons* and those of **alar lamina** will form *sensory neurons*. Alar laminae of both sides are apposed towards each other so obliterating dorsal part of central canal of spinal cord. Two basal laminae diverge ventrolaterally forming future ventral median fissure of spinal cord.

   The neurons of **basal lamina** from two different cell columns as –

   i. *Somatic efferent (motor)*: Medial and close to floor plate. The processes of these neurons will supply voluntary (skeletal) muscles after leaving the spinal cord through ventral root of spinal nerve.

   ii. *Visceral efferent (motor)*: Lateral to and away from floor plate. Their processes leave spinal cord also through ventral root of spinal nerve as preganglionic fibers for involuntary (smooth) muscles and exocrine glands.

JAYPEE BROTHERS

The neurons of **alar lamina** form the following cell columns.

i. *Somatic afferent (Sensory)*: This cell column is medial and close to roof plate. Neurons of this column receive connections from the sensory cells outside central nervous system (posterior root ganglia cells) carrying somatic sensation from peripheral receptors.

ii. *Visceral afferent (Sensory)*: These neurons form cell column which is lateral to somatic afferent column and away from roof plate. They receive sensory impulse from the wall of viscera via posterior root ganglia cells.

Somatic efferent and somatic afferent cell columns of gray matter of spinal cord extend throughout whole length of spinal cord to be present in all 31 segments of spinal cord. Visceral efferent and visceral afferent cell columns being close to each other in the intermediate and lateral area of gray matter form **spinal center of autonomic nervous system**. But these cell groups, unlike somatic centers do not extend throughout all the segments of spinal cord. Neuronal groups of these columns extending from *1st thoracic (T_1) to 2nd lumbar (L_2) segments* of spinal cord form **sympathetic center** and those of *second, third and fourth sacral (S_2, S_3 and S_4) segments* form **parasympathetic center** of spinal autonomic nervous system.

Beside the above four groups of neurons developed in the mantle zone (gray matter) of spinal cord, some cells are known as interneurons or *internuncial neurons* which are functionally connecting neurons.

3. **Cell of marginal zone–(Marcoglia)**: They are supporting cells called marcoglia group of neuroglia which are *astrocytes* and *oligodendrocytes*. Some glial cells are also present in mantle zone. Astrocytes form connecting link between neurons and capillaries for selective transport of nutritive substances from capillaries to neurons and preventing entry of toxic materials (*blood neuron barrier*).
4. **Migrated cells from bloodstream (Microglia)**: Microglia are characterized by letter M. It is *mesodermal* in origin, derived from, *monocytes* and *migratory* in nature to act as *macrophages*.

PERIPHERAL OUTFLOW OF SPINAL CORD

Spinal Nerves

Spinal cord is made up of 31 segments. These segments are numbered regionally as Cervical-8, Thoracic-12, Lumbar-5, Sacral-5 and Coccygeal-1. A pair of nerve (right and left) is attached to the surface of each of the segments of spinal cord by two roots known as anterior (ventral) and posterior (dorsal) roots. Along the length of spinal cord anterior and posterior roots are attached along the lines of anterolateral sulcus and posterolateral sulcus respectively. Anterior or ventral roots of spinal nerve are outgoing (efferent) fibers of spinal nerve which go to the peripheral target organs, e.g. muscles or glands. They are called motor or efferent fibers. Posterior or dorsal roots of spinal nerve are the incoming (afferent) fibers of spinal nerve which carry informations from peripheral sensory end organs known as receptors. They are called sensory or afferent fibers.

All spinal nerves are mixed nerve: It is very clear from the above that each of the spinal nerves, either right or left, is composed of outgoing or efferent (motor) and incoming or afferent (sensory) fibers. So all of them are considered as mixed nerve.

It is to be remembered at this stage that, out of 12 pair of cranial nerve, some are mixed like spinal nerve, whereas others are either motor or sensory.

INTERNAL STRUCTURE OF SPINAL CORD

Internal structure of spinal cord can be understood through the study of its cross section (Fig. 4.10).

Cross section of spinal cord shows fundamentally following two components.

1. **Central gray matter**: This is so called due to grayish color of cell bodies of neurons. Central zones of gray matter looks like 'butterfly' on cross section. Roughly it resembles the capital letter 'H'. Intermediate bar of 'H' represents the body, whereas wings of butterfly are represented by two limbs of the letter.

Basic components of spinal gray matter: Intermediate part of spinal gray matter is traversed centrally be central canal of spinal cord throughout its whole length.

Central canal of spinal cord is lined by ependymal cells. The gray matter anterior and posterior to central canal are known as *anterior* and *posterior gray commissures* respectively.

Each side of spinal cord gray matter is composed of following components:

a) Anterior known as *anterior horn*
b) *Intermediate area*
c) Posterior known as *posterior horn*.

When considered the whole length of spinal cord, anterior gray horn forms the *anterior gray column* and posterior gray horn forms the *posterior gray column*.

In addition to the above mentioned three components, first thoracic to second lumbar segments (T_1 – L_2) of spinal cord gray matter show a lateral

JAYPEE BROTHERS

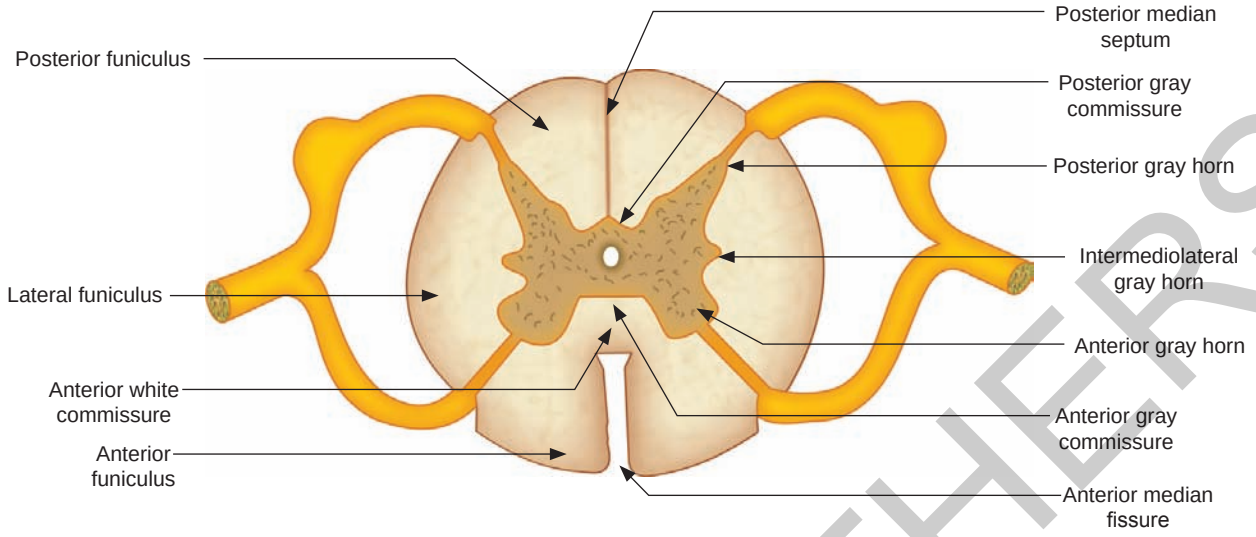

Fig. 4.10 Fundamental components of internal structure of spinal cord

projection of intermediate area, which is known as *intermediolateral cell column*. Neurons of this area constitute *sympathetic center* of autonomic nervous system. It is important to note at this stage that spinal *center of parasympathetic nervous system* is formed by neurons of intermediate area of *second, third and fourth (S_2, S_3 and S_4) sacral segments* of spinal cord.

The different components so also the entire gray matter of spinal cord show variations in appearance in different regions of spinal cord, because it depends upon the relative amount of nerve cells. Basically gray matter is proportionately broader in lower cervical and lumbosacral regions of spinal cord.

2. **Peripheral white matter**: This is mainly made up of compact bundles of nerve fibers running vertically either in ascending or in descending direction.

These fibers in the bundles are myelinated. The lipid-protein substance of myelin sheath of nerve fibers is white in color for which this peripheral zone of spinal cord is called white matter.

The bundles of ascending fibers carry sensory informations to the centers of brain above the level of spinal cord. The descending bundles carry impulse from higher motor centers of brain (above spinal cord) to the motor neurons situated in anterior horn of spinal cord.

On either side of midline, the white matter is composed of following three components called Funiculi (Singular – Funiculus).

a) *Anterior funiculus*: It is the part of white matter between anterior median fissure and anterolateral sulcus presenting outgoing fibers of ventral nerve root. Anterior funiculi of two sides are bridged by a thin midline strip of white matter known as *anterior white commissure*.

b) *Lateral funiculus*: It is the part of white matter demarcated between outgoing fibers of ventral root and incoming fibers of dorsal root of spinal nerve.

c) *Posterior funiculus*: It is the part of white matter between posterior median sulcus and incoming fibers of dorsal root of spinal nerve attached to the posterolateral sulcus. Posterior funiculi of both sides are separated incompletely or even completely by posterior median septum.

The bundles of fibers either ascending (sensory or afferent) or descending (motor or efferent) are called tracts or fasciculi (Singular-Fasciculus).

It is interesting to note at this stage that posterior funiculus is composed of only ascending tracts whereas anterior and lateral funiculi are composed of both ascending as well as descending tracts.

■ **Fundamental cell groups of spinal gray matter**: All neurons of spinal cord are multipolar.

Fundamentally the three different zones of spinal gray matter are made up of following four different neuronal groups.

1. **Posterior horn**: Sensory (afferent) or tract neurons
2. **Anterior horn**: Motor (efferent) neurons.
3. **Intermediate area**:
   i. Interconnecting neurons (interneurons), and
   ii. Parasympathetic neurons at S_2, S_3 and S_4 segments only.
4. **Intermediolateral area**: Sympathetic neurons (only $T_1 – L_2$ segmetns).

Both the sympathetic as well as parasympathetic areas are composed of motor and sensory neurons.

JAYPEE BROTHERS

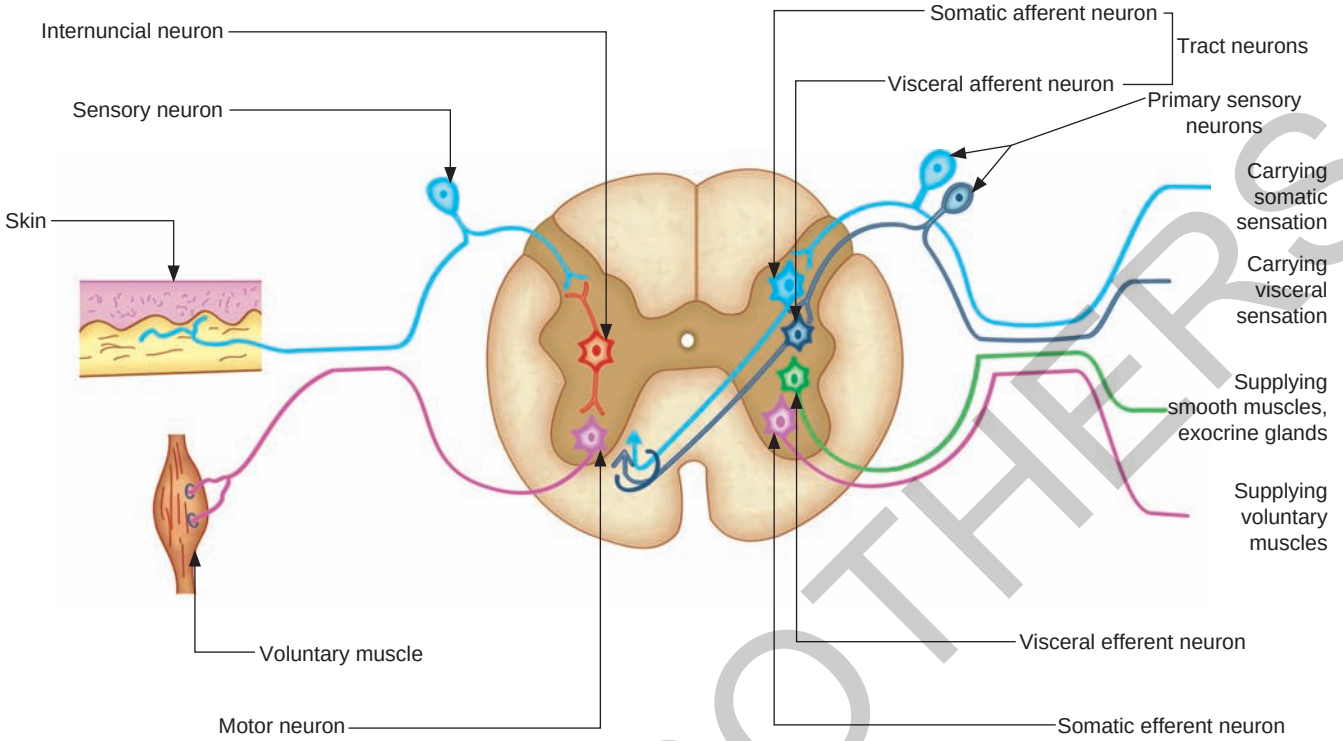

Fig. 4.11 Fundamental types of neurons of spinal gray matter

Functional classification of neurons of spinal gray matter (Fig. 4.11):

A. Tract neurons: These are sensory or afferent neurons present in posterior horn.

They are so called because their axons form compact bundles of ascending (sensory) tracts to relay in higher centers in brain.

They receive synaptic connections from central process of pseudounipolar neurons of posterior root ganglion which collect sensory informations from peripheral sensory end organs (receptors).

It is important to note at this stage that axons of tract cells may ascend in the same side or may cross the midline and then ascend along opposite side of spinal cord to form uncrossed (ipsilateral) or crossed (contralateral) tracts respectively.

B. Motor neurons (efferent neurons): The neurons of anterior horn are motor neurons. Their axons, leaving spinal cord through ventral root, end in voluntary muscles via spinal nerve.

These motor neurons of spinal cord are called *lower motor neurons* on which relay the axons of nerve cells situated at higher centers (brain) which are called upper motor neurons.

Motor neurons of anterior horn of spinal cord sending axons to voluntary muscles are of two types:

i. *Alpha motor neurons*: Their cell bodies are more than 25 microns in size and their axon terminate in extrafusal fibers of voluntary muscles, stimulation of which results in muscular contraction.

ii. *Gamma motor neurons*: Cell bodies of these neurons are less than 25 microns in size and their axons terminate in intrafusal fibers of voluntary muscles, stimulation of which is concerned with increase in muscle tone.

C. Interneurons (internuncial neurons): These are example of short axoned Golgi type II neurons.

Their axon as well as dendrite are shorter being confined in the gray matter of spinal cord.

Functionally they are interconnecting in nature forming synaptic link between sensory and motor neuron which together form a local reflex arc (Fig. 4.11).

Internuncial neuron also leads to an advantage by connecting one first order of neuron, through its multiple axon collateral, to the multiple third order of neurons.

Further classification of motor and sensory neurons (Fig. 4.11):

It is already understood from the knowledge of embryological background that, mantle zone of developing spinal cord forming gray matter forms four column of cells which are as follows from ventral to dorsal aspect.

1. Somatic motor (efferent)
2. Visceral motor (efferent)

JAYPEE BROTHERS

Easy & Interesting Approach to

HUMAN NEUROANATOMY

(Clinically Oriented)

Salient Features

- Text material has been carefully placed on the optimum line of demarcation between comprehensive and precise nature. Much more precise text apparently appears to be simple, but it fails to create concept. Again, if the text is too much comprehensive, it kills time and creates monotony.
- Style of presentation of the book will help the students for self-learning.
- All the figures of the book have been drawn in most simplified manner. Complicated and extensive figures have been deliberately avoided.
- Labelings of all the figures have been made in more scientific way. Optimum words have been used for the labeling, for which a reader will be able to understand a part of text even only consulting the figures.
- Clinical anatomy component of the text has been written as per relevance.



Samar Deb is presently working as Professor of Anatomy, Agartala Government Medical College, Tripura, India. He obtained his MBBS degree from NRS Medical College, Kolkata, West Bengal. He was awarded postgraduate degree (MS in Anatomy) by Institute of Medical Sciences, Banaras Hindu University, Varanasi, Uttar Pradesh, India. He joined the medical teaching profession in 1972 at North Bengal Medical College, Darjeeling, West Bengal, where he worked as Professor of Anatomy till 1992. Following his retirement from government service in 2008, he worked as Academic Director as well as Principal and Professor of Anatomy, Katihar Medical College, Katihar, Bihar and as Principal, College of Medicine and JNM Hospital, Kalyani, West Bengal.

He is a life member of Anatomical Society of India. He was member of Medical Council of India for about a decade. He served as postgraduate teacher for many years and guided a number of PhD students and published many research papers. He possesses the experience of being MCI Inspector and undergraduate and postgraduate examiner of many universities. He has established himself as a popular and successful teacher.

Available at all medical book stores
or buy directly from Jaypee Brothers through online shopping
at www.jaypeebrothers.com

JAYPEE BROTHERS
Medical Publishers (P) Ltd.
www.jaypeebrothers.com

Shelving
Recommendation
ANATOMY

ISBN 978-93-5090-940-9