Essentials of
SPINAL DISORDERS





Jason C Eck
Christian P DiPaola



JAYPEE

Contents

Introduction *xvii*

1. Anatomy of the Spine **1**

- Vertebrae 1
- Ligaments 3
- Intervertebral Disk 4
- Intervertebral Foramen 5

2. Spinal Imaging **7**

- Imaging Modalities 7
  - — Conventional Radiographs 7
  - — Myelography 9
  - — Computed Tomography 10
  - — Magnetic Resonance Imaging 11
  - — Scintigraphy 12
  - — Angiography 13
- Spinal Disorders 15
  - — Degenerative Disorders 15
  - — Spinal Trauma 17
  - — Neoplastic Disease 18
  - — Postoperative Imaging of the Spine 20

3. Spinal Biomechanics **23**

- Definitions of Mechanical and Material Properties 23
- Functional Biomechanics of the Disk 28
- Kinematics of the Spine 29
- Spinal Stability 31
- Biomechanics of Spinal Instrumentation 31

4. History and Physical Examination of the Spine **33**

- Patient's History 34
- Past Medical History 35
- Social History 35
- Physical Examination 36
- Nonorganic Signs 39

5. Cervical Disk Disease 41
- Pathophysiology 41
- Patient Presentation 44
- Imaging Studies 45
- Electrodiagnostic Studies 46
- Nonoperative Treatment 47
- Operative Treatment 49

6. Cervical Spine Stenosis 57
- Pathophysiology 57
- Patient Presentation 58
- Imaging Studies 61
- Electrodiagnostic Studies 64
- Nonoperative Treatment 64
- Operative Treatment 65

7. Cervical Spine Trauma 69
- Pathophysiology 69
  - — Occipitocervical Injury 70
  - — Atlantoaxial Cervical Spine 72
  - — Odontoid Fractures 74
  - — Traumatic Spondylolisthesis of the Axis 74
  - — Subaxial Cervical Spine 75
- Patient Presentation 78
- Imaging 79
- Nonoperative Treatment 82
  - — Occipitocervical Injury 82
  - — Jefferson Fractures 82
  - — Traumatic Spondylolisthesis of the Axis (Hangman's Fractures) 82
  - — Odontoid Fractures 83
  - — Subaxial Cervical Spine Fractures 83
- Operative Treatment 84
  - — Occipitocervical Injury 84
  - — Jefferson Fractures 85
  - — Traumatic Atlantoaxial Instability 85
  - — Traumatic Spondylolisthesis of the Axis (Hangman's Fractures) 85
  - — Odontoid Fractures 85
  - — Subaxial Cervical Spine Fractures 86

8. Spinal Cord Injury 91
- Pathophysiology 91
- Patient Presentation 92

- Neurologic Assessment 92
- Imaging 96
- Nonoperative Treatment 97
- Operative Treatment 100

9. Lumbar Disk Disease 104

- Pathophysiology 104
- Patient Presentation 106
- Imaging 107
- Electrodiagnostic Studies 110
- Nonoperative Treatment 110
- Operative Treatment 111

10. Lumbar Spinal Stenosis 115

- Pathophysiology 115
- Patient Presentation 118
- Imaging 119
- Nonoperative Treatment 119
- Operative Treatment 121

11. Lumbar Spondylolisthesis 124

- Pathophysiology 124
- Patient Presentation 126
- Imaging 127
- Nonoperative Treatment 129
- Operative Treatment 131

12. Thoracolumbar Spine Trauma 133

- Pathophysiology 133
- Patient Presentation 137
- Imaging 139
- Nonoperative Treatment 139
- Operative Treatment 141
  - — Posterior Instrumentation 142
  - — Special Considerations 144
  - — Anterior Spinal Reconstruction 147

13. Adolescent Idiopathic Scoliosis 152

- Pathophysiology 152
- Patient Presentation 154
- Imaging Studies 154
- Nonoperative Treatment 157
- Operative Treatment 159

14. Adult Scoliosis 162
- Pathophysiology 162
- Patient Presentation 164
- Imaging 165
- Nonoperative Treatment 167
- Operative Treatment 168

15. Inflammatory Disorders of the Spine 171
- Rheumatoid Arthritis 171
  - — Pathophysiology 171
  - — Patient Presentation 173
  - — Imaging Studies 173
  - — Nonoperative Treatment 177
  - — Operative Treatment 177
- Seronegative Spondyloarthropathies 178
  - — Pathophysiology 178
  - — Patient Presentation 180
  - — Imaging Studies 180
  - — Nonoperative Treatment 182
  - — Operative Treatment 183

16. Osteoporosis of the Spine 186
- Bone Biology 186
- Pathophysiology 188
- Patient Presentation 189
- Laboratory Studies 191
- Imaging Studies 192
  - — Plain Radiographs 192
  - — Magnetic Resonance Imaging 193
  - — Computed Tomography 194
  - — Bone Densitometry 194
  - — Screening Recommendations 195
- Nonoperative Management 196
- Operative Management 197

17. Spinal Infections 201
- Pathophysiology 201
- Patient Presentation 203
- Imaging Studies 205
- Nonoperative Treatment 205
- Operative Treatment 206

18. Spinal Tumors **212**

- General Principles of Evaluation, Classification and Staging for All Spinal Neoplasms 212
- Pathophysiology 213
- Patient Presentation 214
  - — Metastatic Spinal Disease 214
  - — Primary Spine Tumors 215
  - — Benign Primary Spinal Neoplasms 215
  - — Malignant Primary Spinal Neoplasms 216
- Imaging 216
  - — Hemangioma 216
  - — Osteoid Osteoma 217
  - — Osteoblastoma 217
  - — Aneurysmal Bone Cyst 218
  - — Osteochondroma 218
  - — Giant Cell Tumor 219
  - — Eosinophilic Granuloma 219
- Staging 220
  - — Metastatic Spinal Disease 220
  - — Benign Primary Spinal Neoplasms 221
  - — Malignant Primary Spinal Neoplasms 221
- Nonoperative Treatment 223
  - — Spinal Metastases 223
  - — Benign Primary Spinal Neoplasms 224
  - — Malignant Primary Spinal Neoplasms 224
- Operative Treatment 225
  - — Spinal Metastases 225
  - — Benign Primary Spinal Neoplasms 226
  - — Malignant Primary Spinal Neoplasms 227

19. Bone Grafting **231**

- Allograft 235
- Demineralized Bone Matrix 236
- Bone Morphogenetic Protein 237
- Synthetic Bone Grafts 239
- Osteopromotive Agents 239

Index *243*

CHAPTER 4

History and Physical Examination of the Spine

One of the most important aspects to master in the care of the patient with a spinal disorder is the history and physical examination of the spine. It is during this initial evaluation of the patient that the clinician develops a differential diagnosis, indentifies potential emergent problems, initiates further testing if needed and begins to construct a potential treatment plan.

Despite the fact that spinal disorders are very common, an accurate diagnosis can remain challenging. There are certain clues that can be identified based on the patient's recent history, past medical history, age and physical examination findings that can lead the clinician to a differential diagnosis. The most important initial goal is to rule out the presence of any serious pathology that potentially needs emergent treatment. There are certain "red flags" that can lead the clinician to suspect the presence of more serious pathology as summarized in Table 1. These main categories of emergent problems include cancer, infection, fracture and cauda equina syndrome. Each of these needs to be identified early to initiate the appropriate treatment and decrease the associated complications. Cancer should be considered in the patient with a new onset or worsening pain that is not relieved with rest especially if the patient has a history of cancer or strong smoking. Infection of the spine can be difficult to diagnose initially, as spine infections do not typically present with the same constitutional symptoms as other systemic infections. Infection should be considered in patients who are immunocompromised or with a history of intravenous drug usage. Patients do not need to have fever, chills or elevated white blood cell count to have a spine infection. The most concerning infection is an epidural abscess that results in compression of the spinal cord and a progressive neurologic deficit. In many cases of spinal fracture a recent trauma has occurred. However, in patients with osteoporosis or inflammatory disorders including ankylosing spondylitis (AS) or diffuse idiopathic skeletal hyperostosis (DISH) fracture can occur with little or no trauma to the spine. Any patient with AS or DISH that has a change in the position of the spine or an increased range of motion should be considered to have a spinal fracture until proven otherwise. Cauda equina syndrome is the final category and is a surgical emergency. Patients present with saddle anesthesia, severe lower back and/or lower extremity pain and loss of bowel and/or bladder control. The loss of bowel control consists of bowel incontinence, while the bladder dysfunction consists of an initial inability to void followed by an overflow incontinence.

Table 1: List of "red flags" that may suggest more serious etiology of spinal disorders

Potential etiology	*Finding or symptom*
Cancer	Personal history of cancer
	History of smoking
	Unexplained weight loss
	Age > 50 years
	Pain at night or not relieved with rest
Infection	Fever
	Immunosuppression (from medications or illness)
	Intravenous drug use
	History of recent infection
Fracture	Age > 50 years
	Osteoporosis or osteopenia
	History of recent trauma
	Ankylosing spondylitis
	Diffuse idiopathic skeletal hyperostosis
	Use of corticosteroids
Cauda equina syndrome	Saddle anesthesia
	Loss of bowel or bladder control

PATIENT'S HISTORY

The first step in the patient evaluation is to obtain the chief complaint. This typically can be summarized in a single statement of why the patient is presenting to you. In most cases, this information can be obtained directly from the patient. However, in cases of trauma or dementia the chief complaint may need to be obtained from other sources. The chief complaint may be a simple statement of lower back or neck pain, while in other cases the patient may present with a presumptive diagnosis based on previous evaluation by other providers. Care should be taken to avoid being biased by the patient's presumptive diagnosis prior to your own history and physical examination.

Once the chief complaint has been established, further information regarding the patient's history can be determined with targeted questions. Key components that should be investigated include the duration of the patient's symptoms, whether or not there was any inciting event or trauma that was thought to cause these symptoms, what activities alleviate or exacerbate the symptoms, and whether or not the patient has had any prior history of similar symptoms in the past. Any prior treatment should be determined along with its degree of effectiveness.

The most common complaint of patients with spinal disorders is pain. The severity, character and specific location of the pain can help lead to a diagnosis. The severity of the pain can be rated on either a numeric rating scale (0–10) or a visual analog scale (the patient marks a point on a 10 cm line corresponding to the severity of pain). The character of the pain can be described as sharp, dull, burning, cramping, etc. It can either be isolated to the axial spine or radiate to the extremities. Axial pain is more commonly associated

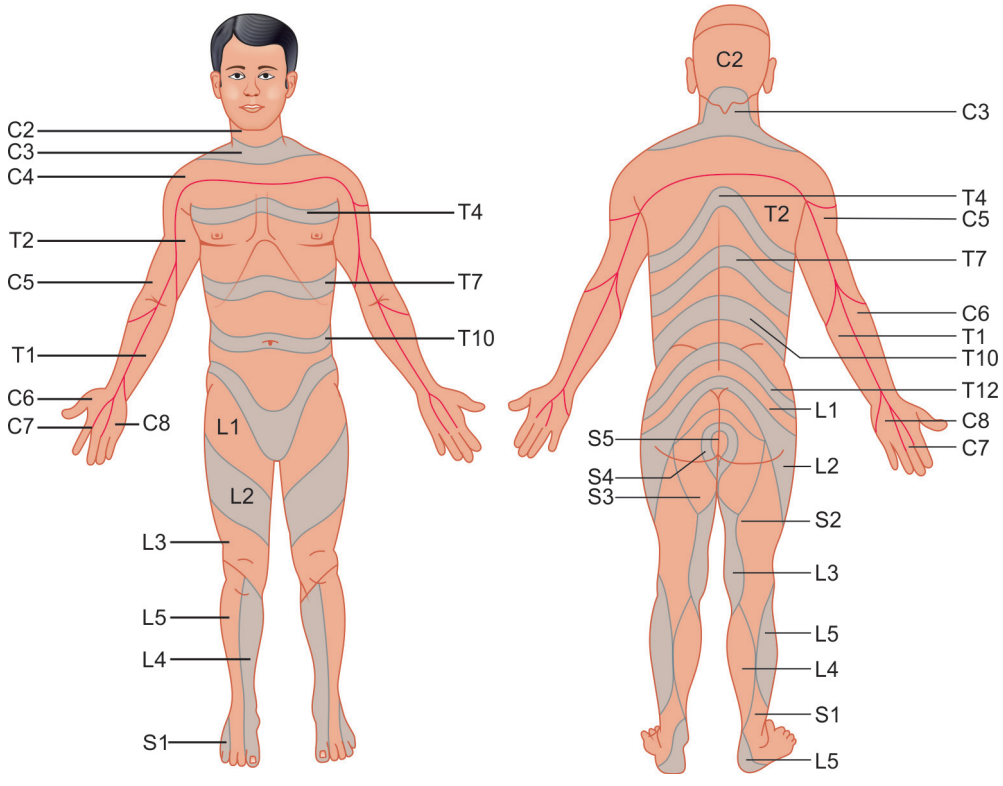

Fig. 1: Anterior and posterior location of spinal dermatomes

with degenerative disk disease, facet joint degeneration, and muscular and ligamentous structures. Radicular pain is more commonly caused by nerve root compression from disk herniations or stenosis. The location of radicular pain often follows a specific nerve root distribution that can assist in determining the location of the pathology (Fig. 1).

PAST MEDICAL HISTORY

In addition to information of the patient's current complaints, it is important to obtain a complete past medical history. This can help with the differential diagnosis as many spinal disorders can be associated with other medical conditions. The patient should be specifically questioned regarding the history of cancer, recent infection, immune suppression, current medications and previous surgeries. Conditions including vascular disorders, diabetes or herpes zoster can each result in peripheral pain complaints similar to radiculopathy from a spinal etiology. Patients with a history of osteopenia, osteoporosis or inflammatory disorders are more prone to fractures with minor trauma.

SOCIAL HISTORY

There are many factors related to the patient's lifestyle that can play a crucial role in both diagnosis and treatment of spinal disorders. The use of tobacco, alcohol or other drugs should be documented. Tobacco use can increase the level of pain and lead to further

degeneration of the spinal structures. Additionally, nicotine is well-known to inhibit normal bone formation which can lead to failure of spinal fusion and chronic pain.[1,2] The use of illicit drugs can decrease the effectiveness of many pain medications. The use of intravenous drugs places the patient at increased risk for spinal infection including epidural abscess.

The patient's education and work status should be documented. Lack of satisfaction with work or poor perceived work environments can increase the incidence of chronic pain and disability and decrease the likelihood of treatment success.[3,4] Involvement of worker's compensation claim or litigation has also been reported to negatively affect patient outcomes.[5,6]

A history of psychological distress, anxiety or depression should also be determined. These conditions can negatively affect outcomes of treatment.[7,8] Additionally, medications for these comorbidities can potentially negatively interact with other medications used for spinal disorders.

PHYSICAL EXAMINATION

After obtaining a complete history, the next step is to perform the physical examination. The examination is often targeted to the areas of complaints identified during the history. The components of the physical examination include inspection, palpation, neurological testing and special tests.

Inspection should begin with observing the patient ambulating into the examination room if possible. Abnormalities in the patient's gait pattern can provide clues to underlying spine pathology. The gait should be evaluated for overall balance, posture, stride length and steadiness. Poor balance could represent a sign of myelopathy, while a forward flexed posture could represent lumbar stenosis. Once in the examination room the patient should be undressed sufficiently to allow for adequate inspection of the entire spine and extremities. The skin should be inspected for any surgical or traumatic scars, rashes or pigment changes. Overall patient balance in the frontal and sagittal view can reveal the presence of scoliosis or increased kyphosis. The spine should be evaluated both in an upright stance as well as with the patient forward flexed to assess for changes in rib prominence. The level of the shoulders and iliac crest should be compared as well as identified as any asymmetric skin creases. Active range of motion testing should be performed of the cervical, thoracic and lumbar spine to assess flexibility and to identify any restrictions in motion or pain generators. The muscles should be inspected for signs of atrophy that could be the result of severe nerve root compression.

Palpation of the midline spinous processes should be performed to locate any area of tenderness or step-offs between the levels. The paraspinous muscles should be palpated to identify areas of localized or generalized tenderness. Any masses or muscles spasms should be noted. The greater trochanters should be palpated as trochanteric bursitis is commonly mistaken for a potential spinal disorder. Evaluation of peripheral pulses can identify potential vascular causes of pain.

The neurologic examination includes evaluation of the sensation, motor function and reflexes. The sensory examination assesses for areas of diminished sensation along specific dermatomes associated with specific nerve roots (Fig. 1). This can be performed for both

Table 2: Motor strength grading scale

Grade	*Description*
5	Full active motion against full resistance (normal strength)
4	Full active motion against some resistance
3	Active motion against gravity
2	Active motion without gravity
1	Muscle twitch only, no active motion
0	No muscular contraction

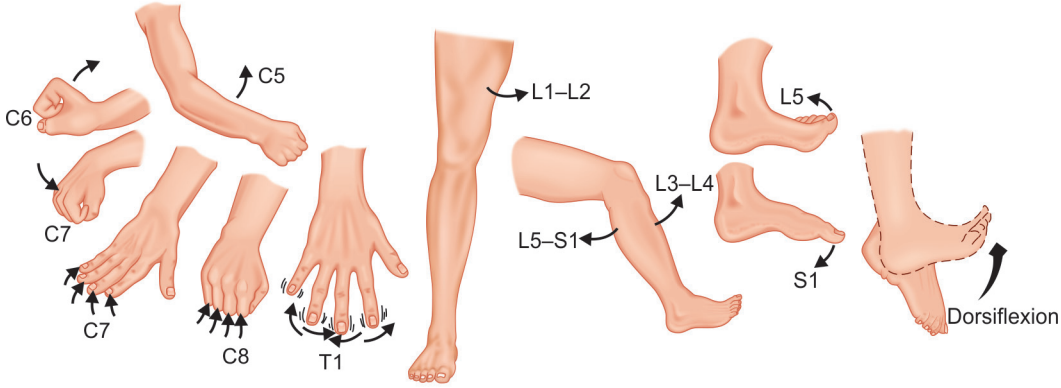

Fig. 2: Muscle strength testing associated with specific nerve roots

light touch and pin prick. More diffuse areas of sensory deficit including a "stocking" or "glove" distribution may suggest the presence of peripheral neuropathy or nonorganic pathology. The motor examination is performed to identify potential areas of muscle weakness that could be the result of specific nerve root dysfunction or a more global spinal cord injury. Muscle strength testing is graded on a five-point scale as described in Table 2. The specific nerve roots responsible for muscle function are illustrated in Figure 2. Testing for the presence of reflexes can also help identify spinal disorders. A reduction or absence of reflex is often associated with a lower motor neuron disorder, while an exaggerated reflex or hyperreflexia is associated with an upper motor neuron disorder. Figure 3 illustrates the reflexes associated with specific nerve roots.

After the history and physical examination have been completed, the clinician may start to form a differential diagnosis. Based on this list of potential diagnoses there are additional maneuvers and tests that can be performed to help confirm or eliminate some disorders from the differential diagnosis. A Spurling's maneuver is performed on patients with unilateral upper extremity radiculopathy. The patient's head is extended and bent toward the side of the symptoms. The clinician then gently pushes downward on the patient's head. A positive test causes an increase in the radiculopathy by causing additional compression of the exiting nerve roots in the cervical foramen. Lhermitte's sign is present if the patient experiences an electrical shock-like sensation radiating into the trunk and upper and lower extremities

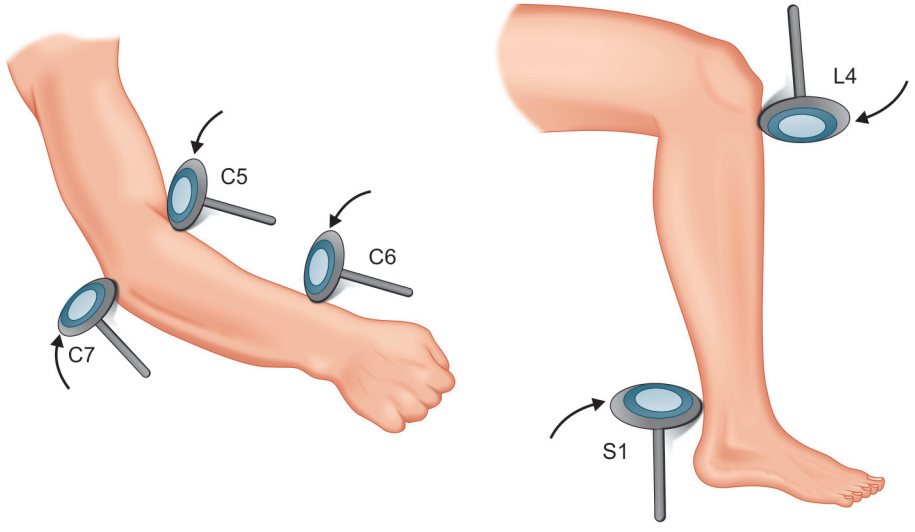

Fig. 3: Reflex testing associated with specific nerve roots

with flexion of the head and neck. This sign is present in some cervical spinal cord disorders and causes additional compression of the cervical spinal cord by reducing the spinal canal diameter. A Hoffman's sign is performed on patients with suspected myelopathy or upper motor neuron disorders. The patient relaxes the wrist, and the examiner places the wrist in slight extension. The distal aspect of the middle finger is flicked into flexion. A positive sign is when the patient's thumb or other fingers spontaneously flex. Beevor's sign is performed to evaluate for thoracic motor function. The patient performs a partial sit-up while the umbilicus is observed. If all thoracic nerve roots are functioning properly the umbilicus retracts proximally along the midline. If there is a dysfunction in the middle or lower thoracic nerve root the umbilicus would deviate to the contralateral side due to relative weakness in the abdominal musculature. The femoral nerve stretch test is performed for suspected upper lumbar (L2-L4) nerve root compression. The patient lies prone on the examination table while the examiner extends the knee and hip joint by lifting the knee off the bed. A positive test causes an increase in the radiculopathy by causing additional stretch or compression of the upper lumbar nerve root. The straight leg raise test is performed for suspected lower lumbar (L4-S1) nerve root compression. It can be performed with the patient seated and supine. The examiner gradually raises the patient's leg and evaluates for recreation or worsening of the radiculopathy. The test is positive if it causes radiating pain in the leg between 30° and 70° of elevation. The Valsalva maneuver can be performed on patients with a suspected lumbar disk herniation. The patient holds his or her breath while bearing down. A positive test causes an increase in the lower extremity radiculopathy by increasing the intradiscal pressure.

Table 3: Waddell's nonorganic physical signs in low back pain

Sign	*Description*
Tenderness	
Superficial	Skin tender to light pinch over a wide area
Nonanatomic	Deep tenderness over a wide area
Simulation Test	
Axial loading	Low back pain elicited by vertical loading of the patient's head
Rotation	Low back pain with passive rotation of the shoulders and pelvis in the same plane
Distraction	Variation in straight leg raising test results when the patient is otherwise distracted
Straight leg raising	
Regional disturbances	
Weakness	Partial "giving way" of multiple muscles in a nonanatomic distribution
Sensory	Decreased sensation in a "stocking" or "glove" distribution as opposed to a dermatomal pattern
Overreaction	Presence of disproportionate response including verbalization, facial expression, tension, tremor or sweating

NONORGANIC SIGNS

If the clinician suspects the possibility of malingering or nonorganic causes of the patient's pain Waddell's signs can be tested[9] that are given in Table 3. These include five types of physical signs that could suggest the presence of a nonorganic component to the patient's complaints. If three or more of the five signs are found to be positive it is felt to be clinically significant. Caution should always be taken in evaluating for nonorganic causes of pain. All patients should be given the benefit of the doubt that their complaints are real. Inappropriately labeling a patient as malingering can lead to a potential delay in proper diagnosis.

KEY POINTS

- It is crucial to identify potential "red flags" that need more emergent treatment.
- A thorough history can help form a differential diagnosis.
- The physical examination can further confirm or eliminate an etiology from the differential diagnosis.
- The presence of nonorganic signs should be considered, but only as a diagnosis of exclusion.

REFERENCES

1. Andersen T, Christensen FB, Laursen M, et al. Smoking as a predictor of negative outcome in lumbar spinal fusion. Spine. 2001;26(23):2623-8.
2. Sanden B, Forsth P, Michaelsson K. Smokers show less improvement than nonsmokers two years after surgery for lumbar spinal stenosis: a study of 4555 patients from the Swedish spine register. Spine. 2001;36(13):1059-64.

3. Macfarlane GJ, Pallewatte N, Paudyal P, et al. Evaluation of work-related psychosocial factors and regional musculoskeletal pain: results from a EULAR Task Force. Ann Rheum Dis. 2009;68(6): 885-91.
4. Mielenz TJ, Garrett JM, Carey TS. Association of psychosocial work characteristics with low back pain outcomes. Spine. 2008;33(11):1270-5.
5. Carreon LY, Glassman SD, Kantamneni NR, et al. Clinical outcomes after posterolateral lumbar fusion in workers' compensation patients: a case-control study. Spine. 2010;35(19):1812-7.
6. Nguyen TH, Randolph DC, Talmage J, et al. Long-term outcomes of lumbar fusion among workers' compensation subjects: a historical cohort study. Spine. 2011;36(4):320-31.
7. Edmond SL, Werneke MW, Hart DL. Association between centralization, depression, somatization, and disability among patients with nonspecific low back pain. J Orthop Sports Phys Ther. 2010;40(12):801-10.
8. Kroenke K, Wu J, Bair MJ, et al. Reciprocal relationship between pain and depression: a 12-month longitudinal analysis in primary care. J Pain. 2011;12(9):964-73.
9. Waddell G, McCulloch JA, Kummel E, et al. Nonorganic physical signs in low-back pain. Spine. 1980;5(2):117-25.

Essentials of Spinal Disorders

Disorders of the spine are one of the most commonly encountered medical complaints affecting nearly everyone at some point during life. *Essentials of Spinal Disorders* provides a succinct overview of the most common spinal disorders in an easy-to-read and understand format. The liberal use of full-color illustrations and radiographic images adds to the value of this text by simplifying these complex topics.



Jason C Eck DO MS is currently in private practice as an orthopedic spine surgeon at the Center for Sports Medicine and Orthopedics in Chattanooga, Tennessee, USA. Prior to this, he was an Assistant Professor of Orthopedic Surgery at the University of Massachusetts, Worcester, Massachusetts, USA. He has edited three previous books and authored over 90 peer-reviewed journal articles. He has received numerous research awards from the American Academy of Orthopedic Surgeons, Cervical Spine Research Society, American Spinal Injury Association, Eastern Orthopaedic Association, and the Scoliosis Research Society.



Christian P DiPaola MD is Assistant Professor of Orthopedic Surgery at the University of Massachusetts, Worcester, Massachusetts, USA. His practice is diverse and focuses on operative treatment of all major spinal disorders. He has special interest and expertise in the management of spinal trauma, tumors and deformity. He enjoys his clinical practice as well as teaching residents and other peer spine surgeons. He is president of the New England Spine Study Group. He has authored multiple book chapters and is active in original research and publishes routinely on a variety of subjects. His special interests include systems optimization and quality improvement.

Shelving Recommendations
SPINE SURGERY
ORTHOPEDIC SURGERY
NEUROSURGERY
PHYSICAL MEDICINE & REHABILITATION

Available at all medical book stores
or buy directly from Jaypee Brothers through online shopping
at www.jaypeebrothers.com

JAYPEE BROTHERS
Medical Publishers (P) Ltd.
www.jaypeebrothers.com

ISBN 978-93-5090-983-6