eebrothers.com, for detailed information of dermatology books, visit our website www.jaypeebrothers.com, for detailed information of dermatology books

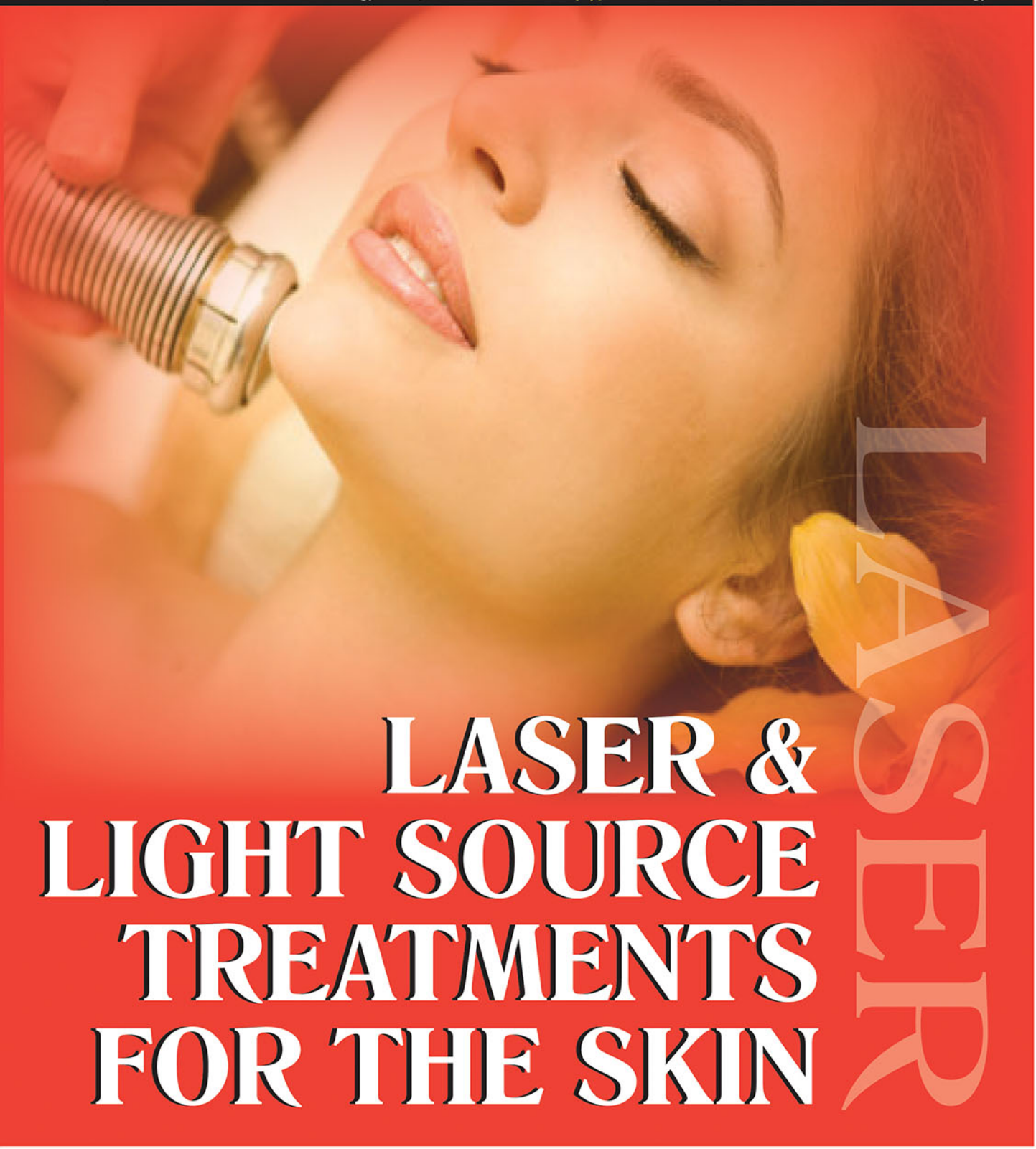

LASER

LASER & LIGHT SOURCE TREATMENTS FOR THE SKIN

Editors
Mathew M Avram
Paul M Friedman

Series Editor
Marc R Avram

Foreword
Marc R Avram

JAYPEE

Contents

1. Introduction to Lasers: Light–Tissue Interaction and Laser Safety **1**

Joshua D Shofner

- Introduction to Lasers 1

2. Laser and Light Treatment for Cutaneous Vascular Lesions **5**

Iris Rubin

- Port-Wine Stains 6
- Infantile Hemangioma 8
- Telangiectasias 9
- Cherry Angiomas 10
- Spider Angiomas 10
- Venous Lakes 10
- Venous Malformations 10
- Spider Veins 11
- Angiokeratomas 11

3. Pigmented Lesions: General Considerations and Epidermal Lesions **13**

Nazanin Saedi

- Pigmented Lesions: General Considerations 13

4. Tattoos, Melasma and Dermal Pigment **17**

Kelly Stankiewicz

- Tattoo Removal 17
- Dermal Pigment 24
- Nevus of Ota and Other Dermal Melanocytoses 25

5. Laser Hair Removal **28**

Omar A Ibrahimi, Suzanne L Kilmer, Mathew M Avram

- The Hair Follicle 28
- Mechanism of Laser Hair Removal 29
- Key Factors in Optimizing Treatment 34

6. Laser and Light Therapy for Acne Vulgaris **43**

H Ray Jalian, Fernanda H Sakamoto

- Lasers 44
- Noncoherent Light Sources 46
- Lipid Selective Light: Towards a True Sebaceous Gland Selective Laser 49

7. Introduction to Laser Skin Resurfacing 52

Tina S Alster, Jennifer L MacGregor

- Introduction to Laser Resurfacing 52
- Resurfacing Lasers: Evolution and Mechanism of Action 52
- Clinical Indications 54
- Patient Selection and Preparation 57
- Laser Safety and Operative Technique 58
- Postoperative Management 59
- Complications 59

8. Nonablative Fractional Resurfacing 65

Elizabeth R Geddes, Parisa Ravanfar, Paul M Friedman

- Patient Selection and Preprocedure Instructions 67
- Clinical Indications and Outcomes 68
- Rhytides 68
- Photoaging: Dyschromia, Lentigines, Skin Texture Resurfacing and Tightening 69
- Melasma 70
- Other Pigmentary and Vascular Disorders 71
- Scars: Acne Scarring, Hypopigmented, Hypertrophic, Burn, Surgical 71
- Striae Distensae/Rubra/Alba 73
- Benign Skin Neoplasms and Deposition Disorders 73
- Precancerous Lesions 74
- Granuloma Annulare 75
- Residual Hemangiomas 75
- Postprocedure Care and Complications 75
- What Lies Ahead: The Future of Fractional Photothermolysis 76

9. Ablative Fractional Resurfacing 80

Sara Risner-Rumohr, Parisa Ravanfar, Paul M Friedman

- Introduction to Ablative Laser Resurfacing 80
- Introduction to Fractional Laser Resurfacing 80
- Introduction to Ablative Fractional Laser Resurfacing 81
- Rhytides 85
- Photorejuvenation 86
- Scars 87
- Keratoses and Other Epidermal Lesions 89
- Other Indications 90
- Contraindications 90
- Novel Applications and Possibilities 91

10. Photodynamic Therapy 96

Jennifer Peterson, Ane Massaki, Mitchel P Goldman

- History 96
- Mechanism of Photodynamic Therapy 96
- Clinical Applications in General Dermatology 98
- Clinical Applications in Cosmetic Dermatology 127
- Practical Considerations in Photodynamic Therapy 134

11. Intense Pulsed Light **144**

Arisa E Ortiz, E Victor Ross

- Various Device Models and Device Modifications 146
- Pigmented Lesions 146
- Vascular Lesions 147
- Photorejuvenation 151
- Hair Removal 152
- Photodynamic Therapy 154
- Acne 155
- Other 155
- Complications 155
- What's New? 157

12. Noninvasive Skin Tightening and Body Contouring **161**

Andrew A Nelson, Mathew M Avram

- Determining Your Patient's Current Status and Treatment Goals 161
- Physical Treatment of Fat and Cellulite 162

13. Laser Treatment in Asians **170**

Henry Hin Lee Chan

- Laser for the Treatment of Congenital Pigmentary Conditions 170
- Laser and Light Sources for the Treatment of Acquired Pigmentary Conditions 174
- Laser and Intense Pulsed Light Treatment for Freckles and Lentigo 174
- Melasma 176
- Acquired Bilateral Nevus of Ota-Like Macules (ABNOM or Hori's Macules) 178
- Laser Treatment of Vascular Lesions in Asians 179
- Ablative, Nonablative and Fractional Skin Resurfacing 181

14. Lasers and Energy-Based Devices for the Consumer: The Future of Esthetic Energy-Based Devices **186**

Eric F Bernstein, Tobin C Island

- Overview of Office-Based Esthetic Lasers and Energy-Based Devices 187
- Devices Developed for Home Use 190
- Other Applications 201
- The Future 202

Index *207*

CHAPTER

4

Tattoos, Melasma and Dermal Pigment

Kelly Stankiewicz

INTRODUCTION

Removal of endogenous and exogenous pigment requires the selective destruction of cellular and subcellular targets. Knowledge of this process rapidly advanced after the introduction of the theory of selective photothermolysis in 1983. This theory predicted that lasers with extremely short pulse durations, like Q-switched (QS) lasers with pulse durations in the nanosecond domain, were needed for the destruction of very small targets, like cells, melanosomes and pigment particles, without collateral damage. This advanced the treatment for many pigmented lesions and tattoos tremendously, giving an important option outside of destruction and scar formation.

The principles for the removal of tattoos and dermal pigment are quite similar, from selection of wavelength and pulse duration, to clinical endpoints and complications.

TATTOO REMOVAL

The art of body tattooing is ancient. It has transcended time periods and civilizations to become a prominent fixture in today's society. The most astounding confirmation of ancient tattooing was the discovery of a five thousand years old bronze age mummy found frozen in the Alps with thirty-nine well-preserved tattoos. Tattooing tools and instruments have been found that date back even further than that—from 38,000 to 10,000 BC.[1] Today, one quarter of the US population between the ages of 18 and 50 has a tattoo, with this number trending upward.[2] For some, permanent tattooing comes with regret. One fifth of tattoo owners are dissatisfied and have considered removal. So, with the increase in placement of tattoos comes the inevitable increase in removal. The most common reasons for tattoo removal are compelling and include the following: embarrassment, feelings of shame or that the tattoo represents a stigma, inability to hide the tattoo with clothing when needed, negative impressions of the tattoo in the workplace or a desire to find a new career or job.[3]

Tattoo removal began as a nonselective and destructive procedure, which aimed to replace the tattoo with scar. Techniques like excision, dermabrasion, salabrasion and CO_2 laser resurfacing were the only options for those who wanted to rid their body of tattoo art. The first treatment of a tattoo with a Q-switched (QS) laser was in the late 1960s, before the physics of laser–skin interactions were truly understood.[4] It was not until after the introduction of the theory of selective photothermolysis in 1983 that the selective removal of tattoos with laser progressed. The theory predicted that lasers with extremely short pulse durations were needed for the selective destruction of tattoo particles without collateral damage. Q-switched lasers with pulse durations in the nanosecond domain were found to successfully treat tattoos without scarring. The widespread use of QS lasers for tattoo removal began in the early 1990s. More than 20 years later, the same techniques are used, but increasing interest in improving tattoo removal has sparked recent advancements.

Laser Principles

Tattoos are exogenous pigment particles found intracellularly within fibroblasts and macrophages distributed perivascularly in the dermis (Fig. 4.1).[5] The particle size ranges from 2 nm to 400 nm with smaller particles grouped into larger membrane-bound granules measuring 0.5–4.0 μm.[5] Selective destruction and elimination of tattoo particles largely depends on two parameters: (1) laser wavelength, which should match the maximum absorption of the tattoo particle, and (2) pulse duration, which is optimized based on the target size. Absorption of laser energy by tattoo particles destroys pigment-containing cells and fragments the tattoo particles. This is accomplished through photomechanical effects, including cavitation, which is the evaporation of water leading to steam bubbles, and shock or acoustic waves, which result from thermal expansion caused by sudden heating. After the laser pulse, the tattoo particles are found extracellularly or within damaged cells, and many of the particles have an altered appearance.[5] Shortly after treatment, an inflammatory infiltrate is seen and the pigment particles are repackaged within phagocytes. The exact mechanism of tattoo lightening is unknown. It is proposed that a combination of phagocytosis and transport of pigment-laden cells, transepidermal elimination, and alteration of the tattoo particle into smaller and less dense fragments, account for tattoo lightening.

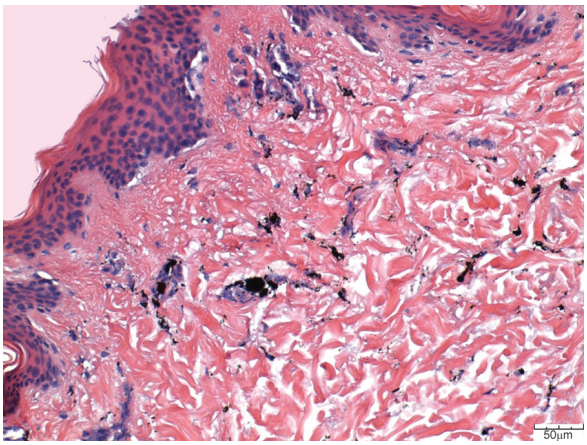

Fig. 4.1: Histologic image of a tattoo showing pigment particles within fibroblasts and macrophages distributed perivascularly within the dermis

Photo Courtesy: H Ray Jalian

Wavelength Selection

Commercially available QS lasers for tattoo removal are the ruby laser (694 nm), alexandrite laser (755 nm), and the Nd:YAG laser (532 nm, 1064 nm). The appropriate wavelength is chosen based on the predicted maximum absorption of tattoo particle, which is dictated by tattoo color. When determining the wavelength of maximum absorption, it is helpful to think of the color wheel, which places complementary colors across from one another. A color absorbs maximally at the wavelength of its complimentary color (Fig. 4.2). For instance, red tattoos absorb green light (450–560 nm) maximally, making the frequency double Nd:YAG (532 nm) the laser of choice. Black ink absorbs all wavelengths of light, making it the easiest color to remove. Orange and yellow absorb at the shortest wavelengths of visible light (400–480 nm) which do not correspond to a commercially available laser, making these tattoo colors the most difficult to remove (Table 4.1).

When selecting wavelength, it is also important to consider skin phototype. Melanin is a chromophore absorbed by all available tattoo lasers. Absorption decreases with increased wavelength (Fig. 4.3) Darker skin types should be treated with longer wavelengths, like the 1064 nm Nd:YAG laser, which has the lowest melanin absorption.

Pulse Duration Selection

According to the theory of selective photothermolysis, a target can be selectively destroyed without collateral

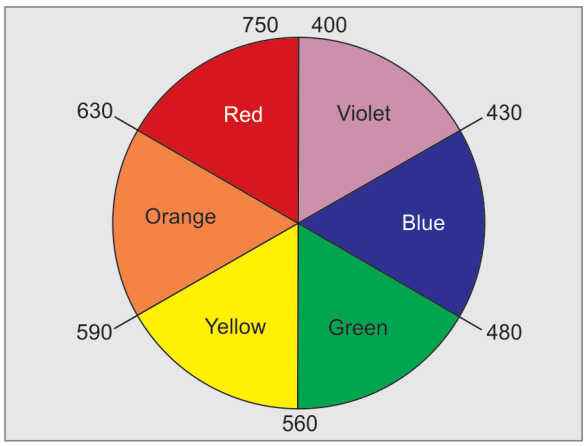

Fig. 4.2: The color wheel. A color absorbs maximally at the wavelength of its complimentary color. The selected wavelength should match the wavelength of complimentary color as closely as possible. Some colors are more difficult to remove because there is no commercially available laser matching the wavelength of maximum absorption

Table 4.1: Ink color and wavelength selection

Ink Color	*Ink Composition*	*Measured Max. Absorption*[53]	*Laser Selection*	*Treatment Notes*
Red	• Mercury sulfide (cinnabar) • Cadmium selenide (cadmium red) • Sienna (red ochre, ferric hydrate and ferric sulfate) • Azo dyes • Hematite (ferric oxide)	500–570 nm	532 nm	Most likely to cause adverse inflammatory reactions
Orange	• Azo dyes • Cadmium seleno-sulfide	420–540 nm	532 nm	
Yellow	• Cadmium sulfide • Ochre • Curcumin yellow • Azo dyes • Limonite • Anthraquinone	470–485 nm	532 nm	
Green	• Chromium oxide (casalis green) • Hydrated chromium sesquioxide (guignet green) • Malachite green • Lead chromate • Ferro-ferric cyanide • Curcumin green • Phthalocyanine dyes (copper salts with yellow coal tar dyes)	570–800 nm	694 nm 755 nm	
Blue	• Cobalt aluminate (azure blue) • Phthalocyanine • Ferric ferocyanide • Indigoid	590–770 nm	630 nm 694 nm 755 nm	
Violet	• Manganese violet • Indigoid	500–570 nm	532 nm 630 nm	
Black	• Amateur: carbon (soot) or India ink • Professional: iron oxide, carbon or logwood extract	600–800 nm	694 nm 755 nm 1064 nm	
Brown	• Ochre	410–550 nm	532 nm 694 nm 755 nm 1064 nm	Immediate ink darkening
White	• Titanium dioxide • Zinc oxide	790 nm	532 nm 755 nm	Immediate ink darkening
Flesh	• Iron oxides	None	532 nm	Immediate ink darkening

damage when the pulse duration of the laser is less than or equal to the thermal relaxation time of the target. The thermal relaxation time is approximately equal to the squared diameter of the target. Given that tattoo particle size ranges from 2 nm to 400 nm, with 40 nm being the most commonly found size,

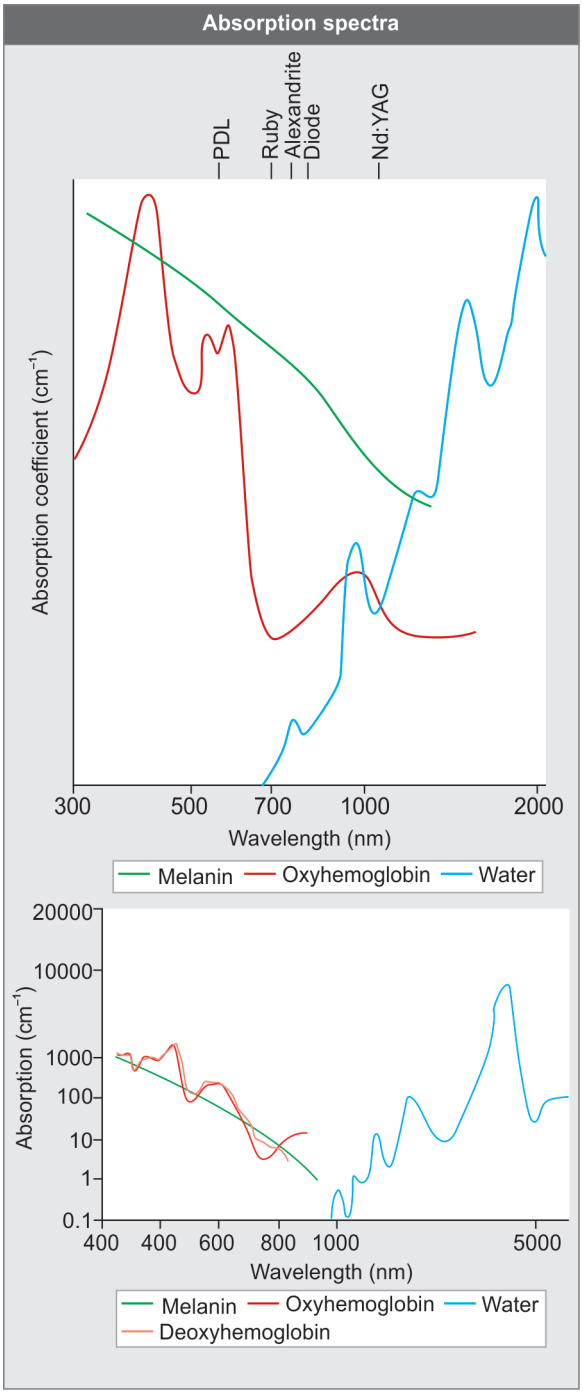

Fig. 4.3: Melanin absorption curve

and granules range from 0.5 µm to 4.0 µm, the ideal pulse duration for destruction of tattoo pigments is in the nanosecond and picosecond domains. Today, the gold standard for tattoo removal is once monthly treatments with QS lasers, which have pulse durations in the nanosecond domain, at wavelengths appropriate for the color of the tattoo and the patient's skin phototype. Picosecond pulse durations may actually be more ideally matched for tattoo removal, especially given the 40 nm particle size most commonly found in professional tattoos. Recent studies have indeed shown greater lightening with picosecond pulse durations when compared to nanosecond pulse durations.[6]

Alternative Treatments

In addition to QS lasers, tattoo removal can be achieved with fractional resurfacing lasers. Fractional lasers destroy a small microcolumn of skin taking the laser ink held within it. When destroying 25% of skin, you can also vaporize 25% of tattoo ink. The concomitant use of QS lasers and fractional lasers in a sequential fashion has been shown to increase patient tolerance for tattoo removal and it may have the potential for enhanced tattoo lightening.[7] Additionally, removal of tattoo by fractional resurfacing is a colorblind process and may be used for cases of resistant ink. Lastly, fractional lasers are a safer option than QS lasers for the removal of allergic tattoos. In one case series, multiple treatments with fractional laser significantly lightened allergic tattoos.[8]

Clinical Principles/Consultation

Tattoo Types

Tattoos can be categorized into several subtypes: professional, amateur, cosmetic, traumatic and medical.

Professional tattoos are exogenous pigment particles placed in the dermis with the moving needle of a tattoo machine. The ink of a professional tattoo is placed at a precise and consistent depth, which has shown to be at the junction of the papillary and reticular dermis extending to the mid-dermis.[5] Professional tattoos are created in an increasing range of colors, many of which are very difficult to treat with commercially available lasers. Cosmetic tattooing, or permanent makeup, is another form of professional tattoo that is becoming increasingly popular. Color can be placed in areas where makeup is ordinarily used, like eyebrows, eyeliner, lip liner, lipstick and blush.

Amateur tattoos are comprised of pigment particles more haphazardly placed with make-shift devices, like handheld needles. The pigment particles in an amateur tattoo can be found extending from the papillary

dermis to the subcutaneous fat.[5] The size and shape of amateur tattoo pigment granules are more heterogeneous than those of professional tattoos.[5]

Traumatic tattoos are caused by the inadvertent deposition of pigment from foreign material, such as asphalt or graphite, into the skin. These tattoos are usually easily treated. Tattoos from explosives, like, firework debris or gunpowder should be treated cautiously as laser removal can cause combustion and pock-like scarring.[9]

Medical tattoos are most conventionally placed to mark the sites of radiation. These tattoos are best left in place and should not be removed without the consent of the treating oncologist. An increasing trend is patient imposed medical tattoos warning of medical conditions and even "do not resuscitate" orders. These tattoos are not currently advocated by physicians, but are patient directed. Additionally, flesh-colored tattoos are used to simulate the areola in breast reconstruction surgery or to camouflage scars.

Tattoo Color

The Food and Drug Administration (FDA) considers tattoo pigment to be under its jurisdiction, but admits it has not exercised its authority in this regard.[10] As such, the exact content of tattoo ink is often unknown or kept as a trade secret. Tattoo ink is pigment suspended in a carrier fluid. Most modern day tattoo pigments are made from inorganic compounds such as metal salts, metal oxides and minerals, or synthetic organic pigments such as azo dyes, phthalocyanine and anthraquinone.[11] Common carrier fluids include witch hazel, purified water, ethanol, glycerol and propylene glycol. Carrier fluids not only suspend ink for even placement into the skin, but also act as preservatives to prevent the growth of pathogens in the tattoo ink.

The pigment for amateur black tattoos is usually carbon (soot) or India ink. Professional black tattoos are made from iron oxide, carbon or logwood extract. Red pigment is traditionally mercury sulfide (cinnabar) or cadmium selenide (cadmium red). Due to toxicity, these are no longer used.[11] Alternative red inks include organic dyes (azo dyes) and hematite (ferric oxide). Red inks of all types are most likely to cause adverse inflammatory reactions. White pigment is usually made from titanium dioxide or zinc oxide. Reduction of white tattoo pigment after an initial tattoo removal treatment can cause darkening of the ink (see Table 4.1).

As an alternative to traditional inks, a removable tattoo ink was developed which can be successfully and completely removed with very few laser treatments. The inks are safe and bioremovable substances encased in polymethylmethacrylate beads with gold nanoparticles. When treated with a QS laser, the beads rupture and the ink is solubilized. Unlike traditional tattoo inks, this ink has been specifically tested for its safety and efficacy.

Contraindications

Past history of parenteral gold therapy is an absolute contraindication for treatment with a QS laser. Several case reports describe laser-induced chrysiasis creating a disfiguring hyperpigmentation.[12-14] In one case, electron microscopy demonstrated a structural change in the dermal gold deposits after treatment with a QS Ruby laser.[14] At the minimum, test spots should be done on patients with a history of gold therapy prior to treatment.

Treatment of allergic tattoos with the QS laser is a relative contraindication due to reports of systemic hypersensitivity reactions, including anaphylaxis.[1] Treatment with ablative fractional lasers may be a feasible alternative.[8]

Care should be taken when treating patients with a history of multiple sclerosis. The exact mechanism responsible for tattoo removal is not entirely known, but travel of ink and foreign material through the lymph system is likely involved. Rarely, healthy patients can experience flu-like symptoms with enlarged lymph nodes. Flaring of multiple sclerosis has been seen after tattoo removal treatment. (This has been the author's experience).

Vitiligo, or any koebnerizing dermatosis, can be precipitated by treatment with laser. In the context of tattoo removal, permanent hypopigmentation can be created in patients with vitiligo. Patients should be questioned about history or family history of vitiligo and counseled appropriately.

Treatment Details

Anesthesia

Tattoo removal is painful and anesthesia may be required for patient comfort. Topical anesthesia

or local injection in the form of a ring block is the standard. Injection of anesthesia directly under the tattoo may rarely result in bleeding of ink beyond the tattoo boundary after treatment with Q-switched lasers.

Endpoint

The clinical endpoint for tattoo removal is immediate skin whitening. This corresponds to the cavitation reaction seen within pigment-laden cells. Cavitation is the formation of steam bubbles due to the evaporation of water. Pinpoint bleeding follows immediate whitening after treatment with the frequency doubled Nd:YAG (532 nm). Obvious tissue splatter or epidermal disruption is a reaction beyond the desired endpoint and indicates that the fluence should be decreased. Some advocate the use of a clear hydrogel dressing applied to the tattoo prior to treatment to prevent any aerosolized blood or tissue from reaching the treating physician. A loud snapping or sparking sound may indicate that makeup or sunscreen is overlying the tattoo on the skin. This is the sound of plasma formation with QS treatment of titanium dioxide or zinc oxide on the surface of the skin. This is not a harmful reaction, but indicates that the laser energy may not be reaching the tattoo. The skin should be cleaned thoroughly to remove any makeup or sunscreen.

Post-treatment Care

Approximately 15 minutes after treatment, tattoos no longer appear white. They can look purpuric or have pinpoint bleeding. Tattoos will crust for a week to two after the treatment. Post-treatment blistering is common and can be significant.

After treatment, tattoos require specific care. The treatment sites should be covered with petrolatum ointment and telfa bandage. This dressing should be changed daily. Friction to the treated area should be strictly avoided. Friction or repeated removal of crust with the bandage can lead to scarring. The patients should be instructed to avoid sunlight after treatment, as well as prior to treatment.

Number of Treatments Needed

Tattoo removal requires a series of treatments ideally spaced 4–8 weeks apart. Total and complete removal of ink is rare. An average of 4–6 treatments is reported for amateur tattoos and 6–10 treatments for professional tattoos.[15] Although, treatment numbers in excess of 20 are not unusual. As the tattoo fades, it usually fades unevenly with some portions of the tattoo fading faster. The rate of clearance depends on ink color and amount of ink placed by the tattoo artist. Higher color density has been associated with slower response to treatment. Other factors associated with slower clinical response include patients who smoke, colors other than red or black, large tattoos, and tattoos on the lower extremity.[16]

Treatment Complications

Post-treatment blistering occurs frequently, especially after the first treatment sessions. These correspond to subepidermal blisters seen on microscopic examination of skin after treatment with Q-switched lasers.[5] Patients should be instructed not to open or rub the blisters.

Pigmentary alterations are often seen with tattoo removal, especially with QSRL and QS 532 nm, which are more likely to cause temporary or permanent hypopigmentation. Hyperpigmentation can be treated with hydroquinone between treatment sessions.

White and flesh-colored tattoos as well as many cosmetic tattoos in red and brown may turn immediately black or gray upon treatment. It is possible to remove the darkened ink with continued treatments, but it may be more difficult than treating a standard black tattoo.[1,16] Reduction of titanium dioxide and iron oxides are responsible for this color change.[11] Patients with cosmetic, flesh-colored or white tattoos should be counseled on the risk of tattoo darkening and the possibility that the darkened ink may not be removed. White pigment may be present in lighter colored inks, as well, like pink or light blue (Figs 4.4A to C and 4.5A and B). Tattoo artists placing cosmetic tattoos may layer ink colors to achieve the desired color effect. It may be possible to fade more easy to treat colors like black, and leave behind more difficult to treat colors like orange (Figs 4.6 A and B).

Scarring is a potential complication from tattoo removal. The risk of scarring is increased with the use of higher fluences of the QS laser, with tanned skin, and with inappropriate postprocedure care. Lasers with millisecond pulse durations and intense pulsed light devices are not appropriate treatment



Figs 4.4A to C: Before, during and after treatment of lip liner tattoo showing darkening of ink after one treatment with Q-switched ruby laser and complete removal with one session of repeat treatments

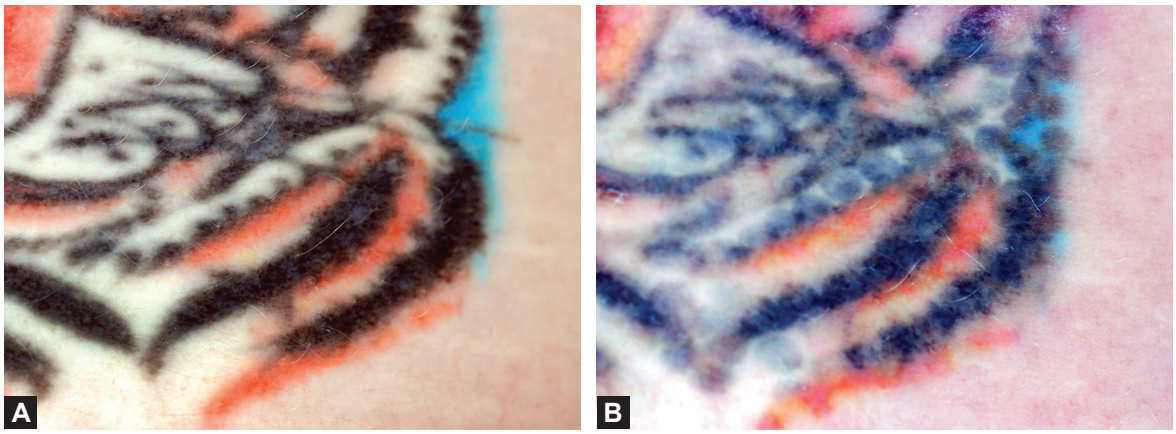

Figs 4.5A and B: Before and after. Darkening of white ink and light blue ink with one treatment with Q-switched alexandrite laser



Figs 4.6A and B: Before and after. Cosmetic eyebrow tattoo treated with Q-switched ruby laser. Black ink was successfully treated revealing orange ink that is difficult to treat

options for tattoo removal due to the high potential for scarring.

Immediate and delayed hypersensitivity reactions, both local and systemic, have been reported with tattoo removal.[1,17,18] In one case report, treatment with a QS laser caused a localized urticaria, which was suppressed in subsequent treatments with prophylactic antihistamines and corticosteroids.[17] Tattoo removal treatment can rarely cause flu-like symptoms with fever and enlarged lymph nodes.

Future Directions in Tattoo Removal

Of those with tattoos, an unfortunate 17–20% are dissatisfied enough to consider removal, yet only 0–6% actually seek removal.[2,3] This discrepancy suggests that a widespread need for tattoo removal is not being met.[19] Lack of efficiency in current tattoo removal techniques is likely a major contributing

factor. Although relatively effective, modern tattoo removal techniques using once monthly treatment with QS lasers are not necessarily efficient. Numerous treatments are required and complete removal of ink is usually rare, making the process time-consuming, expensive and, sometimes, disappointing. Illustrating this point, one laser center published data showing a very low rate, 1.26%, of complete tattoo clearance and cited patient compliance as a major reason.[20] On average, patients only returned for half the predicted number of treatments required, with authors postulating that patient discouragement, pain and high cost of treatments were responsible. In light of these facts, the need for enhanced tattoo removal techniques is apparent.

Since the advent of the use of QS lasers for tattoo removal approximately 25 years ago, very few advances have been made until recently. Lasers with picosecond-domain pulse durations and combination treatments have shown promising improvement in tattoo removal. According to the theory of selective photothermolysis, the laser destruction of a target is optimized when the pulse duration of the laser is matched to the thermal relaxation time of the light-absorbing targets. For the majority of tattoo particles, the optimal pulse duration is predicted to be in the picosecond domain. Studies showing improvement in tattoo removal with lasers emitting picosecond-domain pulses have been recently published.[21-23]

Combining treatments of the QS laser with either repeated QS treatments or fractional resurfacing treatments has also shown some promise. One study showed a marked improvement in tattoo clearance by repeating treatments with the QS laser on a single tattoo in the same day.[24] In this technique, the immediate whitening was allowed to resolve and the tattoo was treated again. The length of time between treatments was 20 minutes. Sixty-one percent of tattoos were completely removed in one treatment session. These extraordinary results have not yet been duplicated. Repeat treatments with the QS laser may have the most utility in treating inks displaying immediate ink darkening, like white, flesh-colored or cosmetic tattoos (Figs 4.4A to C). Combining the QS laser treatments with fractional resurfacing lasers improves treatment tolerability and may enhance tattoo clearance.[7]

DERMAL PIGMENT

Melasma

Melasma is a pigmentary disorder with an incompletely understood pathogenesis that disproportionately affects women of childbearing age, mostly with darker skin phototypes. However, patients of both sexes and all races and ages can be affected. Classically, melasma can involve the epidermis, dermis or both. Epidermal melasma appears as an ill-defined light brown patch that is accentuated by the Wood's lamp. Dermal melasma may appear more blue-gray due to the Tyndall effect and is not enhanced by the Wood's lamp. Patches appear on face and rarely the arms. Melasma corresponds histologically to enlarged melanocytes within the epidermis with prominent dendritic processes, an increase in melanin containing keratinocytes, and melanophages in the dermis.[25]

Ultraviolet light and hormonal changes are the factors most commonly implicated in melasma. Photosensitizing medications and thyroid or ovarian dysfunction have also been associated. The standards for treatment of melasma include strict sun protection, topical therapies like hydroquinone (HQ), retinoids, and combination formulas (hydroquinone, retinoid and corticosteroid combinations), as well chemical peels and microdermabrasion. Lasers and light therapies have not been the mainstay of treatment for melasma due to high incidence of recurrence and the risk for worsening of pigmentation. Ablative fractional lasers, nonablative fractional lasers, QS lasers and intense pulsed light (IPL) have all been used with varying results.

Treatment Principles

Fractional Lasers

Both ablative and nonablative fractional lasers have been used to treat melasma, with nonablative fractional treatments increasing in popularity. The FDA has approved fractional resurfacing for melasma. The mechanism of action appears to be the destruction of melanocytes and elimination of melanin through the epidermis within the microscopic treatment zones (MTZ).[25,26] Additionally, fractional lasers may serve to increase drug delivery of topical melasma treatments. A study comparing topical combination therapy (HQ, retinoic acid

0.1%, dexamethasone 0.1%) and fractional CO_2 laser treatment for melasma showed a greater improvement in the group treated with the fractional CO_2 laser together with topical combination therapy than either treatment alone.[27] Nonablative fractional laser treatments (either 1550, 1540 or 1927 nm devices) have been shown to improve melasma both with and without topical adjuncts, but the improvement is often not sustainable with recurrence at or before 6 months.[28-32] The rate of post-inflammatory hyperpigmentation and worsening of melasma with nonablative fractional treatments has been reported in some studies to be relatively high, at 28–31% of patients.[33,34] Yet another study showed identical improvement in melasma between the nonablative fractional treatment group and the group using sunscreen as monotherapy.[35] Given the potential for no improvement, the high risk for worsening pigmentation and a nonsustainable result, nonablative fractional therapy is best reserved for those with refractory melasma desiring short-term improvement.

QS Laser

QS lasers are capable of selectively destroying pigment-laden keratinocytes and melanophages and have been used as treatment for melasma. QS neodymium-doped yttrium aluminum garnet (Nd:YAG) laser at low fluences has been most frequently reported to improve melasma.[36-44] Lower fluence QS Nd:YAG laser treatments have demonstrated superiority over higher fluence treatments.[45] Mottled hypopigmentation or punctate leukoderma is a concerning potential side effect.[46] One promising treatment regimen combines low fluence, single pass treatment of QS Nd:YAG laser with microdermabrasion and a topical regimen of HQ and tretinoin. More than 80% of patients achieved greater than 75% improvement in their melasma and this improvement was sustained for up to 12 months.[47] Further studies are being done to evaluate this combination therapy.

Intense Pulsed Light

Treatment of melasma with intense pulsed light (IPL) has been reported to be successful, but has the same limitations as other laser treatments for melasma.[48-50] Recurrence and post-inflammatory hyperpigmentation complicate the treatments making IPL best for those expecting temporary improvement of melasma refractory to medical treatments.

NEVUS OF OTA AND OTHER DERMAL MELANOCYTOSES

Dermal melanocytosis includes Nevus of Ota, Nevus of Ito, acquired bilateral nevus of Ota-like macules (ABNOM), and congenital dermal melanocytosis. Nevus of Ota is a blue-gray patch consisting of coalescing macules present unilaterally on the face in the distribution of the first and second trigeminal nerve. The lesion often extends onto the sclera and can involve other structures in the eye. They are more commonly seen in those of Asian or African descent but can be found in Caucasian skin types as well. Nevus of Ota is present in 0.2–0.8% of all dermatology patients in Japan.[51] Nevus of Ota typically presents either within the first year of life or around puberty. Histologically, there are spindle-shaped dermal melanocytes distributed throughout the dermis between collagen bundles. The melanocytes can be seen around blood vessels and skin appendages as well. Nevus of Ito is a lesion identical in appearance and histology to Nevus of Ota but is seen on the posterior shoulder and scapular area. Acquired bilateral nevus of Ota-like macules (ABNOM) (Hori's macules) are another entity similar to Nevus of Ota. ABNOM are gray-brown to blue-gray macules with a bilateral distribution present on the zygomatic cheeks, mostly in Asian women. The age of onset is greater than Nevus of Ota and the eye is not involved. Histologically, ABNOM consists of spindle-shaped melanocytes that are concentrated in the upper dermis and more often around blood vessels when compared to Nevus of Ota.[52] Lastly, dermal melanocytosis is a congenital blue patch most often seen on the lumbosacral area and buttocks. Rarely, it can be found elsewhere on the body. Lesions typically regress in childhood.

Given location and persistence, Nevus of Ota and ABNOM present the greatest concern to patients, but all dermal melanocytosis can be treated with QS lasers.

Treatment Principles

The pulse duration of QS lasers is optimal for selective destruction of melanocytes making them the ideal

tool for treatment of dermal melanocytoses. Nevus of Ota and ABNOM have been successfully treated with the QS ruby laser, QS alexandrite laser, and QS Nd:YAG laser, with ABNOM being more difficult to remove. Local anesthesia may be required and could include nerve blocks or topical anesthesia. The laser–skin interaction is similar to tattoo removal. Immediate whitening, followed by erythema and edema is seen. The average number of treatments needed for removal is 4–8. A significant amount of postinflammatory hyperpigmentation (PIH) can be seen with treatment and usually fades within months. For reasons unknown, treatment of ABNOM results in PIH more often than Nevus of Ota.[52] Postinflammatory hyperpigmentation appears weeks after treatment as a nonmottled hyperpigmentation. Expectations should be set prior to the treatment of ABNOM because treatment may result in more pigmentation than present at baseline.

REFERENCES

1. Bernstein EF. Laser tattoo removal. Semin Plast Surg. 2007;21(3):175-92.
2. Laumann A, Derick A. Tattoos and body piercings in the United States: A national data set. Journal of the American Academy of Dermatology. 2006; 55(3):413-21.
3. Armstrong ML, et al. Motivation for contemporary tattoo removal: a shift in identity. Arch Dermatol. 2008;144(7):879-84.
4. Kent KM,Graber EM. Laser tattoo removal: a review. Dermatol Surg. 2012; 38(1):1-13.
5. Taylor CR, Anderson RR, Gange RW, et al. Light and electron microscopic analysis of tattoos treated by Q-switched ruby laser. J Invest Dermatol. 1991; 97(1):131-6.
6. Izikson L, et al. Safety and effectiveness of black tattoo clearance in a pig model after a single treatment with a novel 758 nm 500 picosecond laser: a pilot study. Lasers Surg Med. 2010;42(7):640-6.
7. Weiss ET, Geronemus RG. Combining fractional resurfacing and Q-switched ruby laser for tattoo removal. Dermatol Surg. 2011;37(1):97-9.
8. Ibrahimi OA, et al. Treatment of tattoo allergy with ablative fractional resurfacing: a novel paradigm for tattoo removal. J Am Acad Dermatol. 2011; 64(6):1111-4.
9. Taylor CR. Laser ignition of traumatically embedded firework debris. Lasers Surg Med.1998;22(3):157-8.
10. Tattoos and Permanent Makeup. 2012 [cited 2012 07/08]; Available from: http://www.fda.gov/cosmetics/productandingredientsafety/productinformation/ucm108530.htm.
11. Ortiz AE, Alster TS. Rising concern over cosmetic tattoos. Dermatol Surg. 2012;38(3):424-9.
12. Almoallim H, et al. Laser induced chrysiasis: disfiguring hyperpigmentation following Q-switched laser therapy in a woman previously treated with gold. J Rheumatol. 2006;33(3):620-1.
13. Geist DE, Phillips TJ. Development of chrysiasis after Q-switched ruby laser treatment of solar lentigines. J Am Acad Dermatol. 2006;55(2 Suppl):S59-60.
14. Trotter MJ, et al. Localized chrysiasis induced by laser therapy. Arch Dermatol. 1995;131(12):1411-4.
15. Jow T, Brown A, Goldberg DJ. Patient compliance as a major determinant of laser tattoo removal success rates: a 10-year retrospective study. J Cosmet Laser Ther. 2010;12(4):166-9.
16. Bencini PL, et al. Removal of tattoos by Q-switched laser: variables influencing outcome and sequelae in a large cohort of treated patients. Arch Dermatol. 2012;148(12):1364-9.
17. England RW, Vogel P, Hagan L. Immediate cutaneous hypersensitivity after treatment of tattoo with Nd:YAG laser: a case report and review of the literature. Ann Allergy Asthma Immunol. 2002;89(2): 215-7.
18. Ashinoff R, Levine VJ, Soter NA. Allergic reactions to tattoo pigment after laser treatment. Dermatol Surg. 1995;21(4):291-4.
19. Anderson R. Commentary: Tattoos and body piercing. Journal of the American Academy of Dermatology. 2006;55(3):422.
20. Jow T, Brown A, Goldberg DJ. Patient compliance as a major determinant of laser tattoo removal success rates: a 10-year retrospective study. J Cosmet Laser Ther. 2010;12(4):166-9.
21. Izikson L, et al. Safety and effectiveness of black tattoo clearance in a pig model after a single treatment with a novel 758 nm 500 picosecond laser: a pilot study. Lasers in Surgery and Medicine. 2010;42(7):640-6.
22. Ross V, et al. Comparison of responses of tattoos to picosecond and nanosecond Q-switched neodymium: YAG lasers. Arch Dermatol. 1998;134(2): 167-71.
23. Brauer JA, et al. Successful and rapid treatment of blue and green tattoo pigment with a novel picosecond laser. Arch Dermatol. 2012;148(7):820-3.
24. Kossida T, et al. Optimal tattoo removal in a single laser session based on the method of repeated exposures. J Am Acad Dermatol. 2012;66(2):271-7.
25. Goldberg DJ, Berlin AL, Phelps R. Histologic and ultrastructural analysis of melasma after fractional resurfacing. Lasers Surg Med. 2008;40(2):134-8.
26. Hantash BM, et al. Laser-induced transepidermal elimination of dermal content by fractional photothermolysis. J Biomed Opt. 2006;11(4):041115.

27. Trelles MA, Velez M, Gold MH. The treatment of melasma with topical creams alone, CO_2 fractional ablative resurfacing alone, or a combination of the two: a comparative study. J Drugs Dermatol. 2010;9(4):315-22.
28. Lee HS, et al. Treatment of melasma in Asian skin using a fractional 1,550-nm laser: an open clinical study. Dermatol Surg. 2009;35(10):1499-504.
29. Katz TM, et al. Treatment of melasma using fractional photothermolysis: a report of eight cases with long-term follow-up. Dermatol Surg. 2010;36(8): 1273-80.
30. Kroon MW, et al. Nonablative 1550-nm fractional laser therapy versus triple topical therapy for the treatment of melasma: a randomized controlled pilot study. J Am Acad Dermatol. 2011;64(3):516-23.
31. Tourlaki A, et al. Combination of fractional erbium-glass laser and topical therapy in melasma resistant to triple-combination cream. J Dermatolog Treat; 2012.
32. Rokhsar CK, Fitzpatrick RE. The treatment of melasma with fractional photothermolysis: a pilot study. Dermatol Surg. 2005;31(12):1645-50.
33. Hong SP, et al. Split-face comparative study of 1550 nm fractional photothermolysis and trichloroacetic acid 15% chemical peeling for facial melasma in Asian skin. J Cosmet Laser Ther. 2012;14(2):81-6.
34. Wind BS, et al. Non-ablative 1,550 nm fractional laser therapy versus triple topical therapy for the treatment of melasma: a randomized controlled split-face study. Lasers Surg Med. 2010;42(7):607-12.
35. Karsai S, et al. Is non-ablative 1550-nm fractional photothermolysis an effective modality to treat melasma? Results from a prospective controlled single-blinded trial in 51 patients. J Eur Acad Dermatol Venereol. 2012; 26(4):470-6.
36. Cho SB, Kim JS, Kim MJ. Melasma treatment in Korean women using a 1064-nm Q-switched Nd:YAG laser with low pulse energy. Clin Exp Dermatol. 2009;34(8):e847-50.
37. Wang HW ,Liu KY. Efficacy and safety of low-energy QS Nd:YAG and QS alexandrite laser for melasma. Zhongguo Yi Xue Ke Xue Yuan Xue Bao. 2009; 31(1):45-7.
38. Choi M, et al. Low-dose 1064-nm Q-switched Nd:YAG laser for the treatment of melasma. J Dermatolog Treat. 2010;21(4):224-8.
39. Polnikorn N. Treatment of refractory melasma with the MedLite C6 Q-switched Nd:YAG laser and alpha arbutin: a prospective study. J Cosmet Laser Ther. 2010;12(3):126-31.
40. Wattanakrai P, Mornchan R, Eimpunth S. Low-fluence Q-switched neodymium-doped yttrium aluminum garnet (1,064 nm) laser for the treatment of facial melasma in Asians. Dermatol Surg. 2010;36(1):76-87.
41. Brown AS, Hussain M, Goldberg DJ. Treatment of melasma with low fluence, large spot size, 1064-nm Q-switched neodymium-doped yttrium aluminum garnet (Nd:YAG) laser for the treatment of melasma in Fitzpatrick skin types II-IV. J Cosmet Laser Ther. 2011;13(6):280-2.
42. Park KY, et al. A randomized, observer-blinded, comparison of combined 1064-nm Q-switched neodymium-doped yttrium-aluminium-garnet laser plus 30% glycolic acid peel vs. laser monotherapy to treat melasma. Clin Exp Dermatol. 2011;36(8):864-70.
43. Suh KS, et al. Efficacy of the 1064-nm Q-switched Nd:YAG laser in melasma. J Dermatolog Treat. 2011; 22(4):233-8.
44. Zhou X, et al. Efficacy and safety of Q-switched 1,064-nm neodymium-doped yttrium aluminum garnet laser treatment of melasma. Dermatol Surg. 2011; 37(7):962-70.
45. Kar HK, Gupta L, Chauhan A. A comparative study on efficacy of high and low fluence Q-switched Nd:YAG laser and glycolic acid peel in melasma. Indian J Dermatol Venereol Leprol. 2012;78(2): 165-71.
46. Chan NP, et al. A case series of facial depigmentation associated with low fluence Q-switched 1,064 nm Nd:YAG laser for skin rejuvenation and melasma. Lasers Surg Med. 2010;42(8):712-9.
47. Kauvar AN. Successful treatment of melasma using a combination of microdermabrasion and Q-switched Nd:YAG lasers. Lasers Surg Med. 2012; 44(2):117-24.
48. Li YH, et al. Efficacy and safety of intense pulsed light in treatment of melasma in Chinese patients. Dermatol Surg. 2008;34(5):693-700; discussion 700-1.
49. Zoccali G, et al. Melasma treated with intense pulsed light. Aesthetic Plast Surg. 2010;34(4):486-93.
50. Wang CC, et al. Intense pulsed light for the treatment of refractory melasma in Asian persons. Dermatol Surg. 2004;30(9):1196-200.
51. Taylor CR, et al. Treatment of nevus of Ota by Q-switched ruby laser. J Am Acad Dermatol. 1994; 30(5 Pt 1):743-51.
52. Lee B, Kim YC, Kang WH, et al. Comparison of characteristics of acquired bilateral nevus of Ota-like macules and nevus of Ota according to therapeutic outcome. J Korean Med Sci. 2004;19(4):554-9.
53. Beute TC, et al. In vitro spectral analysis of tattoo pigments. Dermatol Surg. 2008;34(4):508-15; discussion 515-6.

or detailed information of dermatology books, visit our website www.jaypeebrothers.com, for detailed information of dermatology books, visit our websi

LASER & LIGHT SOURCE TREATMENTS FOR THE SKIN

Salient Features

- This book is an in-depth guide to the safe and effective practice of dermatologic laser surgery.
- Provides an excellent, comprehensive and practical overview of the field of laser, light source and other energy–based treatments within the field of dermatology.
- Written and edited by internationally renowned experts in the field of dermatology.
- Contains many full-color clinical photographs and practical points.
- Covers new technique such as noninvasive fat reduction, advances in fractional resurfacing and patient safety pearls.



Mathew M Avram MD, JD is the Director of the Massachusetts General Hospital Dermatology Laser and Cosmetic Center Massachusetts, USA. Dr Avram is an Assistant Professor of Dermatology at Harvard Medical School, where he is also Faculty Director for Procedural Training in the Department of Dermatology, Harvard Medical School. Dr Avram has also served as Co-Chair for an annual laser teaching session for the past four years for the Food and Drugs Administration in Silver Spring, Maryland. Dr Avram has also been elected to the Board of Trustees of the American Society for Dermatologic Surgery (ASDS). Dr Avram was the Program Co-Chair of the 2010 ASLMS annual meeting in Phoenix, Arizona. He now serves as Treasurer for THE American Society for Laser Medicine and Surgery (ASLMS), where he is also a member of Executive Committee. He has served as Co-Chair of the Cutaneous Laser Surgery Section of the ASLMS meeting in 2009 and 2011. He is co-author of the First and Second Editions of A Color Atlas of Cosmetic Dermatology published by McGraw-Hill (which have been translated into 5 languages and is an "I-phone app). He is a co-editor of Lasers and Lights a textbook published by Elsevier and has published multiple papers in each of the New England Journal of Medicine, the Journal of the American Academy of Dermatology, Lasers in Surgery and Medicine & Dermatologic Surgery as well as multiple chapters in leading dermatology textbooks. He is a co-director of the MGH/Wellman Laser and Cosmetic Fellowship. He is an affiliate faculty member of the Wellman Center for Photomedicine. He is an associate editor of the Journal of Cosmetic and Laser Therapy and serves as Secretary of the American Society of Cosmetic and Laser Surgery Advisory Board. He serves on the Editorial Boards of Archives of Dermatology, Lasers in Surgery and Medicine, Dermatologic Surgery and Lasers in Medical Science. Dr Avram is a frequent guest on the Dr Oz show, ABC, NBC, CBS, FOX and has appeared multiple times in the New York Times, Wall Street Journal, Washington Post, and numerous other media. Dr Avram has chaired 15 national meetings and has given over 250 invited lectures at national and international meetings. Dr Avram attended college at Princeton University, and completed his dermatology residency training at Harvard, where he served as Chief Resident. Subsequently, he completed his Mohs micrographic surgery, laser and cosmetics fellowship at UCLA.



Paul M Friedman MD, board-certified by the American Board of Dermatology, is the Director of Dermatology and Laser Surgery Center, Houston, Texas, USA and also practices at the Laser and Skin Surgery Center, New York, NY, USA. He was educated in dermatology at the New York University School of Medicine where he served as Chief Resident and was twice-awarded the prestigious Husik Prize for his research in dermatologic surgery. He completed a one-year fellowship in dermatologic laser surgery and Mohs micrographic surgery and cutaneous oncology at the Laser and Skin Surgery Center of New York and was the recipient of the Young Investigator's Writing Competition Award of the American Society for Dermatologic Surgery. Dr Friedman is a Clinical Assistant Professor at the University of Texas Medical School, Department of Dermatology, and a Clinical Assistant Professor of dermatology at the Weill Cornell Medical College, The Methodist Hospital. He is also on staff at Texas Children's Hospital and Memorial-Hermann Hospital-Texas Medical Center.

Dr Friedman has been a featured speaker of the American Academy of Dermatology, the American Society for Dermatologic Surgery, the American Society for Laser Medicine and Surgery, and other national and international audiences. He served as Co-Chair for the Cutaneous Laser Surgery Section of the 29th and 31st Annual Conferences of the ASLMS and will serve as program Co-Chair for the 35th ASLMS Annual Conference. He has served as Chair of the Public Service Committee for the American Society of Dermatologic Surgery. Dr Friedman has published over 75 medical articles and book chapters, and coauthored the book "Beautiful Skin Revealed: The Ultimate Guide to Better Skin". He has been recognized as a leading physician and researcher in the field and also been involved in the development of several new laser systems and therapeutic techniques now commonly used throughout the world.



Marc R Avram MD is a Clinical Professor of Dermatology, Department of Dermatology, Weill Cornell Medical College and Presbyterian Hospital, New York, NY, USA. He is a Fellow of the American Academy of Dermatology (AAD) since 1994 to present. He is also a Member of the International Society of Hair Restoration Surgeons (ISHRS) since 1994 to present. Dr Avram is a Fellow of the ASLMS since 1998 to present. He is also Fellow of the American Society of Dermatologic Surgery (ASDS) since 1997 to present. He is a Member of the Dermatologic Society of Greater New York since 1994 to present.

Dr Avram is a Senior Editor of textbooks, such as Hair Transplantation, published by Cambridge University Press and The Color Atlas of Cosmetic Dermatology published by McGraw-Hill Publishing. Besides, he is also a Editor of *The Color Atlas of Cosmetic Dermatology*, Second Edition, published by McGraw-Hill Publishing. He has also published numerous papers in several journals as well as contributed many chapters in leading textbooks. Dr Avram has also given 400–500 invited lectures in the United States and worldwide.

Available at all medical book stores
or buy directly from Jaypee Brothers through online shopping
at www.jaypeebrothers.com

JAYPEE BROTHERS
Medical Publishers (P) Ltd.
www.jaypeebrothers.com

Shelving Recommendation
DERMATOLOGY

ISBN 978-93-5090-995-9