tion of dermatology books, visit our website www.jaypeebrothers.com, for detailed information of dermatology books, visit our website www.jaypeebrothers.com

Volume 3

# HAIR TRANSPLANT 360

## ADVANCES, TECHNIQUES, BUSINESS DEVELOPMENT & GLOBAL PERSPECTIVES



*EDITOR*
SAMUEL M LAM

JAYPEE

# Contents


## SECTION I: HAIR-TRANSPLANT TECHNIQUES 360 — 1

**Section Editor**: *Vance Elliott*

1. **Hairline-Design Strategies and Techniques** *Russell Knudsen* — 5
2. **Micro-Punch Instruments for Recipient-Site Creation** *Samuel M Lam* — 23
3. **Preview Long Hair Transplantation** *Marcelo Pitchon* — 37
4. **Follicular-Unit Extraction with the SAFE System: A Dull Dissecting-Tip FUE Device** *James A Harris* — 73
5. **Spreader Technique for Donor Harvesting** *Robert S Haber* — 87
6. **Eyelash Hair Transplant** *Marcelo Gandelman* — 93
7. **Eyebrow Hair Transplant** *Robert S Haber* — 105
8. **Surgical Female Hairline Lowering** *Mario Marzola* — 111
9. **Stamp Design for Recipient-Site Creation** *Francisco Jiménez* — 127
10. **Megasessions, Lateral Slits, and Dense Packing** *Thomas C Nakatsui* — 133
11. **Implanters in Hair Restoration** *Jose Lorenzo* — 149
12. **Long-Term Strategic Planning for Hair-Restoration Surgery in Male Pattern Baldness** *Carlos J Puig* — 173
13. **Advanced Transplantation of the Crown: How to Increase Visual Perception of Coverage and Density with Cross-Hatching** *Marco N Barusco* — 183
14. **Managing and Correcting Synthetic Hair Implantation** *Vicenzo Gambino* — 193
15. **Pubic Hair Transplants** *Vicenzo Gambino* — 201
16. **Transplantation to the Beard, Chest, and other Areas** *Jeffrey S Epstein* — 223
17. **The No-Shave Technique for Follicular-Unit Extraction** *Marco N Barusco* — 235

## SECTION II: HAIR-REPAIR TECHNIQUES 360 — 247

**Section Editor**: *Robert S Haber*

18. **The PASSO Algorithm for Hairline Correction** *Vance Elliott* — 251
19. **Hairline Correction Techniques** *Michael Beehner* — 265
20. **Scalp Repair using Tissue Expanders** *E Antonio Mangubat* — 287
21. **Managing Aesthetic Problems following Hair Transplantation** *James E Vogel* — 305
22. **Scalp Reductions and the Frechet Triple-Flap Repair** *Daniel W Didocha* — 315
23. **Correcting Facelift and Other Scars** *Bessam Farjo* — 333
24. **Harvesting Follicular Units from the Body for Scalp Repair** *Robert H True* — 339
25. **Scalp Micropigmentation: A Valuable Technique for Use in Hair Loss** *William R Rassman, Jae P Pak, Jino Kim* — 349
26. **Managing Complications in Hair Restoration** *Melvin A Shiffman, Richard C Shiell, Samuel M Lam* — 357
27. **Follicular-Unit Extraction Grafts Transplanted into Strip Scars** *Marc S Dauer* — 375

## SECTION III: BUSINESS CONSIDERATIONS FOR THE HAIR-TRANSPLANT SURGEON 360 379

**Section Editor**: *Glenn M Charles*

28. Strategies for Business Development of a Hair-Restoration Practice *Michael S Ramsey* 383
29. Marketing Your Hair-Transplant Practice *Matt L Leavitt* 401
30. Management of a Cosmetic Practice *Susan Sullivan* 421
31. Running a Successful Solo Practice *Michael L Beehner* 427
32. Running a Successful Multiple-Location Solo Practice *Jeffrey S Epstein* 447
33. Insights into being Part of a Successful Corporate Practice *Melvin L Mayer* 453
34. Transitioning from a Private Practice to a Corporate Practice in Hair-Restoration Surgery *Carlos J Puig* 459
35. Transitioning from a Corporate to a Solo Private Practice in Hair-Restoration Surgery *Glenn M Charles* 463
36. Building and Managing an International Hair-Restoration Practice *Craig L Ziering* 471
37. Expanding a Hair-Transplant Business into a Diversified Cosmetic Practice *Vance Elliott* 481
38. Expanding a Cosmetic Practice to Include Hair Restoration *Samuel M Lam* 491
39. Malpractice Minimization *Richard C Shiell* 499
40. Managing Your Online Reputation and Advanced Internet Marketing *Robert Baxter* 507
41. Perfecting the Patient Consultation *Jon Hoffenberg* 533
42. Leadership, Teamwork, Multiple Profit Centers, and Other Fundamental Business Concepts for a Successful Cosmetic Practice *Scott R Chaiet, Edwin F Williams III* 543

## SECTION IV: ANCILLARY MEASURES 360 549

**Section Editor**: *Melvin L Mayer*

43. Regenerative Medicine Part I: Usage of Porcine Extracellular Matrix in Hair-Loss Prevention, Hair-Restoration Surgery, and Donor-Scar Revision *Gary S Hitzig* 553
44. Regenerative Medicine Part 2: Use of Platelet-Rich Plasma *Robert Reese* 565
45. New Frontiers in Graft-Storage Solutions *Nils Krueger, Neil S Sadick* 575
46. The TrichoScan for Patient Selection *Jerzy Kolasinski, Kinga Jach-Skrzypczak* 583
47. Bimatoprost for Hair Loss: Initial Studies and Application *Bessam Farjo* 597
48. Autocloning by Beard Hair Plucking *Gary S Hitzig* 607
49. Finasteride Side Effects *Melvin L Mayer* 615
50. Oral Minoxidil *Damkerng Pathomvanich* 629
51. Low-Level Laser Therapy *Robert T Leonard Jr* 637

## SECTION V: DIFFICULT CASES 360 643

**Section Editor**: *Russell Knudsen*

52. Hair Transplantation on a Patient with a Large Cranioplasty: Special Considerations *Marco N Barusco* 647

53. Hairline Plug Correction *David Perez-Meza* 663
54. Approach to the Young Patient *Paul V Shapiro* 671
55. Temporo-Parieto-Occipital Flap Repair *Robert P Niedbalski* 683
56. A Case of Poor Judgment with Traditional Plugs *Paul C Cotterill* 701
57. Graft Removal, Redistribution, and Reimplantation using Follicular-Unit Extraction *Bradley R Wolf* 707
58. Mega- and Gigasessions: Restoring Areas 150 $cm^2$ and Over *Arthur Tykocinski* 721
59. Repair of Hairline Height after Juri-Flap Surgery *Paul T Rose* 731
60. Hair Transplants in Young Men *Paul J McAndrews* 737
61. Repair Case of a Wide Donor Scar *Alex Ginzburg* 747
62. Serial Scalp Reduction *W Henry Barber, Daniel E Rousso* 753
63. Management of Donor-Site Necrosis *David Perez-Meza* 765

**SECTION VI: SURGICAL ASSISTANT 360** 771

**Section Editor**: *Tina Lardner*

64. Emergency-Situation Management for Physicians and Staff *Helen Marzola* 775
65. Robotic Follicular-Unit Extraction (The ARTAS System) and the Role of the Surgical Assistant *Tina Lardner* 797
66. Efficiency Versus Effectiveness *Patrick Tafoya* 811
67. Postoperative Care Do's and Don'ts *Cheryl Larobadiere* 815
68. Follicular-Unit Extraction and the Role of the Surgical Assistant *Aleksandr Krasnozhen* 835
69. The Effects of Graft Injury and Desiccation *Janna Shafer* 839
70. Tools of the Trade *Anne Knudsen* 849
71. Efficient Training Techniques *Sara J Kotai* 855
72. Hair Transplant 360 for Assistants: Updates *Emina Karamanovski* 865

**SECTION VII: BUSINESS CONSIDERATIONS FOR THE SURGICAL ASSISTANT 360** 875

**Section Editor**: *Emina Karamanovski*

73. Starting a Career as a Hair-Transplant Technician *Aileen Ullrich* 879
74. Cross-Training Strategy between a Surgical Assistant and a Medical Assistant *Darla Stewart* 883
75. Different Career-Path Options for Surgical Assistants *Emina Karamanovski* 893
76. Coordinating a Combined Dermatological and Hair-Transplant Practice *Jeff Hamm* 897
77. The Consultant Role in Hair Restoration *Michael S Ramsey* 903
78. Staff Management: The Office Manager's Perspective *Suzanne Scheidel* 909
79. Outline to Running a Successful Solo Practice *Pamela Carlson* 913
80. How to Leverage Your Staff Skills *Emina Karamanovski* 917

*Afterword* 921

*Index* 923

# 4 Follicular-Unit Extraction with the SAFE System: A Dull Dissecting-Tip FUE Device

James A Harris

JAYPEE BROTHERS

## BACKGROUND

There is probably no greater controversy in hair restoration today than that regarding the topic of follicular-unit extraction (FUE). The discussion regarding its role and the details of the technique are reminiscent of the debate that raged on for years about follicular-unit transplantation. Perhaps the bright side of the controversy is the fact that many surgeons acknowledge that the technique may be of benefit but are unsure how to perform the procedure, how it is best used, and how to incorporate it into their practice.

The objective of FUE is to remove follicular units from the skin one at a time without harming the follicles. This aim includes avoiding transection as well as the more insidious crushing trauma during follicular-unit removal that causes an injury that is not necessarily visible. The primary reason for the risk of follicular damage during dissection is the variability in the course of the follicles as well as follicle orientation that does not always match the apparent direction of the hair emerging from the skin surface (Fig. 4.1). Some of the variability is caused by follicular curvature, splaying, and unique follicular directions that are distinctly different from the majority of the follicles within a unit. A successful FUE technique is one that provides an inherently wide margin of error to manage these factors.

Sharp-punch FUE is almost always performed with limited-depth dissection using a mechanical limiter. It is my contention that sharp dissection is somewhat unforgiving if the surgeon's guesses about angle, direction, or depth are wrong. When this happens, the follicular unit will suffer transection of one or more follicles. The added difficulty of limited-depth dissection is that with an incomplete limited-depth dissection there is the possibility of residual tethering of the follicular unit to the deeper tissues necessitating excessive forces to remove the graft. The impact of these forces on the follicle is well documented in the study by Rassman and Bernstein.[1]



**Figure 4.1**

The difference in the subcutaneous course of the follicles from the external course of the hair (shown by the blue line) is shown in this cross-sectional view

In an effort to provide an increased margin of safety for the follicles, a blunt-dissection technique and dissecting punch called the SAFE System [2,3] was developed. The advantage of this approach to FUE is that the dull punch does not have to line up precisely with the angle and direction of the follicles because the dull leading edge of the punch acts more like a guide for the follicles to enter the punch while the rotation of the punch separates the follicles from the surrounding tissue. In a "blind"-dissection technique such as FUE the surgeon requires as much margin of error as possible and the blunt-punch device provides this room for error.




## TECHNIQUE

### Preoperative Considerations

Although this view is not shared by all practitioners of FUE, it is my feeling that in general any patient who is a candidate for hair restoration using strip excision would be a candidate for FUE.[4] Because the grafts produced by FUE are the same anatomical structures that are produced by strip excision the aesthetic results are essentially the same. The following patient types may be "good" or "better" candidates for FUE:

Patients who have

- A desire to wear their hair very short
- Significant scarring from previous surgery and limited scalp laxity
- A tendency to heal with thickened or wide linear scars
- A need to resume a high level of activity soon after the procedure
- A significant aversion to pain

JAYPEE BROTHERS

- Extremely wide hair shafts who require finer hair from the supra-auricular or low occiput regions to create a finer, more aesthetic result
- Poor aesthetic results at the frontal hairline due to large grafts; FUE can be used to thin grafts one follicular unit at a time.

One condition that may make FUE difficult or impossible is the presence of scar tissue that binds the follicular unit to a degree that causes damage to the follicle during the extraction process. Another may be certain African patients who have such a high degree of follicular curvature that FUE results in unacceptable rates of transection; test sessions should be considered in this population.

I am frequently asked how I discuss the graft-harvesting options that will lead a patient toward a particular harvest method. The only time I may direct the patient toward a certain technique would be in cases where there is a distinct indication for one harvest procedure or another, such as the situation of no available scalp laxity. This kind of patient would only be a suitable candidate for FUE.

The initial portion of the consultation is similar to any medical consultation and it is focused on the history and physical examination in order to make the diagnosis of androgenetic alopecia. Once the diagnosis is established and the patient would like to discuss surgical options I inform them that there are two basic options for graft harvest: strip and FUE. (Recently, I have had to explain that within FUE there are two options, either a powered dissection device or the ARTAS robotic device, which is covered more in detail in Chapter 65). I discuss the relevant differences between FUE and strip harvest in terms of scarring, length of hair required after healing, recovery timeline, postoperative pain, resumption of activities, length of procedure, possible difference in survival rates, and cost.

Once the patient understands that there is no such thing as “scar-less” surgery and comprehends the relative advantages and disadvantages of each type of procedure the question about “Which is better?” eventually arises. The next part of the conversation is focused on providing the information to empower the patient to make a decision based on one’s specific needs and the relative merits of each type of procedure. Hype or physician zeal about a particular procedure should not play a role in the consultation. The decision about which method is more appropriate should come from the patient, with the physician providing needed information.

Table 4.1 contains the basic information required in the decision-making process. By considering these factors, the patient will usually have a strong idea about which procedure may be the best fit. In my experience, and in the absence of internet hype, the decision is distilled down to one of two major points. The first is a strong feeling about whether or not the patient is comfortable with a strip of skin being removed and as a consequence, the presence of a linear scar. Often, if this is a

JAYPEE BROTHERS

| Table 4.1: Basic information on follicular-unit extraction and strip | | |
|---|---|---|
| *Feature* | *Strip* | *Follicular-Unit Extraction (FUE)* |
| Scar type | Linear | Dot-like |
| Desired hair length | Longer | Shorter |
| Recovery time | 7–10 days | Short (2–3 days) |
| Postoperative pain | Moderate | Minimal |
| Poor scalp laxity | Poor option | Better option |
| Length of procedure | 1 day | 1–2 days |
| Graft survival rate | "Gold" standard | Possibly lower on average |
| Cost | $X/graft | Approximately 1.5X -2X/graft |

major issue, every other advantage or disadvantage is immaterial. The other major factor is cost. Often the patient will not have the resources to consider FUE and the decision becomes one of "hair versus no-hair" instead of "FUE versus strip".

If the patient decides to have an FUE procedure, the next several considerations have to do with the preparation of the donor area and the surgical planning based on the number of grafts. As a matter of necessity, the hair in the donor area must be trimmed to a length of 1–3 mm in order to be able effectively and efficiently to place the dissection tip over the emerging hairs. This fact leads to several decision points. If a patient wants to maximize the number of grafts harvested, the entire donor area will have to be shaved leading to an exposure of the donor sites (Fig. 4.2). After approximately 10–12 days the scabs will have to come off and the remaining hair will have grown to help camouflage the sites. This may not be an issue in patients who desire a shorter hairstyle to begin with, but some patients may normally wear their hair longer or may not want to expose a previous strip scar.

Shaving the entire donor area may yield 2,200–3,200 grafts without over traumatizing the donor area and increasing the risk of donor shock loss. The yield is dependent on the size of the dissecting punch used and the patient's follicular-unit density. FUE cases of this size will frequently be broken up into two consecutive days of surgery. This action is taken in order to minimize surgeon and staff fatigue, ensure patient comfort, and minimize graft out-of-body time.

If a patient is unwilling to shave the entire donor area there is an option to shave multiple strips ("microstrips"), 2–5 mm wide (depending on the hair length), in the temporal, parietal, and occipital donor areas and leave the intervening hair its normal length to cover the shaved donor strips (Figs 4.3A and B). This will effectively decrease the available donor follicular units for that session by approximately 50% so that in the average patient a surgeon will only be able to obtain 1,100–1,600 grafts using this method. In cases requiring more than this number, the surgeon will have to plan on providing multiple procedures to obtain the desired number of grafts.

JAYPEE BROTHERS



**Figure 4.2**

The donor area one day after a 2,400 graft FUE with a full-shave preparation




**Figures 4.3A and B**

The donor area in a patient with the micro-strip shave preparation (A) with the hair combed down and (B) with the donor extraction areas exposed

The final preoperative consideration is the designation of the appropriate "donor area." In general, the appropriate location of the donor area is that described by Unger and Alt. However, with FUE the boundaries can be extended to include the supra-auricular region and the lower occiput. These are areas where surgeons would not often consider harvesting a strip, yet they are good for obtaining finer hairs for use in the hairline or anterior temples. The danger of those areas is a retrograde alopecia as the patient ages. A more controversial area is the superior aspect of the "standard" donor area, the area at risk for continued loss due to androgenetic alopecia. Some surgeons will harvest from this area, selecting the hairs that are

JAYPEE BROTHERS

"terminal" in appearance, so that the density of this upper fringe more closely matches the extraction zone inferiorly. The recruitment of these marginal areas is somewhat risky, as the sites may become visible over time.

## Operative Considerations

Once the appropriate donor zone has been identified, marked and shaved, a ring block using the surgeon's anesthetic of choice is achieved. Because the extraction phase will usually last several hours, long-acting agents such as bupivicaine (Marcaine) or articaine (Septocaine) with epinephrine are useful in this setting.

Infiltration of the anesthetic at the periphery will achieve anesthesia in the temporal area. However, the parietal and occipital regions will require additional infiltration. The low occipital infiltration will anesthetize the third occipital and lesser occipital nerves, but the greater occipital nerves emerging in the region of the occipital protuberance will have to be addressed with an additional line of infiltration (Figs 4.4A and B).

In my practice the last area to be anesthetized is the occiput, and the patient will be in a prone position for this portion of the procedure. This is also my preferred harvest position for the occiput as the direction of instrument movement is toward my body rather than away, as I believe this provides enhanced instrument stability, better target visualization, and less surgeon fatigue. This position will prevent simultaneous graft implantation but I find that it is more efficient to perform the dissection and extractions prior to implantation.

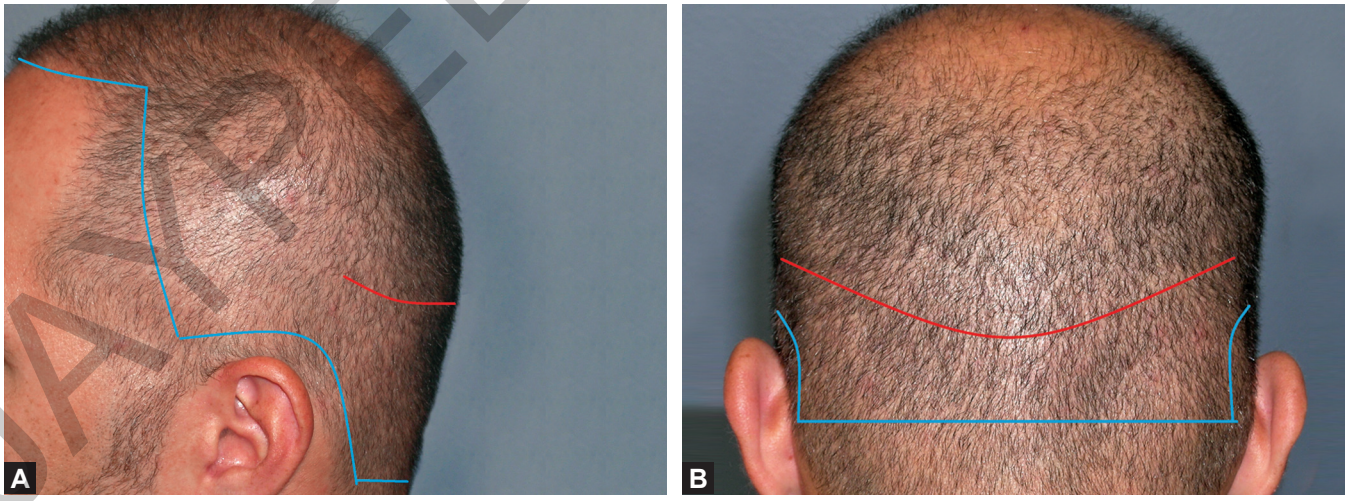


**Figures 4.4A and B**

The donor and recipient areas can be anesthetized at the same time. The blue line represents the area of the ring block while the red line represents the line of infiltration to block the greater occipital nerve in the region of the occipital protuberance

JAYPEE BROTHERS

Of critical importance, and often overlooked by the novice, is the value of adequate magnification. In my experience training physicians to perform FUE, the main reason for the inability to perform the procedure is the failure to accurately place the dissection punch over the emerging hairs. If a physician cannot perform this initial step, it is unlikely that one will be able to extract intact grafts. My suggestion is to rely on good-quality, expanded-field surgical telescopes with a magnification of at least 4x.

The SAFE System, blunt-dissecting punch technique employs either a *two-step manual* dissection technique[5] or a *one-step powered* dissection.[6,7] I will typically employ the manual technique for removing inappropriately placed follicular units from the hairline region or to thin mini-grafts in any scalp location. This technique involves the use of a sharp dermal punch to create a 0.3–0.5-mm depth "scoring incision" around the follicular unit that is then followed by the insertion and manual rotation of a blunt, tapered dissecting punch; the graft is then removed from the skin (Figs 4.5A to C). The blunt tip acts as a "wedge" to separate the follicles from the surrounding tissue and facilitates the "gathering" of splayed follicles or directing follicles that are at disparate angles into the lumen of the punch. In the initial studies this technique was found to have a follicle transection rate of 5.6% in approximately 7,000 extracted grafts.[4] Recent experience reveals transection rates can be less than 2% in some cases and dissection rates can average 200–300 grafts/hour although rates as high as 500 grafts/hour have been achieved.

Although the manual dissection system is effective, it is not very efficient and to address this issue a powered, blunt-punch dissection system was developed. The powered device features a high-speed rotation of a dull punch to allow entry into the skin and a low-torque motor to permit slowing of the punch rotation during the insertion to achieve the graft dissection. The single-step powered-dissection method has replaced the manual technique for all cases except for mini-graft revisions and refinement of the frontal hairline. Follicle-transection rates depend

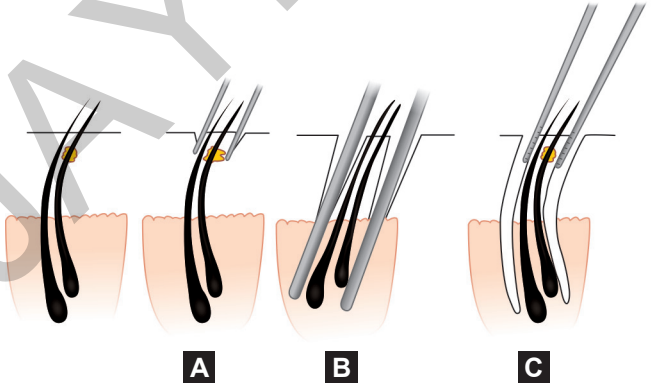


**Figures 4.5A to C**

The steps required for the manual blunt-punch dissection technique. (A) A sharp punch is inserted superficially to "score" the skin, (B) which is followed by the insertion and rotation of a blunt punch. (C) The follicular-unit graft is then removed

JAYPEE BROTHERS

on the patient's skin characteristics and the inside diameter of the punch, and the range is from 2% to 8%[6]. Dissection rates of 750–1,200 grafts/hour are routinely achieved.

The system accommodates a 0.8-mm, 0.9-mm, and 1-mm punch, and the decision to use a particular-sized punch depends on the operator's experience and the average configuration and width of the patient's follicular units. Tighter configurations of the follicular units will permit the 0.8-mm and 0.9-mm punch to be used to extract 3- and 4-hair follicular units; otherwise the 1-mm punch can be used. Punches larger than 1 mm can cause scarring that may be more visible than is acceptable to many patients.

The technique, albeit simple, has definite steps that are critical for successful graft dissection. Prior to the dissection process, a limited area, approximately 3–5 $cm^2$, is injected with 1–2 mL of a dilute epinephrine solution (approximately 1:100,000) in the subcutaneous fat. The purpose is to promote hemostasis and to provide some degree of subcutaneous pressure. The injection should *not* result in "tumescence" or rigid turgor of the skin. The donor area is now ready for the dissection process.

The initial speed setting and its adjustment are very important, especially for novice FUE surgeons. The surgeon should start with the dial in the first one-third of the speed range (corresponding approximately to 1,500–2,400 RPM). A test of 5–10 dissections is performed and the punch should easily enter the skin. However, once the dissection process is underway the surgeon should notice a significant slowing of the rotation, enough so that the surgeon can see and hear the slowing. The reason that the slowing is important is that excessive speed during the dissection will cause the dull punch to interact with the tissue in the same way a sharp punch would, elevating the risk of transection as the depth of dissection increases. The importance of proper speed control cannot be emphasized enough. The surgeon must observe the rotation speed during the entire surgery; and if there are scalp locations where the punch has difficulty entering the skin, the speed will have to be increased. Conversely, in areas where the punch enters the skin and no slowing is noted, the speed must be decreased.

Once the subcutaneous injection has been performed and the speed setting adjusted, the actual dissection process is comprised of the following three steps:

1. The nondominant hand is used to provide skin traction opposite to the direction of the hair emergence in the target donor area. Just enough traction is administered to stabilize the skin so as to prevent skin motion when the punch makes contact with the skin.
2. The punch tip is then aligned to the approximate exit angle and direction of the hair in the target follicular unit.

JAYPEE BROTHERS

3. With the dissection tip rotating, it is placed over the emerging hairs (again magnification is critical) and then onto the skin surface. With gentle pressure on the drill handpiece in a direction that is perpendicular to the skin surface, the side of the punch closest to the skin will create the initial incision (Fig. 4.6). This is called the "engagement" and continued perpendicular pressure on the handpiece will allow the dull punch to track along and dissect the follicular unit from the skin. The dissecting punch can be inserted to the depth limiter for a full dissection. However, in some instances a full dissection can be achieved with less than full-depth insertion.

A somewhat subtle point about where the emerging hairs should be located within the punch should be made. When the surgeon is placing the punch over the follicular unit, the emerging hairs should either be located in the center of the punch or toward the side of the dissection punch that is the last to contact the skin (Figs 4.7A to C). This placement strategy will allow a slight increase in the margin of error. Assuming the surgeon is standing opposite the direction of hair growth and the direction of punch motion is toward the surgeon, the mechanics of punch engagement and insertion will tend to cause the punch to move toward the surgeon.

The follicular units can then be removed from the donor area by an assistant following the dissection process using small, curved, serrated Foerster dressing forceps. We typically employ a double-forceps technique with a "hand-over-hand" motion of the forceps to remove the graft. Care is taken to avoid grasping the bulge region of the follicles, and the serrated surface of the forceps is observed closely to ensure that the teeth are never interlocked.

A possible occurrence with the use of the dull-dissecting tips is that if the angle of insertion is not acute enough or if the punch is inserted too quickly before proper engagement, the skin around the follicular unit can be compressed, which may result in graft burial. Usually pressure on the skin surrounding the buried graft will



**Figure 4.6**

Illustration of the "engagement" process whereby the side of the dissecting punch (dark blue) closest to the surface comes into contact and incises the skin. This is accomplished by the operator aligning the punch to the emerging hair and exerting gentle pressure perpendicular to the skin surface with the direction represented by the black arrow

JAYPEE BROTHERS

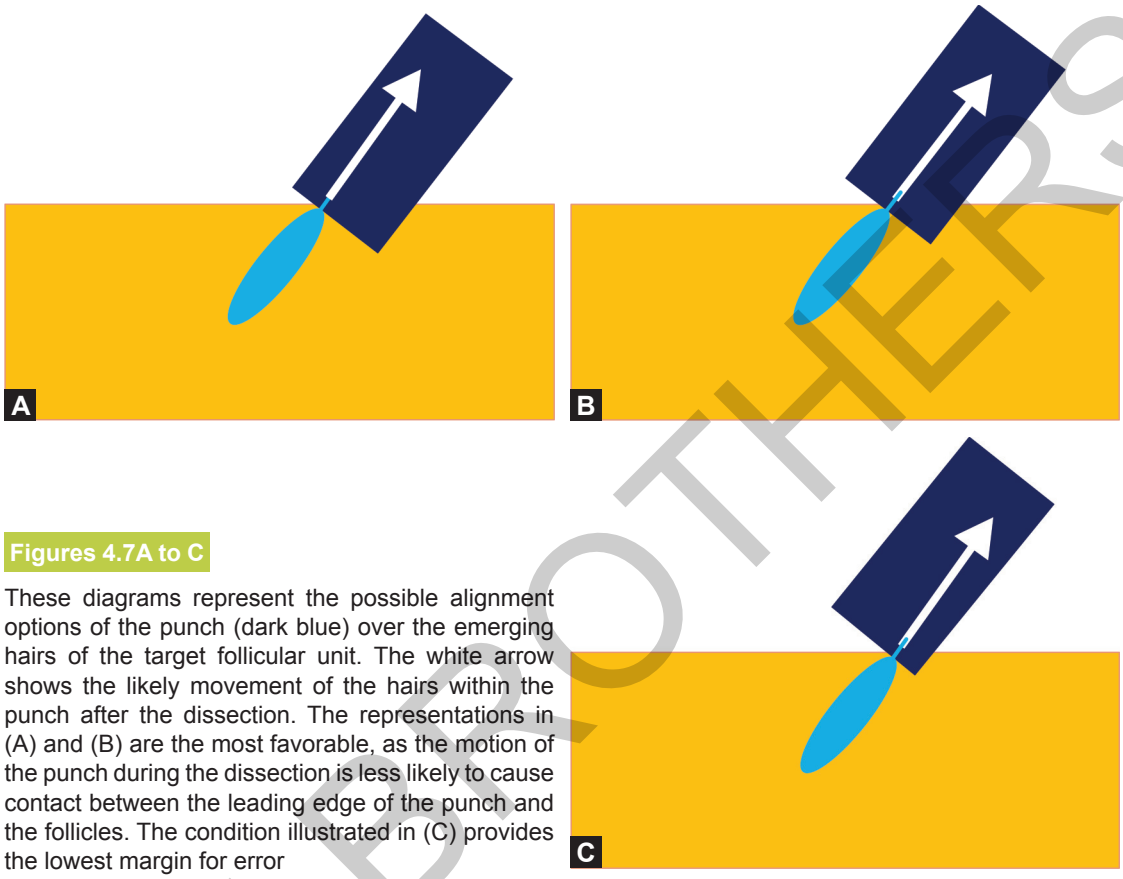


**Figures 4.7A to C**

These diagrams represent the possible alignment options of the punch (dark blue) over the emerging hairs of the target follicular unit. The white arrow shows the likely movement of the hairs within the punch after the dissection. The representations in (A) and (B) are the most favorable, as the motion of the punch during the dissection is less likely to cause contact between the leading edge of the punch and the follicles. The condition illustrated in (C) provides the lowest margin for error

result in its elevation. This problem is encountered much less frequently with the powered one-step dissection but should attempts at locating the graft fail, it may be left in situ, as the rate of inflammatory cyst formation that will require excision is significantly less than 0.002% of all extracted grafts.[5]

## Postoperative Considerations

Once the grafts have been extracted, they are evaluated for transections (the data entered into a spreadsheet), and they are sorted by the number of hairs in the graft. The epidermis is not trimmed off, as it provides a guide for the proper orientation during implantation. This concept will be discussed below.

Implantation of the grafts is essentially the same as strip-harvested grafts except that because most of the grafts lack investing fat, great care must be taken to prevent desiccation during the postextraction process. Keeping the time out of solution to a minimum during the counting and sorting phase, as well as during implantation, is critical.

JAYPEE BROTHERS

The lack of fat also means that there is no tissue on the distal follicle to hold on to during implantation. Great care must be taken not to traumatize the follicles or to bend them during implantation. I will typically make parallel recipient sites with a chisel-shaped blade that is 0.1–0.2 mm wider than I would use on a case using strip grafts. This is to allow a less traumatic insertion with less manipulation. My office has recently adopted an implanter device in order to decrease the manipulation of FUE grafts. The experience thus far has been limited but my initial impressions are that there is definitely less handling of the grafts. An alternative method of implantation is the use of a dilator placed into the pre-made site and then upon its removal, the graft, which is held by the epidermal surface, is placed into the dilated site without the forceps contacting the follicles.

As mentioned above, the epidermis of the graft is not trimmed from the graft, as it is used for graft orientation. When properly placed, the epidermis of the graft should be slightly elevated and should sit parallel to the recipient-area skin when oriented properly (Fig. 4.8). This position will ensure the proper direction and hair curl.

The recipient area after FUE is treated the same way as it would be for strip grafts. If the donor area has been shaved with the microstrip technique, there are no dressings applied but an antibiotic ointment can be used. When the entire donor area is shaved, we apply an antibiotic ointment to the donor area; Telfa dressing is taped in position; and the patient is instructed to leave it in place overnight. The patients are instructed to begin washing the donor area on the first postoperative day as they normally would.



**Figure 4.8**

When the graft is not oriented properly, the skin plug of the graft will appear to be tilted (A) when compared to the skin surface. (B) A properly placed graft will be parallel to the donor skin

JAYPEE BROTHERS

## GRAFT SURVIVAL: FOLLICULAR-UNIT EXTRACTION VERSUS STRIP

This is a hotly debated topic and unfortunately there are no substantial studies to provide a definitive answer to the question of survival. I presented a study in Vancouver in 2004 that compared the survival rates of strip and FUE grafts in a single patient. In four discrete areas 25 3-hair grafts were placed. There were three grids with FUE grafts and one with strip grafts. After 6 months the FUE sites had 69%, 73%, and 54% growth respectively while the strip site had 69% of the hairs growing. This study by no means offers a definitive answer to the question, but it suggests that FUE survival can approximate that of strip grafts. In a small controlled study such as this one there are a low number of grafts; all grafts are handled meticulously; and the entire process is observed very closely. In other words, this is the ideal situation for graft survival.

I do not believe that this study situation is comparable to the case of an FUE harvest of 2,000 or 3,000 grafts in which the out-of-body time is lengthy and planter fatigue and graft handling can play a significant detrimental role. There are a reasonable number of studies[8-10] that support the notion that "chubbier" grafts grow better than skinny grafts and there are no grafts skinnier than those produced by FUE. The logical conclusion is that at this time there is information to at least surmise that the properties of FUE grafts would make them susceptible to a lower survival rate.

Due to the nature of FUE grafts and the data mentioned above about chubby-versus skinny-graft survival, there is likely a higher rate of poor growth in FUE cases as compared to strip surgeries. Anecdotally, the rate has dropped significantly in my practice due to more intense vigilance regarding graft care and handling as well as the advent of powered dull dissection that allows a deeper dissection and that in turn facilitates a more thorough separation of the follicles from the surrounding tissue. Therefore, less manipulation and force are required to harvest the graft.

## THOUGHTS AND PEARLS

Follicular-unit extraction can be an invaluable tool for the physician, as there are certain patients in whom FUE is the only option due to laxity issues or because the patient will not consider strip surgery. It is also an ideal method for removing improperly placed follicular units or to thin plugs or mini-grafts. With practice any surgeon can become proficient in the technique and effectively and efficiently perform FUE to expand his surgical offerings.

To learn to perform FUE the physician must spend time practicing the technique. I suggest that if the physician is currently performing strip harvest the

JAYPEE BROTHERS

following tip can easily be used to gain experience. Prior to the injection of any tumescent solution, the hair in a small area of the soon-to-be strip is cut to a length of 1 mm and 25–50 grafts are extracted in every case. Once the physician can extract approximately 30 grafts in 5 minutes then he is ready to perform FUE in earnest.

Due to the repetitive nature of FUE, the surgeon should adopt an innate flow to the procedure, which will come more easily with experience. When performing a case I typically suggest a methodical flow starting on the side of the surgeon's nonoperating hand, dissect in small segments that are no greater than 1 cm in height, and work toward the side of the operating hand. For example, a right-handed surgeon would work left to right and in this way the technician removing grafts will be able to follow the surgeon and stay clear of the dissection zone. A more important reason for the surgeon to have a consistent and orderly flow of dissection is that there are subtle changes in angles and direction of the follicles and with experience these changes will be compensated for in a gradual manner as the dissection progresses. If the surgeon performs a dissection in one area then skips 4 cm to another area it is harder to anticipate the changes in angles and direction that may be required.

The surgeon should also attempt to find the most comfortable way in which to hold the dissecting handpiece to avoid both mental and physical fatigue. There should be a balance with the weight distributed over 3–4 fingers and the thumb, providing guidance and pressure for the engagement portion of the dissection (Fig. 4.9). Again, the engagement is accomplished with pressure by the thumb exerted in a direction perpendicular to the skin surface and this can be reviewed in Figure 4.6.

When the physician is performing the dissections, it is important to monitor the progress of the dissection effort. The principle visual feedback is the elevation of

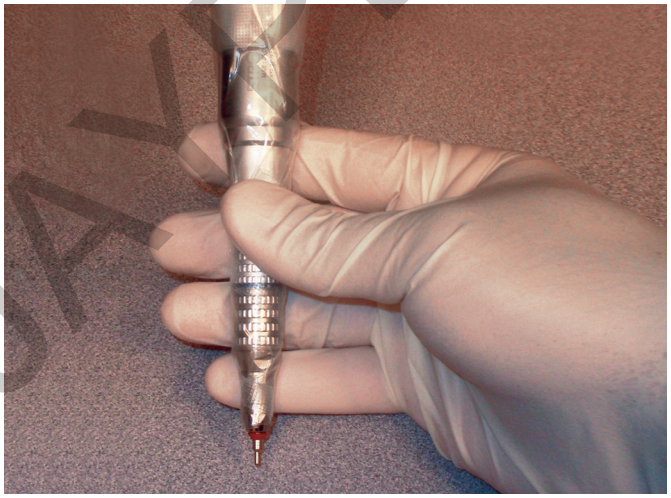

**Figure 4.9**

Holding the handpiece with the weight distributed over several fingers in a cradling position will minimize operator fatigue as well as position the thumb properly for punch engagement

JAYPEE BROTHERS

the dissected graft approximately 1–2 mm above the skin surface, as this indicates a good dissection. Evidence of transections or graft burials is a sign that there is an error in the angle or direction of punch insertion or that the engagement process has not been performed properly.

The final noteworthy point is that each follicular-unit dissection should be treated as a "procedure", i.e., for each dissection the surgeon should perform a conscious review and performance of the appropriate steps that include skin traction, proper punch alignment, effective punch engagement, punch advancement, and a check for graft elevation and rotation speed slowing (and any adjustment if required). The proper repetition of these steps for each dissection attempt will enhance the efficiency and effectiveness of the procedure.

This chapter is intended to enhance the reader's understanding of the proper methodology to perform powered blunt-punch FUE. In addition to a thorough understanding of the technique, practice is required to become proficient and efficient. Once the time is invested, there is a high likelihood of personal satisfaction in mastering a challenging technique as well as offering the fastest-growing procedure in hair-restoration surgery.[11]

## REFERENCES


1. Rassman WR, Bernstein RM, McClellan R, et al. Follicular unit extraction: minimally invasive surgery for hair transplantation. Dermatol Surg. 2002;28:720-8.
2. Harris JA. Follicular unit extraction: the SAFE system. Hair Transpl Forum Int. 2004;14: 157,163,164.
3. Harris JA. New Methodology and Instrumentation For Follicular Unit Extraction (FUE): Lower Follicle Transection Rates and Expanded Patient Candidacy. Dermatol Surg. 2006;32:56-62.
4. Harris JA. Follicular Unit Extraction in Hair Transplantation. In: Avram M, Rogers N (Eds). New York: Cambridge University Press; 2010. pp. 23-34.
5. Rassman W, Harris J, Bernstein R. Follicular Unit Extraction in Hair Transplantation In: Haber R, Dow D (Eds). Philadelphia: Elsevier Saunders; 2006. pp. 133-7.
6. Harris J. Conventional FUE in Hair Transplantation, 5th Edition. In: Unger W, Shapiro R, Unger R, Unger M (Eds). London: Informa Healthcare; 2011. pp. 291-6.
7. Harris JA. Powered Blunt Dissection with the SAFE System for FUE (Part I and II). Hair Transpl Forum Int. 2010;20:188-189;2011; 21:16-17.
8. Seager D. Micrograft Size and Subsequent Survival. Dermatol Surg. 1997;23(9):757-61.
9. Beehner ML. A comparison of hair growth between follicular units trimmed "skinny" vs "chubby." Dermatol Surg. 1999;25(4):339-40.
10. Beehner ML. Comparison of Survival of FU Grafts trimmed chubby, medium, and skeletonized. Hair Transpl Forum Int. 2010:20(1):1,6.
11. International Society of Hair Restoration Surgery: 2011 Practice Census Results, July 2011.


JAYPEE BROTHERS

r detailed information of dermatology books, visit our website www.jaypeebrothers.com, for detailed information of dermatology books, visit our website www.ja

# HAIR TRANSPLANT 360

ADVANCES, TECHNIQUES, BUSINESS DEVELOPMENT & GLOBAL PERSPECTIVES

*Hair Transplant 360, Volume 3*, works as a standalone edition that offers a brand-new, global, multi-author perspective and advances in the world of hair restoration for the starting, intermediate, and advanced hair-transplant surgeon; the assistant; and the office staff. In addition, it complements the single-author editions, Volumes 1 and 2, by providing insight, techniques, and practice management not covered in the first two volumes of this series and written by esteemed colleagues from across the world.

***Salient Features***

- 80 new chapters on diverse topics (with over 900 color photographs and illustrations) including eyelash, eyebrow, beard, chest, and pubic hair transplants; surgical female hairline lowering; megasessions/lateral slits; use of implanters; micro-punch instruments; stamp design for recipient sites; correction of synthetic hair transplants, among many other topics, with 21 exciting videos including surgical hairline lowering, the Frechet triple-flap repair, eyelash transplant, beard transplantation, no-shave FUE, etc.
- Multiple chapters on FUE including "No-Shave FUE", body-to-scalp/scalp-to-body FUE, manual methods of FUE, automated/robotic FUE, FUE for scar repair, difficult cases with FUE, assistant role in manual and automated FUE, and staff management for FUE
- Extensive chapters on repair topics including facelift scar repair, multiple chapters on hairline repair, tissue expanders, scalp reduction and the Frechet triple-flap repair, scalp micropigmentation, plug recycling and repair, managing complications in hair restoration, and scar repairs
- First and only book of its kind with 15 chapters on business development in the hair-transplant industry including marketing, internet/reputation management, running a solo practice, running a multi-location practice, going from a corporate to a private hair practice (and vice versa), building an international hair brand, expanding into the hair business, expanding into a cosmetic business from a hair practice, improving consultation techniques, leadership, developing multiple profit centers, and malpractice minimization
- Chapters dedicated to new technology and harnessing established techniques including the use of platelet-rich plasma (PRP), porcine extracellular matrix (ACell), new graft-storage solutions, use of the TrichoScan, bimatoprost, autocloning, oral minoxidil, finasteride side effects and consent forms, and low-level laser therapy
- Section on difficult cases with 12 chapters that help a starting and seasoned surgeon think critically about hair problems from a case-based perspective including hair transplant in a cranioplasty case, plug correction, young-patient issues, gigasession transplants, repair after a Juri flap, serial scalp reduction, and management of donor-site necrosis
- First and only multi-author book for hair-transplant assistants and technicians that includes topics on emergency management, robotic FUE, improving efficiency, postoperative care, graft selection, industry tools, training techniques, and updates from *Hair Transplant 360, Volume 2*
- First and only multi-author book for assistants dedicated to practice management including how to start as a technician, cross-training between the surgical assistant and the medical assistant, exploring career path options for surgical assistants, coordinating a combined dermatological and hair-transplant practice, the consultant role in hair restoration, staff management, outline guide to daily responsibilities, and how to leverage your staff skills



**With 4 DVDs**



**Samuel M Lam** is the author of five other medical textbooks and over 200 scientific articles and book chapters. He lectures both nationally and internationally and runs a national course on hair restoration. He is triple board-certified and is a diplomate of the American Board of Hair Restoration Surgery. He is an active member of and has chaired committees for the International Society of Hair Restoration Surgery (ISHRS). His clinical practice in Plano, Texas, is limited to facial plastic surgery and hair restoration.

Shelving Recommendations
**DERMATOLOGY, PLASTIC SURGERY & HAIR TRANSPLANT**

ISBN 978-93-5152-070-2
9 789351 520702

**Available at all medical book stores**
**or buy directly from Jaypee Brothers through online shopping**
**at www.jaypeebrothers.com**

**JAYPEE BROTHERS**
**Medical Publishers (P) Ltd.**
**www.jaypeebrothers.com**