ur website www.jaypeebrothers.com, for detailed information of orthopedic books, visit our website www.jaypeebrothers.com

Recent Advances in ORTHOPEDICS



Matthew S Austin
Gregg R Klein

JAYPEE

Contents

1. What's New in Spine **1**

D Greg Anderson, Alex Johnson

- Tubular Decompression for Lumbar Stenosis and Herniated Lumbar Disc Disease 1
- Minimally Invasive Transforaminal Lumbar Interbody Fusion 3
- Lateral Interbody Fusion 5
- Percutaneous Pedicle Screw Instrumentation 7

2. What's New in Hip Joint Preservation Surgery **11**

Frank R Avilucea, Christopher E Pelt, Jill Erickson, Christopher L Peters

- Pediatric Disease Sequelae 11
- Femoroacetabular Impingement 17
- Dysplasia 26

3. What's New in Total Hip Arthroplasty **34**

Harlan Levine

4. What's New in Knee Arthroplasty **48**

Carl Deirmengian, Jess H Lonner

- Improving the Patient's Surgical Experience 49
- Implant Performance 54
- Facilitating the Surgeon's Abilities 57

5. What's New in Sports Medicine **64**

Frank G Alberta, Michael A Kelly

- Knee 65
- Shoulder 72
- Elbow 78

6. Recent Advances in Shoulder and Elbow Surgery **85**

Charles L Getz

- Shoulder Arthroplasty 85
- Reverse Shoulder Arthroplasty 86
- Infection 87
- Rotator Cuff 88
- Instability 89
- Arthroscopy 90
- Fractures 90

- Acromioclavicular Joint 91
- Elbow 92

7. What's New in Foot and Ankle 96

David I Pedowitz, Boleslaw Czachor

- Tendinopathy/Instability 96
- Arthroscopy/OCD 102
- Ankle Arthritis 105
- Forefoot, Trauma, Miscellaneous 107

8. What's New in Hand and Wrist 116

Kevin Lutsky, Asif Ilyas, Jonas L Matzon, Pedro K Beredjiklian

- Trauma 116
- Nerve 120
- Kienbock Disease 122
- Antibiotics 123
- Scapholunate Reconstruction 123
- Tendon 123
- Ulnar Sided Wrist Pain 126
- Trapeziometacarpal Arthritis 127
- Dupuytren's Disease 128

9. What's New in Orthopedic Oncology 132

Benjamin E Bluth, Susan V Bukata

- Giant Cell Tumor of Bone 132
- Osteosarcoma 134
- Unicameral Bone Cyst 138

10. What's New in Trauma 145

Kenneth R Gundle, James C Krieg

- Upper Extremity 146
- Pelvis 148
- Lower extremity 151

11. What's New in Pediatric Orthopedics 165

David A Podeszwa, Brandon A Ramo, Rebecca Clinton, Henry B Ellis Jr, Lawson A Copley, David W Roberts

- Pediatric and Adolescent Hip Disorders 165
- Pediatric Trauma 170
- Pediatric Musculoskeletal Infection 176

12. What's New in Orthopedics: European Perspective 186

Henry Budd, Chris Lawrence, Vikas Khanduja

- Upper Limb Surgery 186
- Lower Limb Adult Reconstruction 192

- Sports Knee Surgery 195
- Foot and Ankle Surgery 196
- Lower Limb Trauma Surgery 197
- Spinal Surgery 198

13. What's New in Orthopedics: Asian Perspective—Hip 202

Tetsuya Jinno, Kazuyoshi Yagishita

- Hip Diseases in Japan and Other Asian Countries 202
- Joint-Preserving Surgeries for Dysplastic Hips 203
- Total Hip Arthroplasty 207
- Patient-Based Assessment of Hip Joint Function 211

14. What's New in Orthopedics: Asian Perspective—Knee 215

Kazuyoshi Yagishita, Tetsuya Jinno

- Osteometry of Knee Joint in Asian Population 215
- Total Knee Arthroplasty for Asian Patients 216

15. What's New in Total Knee Arthroplasty: South American Perspective 221

David Figueroa, Rafael Martínez, Maria Jesus Tuca

- Epidemiology 221
- Modularity 222
- Compartmentalization 222
- High-Flexion Designs 225
- Surgical Approaches and MIS 226
- Fixation 227
- Image Guidance 228
- Posterior Cruciate Ligament 228
- All-Poly Components 229
- Gender Designed 230
- Crosslinked Polyethylene 230

16. What's New in Hip Arthroplasty: South American Perspective 234

Claudio Mella, Claudio Diaz-Ledezma

- Preoperative Optimization and Risk Stratification: Avoiding Catastrophic Problems 234
- Implant Selection: What's In and What's Out 236
- Bearing Couples: Is Metal-On-Metal Over? 237
- Trunionosis: A Real Problem 237
- Tranexamic Acid (TXA): An Indispensable Ally 237
- Thromboprophylaxis: Green Light for Aspirin 238
- Local Infiltration Analgesia during the Postoperative Period: The Facts 238
- Dual-Mobility Cups (MDM): A Real Deal? 239
- Uncemented Femoral Revisions: When and Why? 239

- Acetabular Revision: What if We Don't Have Metal Augments? 239
- Infections: A Common Target Plus New Guidelines to Decrease Variability in Management 240
- Intracapsular Displaced Fractures in the Healthy Elderly: THA Versus Hemiarthroplasty 240

17. Recent Advances in the Basic Orthopedic Sciences: Osteoarthritis, Infection, Degenerative Disc Disease, Tendon Repair, and Inherited Skeletal Diseases 245

George Feldman, Andrzej Fertala, Theresa Freeman, Noreen J Hickok, Rowena McBeath, Makarand V Risbud, Irving M Shapiro

- The Importance of Subchondral Bone in the Pathogenesis of Osteoarthritis 245
- Impact of Genetics on the Diagnosis of OA 249
- Degenerative Disc Disease: New Insights into Disease Pathogenesis and Radicular Pain 253
- Control of Infection in Orthopedic Surgery 256
- Cellular Responses to Mutations in Collagens that Form Skeletal Tissues 258
- Mechanical Forces and Growth Factor Signaling in Tenogenesis 261

Index *269*

Chapter 2

Frank R Avilucea, Christopher E Pelt, Jill Erickson, Christopher L Peters

What's New in Hip Joint Preservation Surgery

INTRODUCTION

Over the course of the last two decades, there has been substantial growth in the understanding and diagnosis of the spectrum of disorders resulting in hip pain in the young adult. There is a growing body of evidence regarding the pathomorphology of the hip, surgical treatment approaches and treatment outcomes. Additionally, recent advancements in surgical treatment have heightened interest in the management of these disorders. In this review, we provide an update on recent evidence and clinical implications of surgical management of hip pathomorphologies in young adult patients, including sequelae of pediatric hip disease, femoroacetabular impingement, hip dysplasia, and the retroverted acetabulum.

PEDIATRIC DISEASE SEQUELAE

Legg–Calvé–Perthes Disease

Legg–Calvé–Perthes is caused by disruption of blood supply to the growing femoral head in children. The characteristic sequence of epiphyseal growth retardation, femoral head sclerosis, fragmentation and reossification leads to coxa magna, coxa plana and trochanteric overgrowth (given that the trochanteric apophysis is usually unaffected). Because the femoral head insult typically occurs between ages 6 and 12, the deformed femoral head often influences acetabular development and may result in some degree of acetabular dysplasia. The Perthes hip often becomes symptomatic during the initial osseonecrotic process and may also manifest symptoms later in adolescence or young adulthood due to abnormal morphology and altered

hip biomechanics. It is not uncommon for a Perthes hip in this latter age group to present with symptoms of both hip impingement and instability making surgical decision challenging (Figs 2.1A and B).

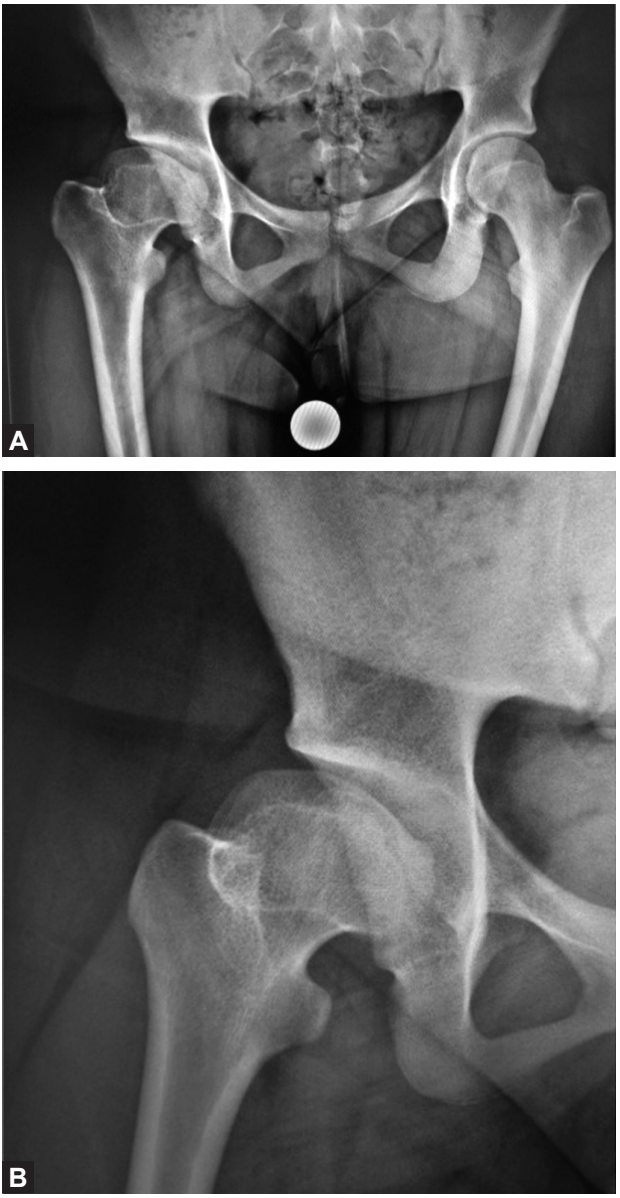

Figs 2.1A and B: Anteroposterior pelvis and right hip lateral radiographs demonstrating right-sided coxa magna with associated proximal femur deformity, femoral neck shortening and upward sloping sourcil. These findings, identified in a young adult, are consistent with Perthes.

The efficacy of surgical treatment in the early stages of Perthes remains a topic of debate. Historically, surgical management has focused on containment of the femoral head within the acetabulum and improving hip biomechanics with distal trochanteric advancement. Prevention of impingement has been accomplished mainly with anterolateral cheilectomy. These surgical techniques have been variably effective and the typical post-Perthes hip in adolescence and young adulthood most often has the pathomorphologic femoral and acetabular findings noted above.[1]

The treatment of the post-Perthes hip in these patients has been substantially improved by the technique of safe surgical hip dislocation.[2] The surgical dislocation approach allows for femoral head reshaping or debulking, treatment of associated intra-articular hip pathology such as labral or hyaline cartilage damage, and trochanteric advancement to improve hip biomechanics. Several recent reports support improved outcomes with so-called relative femoral neck lengthening safely performed via surgical hip dislocation.[2–5] There is also new evidence that treatment of associated acetabular dysplasia with combined or staged periacetabular osteotomy may effectively manage associated hip instability, which may manifest after surgical remodeling of the femur (Fig. 2.2).[5,6]

Finally, more advanced extensions of the surgical hip dislocation approach based on development of an extended retinacular flap (Figs 2.3A to C) to protect the medial femoral circumflex based blood supply to the femoral head, are being utilized to perform fascinating morphology changes of the femoral head. Collectively termed "femoral head reduction," these approaches offer the potential for substantial modification of post-Perthes femoral morphology and at least, in some select centers, can be safely performed (Figs 2.4A and B).

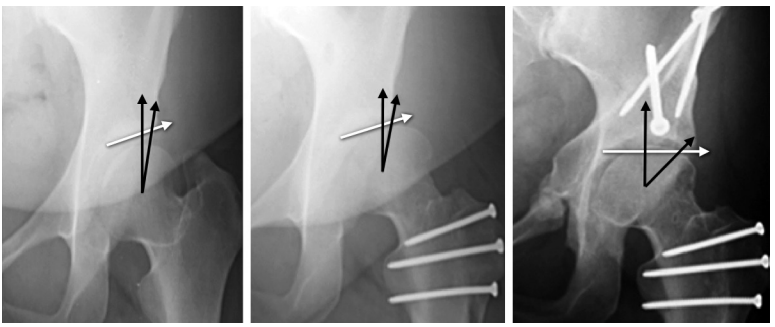

Fig. 2.2: Serial radiographs demonstrating post-Perthes patient who underwent surgical dislocation and relative femoral neck lengthening. The radiographic series demonstrates the surgical correction achieved.

Although literature is surfeit with small case series, there is need for long-term outcome studies to help identify which patients are ideal candidates to undergo a comprehensive surgical intervention to treat the complex deformity and intra-articular pathology associated with Legg–Calvé–Perthes.

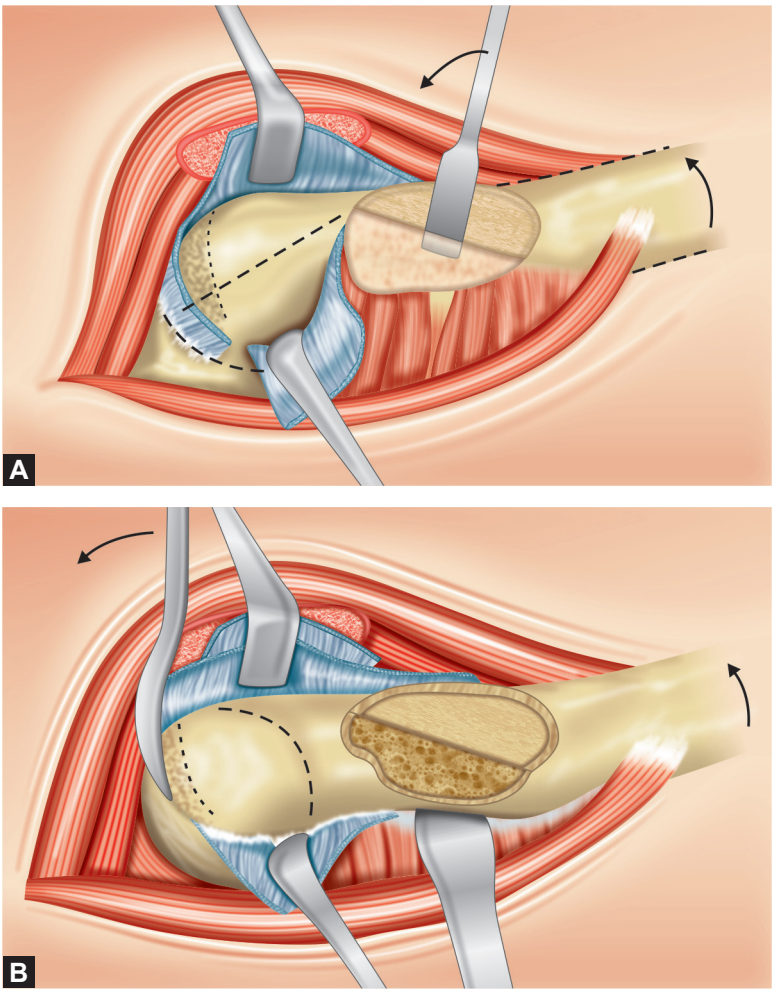

Figs 2.3A and B: (A) Development of the extended retinacular flap includes reducing the posterior portion of the greater trochanter through the apophysis to the femoral neck. Distally, the short external rotators are subperiosteally released from the bone and at the cranial end of the osteotomy, incise the retinaculum in line with the femoral neck axis (dashed line); (B) Further mobilize the retinaculum proximally and dorsally while carefully respecting the vascular foramina. After transepiphyseal separation the posterior callus can be resected to original bone of the neck avoiding tension on the retinaculum.

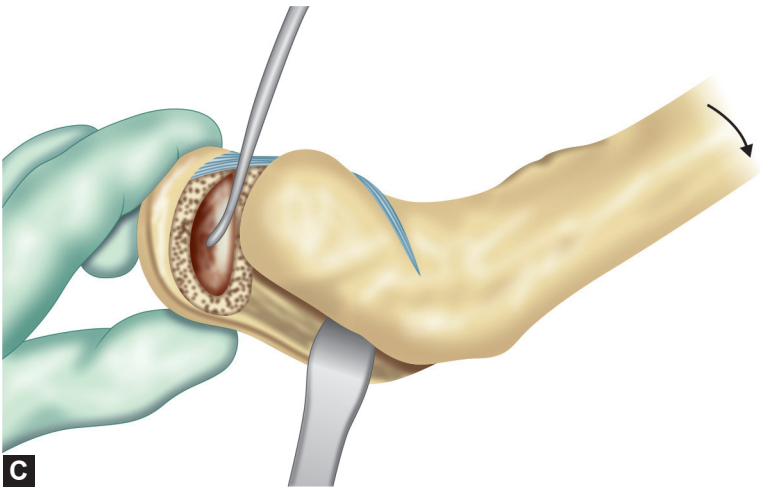

Fig. 2.3C: Manually, debride the remaining cartilage from the physis before reduction. *Source*: Figures reprinted with permission from AAOS: Leunig M, Slongo T, Ganz R. Subcapital realignment in slipped capital femoral epiphysis: surgical hip dislocation and trimming of the stable trochanter to protect the perfusion of the epiphysis. Instr Course Lect 2008;57:499–507.

Slipped Capital Femoral Epiphysis (SCFE)

Numerous factors are currently thought to contribute to the pathologic development of SCFE, including body habitus and adolescent obesity, mechanical factors, and endocrine disorders. The incidence is known to vary broadly across different geographic regions, an epidemiologic finding that remains largely unexplained. For the vast majority of SCFE, in situ pinning remains the *sina qua non* approach to treatment of children, an intervention that for mild and moderate cases ostensibly stabilizes the deformity and, in some cases, can lead to relatively normal hip function.[7,8]

Slipped capital femoral epiphysis is a known pathologic entity that often results in development of adolescent and young adult femoroacetabular impingement (FAI). In the patient with SCFE, a gradual or acute disruption of the capital femoral epiphysis results in posterior translation of the femoral head, femoral retroversion and an anterior prominence of the proximal femoral metaphysis, which may cause femoroacetabular impingement leading to early labral and cartilage injury (Figs 2.5A and B).[9–11] The degree of metaphyseal deformity has also been shown to exert damaging loads on the acetabular labrum and rim in addition to increasing the risk for osteoarthritis.[8,10]

Although conventional wisdom, heavily influenced by long-term follow-up data from Iowa,[8] has held that the majority of hips with mild to moderate

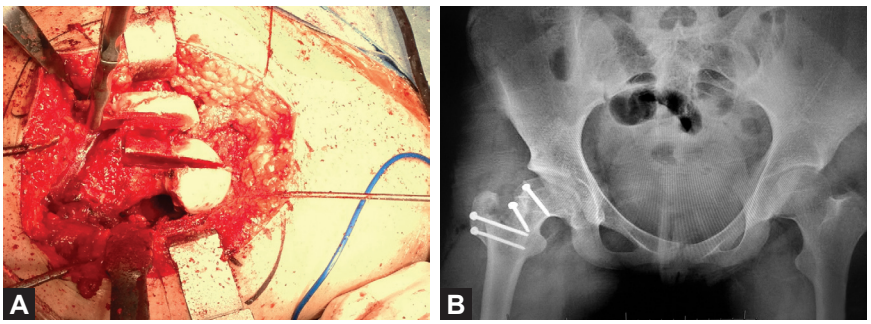

Figs 2.4A and B: (A) Intraoperative photograph of surgical hip dislocation with extended retinacular flap and osteotomy utilized to achieve a "femoral head reduction"; (B) Figure 2.4B demonstrates the postoperative radiograph following femoral head reduction osteotomy.

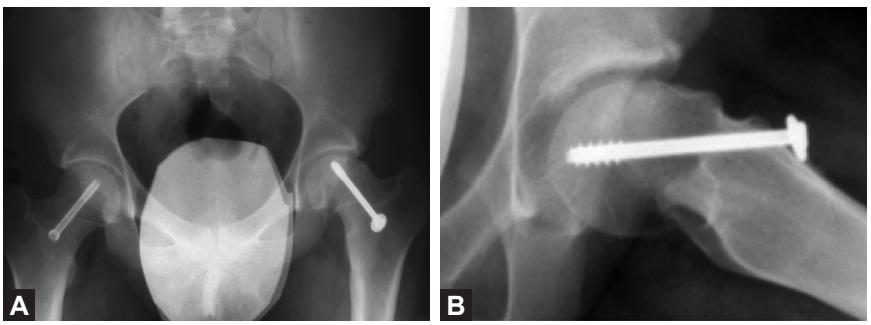

Figs 2.5A and B: Anteroposterior pelvis and left hip lateral radiographs demonstrating post in-situ pinning of slipped capital femoral Epiphysis (SCFE). The posterior translation of the femoral head has resulted in an anterior prominence of the proximal femoral metaphysis creating cam-type FAI with obvious pistol-grip deformity at the head-neck junction

deformity do well into young adulthood, more recent evidence suggest that even mild slips may lead to femoroacetabular impingement, pain, loss of function and early joint degeneration.[10,12] From a treatment perspective, pinning a stable or unstable slip in situ remains a mainstay but there is increased recognition that leaving a moderate to severe slip without further treatment is perhaps suboptimal. Similar to Perthes, the surgical hip dislocation approach (frequently with an extended retinacular flap) has proven safe and powerful for addressing the morphology abnormalities commonly encountered in more severe slips.[13]

Depending on the magnitude and timing of the slip, surgical hip dislocation is currently utilized to perform femoral head realignment, proximal femoral osteotomy, relative neck lengthening and femoral

head-neck osteochondroplasty. For the more severe slip (slip angle > 45°) with an open proximal physis, subcapital realignment via the modified Dunn procedure is safe and effective in experienced hands without an increase in avascular necrosis (AVN) from the baseline risk that SCFE imparts.[13–15]

The risk of AVN following subcapital realignment in the setting of closed physis may be higher.[16] For the severely deformed hip with functional limitations in adolescence valgus-flexion osteotomy (so-called Southwick or Imhauser osteotomies) at the intertrochanteric level can be combined with femoral head-neck offset improvement and treatment of intra-articular pathology via the surgical dislocation approach.[17–19] A recent report has also described arthroscopic head-neck offset improvement in more mildly deformed slips to prevent the joint damage associated with FAI.

The occurrence of SCFE potentially results in irreversible degenerative changes leading to early total hip arthroplasty. In an effort to protect hip mechanics and articular longevity, Schoenecker et al. formulated an algorithm aimed at treating varied pathology seen with stable slips.[20] The algorithm helps the surgeon conceptualize the pattern of slip in addition to selecting an appropriate surgical intervention at the index procedure and, if needed, recommendations for subsequent reconstructive procedures for correction of residual deformity.

FEMOROACETABULAR IMPINGEMENT

Various Forms of Impingement

To date, four main morphologically abnormal relationships between the acetabulum and femoral head have been identified leading to abnormal contact between the femoral neck and the anterolateral acetabular margin: cam, pincer, mixed (combined cam and pincer) and cam in the setting of developmental dysplasia of the hip (DDH). Other unusual sources of intra-articular impingement may also be found, and more recently emphasis has also been placed on identification of extra-articular sources of impingement.

In cam-type FAI, impingement most commonly occurs with hip flexion and internal rotation whereby the aspherical portion of the femoral head enters the acetabulum creating a shear injury to the acetabular labral-articular margin (Figs 2.6 and 2.7). This outside-in type injury often occurs at the anterolateral acetabulum and frequently spares the capsular margin of labrum until late in the disease process. Cam-type FAI has been shown to produce a characteristic chondral injury, hyaline cartilage delamination, at the area of impingement. The presence of this delamination injury may adversely affect surgical treatment outcome and complicate surgical decision making.[21]



Fig. 2.6: The right hip lateral radiograph shows a significantly decreased femoral-head neck offset and presence of calcified labrum, findings consistent with cam-type FAI.



Fig. 2.7: Shows a lateral of the hip following surgical dislocation to increase the head-neck offset and treat the intra-articular pathology.

The pincer-type lesion, on the other hand, is an acetabular-based pathomorphology where at the limit of hip flexion, the acetabular rim and labrum impact the femoral neck or head-neck junction (Fig. 2.8). This



Fig. 2.8: Anteroposterior pelvic radiograph demonstrating excessive global coverage of the left hip and a significantly increased lateral center edge angle measured greater than 40 degrees. These are common findings seen in pincer-type FAI.

inside-out mechanism may result in labral attenuation, gradual ossification, and over time, the potential for posterior joint damage (contrecoup injury pattern) due to increased pressure from levering posteriorly. In pincer-type FAI the pathomechanic phenomenon of impaction of the acetabular rim at the femoral head-neck junction may be due to acetabular retroversion, focal anterosuperior overcoverage, global acetabular overcoverage or possibly coxa-profunda.

Pincer-type FAI is often radiographically characterized by a crossover sign, a posterior wall sign, an ischial spine sign, increased lateral center-edge angle, low acetabular index, and acetabular protrusio.[22] Coxa profunda, defined radiographically as the medial acetabular fossa in contact or projecting medial to the ilioischial line, is another finding often thought to be an indicative feature of FAI consistent with acetabular overcoverage. However, two recent studies have questioned this belief. After comparing a cohort of 67 collegiate football players to 179 hips in patients who had undergone hip preservation surgery, Anderson et al. found coxa profunda was not consistently associated with acetabular overcoverage.[23] Additionally, Nepple et al. recently completed a retrospective assessment of 157 hips with the diagnosis of either acetabular dysplasia, Perthes, FAI and asymptomatic hips.[24] As coxa profunda was identified in the majority of asymptomatic hips, they concluded that this radiographic finding was a nonspecific finding.

The mixed form of pincer and cam FAI remains the most commonly identified pattern of FAI. The combined pattern may produce

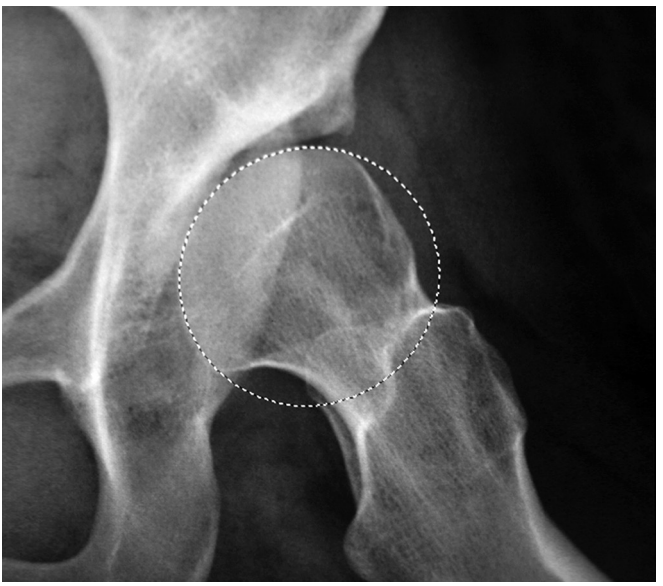

Fig. 2.9: Frog-leg lateral radiograph of the left hip showing lack of femoral head-neck offset in an aspherical femoral head with concomitant acetabular dysplasia.

pathomechanical elements of both cam and pincer FAI, leading to an array of pathological findings including labral and acetabular chondral injury. Typically, femoral articular cartilage is preserved until very late in the disease process.

The final morphotype of intra-articularly based FAI is the cam-like femoral deformity associated with acetabular dysplasia or DDH (Fig. 2.9). The cam deformity may often be a relative lack of femoral head-neck offset more than an excess of bone at the head-neck junction. At present it is unclear whether the femoral morphology is a contributor to joint dysfunction in the setting of acetabular dysplasia. However, at least two observations of recent treatment trends may be noted. First, isolated treatment of the femoral head-neck offset deformity in the setting of dysplasia may result in inferior surgical outcomes, particularly if the labrum is resected.[25,26] Second, definitive treatment of acetabular dysplasia via periacetabular osteotomy (PAO) may create the potential for subsequent impingement due to the acetabular reorientation in the setting of existing decreased femoral head-neck offset. The now improved acetabular coverage may accentuate impingement due to the lack of head-neck offset. Indeed, early in our understanding, FAI was described by Dr. Ganz and team as a sequelae of having treated dysplasia with acetabular reorientation.[27]

While there has been much focus on identification and treatment of intra-articular FAI there is a growing body of evidence describing extra-articular

sources of impingement. The anterior inferior iliac spine (AIIS) is one such source demonstrated in several studies to impinge against the distal femoral neck.[28–30] To further characterize and understand AIIS morphologic variants contributing to impingement, Hetsroni et al. evaluated 3-D CT reconstructions of 53 hips with impingement.[31] Based upon this study, three variants have been identified: Type I, presence of a smooth ilium wall between the most caudal level of the AIIS and the anterosuperior acetabular rim; Type II, the AIIS prominence extends to the level of the acetabular rim; and Type III, the AIIS extends distally to the acetabular rim. The study further identified that Type II and III variants are associated with decreased hip flexion and internal rotation, objective findings to consider regarding the need for AIIS decompression of variants extending to and below the acetabular rim. In these cases, terminal hip flexion results in impingement of the caudal prominence of the AIIS against the distal aspect of the femoral neck. Radiography often reveals subchondral cystic change at the distal femoral neck, a finding identified with Type II and III AIIS morphology.[31]

Resection of the AIIS prominence has been shown to improve hip flexion and decrease pain (Figs 2.10 and 2.11).[28–30] A recent retrospective analysis of 10 patients treated with arthroscopic decompression of either a Type II or III AIIS, in addition to cam resection, labral debridement and rim trimming, with a mean follow up of 14.7 months showed an 18° increase in hip flexion, and a 34-point increase in the HHS.[28] It is important to consider the various procedures that took place in these patients as the AIIS decompression may not have been the isolated variable resulting in the aforementioned clinical improvement.

Current Surgical Trend in Treating FAI

As the capacity to assess and treat injuries to the hip has increased, a greater understanding of the etiology of symptomatic hip pathology in the prearthritic patient has emerged. Over the last several decades, technical advances in arthroscopic management of the hip has enabled access to the deeply recessed femoral head leading to an expansion of applications, including the treatment of symptomatic labral tears, chondral lesions, injuries to the ligamentum teres, capsular laxity, numerous extra-articular pathologies, and femoroacetabular impingement. Due to the various advantages of hip arthroscopy, including a potentially improved recovery compared to open surgery, the prevalence of arthroscopic surgery for FAI has quickly become the predominant surgical modality over the last decade, a surgical trend noted to increase 18-fold amongst American Board of Orthopaedic Surgery candidates.[32]



Fig. 2.10: Anteroposterior (AP) pelvis radiograph demonstrating a Type III anterior iliac spine (AIIS) in addition to decreased femoral head-neck junction of the left hip. There is also presence of subchondral cystic formation at the femoral head-neck junction consistent with cam-type FAI, and similar findings located at the distal femoral neck consistent with extra-articular impingement.

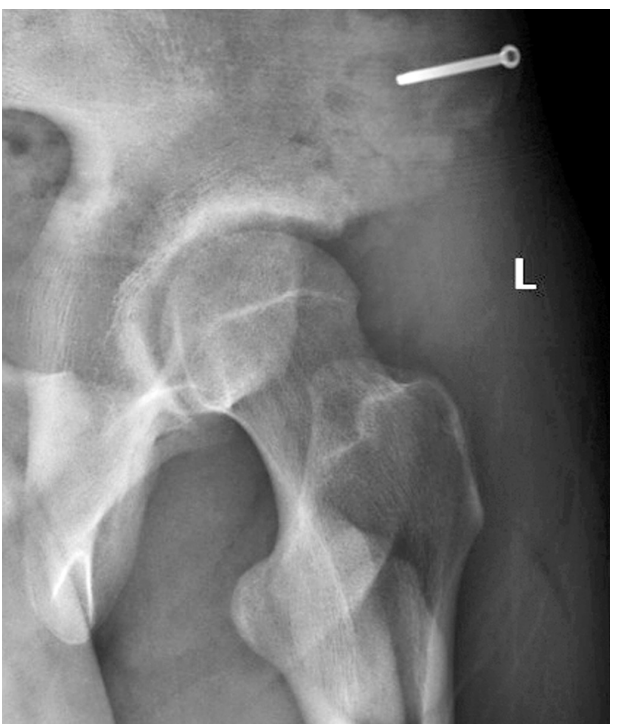

Fig. 2.11: Figure 2.11 shows a left lateral hip radiograph following open surgical treatment to resect the low-lying anterior inferior iliac spine (AIIS) and increase the femoral head-neck offset.

for detailed information of orthopedic books, visit our website www.jaypeebrothers.com, for detailed information of orthopedic

Recent Advances in ORTHOPEDICS

Recent Advances in Orthopedics is intended to keep busy adult reconstructive surgeons in training and in practice up-to-date with recent advances and best practices in the field.

Each chapter distills the recent literature on changes in practice and in emerging therapies and technologies for each specialty area within orthopedics, including

- Spinal Surgery
- Hip Joint Preservation Surgery
- Total Hip Arthroplasty
- Knee Arthroplasty
- Sports Medicine
- Shoulder and Elbow Surgery
- Foot and Ankle Surgery
- Hand and Wrist Surgery
- Orthopedic Oncology
- Trauma Surgery
- Pediatric Orthopedics
- Basic Sciences

Additional chapters examine updates in practice in Europe, South America, and Asia.

Shelving Recommendation
ORTHOPEDIC SURGERY

ISBN 978-93-5152-112-9
9 789351 521129

Available at all medical bookstores or buy directly from Jaypee Brothers at www.jaypeebrothers.com

JAYPEE BROTHERS
Medical Publishers (P) Ltd.
www.jaypeebrothers.com