our website www.jaypeebrothers.com, for detailed information on otolaryngology books, visit our website www.jaypeebrothers.com

VOLUME 3

RECENT ADVANCES IN OTOLARYNGOLOGY

HEAD & NECK SURGERY

ANIL K LALWANI • MARKUS HF PFISTER

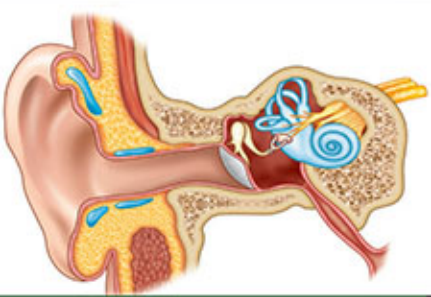

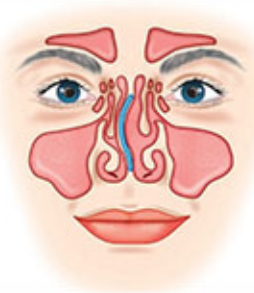



JAYPEE

Contents

1. Transoral Robotic Surgery for Obstructive Sleep Apnea **1**
Hardik K Doshi, Rahmatullah Rahmati
◊ Transoral Robotic Surgery Background and Technique 1
◊ Transoral Robotic Sleep Surgery Literature Review 2

2. Image Guidance in Sinus Surgery **9**
Laura Oleaga, Manuel Bernal-Sprekelsen
◊ Computed Tomography 9
◊ Magnetic Resonance Imaging 19

3. Endoscopic Repair of Cerebrospinal Fluid Leaks **23**
Timothy R DeKlotz, Eric W Wang, Carl H Snyderman
◊ Types of CSF Leaks 23
◊ Epidemiology 25
◊ Preoperative Assessment and Considerations 26
◊ Adjunctive Measures 29
◊ Methods of Repair 32
◊ Outcomes 39
◊ Complications 39

4. Measuring Quality of Life in Nasal Surgery **44**
Ingo Baumann
◊ Quality of Life—Basics and Definitions 44
◊ Quality of Life in Patients with Chronic Rhinosinusitis 45
◊ Quality of Life after Septoplasty 50
◊ Quality of Life after Rhinoplasty 52

5. Personalized Therapy in Head and Neck Cancer **61**
Xiao Xiao, Jennifer R Grandis
◊ EGFR Pathway 62
◊ JAK-STAT Pathway 68
◊ PI3K Pathway 69

6. Vascular Anomalies—Advances and Updates for the Otolaryngologist **74**
Francine Blei, Ascanio Guarini
◊ How to Distinguish a Hemangioma from a Vascular Malformation? 75
◊ Treatment of Hemangiomas 85
◊ Vascular Malformations 85
◊ Clinical Pearls to Distinguish Vascular Malformations 88
◊ Genetics and Vascular Malformations 88

7. Open Procedures for Airway Obstruction 102
Catherine K Hart, Aliza P Cohen, Robin T Cotton
◊ Historical Overview 102
◊ Preoperative Assessment 102
◊ Preoperative Decision Making 103
◊ Expansion Surgery 105
◊ Resection Surgery 108

8. Hypoglossal Nerve Stimulation for Obstructive Sleep Apnea 114
Stefan Mlot, Rahmatullah Rahmati
◊ Physiology of the Upper Airway in OSA 114
◊ Measures of Respiratory Status Used in the Analysis of Patients with Obstructive Sleep Apnea 116
◊ The Current State of Hypoglossal Nerve Stimulation 117
◊ Future Directions 123

9. Cochlear Implants: An Update 125
Divya Chari, Maura K Cosetti, Anil K Lalwani
◊ Updates in Cochlear Implant Technology: Hardware and Software 126
◊ Developments in Device Design 128
◊ Updates in CI Candidacy and Assessment of Efficacy 134

10. Implantable Hearing Aids 149
Arnaud Devèze
◊ What are the Drawbacks of Conventional Hearing Aids that AMEI should Overcome? 151
◊ Active Middle Ear Implants 153
◊ Bone Conduction Implants 154
◊ The Different Types of Currently Available Implants and their Characteristics 156
◊ The Middle Ear Transducer (MET; Previously Otologics LLC, Boulder, CO, USA, and Now Cochlear, Australia) 159
◊ The Ideal AMEI: Discussion on Limitations and Challenge to Improve the Output and Use of Implantable Auditory Prostheses 170
◊ What are the Main Indications of AMEI Nowadays? 177
◊ What is the Preoperative Selection Workup? 177

11. Endoscopic Ear Surgery 187
Muaaz Tarabichi, Marchioni Daniele, Livio Presutti
◊ History 187
◊ Instrumentation 188
◊ Discussion 188
◊ Basic Techniques and Management Algorithm 199
◊ Transcanal Transpromontorial Exclusive Endoscopic Approach 215
◊ Transvestibular Approach 222
◊ Transcochlear Approach 225

12. Some Mechanical Aspects of Implant Coupling **234**

Albrecht Eiber, Markus HF Pfister

◊ Mechanics of Middle Ear 234
◊ Implants 236
◊ Mechanical Coupling of Implants to Natural Structures 240
◊ Clinical Aspects 249
◊ Preload 249

13. Stereotactic Radiosurgery for Acoustic Neuroma **257**

Ajay Niranjan, Edward Monaco III, Hideyuki Kano, John C Flickinger, L Dade Lunsford

◊ Gamma Knife Radiosurgery Technique for Acoustic Neuromas 258
◊ Radiosurgery: Clinical Results 260

14. Vestibular Rehabilitation **271**

Jan Hendrik Wagner, Dietmar Basta, Arne Ernst

◊ Mechanisms of Compensation of a Vestibular Loss 271
◊ Mobile Posturography 274
◊ Vestibular Rehab (Training) Programs 274
◊ Surgical Treatment of Vestibular Disorders 276
◊ Disorders of the Semicircular Canals 277
◊ Further Otological Disorders with Vertigo 278

15. Tinnitus Therapy **281**

Timea Tóth, Markus HF Pfister, Peter A Tass

◊ History of Tinnitus Medicine 281
◊ Treatments of Tinnitus 283
◊ Pharmacological Treatment 283
◊ Treatment of Chronic Tinnitus 286
◊ Hyperbaric Oxygen Therapy 288
◊ Sound Therapy (Hearing Devices) 289
◊ Tinnitus Retraining Therapy 291
◊ Cognitive Behavior Therapy 293
◊ Biofeedback and Neurofeedback 294
◊ Magnetic and Electrical Brain Stimulation 297
◊ Acoustic Coordinated Reset (CR) Neuromodulation 301
◊ Music Therapy 304

16. Geriatric Otolaryngology—An Emerging Subspecialty **313**

Karen M Kost, David E Eibling

◊ General Concepts in Geriatrics 314
◊ Geriatric Otolaryngology 317
◊ Dysphonia in the Elderly 318
◊ Dysphagia in the Elderly 320
◊ Presbycusis 324
◊ Balance in the Elderly 326

17. Genetics in Otolaryngology **332**

Nicolas Gürtler, Benno Röthlisberger

◊ Hereditary Hearing Impairment 333
◊ Oncology 341
◊ Miscellaneous 345

18. Botulinum Toxin in Otorhinolaryngology **350**

Saskia Rohrbach, Rainer Laskawi

◊ How Botulinum Toxin Acts 350
◊ Well-Established BTX Indications 351
◊ More Recent and Rare Indications 354
◊ More Recent Salivary Gland Applications 358

19. Computer-assisted Surgery of the Paranasal Sinuses and Skull Base **371**

Edgar Mauricio López-Chacón, Manuel Bernal-Sprekelsen

◊ Technical Characteristics 371
◊ Accuracy of CAS 376
◊ Indications for CAS 377
◊ Advantages and Disadvantages 378
◊ Special Features 379

Index *383*

Chapter

2

Image Guidance in Sinus Surgery

Laura Oleaga, Manuel Bernal-Sprekelsen

JAYPEE BROTHERS

INTRODUCTION

Sinonasal cavities are part of the upper respiratory tract. The most frequent pathological processes involving the paranasal sinuses are inflammatory or allergic conditions.

Tumors in this region represent 3–4% of head and neck neoplasms.[1] Imaging studies are crucial in the assessment of the anatomy and to further characterize lesions or stage tumors. The main indications for imaging the nasal cavity and paranasal sinuses are trauma, subacute, chronic or recurrent rhinosinusitis, preoperative planning for functional endoscopic sinus surgery (FEES), postoperative complications, and in the study and staging of benign or malignant tumors.

The two most important imaging procedures used to evaluate the nasal cavity and paranasal sinuses are computed tomography (CT) and magnetic resonance imaging (MRI). Plain radiographs nowadays are rarely used in patients with sinonasal disease, due to the overlapping of the anatomic structures that prevents the adequate display of important structures such as the ostiomeatal complex. High-resolution CT has replaced plain films in the initial workup of sinonasal inflammatory diseases. For the assessment of sinonasal tumors, both CT and MRI provide good complementary information.

COMPUTED TOMOGRAPHY

CT imaging is important to depict the anatomy of the most important structures in the sinonasal region and skull base. CT is more sensitive and accurate in assessing the osseous margins of the sinonasal cavity. It provides an accurate evaluation of the craniofacial bones and pneumatization of the paranasal sinuses.[1–3]

High-resolution CT provides high-quality images allowing good delineation of the local inflammatory process, detection of disease-related complications, and description of the anatomical variations that may be important

during FESS, to avoid relevant complications. Major complications include blindness due to damage of the optic nerve, cerebrospinal fluid (CSF) leak, meningitis, life-threatening hemorrhage due to internal carotid injury, orbital injury with blurred or double vision, severe bleeding from any of the ethmoidal arteries or branches of the sphenopalatine artery, and nasolacrimal duct stenosis producing epiphora.

FESS is limited to a box located between the middle turbinate, the anterior skull base, and the lamina papyracea of the orbit. The more anatomical landmarks are identified, the better the orientation and, subsequently, the risk of any complication is considerably reduced.

Critical structures to identify on CT images to guide FESS include the following:

- Cribriform plate and the depth of the olfactory fossa, as classified by Keros[4]
- Lamina papyracea to delineate the orbit
- Internal carotid artery bulging into the sphenoid sinus and its potential dehiscence
- Optic nerve: identify the exact location in relation to the sphenoid sinus or the posterior ethmoid cell (Onodi cell)
- Sphenoid sinus with all the variations in pneumatization
- Anterior ethmoidal artery

These landmarks are better demonstrated at in the coronal plane, as it offers the same direction of the surgical procedure, with the exception of the internal carotid and optic nerve bulging, that are better visualized in axial planes.

CT Technique

High-resolution axial images, parallel to the hard palate or orbitomeatal unit of the sinuses, are acquired with a spiral CT technique with a rotation time of 1s or less, using a display matrix of 512 × 512 or 1024 × 1024 pixels. Axial, coronal and sagittal 2 mm images are reformatted from the volume raw data set for soft tissue and bone algorithms.

No intravenous contrast is necessary for sinus CT unless complications of sinusitis or tumors are suspected. For contrast examination studies, 80–100 mL of iodinated contrast media, with a concentration of 300 mgr, is applied with an injection rate of 2 mL/s followed by 20 mL of saline at the same injection rate. The start delay of the scan varies between 60 and 80s in order to achieve an optimal interstitial contrast.[5]

The main concern when using CT imaging of the head and neck region is the radiation dose delivered to the lens and to the thyroid gland. Cone-beam CT systems (CBCT) have been proposed for sinus applications; however, low tissue contrast and inferior visualization of thin anatomical structures discourage its use for detection of sinonasal pathology.

JAYPEE BROTHERS

Standard CT protocols for paranasal sinuses use 140 kV and effective mAs of 100. With the new multidetector CT systems, images of diagnostic quality can be obtained using a low-dose technique at 120 kV and 40 mAs in the axial plane.[6]

The new-generation multidetector helical CT scanners provide a better spatial and contrast resolution and more dose-efficient detectors, maintaining image quality at lower mAs. Modern CT scanners have different dose reduction systems that enable modulation of the radiation dose using different reconstruction-algorithm such as filtered back-projection or iterative reconstruction.[7] Three-dimensional spiral CT data sets may be transferred directly into computer systems and thus be used in computer-assisted surgery.[8,9]

The coronal plane is the best to depict the anterior ostiomeatal complex and the level of the anterior skull base, together with the anterior ethmoidal arteries. This is the preferred plane by surgeons, as it shows the anatomy in the same direction of the surgical procedure; it provides an excellent road map of the sinus anatomy and extent of disease.[1,2,10]

The axial plane is useful for identifying the basal lamella, which divides the anterior and posterior ethmoidal sinuses,[1–3] and posteriorly the bulging of the optic nerve and the internal carotid artery. Both, coronal and axial planes, delineate the relationship of the paranasal sinuses with the orbit. The sagittal plane is useful for the evaluation of the posterior ostiomeatal complex. It provides excellent evaluation of the posterior ethmoidal air cells and the sphenoethmoidal recess.[1–3] It can be helpful to study the frontal recess. Posteriorly, also the relationship with the pituitary gland is nicely depicted in a sagittal view.

CT Anatomy

Detailed radiological study of the anatomy of the nasal cavity and paranasal sinuses is crucial before FESS. The anterior ostiomeatal complex/unit is the crossroad for the maxillary sinus, the frontal, and the anterior ethmoidal cells. It is here where the inflammatory disease initially starts, and thus it deserves special attention.

The following key anatomic structures of the anterior ostiomeatal complex and its vicinity are the ethmoid infundibulum, uncinate process, perpendicular plate and basal lamella of the middle turbinate, ethmoid bulla, nasofrontal recess, the lamina papyracea, and the fovea ethmoidalis.[10,11] The anterior ostiomeatal complex/unit includes the superomedial maxillary sinus ostium, maxillary infundibulum, uncinate process, hiatus semilunaris, ethmoid bulla, middle turbinate, and middle meatus (Fig. 2.1).

Coronal and axial planes are the most useful planes to evaluate the anterior ostiomeatal complex. The maxillary ostium is located in the superior segment of the medial maxillary wall and drains into the posterior aspect of

JAYPEE BROTHERS

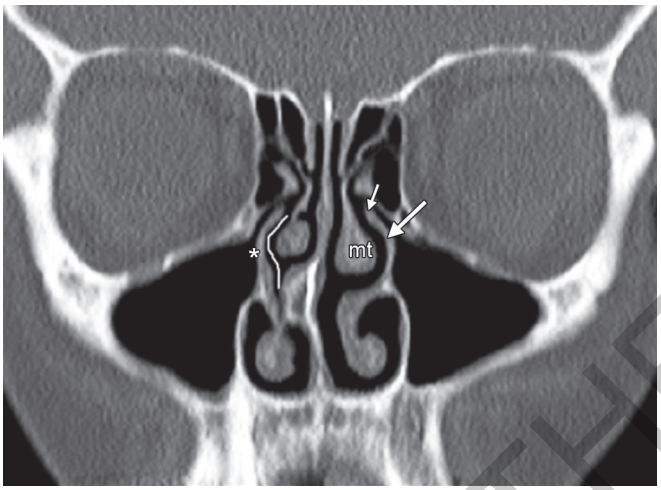

Fig. 2.1: Coronal noncontrast computed tomography (bone window). Anterior ostiomeatal unit, uncinate process (arrow), infundibulum (asterisk), hiatus semilunaris (small arrow), middle turbinate (mt), and middle meatus (white line).

the ethmoid infundibulum. The infundibulum is the tunnel that connects the maxillary sinus to the middle meatus. The limits of the infundibulum are the uncinate process medially and the inferomedial wall of the orbit laterally.

The uncinate process is a wing-shaped piece of bone. It attaches anteriorly to the posterior edge of the lacrimal bone, and inferiorly to the superior edge of the inferior turbinate. Superior attachment of the uncinate process is highly variable, may be attached to the lamina papyracea, or the roof of the ethmoidal sinus, or sometimes to the middle turbinate.[1,2,10]

The hiatus semilunaris is a semilunar region between the uncinate process and ethmoid bulla; it receives drainage from anterior ethmoid air cells and maxillary sinus via infundibulum. The ethmoid bulla is a large ethmoid air cell located at the superior aspect of the ostiomeatal complex, receives drainage from anterior ethmoid air cells. The sinus lateralis or suprabullar recess is the space between the posterior wall of the ethmoid bulla and the basal lamella.

The middle turbinate attaches superiorly to the cribriform plate via vertical lamella and posteriorly and laterally to the lamina papyracea via basal lamella. The middle meatus receives drainage from the maxillary sinus via the hiatus semilunaris, ethmoid bullae, and frontal sinus.

The frontal recess is a narrow space with a complex anatomy surrounded by various anterior ethmoidal cells (Fig. 2.2). The frontal recess is the outflow tract for frontal sinus drainage into the middle meatus.[11] It is important to have a comprehensive understanding of the anatomy of the anterior ethmoid cells: agger nasi, frontal cell, supraorbital ethmoid cell, frontal bullar cell, suprabullar cell, and interfrontal sinus septal cell to identify the frontal recess

JAYPEE BROTHERS



Fig. 2.2: Sagittal noncontrast computed tomography (bone window). Frontal sinus (fs), frontal recess (arrow), anterior ethmoid cell (asterisk), and sphenoid sinus (ss).

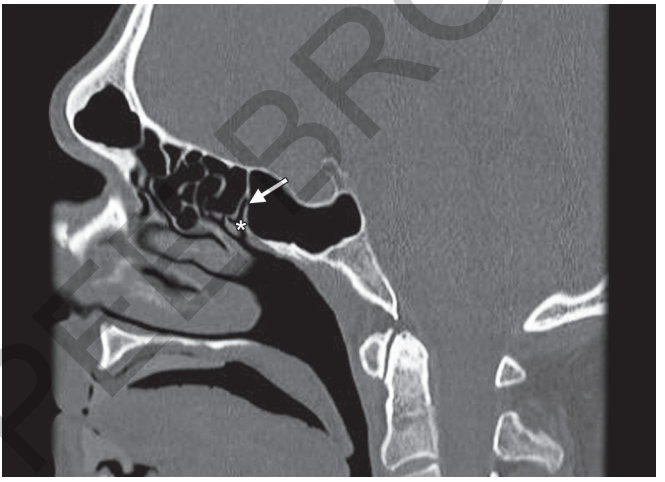

Fig. 2.3: Sagittal noncontrast computed tomography (bone window). Sphenoid sinus ostia (arrow) and sphenoethmoidal recess (asterisk).

and its pneumatization pattern.[12] Incomplete removal of cells in the frontal recess is the most common cause of failed FEES. The best imaging plane to analyze the frontal recess is the sagittal reconstruction plane.

The posterior ostiomeatal complex/unit includes the sphenoid sinus ostium, sphenoethmoidal recess, and posterior ethmoid cells. It is the region of drainage of the sphenoid sinus and posterior ethmoid cells into the sphenoethmoidal recess that drains into the superior meatus of the nose (Fig. 2.3). The sphenoid sinus ostium is found at the anterosuperior portion of the sphenoid sinus and it is better seen in the axial and sagittal planes.[1,2,10]

JAYPEE BROTHERS



Fig. 2.4: Axial noncontrast computed tomography (bone window). Image demonstrates both pterygopalatine fossae (arrows) back to the posterior wall of maxillary sinuses.

The pterygopalatine fossa (PPF) is an important, strategic, anatomic space, which communicates the middle cranial fossa, orbital, nasal and oral cavities, pharynx, foramen lacerum, and the infratemporal fossa (Fig. 2.4). There are a large number of fissures and canals communicating with the PPF: the inferior orbital fissure, the foramen rotundum (Fig. 2.5), the vidian canal (Fig. 2.6), the sphenopalatine foramen, the pterygomaxillary fissure, the greater pterygopalatine canal, the lesser pterygopalatine canal, and the palatinovaginal or pharyngeal canal.[4,13] It represents a major pathway of spread of malignancy and infection in the deep face.

Normal Anatomic Variants

A large number of anatomical variants can narrow the sinus drainage pathways and limit surgical access. It is important to recognize those anatomical variants when reading CT images.[1,2,11,14] Nasal septum variants, deviations, or spurs may involve the middle meatus.

Concha bullosa: Aeration of middle turbinate is seen in 4–15% of the population. Large concha bullosa can narrow the middle meatus (Fig. 2.7).

Uncinate process: Pneumatization of the uncinate process may result in anatomic narrowing of the infundibulum. The uncinate process might be deviated medially obstructing the middle meatus or laterally obstructing the infundibulum. Lateral deviation of the uncinate process can increase the risk of medial orbital wall injury during uncinectomy.

Anterior ethmoidal bulla: When enlarged can narrow or obstruct the middle meatus and infundibulum (Fig. 2.8).

JAYPEE BROTHERS



Fig. 2.5: Axial noncontrast computed tomography (bone window). Pterygopalatine fossa (asterisk) communicates with foramen rotundum (arrow).

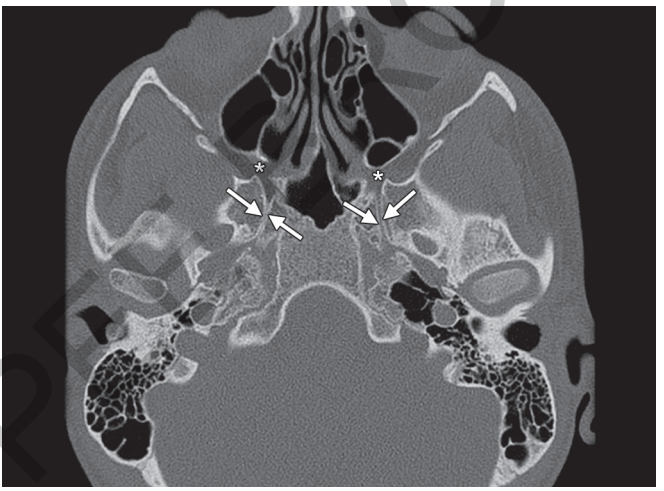

Fig. 2.6: Axial noncontrast computed tomography (bone window). Pterygopalatine fossa (asterisks) communicates with vidian canal (arrows).

Agger nasi air cell: The most anterior ethmoid cell, lateral to lamina papyracea, adjacent to frontal recess. The frontal recess can be narrowed by enlargement of the agger nasi cell (Fig. 2.9).

Frontal cell: Anterior ethmoid cell above the agger nasi cell. Its enlargement can produce narrowing of the frontal recess.

Haller cells: Ethmoidal cells extending along the medial floor of the orbit. When they enlarge may cause narrowing of the infundibulum (Fig. 2.10).

JAYPEE BROTHERS

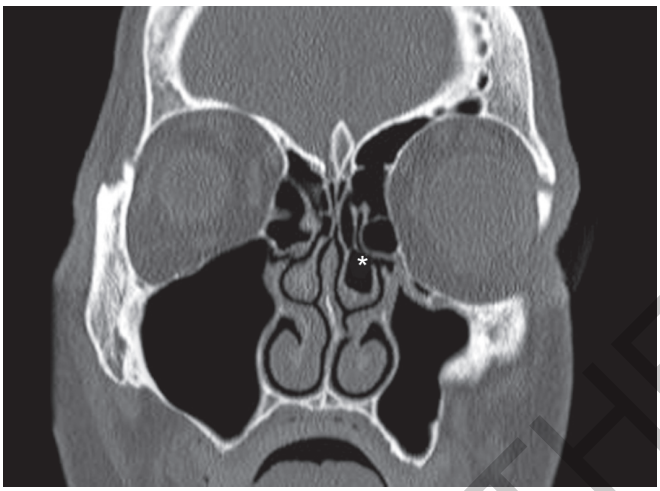

Fig. 2.7: Coronal noncontrast computed tomography (bone window). Pneumatized left middle turbinate (asterisk) 'concha bullosa'.



Fig. 2.8: Coronal noncontrast computed tomography (bone window) through the ethmoid sinuses. Anterior ethmoid bulla (asterisk) and anterior ethmoid air cells (arrow).

Onodi cells: The most posterior ethmoidal cells that extend posterolaterally and surround, at least partially, the optic canal. The lateral lamella represents the segment of bone lateral to the attachment of middle turbinate and medial to the roof of the ethmoid or fovea ethmoidalis. It is the thinnest part of the cribriform plate and at risk of fracture during FES (Fig. 2.11). The appearance of the cribriform plate has been classified into Keros types 1–3 according to the depth that it extends into the nasal cavity.[4] The risk of

JAYPEE BROTHERS

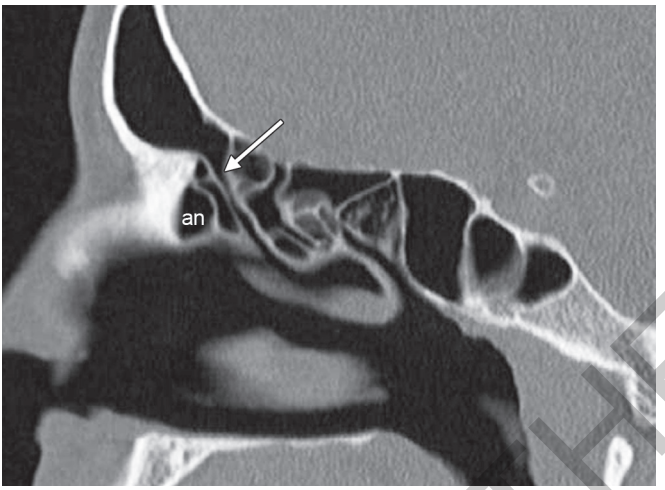

Fig. 2.9: Sagittal noncontrast computed tomography (bone window). Agger nasi cell (an), most anterior ethmoid cell, and frontal recess (arrow).



Fig. 2.10: Coronal noncontrast computed tomography (bone window). Haller cell located lateral to maxillary infundibulum inferolateral to the orbit (asterisk).

perforating the cribriform plate during FESS increases when the olfactory fossae are deep or asymmetric.

Medial deviation or dehiscence of the lamina papyracea: The anterior ethmoidal artery runs through a bone canal in the superior lamina papyracea and serves as a surgical landmark. It can be identified on coronal CT images. It emerges between the medial rectus muscle and the superior oblique muscle in a kind of pyramid. It is usually located at the insertion of the anterior wall of the ethmoidal bulla or behind. When it courses through the ethmoidal

JAYPEE BROTHERS

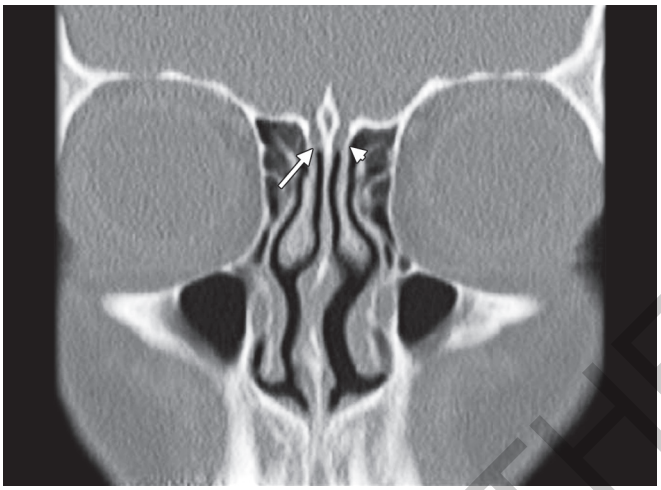

Fig. 2.11: Coronal noncontrast computed tomography (bone window). Fovea ethmoidalis (arrow), lateral lamella (arrowhead).

air cells, can be inadvertently injured. Penetration of the lamina papyracea during FESS can also cause orbital injury.

Extensive pneumatization of the sphenoid sinus: Bone dehiscence of the sphenoidal walls can produce a bulging of the optic or carotid canals and places them at risk of injury during surgery.

CT Indications

CT is the imaging modality of choice for evaluation of inflammatory rhinosinusitis and preoperative planning of FEES. CT is used mainly to assess the extent of the disease, characterize bone lesions, identify bone involvement, and serve as a surgical road map to check for normal anatomy and potential anatomic variants that can affect surgery.

CT is useful in the evaluation of FESS complications. Complications after FESS include orbital hematoma, emphysema, and abscess. Other complications associated with FESS include interruption of the lamina papyracea usually at the site of attachment of the basal lamella; orbital fat can be herniated into the ethmoid sinus.

Diplopia is one of the major orbital complications usually caused by extraocular muscle damage due to direct muscle injury. The most commonly injured extraocular muscle is the medial rectus muscle, followed by the inferior rectus muscle and superior oblique muscle.

Intracranial complications include CSFs leak, intracranial bleed, and cerebritis. CT can provide helpful information to assess the integrity of the cribriform plate, lateral lamella, fovea ethmoidalis, and anterior cranial fossa.

JAYPEE BROTHERS

MAGNETIC RESONANCE IMAGING

MRI provides better soft tissue contrast and the possibility of acquiring the images in multiple different planes. An important advantage of MRI over CT is the absence of artifacts due to dental filling. The most important disadvantage is the long imaging time required when comparing with CT. It is the study of choice in cases of intracranial extension of infection or tumors and for perineural infiltration assessment.[15–18]

MRI Technique

MRI studies are obtained using the head coil or a head and neck coil as a receiver, with a slice thickness of 2–4 mm and acquisition matrix of 256 × 256. Contrast-enhanced images are acquired with a paramagnetic contrast media gadolinium diethylenetriaminepenta-acetic acid (Gd-DTPA), dosage of 0.2 mmol/kg body weight.

The recommended MRI protocol includes axial, coronal, and sagittal noncontrast T1-weighted images, axial diffusion-weighted images, axial and coronal noncontrast T2-weighted images, and postcontrast gadolinium-enhanced axial, coronal, and sagittal T1-weighted images with fat suppression.[19,20] Coronal and sagittal planes allow assessment of craniocaudal tumor extension. Imaging should include the paranasal sinuses, the orbits, skull base, and adjacent intracranial structures.

MRI Indications

MRI is better than CT for separating tumor from inflammatory mucosal disease and retained secretions increasing the staging accuracy.[16,17,19] Sinonasal secretions demonstrate low signal intensity on T1-weighted images and high signal intensity on T2-weighted images. In chronic secretions, the signal intensity may vary depending on the protein concentration and the extent of free water resorption.[16,17] As the protein content increases up to 25% in an obstructed sinus, the signal intensity on T1-weighted images becomes high and remains high on T2-weighted images. Above 25% protein concentration, both T1- and T2-weighted signal intensities decrease (Fig. 2.12). MRI is indicated for sinonasal tumors staging before surgery to determine resectability and define optimal surgical approach.[20]

Tumors display low signal intensity on T1-weighted images and higher signal intensity than muscle on T2-weighted images and enhance after gadolinium injection.[21] MRI provides good delineation of the tumor, assessment of the extension, and involvement of adjacent structures, such as the skull base, the anterior and middle cranial fossa, orbits, paranasal soft tissues, palate, infratemporal fossa, and PPF (Fig. 2.13). It is more sensitive to evaluate skull base invasion and to depict perineural spread.[21]

JAYPEE BROTHERS

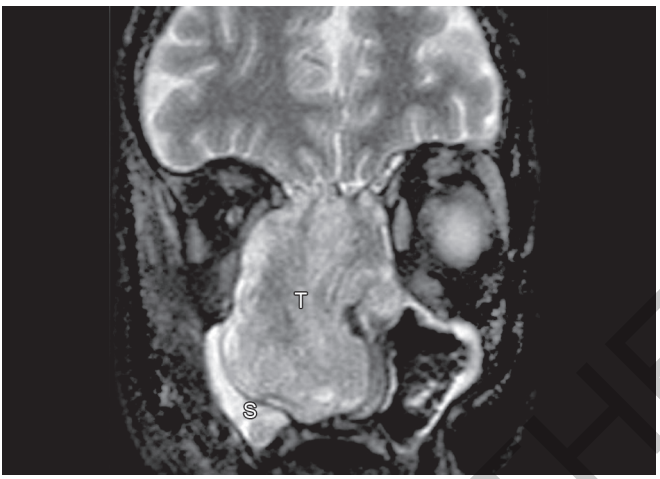

Fig. 2.12: Coronal T2-weighted magnetic resonance imaging allows separating the high signal intensity secretions in the right maxillary sinus (S) from tumor (T).

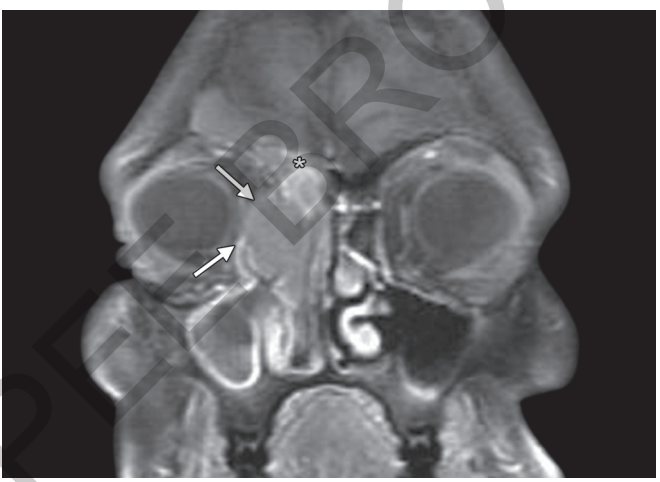

Fig. 2.13: Coronal T1-weighted gadolinium-enhanced fat suppression magnetic resonance imaging. Sinonasal undifferentiated carcinoma, orbital (arrows), and cribriform plate (asterisk) invasion.

MRI is more sensitive than CT to depict perineural spread. Postcontrast images with fat suppression are crucial to demonstrate perineural infiltration.[22] Certain tumors can be characterized by its MRI appearance. Hemangiomas of the nasal cavity are well-defined masses with high signal intensity on T2-weighted images, and hemorrhage. Inverted papillomas have a characteristic convoluted cerebriform pattern on MRI (Fig. 2.14). MRI is the imaging of choice in aggressive sinonasal inflammatory diseases (aggressive bacterial sinusitis, fungal sinusitis, Wegener's granulomatosis) that spread to the skull base, brain, orbit, or cavernous sinus (Fig. 2.15).

JAYPEE BROTHERS

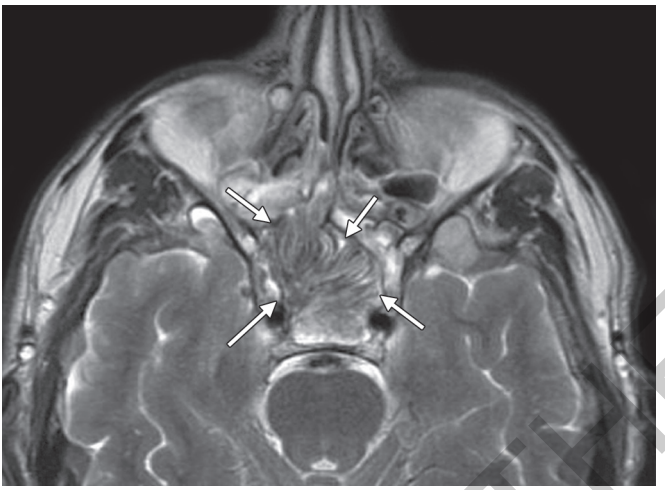

Fig. 2.14: Axial T2-weighted magnetic resonance imaging inverted papilloma demonstrating a characteristic convoluted cerebriform pattern (arrows).

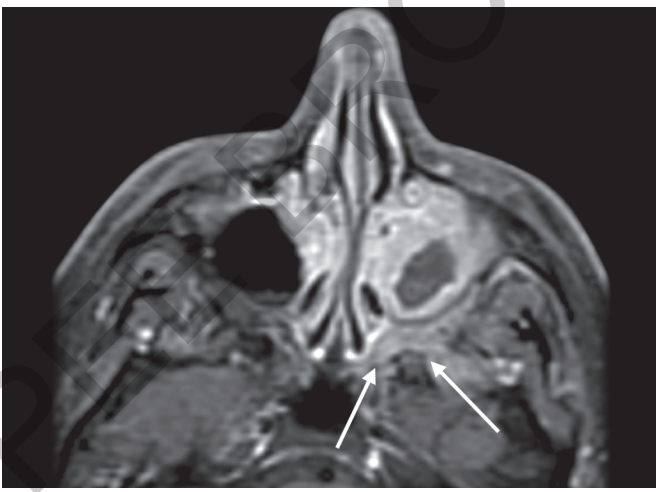

Fig. 2.15: Axial T1W gadolinium-enhanced fat suppression magnetic resonance imaging fungal sinusitis involving the left maxillary sinus with invasion of the pterygopalatine fossa (arrows).

JAYPEE BROTHERS

REFERENCES

1. Hoang JH, Eastwood JD, Tebbit CL, et al. Multiplanar sinus CT: a systematic approach to imaging before functional endoscopic sinus surgery. AJR. 2010; 194:527–36.
2. Lame1 FJ, Smoker WR. The ostiomeatal unit and endoscopic surgery: anatomy, variations, and imaging findings in inflammatory diseases. AJR. 1992;159: 849–57.

3. Anzai J, Yueh B. Imaging evaluation of sinusitis: diagnostic performance and impact on health outcome. Neuroimag Clin N Am. 2003;13:251–63.
4. Rudmik L, Smith TL. Evaluation of the ethmoid skull base height prior to endoscopic sinus surgery: a preoperative CT evaluation technique. Int Forum Allergy Rhinol. 2012;2:151–4.
5. Sievers KW, Greess H, Baum U, et al. Paranasal sinuses and nasopharynx CT and MRI. Eur J Radiol. 2000;33:185–202.
6. Zammit-Maempel I, Chadwick CL, DCR(R), et al. Radiation dose to the lens of eye and thyroid gland in paranasal sinus multislice CT. Br J Radiol. 2003;76: 418–20.
7. Willemink MJ, de Jong PA, Leiner T, et al. Iterative reconstruction techniques for computed tomography Part 1: technical principles. Eur Radiol. 2013;23: 1623–31.
8. De Nicola M, Salvolini L, Salvolini U. Virtual endoscopy of nasal cavity and paranasal sinuses. Eur J Radiol. 1997;24:175–80.
9. Dearking AC, Pallanch JF. Mapping the frontal sinus ostium using virtual endoscopy. Laryngoscope. 2012;122:2143–7.
10. Rao VM, El-Noueam KI. Sinonasal imaging. Radiol Clin N Am. 1998;36:921–39.
11. Daniels DL, Mafee MF, Smith MM, et al. The frontal sinus drainage pathway and related structures. AJNR. 2003;24:1618–27.
12. Park SS, Yoon BN, Cho KS, et al. Pneumatization pattern of the frontal recess: relationship of the anterior-to-posterior length of frontal isthmus and/or frontal recess with the volume of Agger nasi cell. Clin Exp Otorhinolaryngol. 2010;3: 76–83.
13. Daniels DL, Mark LP, Ulmer JL, et al. Osseous anatomy of the pterygopalatine fossa. AJNR. 1998;19:1423–32.
14. Martinez Del Pero M, Philpott C. A useful tool – systematic checklist for evaluating sinus scans. Clin Otolaryngol. 2012;37:82–4.
15. Loevner LA, Sonners AI. Imaging of neoplasms of the paranasal sinuses. Magn Reson Imaging Clin N Am. 2002;10:467–93.
16. Hartman MJ, Gentry LR. Aggressive inflammatory and neoplastic processes of the paranasal sinuses. Magn Reson Imaging Clin N Am. 2012;20:447–71.
17. Mossa-Basha M, Blitz AM. Imaging of the paranasal sinuses. Semin Roentgenol. 2013;48:14–34.
18. Walden MJ, Aygun N. Head and neck cancer. Semin Roentgenol. 2013;48:75–86.
19. Tomura N, Hirano H, Kato K, et al. Comparison of MR imaging with CT in depiction of tumour extension into the pterygopalatine fossa. Clin Radiol. 1999;54:361–6.
20. Shah GV, Nancy J, Fischbein NJ, et al. Newer MR imaging techniques for head and neck. Magn Reson Imaging Clin N Am. 2003;11:449–69.
21. Jégouxa F, Métreaua A, Louvelb G, et al. Paranasal sinus cancer. In press. European Annals of Otorhinolaryngology Head and Neck diseases (2013), http://dx.doi.org/10.1016/j.anorl.2012.07.007
22. Lawrence E, Ginsberg LE. MR imaging of perineural tumor spread. Neuroimag Clin N Am. 2004;14:663–77.

JAYPEE BROTHERS

for detailed information on otolaryngology books, visit our website www.jaypeebrothers.com, for detailed information on otolaryngolo

Recent Advances in Otolaryngology Head & Neck Surgery

The 21st century Otolaryngologist is fortunate to practice in an era of technological and technical advance unprecedented in the history of medicine. The pace of new knowledge very quickly leaves our prior training obsolete: the half life of medical knowledge is now under five years. From the newest techniques for treatment of CSF leak, sleep apnea, vascular anomalies and airway obstruction to personalized treatment for head and neck cancer and the emergence of the new subspecialty of geriatric otolaryngology, the Otolaryngologist is struggling to stay abrest of innovations that directly impact patient care. *Recent Advances in Otolaryngology—Head and Neck Surgery,* 3rd volume, has been designed to meet the need of the busy practicing clinician to efficiently keep current with what is new in each of the subspecialties of Otolaryngology. All of the chapters have been contributed by leading experts in the field. Due to its rapid publication cycle, the material is current, topical, and immediately relevant to the clinician.

Key Features

- Robotics in Sleep Apnea
- Image Guidance in Sinus Surgery
- Endoscopic Surgery for CSF Leaks
- Personalized Therapy for Head and Neck Cancer
- Hypoglossal Nerve Stimulation for Obstructive Sleep Apnea
- Endoscopic Ear Surgery

What is different in this book compared to competitions

- It covers all the subspecialties of Otolaryngology.
- Rapid publication cycle—less than 6 months from submission of manuscript to publication to ensure that content is current.
- Clear artwork rendered in color to convey new concepts and surgical approaches.
- Outstanding international editorial board.



Anil K Lalwani MD is Professor and Vice-Chair for Research in the Department of Otolaryngology at Columbia University College of Physicians and Surgeons, New York, NY, USA, where he is Director of Division of Otology, Neurotology and Skull Base Surgery and Director of the Columbia Cochlear Implant Program. Doctor Lalwani's basic research has focused on two key areas: identifying genes that are critical for hearing through the use of molecular genetic and molecular biologic methods, and developing and investigating gene transfer technology for the treatment of hearing disorders. His clinical interests in otology include cochlear implantation, chronic ear disease, facial nerve disorders, cerebellopontine angle tumors (e.g. acoustic neuromas), and skull base surgery. Dr Lalwani is considered one of the leading experts on hearing loss in children and adults and its surgical treatment. He is the author of more than 175 peer-reviewed articles, numerous book chapters, and a textbook defining the subspecialty of Pediatric Otology and Neurotology. The 3rd edition of his second book, *Current Diagnosis & Treatment in Otolaryngology—Head & Neck Surgery* has recently been published.



Markus HF Pfister MD is an Otolaryngologist with subspecialization in Otology and Neurotology. He has been trained at the University of Tuebingen, Germany, University of California, San Francisco and Stanford University, USA, and he is academically affiliated with the University of Tuebingen, Germany. He has been responsible for the molecular genetics unit of hereditary hearing impairment at the Department of Otolaryngology, University of Tuebingen, Germany, and has been a member of the European Work Group on Genetics of Hearing Impairment. Dr Pfister's interests include innovative approaches in the diagnosis and therapy of disorders in otolaryngology and head and neck surgery, particularly in otology and neurotology. He is considered a leading expert on hereditary hearing loss and has contributed to several international studies on hereditary hearing impairment. He is author of more than 80 peer-reviewed articles and numerous book chapters.

Available at all medical book stores
or buy directly from Jaypee Brothers through online shopping
at www.jaypeebrothers.com

JAYPEE BROTHERS
Medical Publishers (P) Ltd.
www.jaypeebrothers.com

Shelving
Recommendation
OTOLARYNGOLOGY

ISBN 978-93-5152-145-7