ebrothers.com, for detailed information of otolaryngology books, visit our website www.jaypeebrothers.com, for detailed information of otolaryngology book

JAYPEE

ENDOSCOPIC ENDONASAL SURGERY

SINUSES & BEYOND

Editor
Milind V Kirtane



Foreword
MV Ingle

Contents

1. Lateral Nasal Wall **1**
Renuka Bradoo
Overview 1; Vestibule and Atrium 1; Turbinates 2; Ostiomeatal Unit 2; Maxillary Ostium 2; Frontal Recess 3; Ethmoid Labyrinth 3; Sphenoethmoidal Recess and Sphenoid Sinus 4

2. Endoscopic Surgical Anatomy **5**
Renuka Bradoo
Diagnostic Endoscopy 5; Turbinates 6; Dissection of Frontal Recess 7; Dissection of the Ethmoid Sinus and the Ostiomeatal Unit 7; Dissection of Posterior Ethmoid Cells 9; "Wandering" Cells 10; Dissection of Sphenoid Sinus 10

3. Imaging for Paranasal Sinuses **12**
Nishit J Shah, Sunita Kanojia
Pre-FESS CT Checklist 12; How to Approach CT Scan Reading? 13

4. Preoperative Preparation of Functional Endoscopic Sinus Surgery **19**
Arpit Sharma
Indications of Surgery 19; Goals of Surgery 19; Patient Management before Surgery 20; Postoperative Management 20

5. Postoperative Management after Functional Endoscopic Sinus Surgery **22**
Siddharth Chaudri
Need for Postoperative Care 22; Patient Counseling and Advice 23; Resuming Activities 23; Nasal Irrigation 24; Medical Treatment 24; Cleaning and Debridement 25

6. Endoscopic Ethmoid Sinus Surgery **27**
Anagha Joshi
Indications of Ethmoidectomy 27; Presurgical Considerations 27; Steps of Ethmoidectomy 27; Revision Surgery 30; Cleaning and Packing 31; Mucosal Preservation and Prevention of Adhesions 31; Optimizing the Surgical Field 32; Management of Complications 32; Postoperative Care 33

7. Endoscopic Surgery for the Frontal Sinus **35**
Abhineet Lall, Milind V Kirtane
Embryology 35; Endoscopic Anatomy 35; Other Factors Affecting the Frontal Sinus Outflow Tract 38; Pathologies Affecting the Frontal Sinus 38; Imaging for the Frontal Sinus 39; Magnetic Resonance Imaging 40; Approaches to the Frontal Sinus 40; Endonasal Frontal Sinus Surgery Type I–III 41; Frontal Sinus Trephination 42; Stenting in the Frontal Recess 44

8. Endoscopic Maxillary Sinus Surgery **47**
Milind Navalakhe
History 47; Anatomy 47; Pneumatization and Growth 48; Clinical Anatomy 48; Physiology of Sinus Drainage 48; Pathology 48; Clinical Features of Rhinosinusitis 48; Medical Management of Rhinosinusitis 49; Preoperative Evaluation of Patient 49; Indications of Maxillary Sinus Surgery 49; Preoperative Preparation of Patient 49; Steps of Surgery 49; Tips for Complete Clearance of Antrochoanal Polyp 50; Postoperative Care 50; Complications 50; Difficulties Arising in Endoscopic Maxillary Sinus Surgery 50

9. Approach to the Sphenoid Sinus **51**
Nishit J Shah, Rahul P Tejankar
Anatomy 51; Surgical Approaches 52; Pathologies 55; Complications of Sphenoid Surgery 55; Landmarks and Precautions during Sphenoid Surgery 57; Sphenoid as a Route 58

10. Sinonasal Polyposis **59**
Sujata Muranjan
Pathophysiology and Theories 59; Other Diseases Associated with Nasal Polyposis 60; Symptoms 62; Signs 62; Differential Diagnosis 63; Investigations 63; Medical Management 64; Recurrence 66

11. Rhinosinusitis **68**
Arpit Sharma, Shraddha Deshmukh, JP Dabholkar
Definition 68; Duration of the Disease in Adults 68; Acute Rhinosinusitis 68; Chronic Rhinosinusitis 71

12. Invasive Fungal Sinusitis **76**
Kashmira Chavan, Gauri Mankekar, Bachi Hathiram, Milind V Kirtane
Classification 76; Microbiology 77; Pathogenesis 77; Clinical Features 77; Investigations 78; Treatment 80; Prognosis 82

13. Instrumentation in Functional Endoscopy Sinus Surgery **84**
Samir Bhargava
Operation Theater Layout 84; Endoscopes 84; Camera 85; Suction Tips 85; Sickle Knife 85; Freer Elevator 86; Ball Probes 86; Curettes: Straight and Curved Curettes 86; Blakesley Forceps 86; Through-Cutting Instruments: Rhinoforce Blakesley 87; Tobey Reverse Cutting Forceps and Stammberger Antrum Punch 87; Stammberger Mushroom Punch 88; Kerrison Punch 88; Bellucci Scissors 88; Heuwieser Antrum Grasping Forceps 88; Giraffe Forceps (Kuhn) 88; Stammberger Side-Biting Punch Forceps 89; Microdebrider Power Shavers 89; Nasal Packing 89; Dissolvable Nasal Packing 90; Suction Diathermy 90; Balloon Catheter 90; Image-Guidance Systems 91; Procedure 91

14. Endoscopic Sinus Surgery in Orbital Lesions **93**
Hetal Marfatia Patel
Endoscopic Approach 93; Orbital Abscess 94; Orbital Decompression of Graves' Orbitopathy 94; Orbital Hematoma 95; Blow Out Fracture of the Orbit 95; Foreign Body of the Orbit 96; Orbital Tumor 96; Endoscopic Assisted Orbital Lesion 97; Tips and Pearls 98; Limitations 98

15. Endoscopic Decompression for Post-traumatic Optic Neuropathy **100**
Milind V Kirtane, Roshni Nambiar
Historical Aspects 100; Surgical Anatomy 100; Pathophysiology 101; Preoperative Work-up 101; Ophthalmic Examination 101; Imaging 102; Medical Therapy 102; Surgical Management 102; Complications 103

16. Endoscopic Dacryocystorhinostomy **105**
Milind Navalakhe
History 105; Anatomy 105; Endoscopic Anatomy 106; Physiology of Lacrimation 107; Clinical Features of Dacryocystitis 107; Diagnostic Nasal Endoscopy 107; Preoperative Patient Preparation 109; Anesthesia 109; Steps of Surgery 109; Challenges Faced in Surgery 109; Steps to Enhance Success Rates in Endoscopic Dacryocystorhinostomy 110; Pack Removal and Treatment 110; Stent Removal and Results 110; Advantages of Endoscopic Dacryocystorhinostomy 110; Complications 110

17. Endoscopic Management of Epistaxis **112**
Sujata Muranjan
Anatomy 112; Causes of Epistaxis 114; Pathophysiology 114; Management 114; Endoscopic Electrocauterization 116; Endoscopic Ligation of Sphenopalatine Artery 117

18. Juvenile Nasopharyngeal Angiofibroma **119**
Renuka Bradoo, Milind V Kirtane, Anagha Joshi
Epidemiology 119; Etiopathogenesis 119; Pathology 120; Mode of Spread 120; Classification 121; Blood Supply 121; Clinical Features 121; Diagnosis 122; Treatment 123; Complications 125; Prognosis 125

19. Pituitary Tumors **127**
Nishit J Shah, Chandrashekhar E Deopujari, Gauri M Kapre
Epidemiology 128; Clinical Features 128; Mass Effect of Tumor 129; Investigations 129; Management 130; Equipment 133; Anesthesia and Position 133; Surgical Technique 133; Complications 137; Other Lesions in the Pituitary 139; Malignant Tumors of the Pituitary 140

20. Endoscopic Approach to Sinonasal and Anterior Skull-base Tumors **141**
Prathamesh S Pai
Progress 141; Biology of Tumors 142; Evaluation 142; Treatment 143; Why Transnasal Surgical Access? 143; Is Endonasal Access Suitable? 144; Contraindications 144; Debate: Endoscopic Surgery Versus Conventional Surgery 147; Author's Experience 147

21. Endoscopic Management of Cerebrospinal Fluid Rhinorrhea **150**
Milind V Kirtane, Hetal Marfatia Patel, Kashmira Chavan, Dhruv Satwalekar
Historical Aspects 150; Pathophysiology 150; Clinical Presentation 152; Management 153; Conservative Management 155; Surgical Management 155; Postoperative Care 160; Postoperative Complications 160

22. Complications of Endoscopic Sinus Surgery **163**
Satish Jain, Gaurav Shankar Medikeri
Classification of Complications of Endoscopic Sinus Surgery 163; Risk Factors for Complications in Endoscopic Sinus Surgery 163; Orbital Complications 163; Prevention of Orbital Complications 168; Intracranial Complications in Endoscopic Sinus Surgery 170; Intranasal Complications of Endoscopic Sinus Surgery 176; Pearls and Perils for Safe Endoscopic Sinus Surgery 177

23. Image-guided Sinus Surgery **180**
TN Janakiram
History 180; Technology and Practical Use 180; Steps to Get Started with the Navigation System 181; Clinical Indications for Navigation Surgery 181; Surgical Advantages 182; Limitations 182

24. Nasal Packing Materials **183**
Siddharth Chaudri
Nonabsorbable Nasal Packing Materials 183; Absorbable Nasal Packing Materials 184; Newer Absorbable Nasal Packs 185

25. Revision Endoscopic Sinus Surgery **188**
Milind V Kirtane, Swapna Patil, Sharmela Sondhi
Indications for Revision Sinus Surgery 188; Diagnosis and Preoperative Evaluation 189; Techniques of Revision Surgery 190; Postoperative Care 196

26. Balloon Sinuplasty **198**
Nishit J Shah
Balloon Sinuplasty System 198; Procedure 200; Clinical Studies for Safety and Efficacy 202; Recent Advances 204

27. Pediatric Endoscopic Sinus Surgery **205**
Hetal Marfatia Patel
Antrochoanal Polyp 205; Ethmoidal Polypi 206; Meningocele 206; Deviated Nasal Septum 207; Congenital Dacryocystocele 207; Choanal Atresia (CA) 208; Juvenile Angiofibroma 208; Hemangioma 208; Nasal Glioma 208; Preoperative Work-up 209; Anesthesia 209; Instruments 209; Tips and Pearls 209

28. Imaging of Paranasal Sinuses Pathologies **211**
Abhijit A Raut, Prashant S Naphade
General Considerations 211; Common Pathological Conditions 213; Benign Sinonasal Neoplasms 220; Malignant Sinonasal Neoplasms 224

Index *229*

CHAPTER 2

Endoscopic Surgical Anatomy

Renuka Bradoo

"Operate on the cadaver with as much patience and meticulousness as though it were a live patient"

INTRODUCTION

The cornerstone of every safe and effective surgery is a sound knowledge of the normal anatomy and all its variations.

An exhaustive discussion of the anatomy of the lateral nasal wall as well as endoscopic anatomy of paranasal sinuses is beyond the scope of this chapter. I have therefore endeavored to present the most salient features in "bite size" capsules for ready practical references.

DIAGNOSTIC ENDOSCOPY

A thorough preoperative endoscopy not only helps to establish an overview of the area to be operated but also creates a muscle memory of the angle and trajectory in which the instruments can be easily introduced in a particular patient.

It consists of three basic passes to be carried out in a sequential manner so that no key area is missed in preoperative evaluation.

First Pass

The endoscope is passed along the floor of the nose between the inferior turbinate and the septum up to the nasopharynx (Fig. 2.1). This is usually the roomiest part of the nasal cavity. The inferior turbinate tends to have a large bulbous anterior end which tapers posteriorly to end at the posterior choana just in front of the eustachian tube orifice. The septum may show various cartilaginous and bony deviations or spurs. The roof of the posterior choana has a submucosal plexus of vessels called the Woodruff's plexus. On entering the nasopharynx one can visualize the adenoids and the opening of eustachian tube guarded by the torus tubarius, behind which lies the fossa of Rosenmüller. A 30° angled telescope can be used to visualize the opposite eustachian tube and fossa of Rosenmüller.

Second Pass

The scope is then withdrawn into the nose and tilted upwards along the roof of the posterior choana to visualize the sphenoethmoidal recess. The superior turbinate and the ostium of the sphenoid sinus can be visualized. The roof of the posterior choana, septum and the superior turbinate form an anatomical triad which help locate the sphenoid ostium. The ostium is placed close to the septum 1–1.5 cm above the roof of the posterior choana and is partially overhung by the superior turbinate (Fig. 2.2).

Third Pass

The third pass enables us to look into the structures within the middle meatus, the ostiomeatal unit. The middle meatus

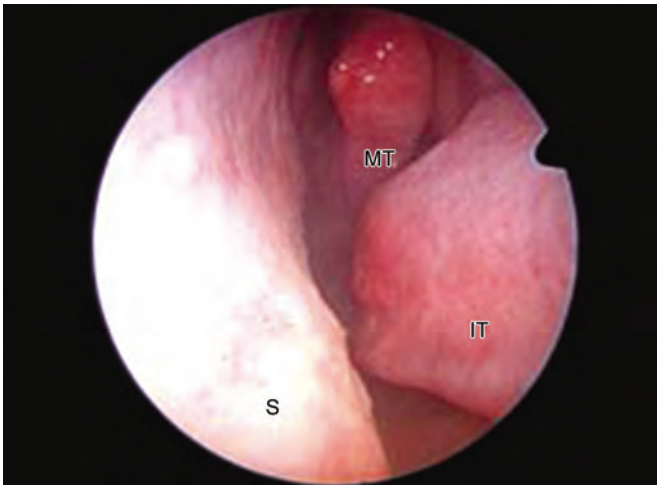

Fig. 2.1: First pass
(S-Septum, MT-Middle turbinate, IT-Inferior turbinate)

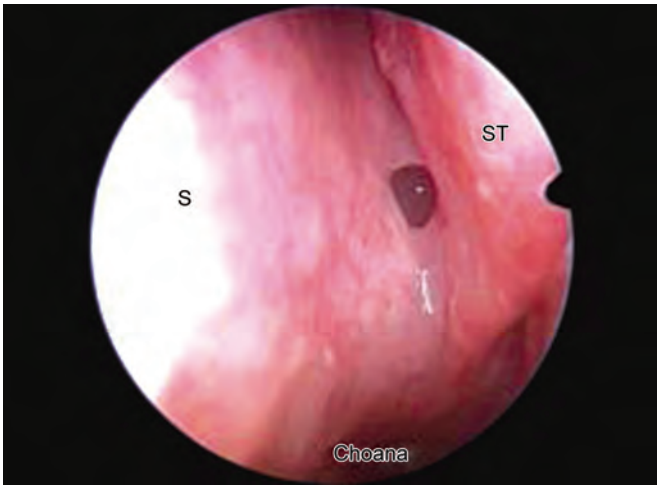

Fig. 2.2: Second pass
(S-Septum, ST-Superior turbinate)

can be entered by retracting the middle turbinate gently. If the anterior end of the middle turbinate is bulbous and rigid, the scope can be rolled into the posterior part of the middle meatus from under the inferior edge of the middle turbinate and then withdrawn gradually to view the various structures of the middle meatus. The two main structures seen within the middle meatus are the uncinate process and the bulla ethmoidalis (Fig. 2.3). Between the two is a crescentic slit called the hiatus semilunaris inferioris. One can trace the inferior margin of the middle turbinate backward to see it turn laterally behind the bulla to attach to the lamina papyracea. This is the ground lamella.

Two other areas need to be viewed on diagnostic endoscopy. The first is the atrium, which is a relatively featureless area anterior to the middle turbinate. It shows two important anatomical landmarks. The first is the area anterior and anterosuperior to the axilla of the middle turbinate. This is the region of the lacrimal sac. If the lacrimal bone is pneumatized, then an agger nasi cell may be present which then presents as a distinct bulge in the region. The lacrimal sac extends up to at least 5–7 mm above the axilla of the middle turbinate. The second landmark is the maxillary line, which is a linear prominence extending from the bulge of the agger cell up to the peak of the attachment of the inferior turbinate to the lateral nasal wall. This line indicates the location of the nasolacrimal duct.

The second area to be examined, if possible, is the inferior meatus. The nasolacrimal duct opens in the lateral wall of the inferior meatus and is guarded by a mucosal fold, the Hasner's valve.

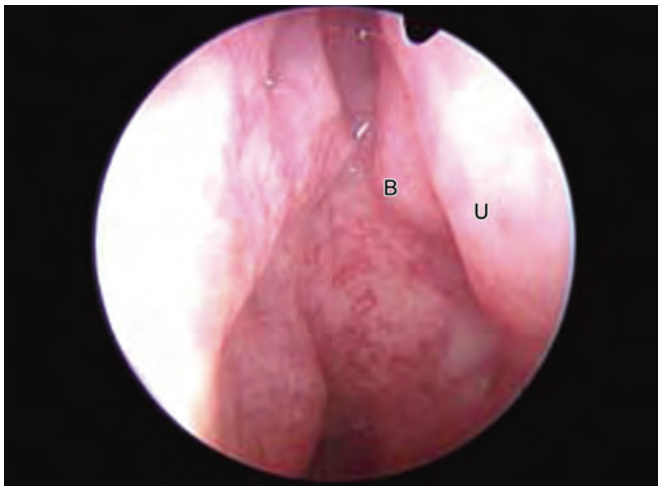

Fig. 2.3: Third pass (U-Uncinate process, B-Bulla ethmoidalis)

TURBINATES

The inferior turbinate is a separate bone unlike the superior and middle turbinate which are parts of ethmoid bone. It is relatively straight in an anteroposterior direction. Its line of attachment to the lateral nasal wall however shows a peak or inverted "V" at the junction of anterior and middle third. This is the region at which the nasolacrimal ducts passes into the inferior meatus. The duct however does not open at the apex of the inferior meatus but runs submucosally a few mm to open in the lateral wall of the inferior meatus as stated earlier.

The anatomy of middle turbinate is easier to understand if one thinks of it as a dried-up leaf bent in various directions. The first attachment is in the sagittal plane to the cribriform plate more precisely, at the junction of the medial and lateral lamellae of the cribriform plate. It is less frequently documented that the anterior most 2–3 mm however does not attach to the cribriform plate but to the frontonasal process of the maxilla. The second attachment is in the coronal plane to the lamina papyracea, the ground lamella (the superior

turbinate as well as the supreme turbinate, if present, have similar ground lamellae). The third attachment is in the horizontal plane along the perpendicular plate of the palatine bone extending up to the roof of posterior choana.

Middle Turbinate

It may show different anatomical variations:

- Quite commonly it may be ballooned out due to an air cell enclosed within it. This air cell may be pneumatized from the frontal recess, agger nasi cell or anterior ethmoids. In such a case the middle turbinate is called the concha bullosa. This balloon-like concha bullosa may block the ostiomeatal unit and the drainage of the anterior group of sinuses.
- The vertical lamella of the middle turbinate may also be pneumatized from the superior meatus to form the interlamellar cell of Grunwald.
- The middle turbinate may have a paradoxical curve bending laterally towards the middle meatus.
- Occasionally, it may be bifid.
- The ground lamella of the middle turbinate may not attach to the lamina papyracea, but may miss the lamina papyracea, pass inferiorly to it and attach to the lateral wall of the maxillary sinus instead. The maxillary sinus in this case is divided into two parts. The posterior part behaves like a posterior ethmoidal cell because it drains behind the ground lamella of the middle turbinate.
- The lower part of a normally curved middle turbinate may curve far laterally to produce a concavity within it. This concavity is called the turbinate sinus.

The superior turbinate is attached anteriorly to the middle turbinate while its posterior end partially overlies the sphenoid ostium. It overhangs a small space, the superior meatus into which open the posterior ethmoid cells. It may show variations similar to the middle turbinate like being paradoxically curved or pneumatized. The mucosa of the superior turbinate contains olfactory epithelium. However, partial resection of the turbinate during surgery does not cause any disturbance in olfaction. One or more supreme turbinate may also be occasionally found.

DISSECTION OF FRONTAL RECESS

The frontal recess is related to many critical structures like the orbit, anterior ethmoid artery and the dura. It is also subject to many anatomical variations.

When viewed from above, the frontal sinus narrows posteromedially to form a funnel-like region called the frontal infundibulum. This infundibulum leads to the frontal ostium, which in turn leads to the frontal recess in the middle meatus. This configuration consisting of the infundibulum, the ostium, and the frontal recess has the classical "hour-glass" or "egg-cup" appearance. When viewing the opening of the frontal sinus endoscopically from within the middle meatus, one must remember that almost all of the frontal sinus lies anterior to it, as the frontal sinus ostium is in the most posterior and medial region of the frontal sinus. The thick bone of the floor frontal sinus, the frontal beak, contains no important structure.

The anterior wall of frontal recess (Fig. 2.4) is formed by the anterior wall of the agger nasi cell. The posterior wall is formed by the anterior wall of the bulla. The medial wall is formed by the middle turbinate and the lateral wall by the lamina papyracea. The uncinate process lies within the frontal recess. A variable number of frontal cells are present in the frontal recess, and these cells need to be uncapped in order to provide a wide drainage to the frontal sinus. The frontal cells are categorized depending on their number and location, with the modified Kuhn's classification being most commonly used (Refer to Chapter 1).

It is interesting to note that almost all the components of the frontal recess can show different variations. The agger cell may be absent or very large, the bulla may or may not reach up to the base of skull, the uncinate process may show variable attachments as mentioned earlier, and the number and size of the frontal cells may differ. It is therefore little wonder that the frontal recess area shows such a high interpersonal variation.

DISSECTION OF THE ETHMOID SINUS AND THE OSTIOMEATAL UNIT

Within the middle meatus lies the ostiomeatal unit (Fig. 2.5) formed mainly by the bulla ethmoidalis and the uncinate process along with the intervening space. The uncinate



Fig. 2.4: Frontal recess

process is boomerang shaped and consists of an anterior vertical part, an intermediate part, and a posterior horizontal part. The maxillary sinus ostium most often lies lateral to the intermediate part. The uncinate process may be atrophic, flattened, and laterally rotated, in which case it is very closely related to the lamina papyracea. On the other hand, it may be very prominent, with a distinct line indicating its attachment to the lateral nasal wall. An extremely medially rotated uncinate process may sometimes mimic a duplicated middle turbinate. The superior attachment of the uncinate process is variable, and the configuration of the frontal sinus outflow tract depends on it. In approximately 80% cases, the upper part of the uncinate process curves laterally to attach to the lamina papyracea. It encloses within it a blind recess called the recessus terminalis. When a recessus terminalis is present, the frontal sinus opens into the middle meatus, medial to this recess. It is therefore useful to remove the upper part of the uncinate process completely in order to access the frontal sinus. Occasionally, the uncinate process attaches to the base of skull or the middle turbinate, in which case the frontal sinus opens lateral to the uncinate process in the infundibulum. The uncinate process may also have multiple attachments or may itself be pneumatized (Fig. 2.6).

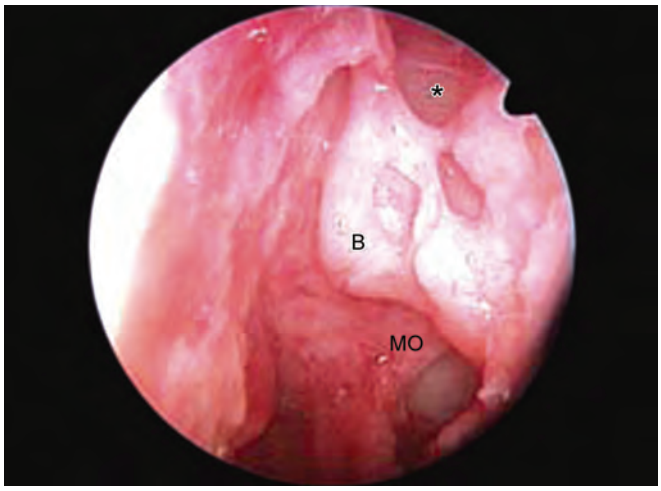

Fig. 2.5: Ostiomeatal unit (B-Bulla ethmoidalis)
* = Suprabullar recess; MO = Maxillary ostium

The bulla is the largest and most constant anterior ethmoid air cell, and although it may show variations, it is very rarely absent. It may extend all the way up to the base of skull. If the upper attachment stops short of the skull base, then the space between the skull base and the upper border of bulla is called the suprabullar recess. Posteriorly, the bulla may extend all

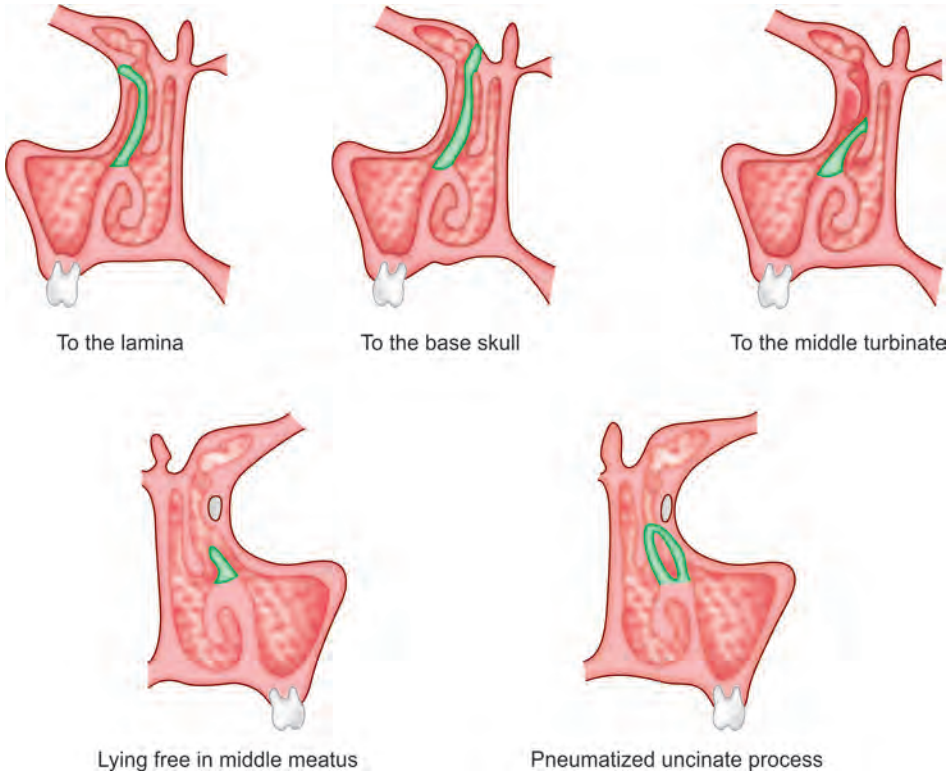

Fig. 2.6: Attachments of the uncinate

the way up to the ground lamella. If it stops short then the space between the ground lamella and the bulla is called the retrobullar recess.

The slit-like opening between the bulla and the uncinate process is the hiatus semilunaris inferioris, which leads into a tunnel-like space called the infundibulum.

The ostium of the maxillary sinus opens within the depths of this infundibulum very close to the attachment of the uncinate process. The more prominent the uncinate process, the deeper is the infundibulum, and therefore, the more relatively inaccessible is the maxillary ostium. It is therefore important to remove the entire uncinate process right up to its attachment to the lateral nasal wall in order to reveal the maxillary ostium (Fig. 2.7).

If the suprabullar and retrobullar spaces mentioned above are both present then a crescentic, slit-like opening is seen above and behind the bulla, which mirrors the hiatus semilunaris inferioris. This opening is called the hiatus semilunaris superioris, which leads to the suprabulbar and retrobulbar spaces collectively referred to as the sinus lateralis of Grunwald.

Accessory maxillary ostia may be seen in the anterior fontanelle, which lies anteroinferior to the uncinate process or in the posterior fontanelle, which is near the posterior horizontal part of the uncinate process. The accessory ostia are usually circular in shape, easily seen with a 0° endoscope, and have only two-dimensions with no depth. In contrast, the normal maxillary ostium is ovoid, tunnel like and not seen easily with a 0° endoscope as it lies in the depths of the infundibulum well hidden by the uncinate process.

The cells of the ethmoid labyrinth which open into the middle meatus are defined as the anterior ethmoid cells. For the most part they lie anterior to the ground lamella.

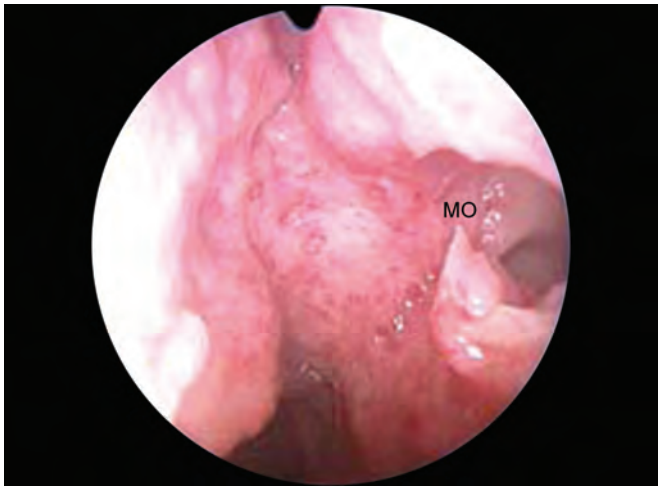

Fig. 2.7: Maxillary ostium (MO)

Occasionally, the cells may extend posteriorly to the coronal plane of the ground lamella. However, it is the pattern of their drainage rather than the actual location in relation to the ground lamella which determines their classification as the anterior ethmoid air cells.

The anterior ethmoidal artery runs obliquely in the base of the skull just behind the anterior wall of the bulla, at the point where the skull base turns from a vertical to the horizontal plane. This corresponds to the point where the vertical posterior wall of frontal sinus turns and extends backward as the cribriform plate. Since the artery lies 2–3 mm behind the anterior wall of the bulla, the intact bulla technique for the frontal recess helps to protect the anterior ethmoidal artery. However, if the anterior wall of the bulla does not reach up to the base of skull and there is a suprabullar recess, then the anterior ethmoidal artery may be damaged even in the intact bulla technique. The suprabullar recess, when present, opens into the posterior wall of the frontal recess.

Occasionally, a large cell may pneumatize the skull base along with roof of the orbit just posterior to the frontal sinus. This cell is called the supra-orbital cell and it opens into the suprabullar recess. There is usually only a thin partition between the supra-orbital cell and the frontal sinus, and very often the supra-orbital cell is mistaken for the frontal sinus in the CT scans of the paranasal sinuses. The anterior ethmoidal artery appears to lie low along the base of skull, when that region of the base of skull is pneumatized by the supra-orbital cell. In such a case, the artery usually has a bony mesentery attaching it to the base of skull or it may even be dehiscent. Dissection along the skull base in this region often shows three "openings": Those of the frontal sinus, the suprabullar recess, and the supra-orbital cells.

DISSECTION OF POSTERIOR ETHMOID CELLS

The ground lamella (Fig. 2.8) of the middle turbinate is an important landmark as it demarcates the anterior from the posterior ethmoidal cells. It is subject to many variations. It may be bowed anteriorly or posteriorly, may be pneumatized, or may be occasionally absent. It may occasionally "miss" the lamina papyracea completely and get attached to the lateral wall of the maxillary sinus. Or removing the ground lamella, one can see the posterior ethmoidal cells, which are often larger and fewer than the anterior ethmoidal cells. The posterior ethmoidal artery is sometimes seen running along the base of skull in the region of the posterior ethmoidal cells behind the ground lamella.

The most posterior ethmoid cell is easily recognized as it has a very characteristic appearance. It is pyramidal in shape and tapers to an apex away from the viewer's eye. It always



Fig. 2.8: Ground lamella (GL)

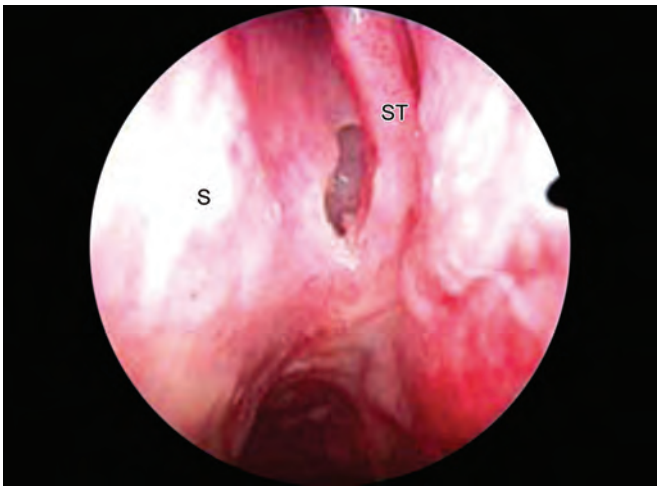

Fig. 2.9: Medial approach
(S-Septum, ST-Superior turbinate)

partially overlies the sphenoid, and hence, the sphenoid is related inferomedially to this cell. Occasionally, this cell may pneumatize over the sphenoid sinus to a greater extent. In this case, the optic nerve which routinely lies in the superolateral wall of the sphenoid, can then be related to the lateral wall of this ethmoid cell. Such a cell, which tends to "separate" the optic nerve from the sphenoid sinus, is called the Onodi cell. The optic nerve is often dehiscent in such cases. The internal carotid artery may also be seen as a bulge in the lateral wall of an extremely large Onodi cell.

"WANDERING" CELLS

The cells of the ethmoid labyrinth may "wander" and pneumatize the surrounding bones such as the lacrimal bone and sphenoid. Anterior ethmoid cells that pneumatize the lacrimal bone and the frontonasal process of maxilla anteriorly form the agger nasi cell. Similarly, if this pneumatization extends superiorly into the region of the frontal recess and the bony floor of the frontal sinus, it would form different types of frontal cells. Further pneumatization in this direction will form a pneumatized crista galli. An anterior ethmoid cell, which pneumatizes the floor of the orbit at the level of the infundibulum is the Haller cell; and one that pneumatizes the roof of the orbit behind the wall of the frontal sinus is the supra-orbital cell. A posterior ethmoid cell that pneumatizes the middle turbinate forms the concha bullosa, and one that extends backward from the posterior ethmoid cells over the sphenoid forms the Onodi cell.

Once all the posterior ethmoid cells are removed, one can delineate the entire lamina papyracea and ethmoid fovea or the skull base. Anteriorly, the lamina papyracea is related to the orbital fat, but posteriorly, the medial rectus is very often in direct contact with the lamina papyracea. The ethmoid fovea is formed partially by the frontal bone and partially by the lateral lamella of the cribriform plate. The superolateral part, which is formed by the frontal bone, is much thicker than the medial portion formed, which is formed by the lateral lamella. The thinnest part of the base of skull is where the anterior ethmoidal artery passes through the lateral lamella of the cribriform plate into the anterior cranial fossa.

DISSECTION OF SPHENOID SINUS

The sphenoid sinus can be approached endoscopically in three ways. These are called the medial, lateral, and intermediate approaches with respect to the middle turbinate.

The medial approach (Fig. 2.9) is used to access the sphenoid sinus medial to the middle turbinate via the sphenoid ostium. The sphenoid ostium is identified as mentioned earlier, and the anterior wall of sphenoid is removed in an inferior direction. The septal branch of sphenopalatine artery runs across the anterior face of the sphenoid just above the roof of the posterior choana.

The lateral approach (Fig. 2.10) is through the posterior ethmoidal cells. The sphenoid is opened in an inferomedial direction through the posterior-most ethmoid cell. The bony partition between the two is removed to widen the opening of the sphenoid sinus. It is important to note that this bony partition is in an oblique or axial plane rather than in a coronal plane.

The sphenoid sinus is very different in appearance from the posterior-most ethmoid cell. While the ethmoidal cell is pyramidal in shape, the sphenoid is globular, like the inside of a large pot. Another landmark is the "maxillary ridge" which is a surgical landmark formed at the junction of the lamina papyracea and the floor of the orbit. If this ridge is extrapolated backward, then those cells which open above the level of this

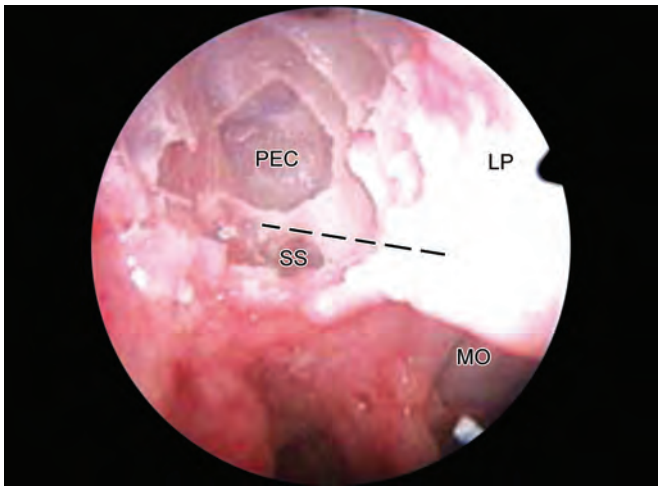

Fig. 2.10: Lateral approach (SS-Sphenoid sinus, PEC-Posterior ethmoidal cell, LP-Lamina papyracea, MO-Maxillary ostium)

ridge are posterior ethmoid cells. The cell that opens below the level of this ridge is usually the sphenoid sinus.

The intermediate approach is through the middle turbinate. The turbinate is perforated a few millimeters behind the ground lamella to enter the sphenoethmoidal recess and then access the sphenoid sinus. The inferior portion of the superior turbinate very often needs to be trimmed to get access to the sphenoid sinus and to communicate the lateral sphenoid opening with the normal ostium.

The sphenoid sinus may vary in pneumatization from a small conchal sinus (Fig. 2.11) to a large sellar sinus.

The structures related to the lateral and superior wall of the sphenoid sinus can best be studied in a well pneumatized sinus. The lateral wall is related above to the optic nerve and inferoposteriorly to the internal carotid artery. A small recess is present between these two structures, which is called the opticocarotid recess. This recess is very deep if the anterior clinoid process is pneumatized. Anterior to the pituitary sella is the planum sphenoidale and it forms the lowest level of the base of the skull. If there is large lateral recess present then the vidian nerve and maxillary nerve may also be seen as ridges along the inferior and superior walls of the lateral recess, respectively.

Although the sphenoid rostrum is always in midline, the intersphenoid septum very often lies to one side, making one sphenoid much larger than the other. The larger sphenoid is called the dominant sphenoid. Intrasphenoid septae often tend to attach to important structures such as the optic nerve and carotid artery, and therefore, they should not be avulsed.

In conclusion, it is important to remember that endoscopic cadaveric dissection should always be performed in "layers". Removal of each layer will reveal different anatomical landmarks which need to be studied in detail before proceeding to the next deeper layer of cells.

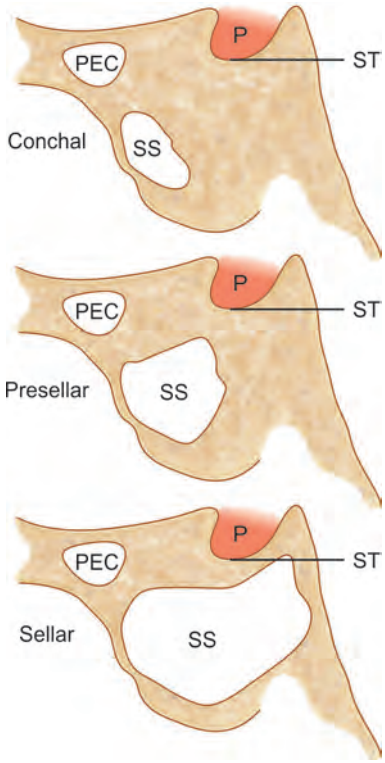

Fig. 2.11: Pneumatization of sphenoid sinus (PEC-Posterior ethmoidal cell, SS-Sphenoid sinus, P-Pituitary, ST-Sella turcica)

BIBLIOGRAPHY

1. Bolger WE, Butzin CA, Parsons DS. Paranasal sinus bony anatomic variations and mucosal abnormalities: CT analysis for endoscopic sinus surgery. Laryngoscope. 1991;101:56-64. [PubMed]
2. Braun H, Stammberger H. Pneumatization of turbinates. Laryngoscope. 2003;113:668-72. [PubMed]
3. DeLano MC, Fun FY, Zinreich SJ. Optic nerve relationship to the posterior paranasal sinuses. CT anatomic study. Am J Neuroradiol. 1996;17:669-75. [PubMed]
4. Keros P. On the practical value of differences in the level of the lamina cribosa of the ethmoid. Z Laryngol Rhinol Otol. 1962;41:809-13.
5. Lund V. Anatomy of the nose and paranasal sinuses. In: Gleeson M, Kerr AG (Eds). Scott Brown's Otolaryngology: Basic Sciences. 6th edition. Oxford, UK: Butterworth-Heinemann. 1997;pp. 1-30.
6. Messerklinger W. On the drainage of the normal frontal sinus of man. Acta Otolaryngol. 1967;63(2):176-81.
7. Messerklinger W. Endoscopy of the nose. Baltimore, MD: Urban & Schwarzenberg; 1978.
8. Stammberger H. Endoscopic anatomy of lateral wall and ethmoidal sinuses. In: Stammberger H, Hawke M (Eds). Essentials of functional endoscopic sinus surgery. St Louis: Mosby-Year Book. 1993;pp.13-42.
9. Wormald PJ. The agger nasi cell: the key to understanding the anatomy of the frontal recess. Otolaryngology—Head and Neck Surgery. 2003;129(5):497-507. [PubMed]

for detailed information of otolaryngology books, visit our website www.jaypeebrothers.com, for detailed information of otolaryngology books, visit our webs

ENDOSCOPIC ENDONASAL SURGERY

SINUSES & BEYOND

Salient Features

- Includes a wide range of topics such as anatomy, radiology, instrumentation, preoperative work-up, medical and surgical management and complications related to various sinonasal pathologies and procedures
- Covers the extended applications of endoscopic sinus surgery by way of chapters related to skull-base surgery, cerebrospinal fluid rhinorrhea, orbital conditions and endoscopic management of malignancies
- The book would be a valuable reference for practicing otolaryngologists and skull-base surgeons as well as for beginners and trainee endoscopic surgeons.



Milind V Kirtane MS (ENT) DORL is Professor Emeritus, Department of ENT, Seth GS Medical College and King Edward Memorial Hospital, Mumbai, Maharashtra, India. He is Senior Consultant ENT Surgeon, PD Hinduja National Hospital and Medical Research Centre, Breach Candy Hospital, Cumballa Hill Hospital and Saifee Hospital, Mumbai, Maharashtra, India. He is recipient of many awards including prestigious Dr BC Roy Award in the category of Recognition of the Best Talents in Engineering the Development of Specialties in Different Branches of Medicine on 1st July, 2005 at Rashtrapati Bhavan, New Delhi, India; Padmashree (2014) by Government of India; Qimpro Platinum Award for Healthcare (2014), Tato–Claussen Sponderpries Award for the work in the field of neuro-otology in Asia Pacific at the XXIX International NSE at Bad Kissingen, Germany (2002), Dr RAF Cooper Award (1977) of the Association of Otolaryngologists of India (AOI), E Merck Award (1978) of the AOI. He is the first member from India to be elected to the Barany Society (1983), Sweden. He is also on the Editorial Board of the International Tinnitus Journal and ISRN Otolaryngology and he holds many important positions, viz. Ex-President and Member of Association of Otolaryngologists of India, Founder President of the Sinus Endoscopic Society of India, Founder Member of Indian Society of Otology and Indian Society of Laryngology, Member of Neurotological and Equilibriometric Society (International), Member and Ex-President of Neurotological and Equilibriometric Society of India, Member of 4G Forschung, Germany and American Rhinologic Society and the Member of Barany Society, Sweden. He has about 50 publications in indexed journals and has authored many books on otology and neurology and endoscopic sinus surgery. His areas of special interest are cochlear implants, endoscopic sinus surgery and neurotology.

Available at all medical bookstores
or buy online at www.jaypeebrothers.com

JAYPEE

JAYPEE BROTHERS
Medical Publishers (P) Ltd.
www.jaypeebrothers.com

Join us on facebook.com/JaypeeMedicalPublishers

Shelving
Recommendation
OTOLARYNGOLOGY

ISBN 978-93-5152-150-1

9 789351 521501