ur website www.jaypeebrothers.com, for detailed information on obstetrics & gynecology books, visit our website www.jaypeebrothers.com

Federation of Obstetric & Gynaecological Societies of India

ULTRASOUND IN OBSTETRICS & GYNECOLOGY

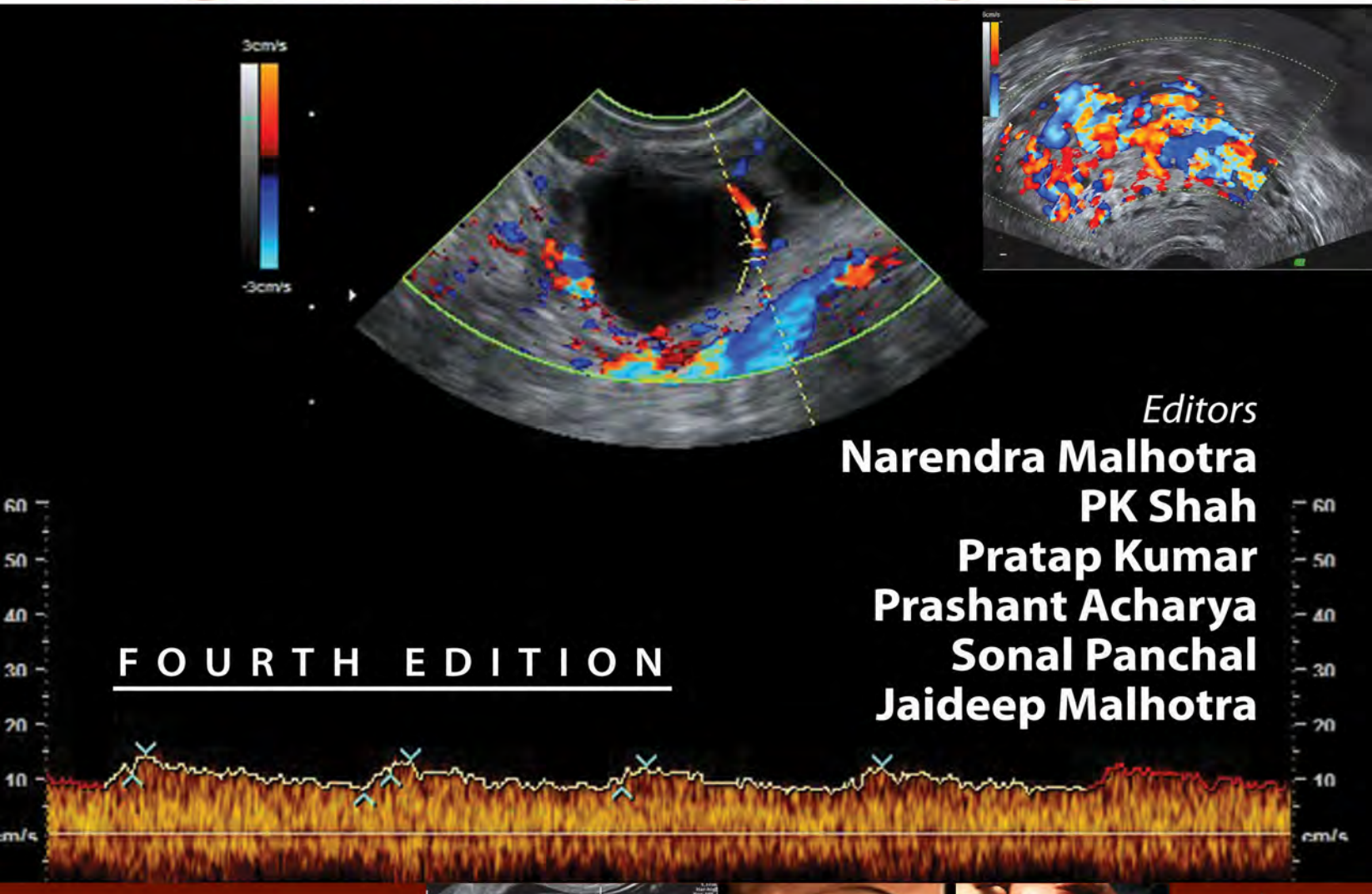

Editors
Narendra Malhotra
PK Shah
Pratap Kumar
Prashant Acharya
Sonal Panchal
Jaideep Malhotra

FOURTH EDITION

Foreword
WW Sumpaico &
KY Leung



JAYPEE

Contents

Section 1: Ultrasound Physics and Machines

Chapter 1. **Scientific Basis of Ultrasonography** 3
AK Debdas

- Historical Background 3
- Ultrasound Production 3
- Echoing Mechanism of Ultrasound 5
- Types of Images 5
- What is a Gray Scale? 8
- Focusing Mechanism of US Beam 8
- Time Gain Control Amplifier 8
- Types of Transducer/Scanners 9
- Scientific Basis of Selection of Appropriate Transducer for a Particular Job 9
- Image Storage System 10
- Color Flow Imaging 10
- 3D Ultrasound Imaging 10
- 4D Ultrasound Imaging 10
- Volume Imaging 10
- Ultrasound Contrast Agents 10
- Artifacts in USG Images and their Physical Basis 11
- Recent Technical Innovations 11

Chapter 2. **Physics and Machines** 13
Rishabh Bora, Narendra Malhotra

- Requirements of an Obstetrician 13
- Machines Available 14
- What to Expect? 14
- Assessment 14
- Development of Various Types of Transvaginal Probes and the Clinical Evolution 17
- Color Flow Imaging in Obstetrics: Understanding its Art, Science, and Technology 17
- Conclusion: Ideal Equipment 18

Chapter 3. **Measurements** 20
Sakshi Tomar

- Measurements in First Trimester 20
- Measurements in Second and Third Trimesters 21
- Gynecological Measurements 22
- Doppler Measurements 23

Section 2: Obstetrics

Chapter 4. **Obstetric Ultrasound When?** 27
R Rajan

- Ovum, Embryo, and Fetus 27
- Prenatal Implications of the Embryo and Fetus 28
- Transvaginal Sonography 28
- Detection of Fetal Organ Malformations 30

Chapter 5. **Sonoembryology** 32
Rajat Ray

- Gestational Sac 32
- Yolk Sac 34
- Embryo and Cardiac Activity 34
- Amnion 34
- Musculoskeletal System 34
- Placenta 38

• Umbilical Cord 38
• Dating of a Pregnancy 38

Chapter 6. **Problems of First Trimester** 40
BI Patel
• Guidelines for first Trimester: Minimum Standard for the first Trimester 40
• Sonoembryology 41
• Role of Transvaginal Sonography in Early Pregnancy Loss 41
• Information Provided by First Trimester Ultrasound 41
• Pseudopathology of Embryo 42
• Gestational Sac 44
• Yolk sac 46
• Anembryonic Pregnancy: Blighted Ovum 48
• Missed Abortion 49
• Hydatid Mole: Gestational Trophoblastic Disease 49
• Subchorionic Hematoma 49
• Yolk Sac and Other Biometry Measure for Viability Assessment 52
• Incomplete Abortion 53
• Missed Abortion 56
• Minor Anomalies 56

Chapter 7. **11–14 Weeks Scan** 64
Ashok Khurana
• Statistical Perspective and Natural History of Chromosomal Abnormalities 65
• Parameters for First Trimester Screening 65
• How Screening Protocols Work? 70
• Dysmorphology Diagnosis in the First Trimester 71

Chapter 8. **First Trimester Biochemical Screening** 73
PK Shah, Neelima Y Mantri
• Indications 73
• Screening Methods 74
• Biochemical Markers 74
• Nuchal Translucency and Nasal Bone Assessment 75
• Down Syndrome 76
• Advantages of First Trimester Screening 76
• Disadvantages of Biochemical Screening in First Trimester 76
• Various Protocols for First Trimester Screening 76
• Comparison 77
• Conclusion 78
• Newer Trends 78

Chapter 9. **Transvaginal Ultrasonography in Ectopic Extrauterine Pregnancy** 81
Jaideep Malhotra, Narendra Malhotra, Neharika Malhotra
• Overview of Sonographic Signs 82
• Color and Pulsed Doppler Sonography for Ectopic Pregnancy 83
• Ultrasound-guided Conservative Management of Ectopic Pregnancy 83

Chapter 10. **Prenatal Diagnosis in First Trimester** 85
Raju R Sahetya, Ankesh R Sahetya
• Genetic Counseling 85
• Informed Written Consent and Medical Malpractice 85
• Indications of Prenatal Genetic Diagnosis 86
• Methods of Prenatal Screening and Diagnosis to Determine the Health of the “Unborn” 86
• Typical Screening Sequence 86
• Protocol for Fetal Anatomic Survey with Ultrasound at 11–14 Weeks Gestation 88
• Invasive Techniques 88
• Cytogenetic Chromosomal Studies 90
• Results 91
• Benefits of Prenatal Diagnosis 92
• Ethical and Practical Issues 92

Chapter 11. **Doppler in Obstetrics: Basic Principles** 94
Alok Sharma
• Basic Concepts of the Doppler Principle 94
• Doppler Modalities 95

Chapter 12. **3D-4D Ultrasound in First Trimester** 98
Sonal Panchal
- Technical Aspects 98
- Applications of 3D and 4D US in First Trimester 98

Chapter 13. **3D Ultrasound in Reproductive Medicine** 116
Sonal Panchal
- Uterus 116
- Adnexa 122
- Assessment of Tubal Patency 122
- Infertility 123

Chapter 14. **Trophoblastic Diseases** 126
Kazuo Maeda, Asim Kurjak, Gino Varga, Ulrich Honemeyer
- Classification, Development, and Pathology 126
- Symptoms of Gestational Trophoblastic Disease 130
- Diagnosis of Gestational Trophoblastic Disease 130
- Therapy of Trophoblastic Diseases 139

Chapter 15. **Ultrasound Markers of Chromosomal Anomalies in the First Trimester** 144
Ashok Khurana
- Statistical Perspective and Natural History of Chromosomal Abnormalities 144
- Parameters for First Trimester Screening 144
- Overview of Screening Protocols 147

Chapter 16. **Second Trimester Biochemical Screening for Chromosomal Anomalies/Aneuploidy** 149
Shantala Vadhiyar
- Indications and Algorithms for Second Trimester Screening 149
- Timing of the Test and Markers that are Measured in Maternal Serum 149
- Interpretation of Results 150

Chapter 17. **Managing Multiple Pregnancy** 151
S Suresh, Uma Ram, Indrani Suresh, Shanthi Sairam
- Assessing Chorionicity: Fundamental First Step in Multiple Pregnancy 152
- Maternal Problems in Multiple Pregnancy 154
- Fetal Growth in Twins 157
- Problems Unique to Monochorionic Diamniotic Twins 158

Chapter 18. **Complications and Management of Monochorionic Twins** 162
Akshatha Prabhu Sharma, Anita Kaul
- Complications Specific to Monochorionic Twin Pregnancies 162
- Management 170

Chapter 19. **Ultrasound Diagnosis of Fetal Growth Restriction** 172
Prashant Acharya, Ashini Acharya
- Definition of Intrauterine Growth Restriction/Fetal Growth Restriction 172
- Etiology 173
- Uterine Artery Doppler Measurement 178
- Other Fetal Vessels 179

Chapter 20. **Placental Evaluation** 182
TLN Praveen, Nozer K Sheriar
- Placental Development 182
- Normal Placental Appearance 182
- Placental Maturation and Grading 182
- Placental Localization 184
- Abnormalities of Placentation 185

Chapter 21. **Amniotic Fluid Index** 188
Neharika Malhotra, Rishabh Bora
- Amniotic Fluid Index 188
- Discussion 189
- Admission Test 190

Chapter 22. **Management of Fetal Growth Restriction and Fetal Compromise** 192
Narendra Malhotra, Jaideep Malhotra
- Etiology 192
- Pathophysiology 192

- Fetal Growth Rates 193
- Diagnosis of Fetal Growth Restriction 193
- Diagnosis of Fetal Compromise or Jeopardy 193
- Tests For Fetal Well-being 194
- Indications of Fetal Well-being Studies 194
- Markers for Fetal Distress Hypoxia 197
- Fetal Oxygenation 197

Chapter 23. **Transvaginal Sonography in Cervical Incompetence** 200
PK Shah, Neelima Y Mantri
- Incidence 200
- Etiology 200
- Classification of Cervical Incompetence 201
- Diagnosis 201
- Types of Sonography Procedures 202
- Management of Cervical Incompetence 206

Chapter 24. **Hydrops Fetalis** 209
Prashant Acharya, Ashini Acharya, Hriday Acharya
- Categories of Hydrops Fetalis 209
- Diagnostic Approach to the Fetus with Hydrops 213
- Neonatal Management of Hydrops Fetalis 214
- Clinical Management 217
- Outcome 220

Chapter 25. **Fetal Anomaly Scan Checklist** 225
Kuldeep Singh
- Measurement/Methodology 225

Chapter 26. **Antenatal Assessment of Fetal Well-being** 227
Narendra Malhotra, Jaideep Malhotra, Vanaj Mathur, Sakshi Tomar, Kuldeep Singh JP Rao, Samiksha Gupta, Neharika Malhotra
- High-risk Patients 228
- Indications for Well-being Tests and Studies 228
- Methods of Fetal Surveillance 228
- Antenatal Fetal Well-being Assessment 235
- Biochemical Tests 239
- Conclusion 239
- Management Protocols for Fetal Growth Restriction 239
- Intrapartum Fetal Monitoring 239

Chapter 27. **Doppler Evaluation in Fetal Hypoxia** 242
PK Shah, Neelima Y Mantri
- Fetal Hypoxia 242
- Doppler Effect 242

Chapter 28. **Use of Three-dimensional/Four-dimensional Ultrasound in Obstetrics** 253
Betty Lau, Fang Yang, Teresa Ma, KY Leung
- Basic Three-dimensional Ultrasound Techniques 253
- Techniques of Three Dimensions 255
- Four-dimensional Ultrasound 256
- Roles of 3D/4D US in Obstetrics 256

Chapter 29. **Organ-targeted Ultrasound Scanning** 261
Kuldeep Singh
- Practical Schematic Analysis for Fetal Abnormalities 262
- Checklist for a Detailed Abnormalities Scan 272
- Things to Remember 272

Chapter 30. **Prenatal Diagnosis of Congenital Malformations** 274
Kuldeep Singh
- Ultrasound Imaging of Fetal Anomalies 274
- Cisterna Magna 275
- Fetal Face 278
- Fetal Spine 280
- Fetal Thorax 281
- Fetal Abdomen 284
- Esophageal Atresia 284
- Fetal Skeletal System 287

Chapter 31. **Ultrasound Markers of Chromosomal Anomalies** 289
Jaideep Malhotra, Ashok Khurana
- Statistical Perspective and Natural History of Chromosomal Abnormalities 289
- Parameters for First Trimester Screening 289
- Overview of Screening Protocols 291

Chapter 32. **Aneuploidy Assessment in Second Trimester Scan—Soft Markers** 292
Pooja Lodha, Anita Kaul
- History 292
- Soft Markers on Genetic Sonogram 293

Chapter 33. **Fetal Echocardiography** 297
Sonal Panchal
- Equipment Settings 298
- Evaluation of the Heart 300
- Study of Internal Cardiac Anatomy 302
- Fetal Circulation 307
- Classification of Cardiac Diseases 308

Chapter 34. **Antenatal Cardiac Diagnosis, Counseling, and Management** 318
Vikas Kohli
- Indications of Fetal Echocardiography 318
- Fetal Cardiac Screening 318
- Timing, Mode, and Place of Delivery 319
- Management of Fetal Arrhythmias 320

Chapter 35. **Color Doppler and 3D and 4D Ultrasound in Screening for Birth Defects** 322
Narendra Malhotra, Kuldeep Singh, Sakshi Tomar, Jaideep Malhotra, JP Rao, Neharika Malhotra
- Screening of Congenital Birth Defects 322
- Role of 3D and 4D Ultrasound 324
- 3D and 4D Ultrasound Equipment and Technique 325

Chapter 36. **Ultrasonography Role in Perinatal Infection** 331
Alaa Ebrashy
- Ultrasound Features in Congenital Infection 331
- Role of Invasive Procedures in the Diagnosis of Intrauterine Infection 334
- Prenatal Management of Specific Congenital Infections Using Ultrasound Markers and Invasive Procedures 334

Chapter 37. **Fetal Behavior Assessed by 4D Sonography** 339
Asim Kurjak, Badreldeen Ahmed, Berivoj Miskovic, Maja Predojevic, Aida Salihagic Kadic
- Basic Technology of the 4D Sonography in the Assessment of Fetal Behavior 339
- Classification of Movement Patterns 341
- Onset of Specific Fetal Behavioral Patterns Assessed by 3D or 4D Ultrasonography 344
- Fetal Behavior as an Indicator of Disturbed Brain Development 347

Chapter 38. **Three-dimensional Ultrasound in Obstetrics** 362
Asim Kurjak, Milan Kos, Nika Kalogjera
- Modalities of 3D Imaging 363
- Three-dimensional Evaluation of Normal Fetal Anatomy 364
- Volumetry—Organ Volume Measurements 366
- Three-dimensional Assessment of Fetal Malformations 367

Chapter 39. **Prenatal Diagnostic Techniques** 376
Prashant Acharya, S Suresh, Deepika Deka, Prathima Radhakirshnan, Anita Kaul, Narendra Malhotra, Jaideep Malhotra, Ashok Khurana, PK Shah, Mandakini Pradhan, Geeta Kolar, Suseela Vavilala, Chander Lulla, Hema Divakar, Gokul Das
- Training and Registration 376
- The 11–13 + 6 Weeks Scan 376
- The "18–20 Weeks"—Targeted Anomaly Scan 378
- Prenatal Diagnostic Tests 380
- Conclusion 382
- General Principles for Prenatal Diagnosis Programs 382

Chapter 40. **Rh Negative Mother-Antenatal Management** 386
Prashant Acharya

Chapter 41. **Genetics and Pathophysiology of Rhesus Disease** 387
Prashant Acharya, Ashini Acharya, Hriday Acharya
- Genetics of the Rh System 387
- Pathophysiology of Rh Disease 388

Chapter 42. **Rhesus Alloimmunization Management** 390
Prashant Acharya, Hriday Acharya
- Diagnostic Approach 390
- Clinical Management 392
- Intravascular Transfusion 393
- Intraperitoneal Transfusion 394
- Outcome 395

Chapter 43. **Labor Room Protocol for Rhesus Negative Mother** 397
Prashant Acharya, Hriday Acharya
- Methods of Assessment for Fetomaternal Hemorrhage 397
- Prophylaxis 398

Chapter 44. **Fetal Abdominal Wall Defects** 401
Sudheer Gokhale
- Pathogenesis 401
- Sonography of Fetal Abdominal Wall 401
- Gastroschisis 402
- Omphalocele 403
- Thoracoabdominal Syndrome, Pentalogy of Cantrell 404
- Omphalocele–exstrophy–Imperforate Anus–spinal Defects Complex 405
- Limb-Body Wall Complex and Amniotic Band Syndrome 407

Chapter 45. **Sonography of Fetal Chest Anomaly** 409
Sudheer Gokhale
- Pleural Effusion 409
- Congenital Pulmonary Airways Malformation 410
- Congenital High Airways Obstruction 412
- Congenital Diaphragmatic Hernia 413

Chapter 46. **Diagnosis of Fetal Anemia** 416
Babu S Patel
- Pathophysiology 416
- Diagnosis 416

Chapter 47. **Fetal Monitoring in Labor: Diagnosing Fetal Distress in the Indian Scenario** 420
Jaideep Malhotra, Ajay S Dhawle, Narendra Malhotra, Neharika Malhotra
- Fetal Physiology in Labor 420
- Intermittent Auscultation 421
- Continuous Electronic Fetal Monitoring 422
- The Admission Cardiotocograph 425
- Fetal Pulse Oximetry 426
- Fetal Scalp Blood Sampling 427
- Fetal Scalp Lactate 427
- Fetal Scalp Stimulation 428
- Fetal Electrocardiogram: ST Waveform Analysis 428
- Umbilical Cord Blood Gases 429
- Indian Scenario 429

Chapter 48. **Prediction of Preeclampsia** 432
Ranjit Akolekar
- Maternal Characteristics and Obstetric History 432
- Biophysical Markers 433
- Biochemical Markers 434
- Screening for Preeclampsia in the First Trimester 435

Chapter 49. **Prediction of Preterm Labor by Ultrasound Cervical Length** 438
Anu Vij
- Early Diagnosis of Preterm Labor 438
- Evaluation of Cervical Length by Ultrasound 438
- Cervical Length: Multiple Pregnancies 439
- Measurement of Cervical Length 440
- Lower Uterine Segment Contraction 442
- Cervical Funneling: An Independent Predictor of PTD? 442

Section 3: Gynecology

Chapter 50. **Normal Pelvic Anatomy and Gynecologic Ultrasound** 449
Amar R, Pratap Kumar, Prashanth Adiga, Ashwini V
- Transabdominal Sonography vs Transvaginal Sonography 449
- Methodology 449
- Orientation and Basic Scanning Maneuvers 450
- Relevant Pelvic Anatomy 451

Chapter 51. **Ultrasonography in Gynecology** 456
Narendra Malhotra, Jaideep Malhotra, Sakshi Tomar, Neharika Malhotra, JP Rao, Rohit Jain
- Normal Female Pelvis 456
- Ultrasound of the Uterus 458
- Diseases of Cervix 468
- Vagina 468
- Ovarian Sonography 468
- Gestational Trophoblastic Disorders 477
- Pelvic Kidney 477

Chapter 52. **Ultrasound of Cervix** 479
Neharika Malhotra, Amreen Singh
- Cervical Pathology 480
- Measurement of Cervix 483

Chapter 53. **Chronic Pelvic Pain** 486
Rohit Jain
- Gynecological Chronic Pelvic Pain 487
- Approach to a Patient with Pelvic Pain 490

Chapter 54. **Ultrasonography of the Adnexal Masses** 494
Sakshi Tomar
- Ovaries 494
- Fallopian Tubes 494
- Ovarian Sonography 494

Chapter 55. **3D and 4D Ultrasound of Female Pelvis** 503
Sonal Panchal
- Technical Aspects 503
- Standardization of Image 504
- Uterus 505
- Adnexa and Ovaries 514

Chapter 56. **Malignancies of Pelvis** 523
Juan Luis Alcázar
- Endometrial Cancer 523
- Uterine Leiomyomas and Sarcomas 528
- Cervical Cancer 533
- Adnexal Tumors 536

Chapter 57. **Ultrasound in the Postmenopause** 547
Martina Ujevic, Biserka Funduk Kurjak, Boris Ujevic
- Challenges of the Postmenopause 548
- Instrumentation 548
- Scanning in the Postmenopause 548
- Postmenopausal Ovary 549
- Postmenopausal Uterus 554
- Postmenopausal Endometrium 557

Chapter 58. **Ultrasound of Menopausal Pelvis** 565
Narendra Malhotra, Kuldeep Singh, Jaideep Malhotra, Neharika Malhotra, Rishabh Bora
- Normal Endometrium in Menopause 565
- Postmenopausal Bleeding 566
- Endometrial Fluid Collections 566
- Myometrium in Menopause 566
- Normal Atrophic Ovary 567
- Ovary and Ovarian Cancer Screening 567

Section 4: Infertility

Chapter 59. **Evaluation of Female Infertility** 573
Chaitanya Nagori
- Baseline Scan 574
- Ovaries 574
- Uterus 578

Chapter 60. **Sonosalpingography** 585
Narendra Malhotra, Jaideep Malhotra, Sakshi Mittal, Neharika Malhotra

Chapter 61. **Ultrasound for Cervical Factor Infertility** 588
Shashi Gupta, Sumit Gupta, Pradeep Kumar Gupta
- Cervical Mucus 588
- Postcoital Test or Sims–Huhner Test 588
- Role of Ultrasound 589

Chapter 62. **Transvaginal Sonography in Infertility** 595
Narendra Malhotra, Sakshi Tomar, Jaideep Malhotra, JP Rao, Neharika Malhotra, Rishabh Bora, Keshav Malhotra
- Ultrasound Assessment of the Male Partner 595
- Assessment of the Female Reproductive Tract 597
- Ovarian Evaluation by Ultrasound 604
- Role of Transvaginal Color Doppler in Infertility 607
- Role of Transvaginal Color Doppler in Other Conditions Associated with Infertility 607
- Ultrasound-Guided Assisted Reproductive Techniques 608

Chapter 63. **Ectopic Pregnancy—No Longer An Enigma** 610
Narendra Malhotra, Jaideep Malhotra, PK Shah
- Investigations 610
- Medical Management 610
- Surgical Management 611
- Future Fertility 611

Chapter 64. **Magnetic Resonance Imaging of the Female Pelvic Region** 613
Mary C Olson, Harold V Posniak, Clare M Tempany, Christine M Dudiak
- Technique 613
- Normal Anatomy 613
- Abnormalities of the Female Pelvic Region 615
- Tumor Recurrence Versus Fibrosis 629
- Other Pathologic Conditions 629

Section 5: Interventional Procedures

Chapter 65. **Genetics for Obstetricians** 637
Mandakini Pradhan
- What Are Genetic Diseases? 637
- Cell Division and its Importance 638
- Clinical Aspects of Chromosomal Abnormality 638
- Clinical Aspects of Multifactorial Disorder 639

Chapter 66. **Risks of Prenatal Diagnostic Procedures: Present Scenario** 641
Dipika Deka, Mrinalini
- Risks of Prenatal Diagnostic Procedures 641
- **Pretest Counseling for Prenatal Diagnostic Procedures 642**
- Complications of Amniocentesis 642
- Cordocentesis 643
- Chorionic Villus Sampling 644

Chapter 67. **Gynecological Interventional Procedures** 646
- **2D and 3D Saline infusion sonography and Hystero-contrast-salpingography 646**

Sanja Kupesic Plavsic, Branko M Plavsic
- Ultrasound Assessment of the Uterus and the Fallopian Tubes 647
- Three-dimensional Hystero-contrast-salpingography 654
- **Guided Procedures Using Transvaginal Sonography 658**

Sanja Kupesic Plavsic, Nadah Zafar, Asim Kurjak
- Transvaginal Puncture Procedures 659
- Conservative Management of an Ectopic Pregnancy 663
- Other Applications 665

Section 6: Radiology

Chapter 68. **Radiology in Obstetrics and Gynecology** 671
Satish K Bhargava, Sudhanshu Bankata, Shifali Gupta, Mukta Jain, Rishabh Bora
- Obstetrics Radiology 671
- Fetal Abnormalities 672
- Pelvimetry 674
- Radiation Hazard 677
- Plain Radiographs of the Abdomen 677
- Role of Plain Radiographs in Specific Gynecological Conditions 679
- Role of Intravenous Urography in Gynecology 680
- Role of Cystography 680
- Barium Enemas 680
- Lymphangiography 680
- Angiography 681
- Vaginography 681
- Pneumogynecography 681
- Hysterosalpingography 682
- Normal Radiological Anatomy 683
- Hysterosalpingography Appearances 684

Chapter 69. **CT and MRI in Obstetrics and Gynecology** 691
Nitin P Ghonge, Sanchita Dube Ghonge
- Imaging in Obstetrics and Gynecology: An Overview 691
- Magnetic Resonance Imaging in Obstetrics 693
- CT and MRI in Gynecology 702
- Radiation Concerns in Diagnostic Imaging 719
- Newer Gynecologic Applications of MRI—Diffusion-Weighted MRI 720

Chapter 70. **Endoscopic Ultrasound** 725
Pranay R Shah
- Instrumentation 725
- Techniques 726
- Clinical Applications 726

Chapter 71. **Imaging of the Breast** 727
Meeta Kulshreshtha
- Mammography 727
- Breast Ultrasonography 732
- Breast Magnetic Resonance Imaging 734
- Molecular Breast Imaging (Scintimammography) 736
- Positron Emission Tomography 736
- Electrical Impedance Imaging (T-Scan) 737
- Thermography (Thermal Imaging) 737
- Optical Imaging 737
- Ductogram (Galactogram) 738

Chapter 72. **Magnetic Resonance Imaging: How to Use it During Pregnancy?** 739
Ichiro Kawabata, Yuichiro Takahashi, Shigenori Iwagaki
- Safety of Magnetic Resonance Imaging 739
- Indication and Procedures for MRI During Pregnancy 739

Section 7: Miscellaneous

Chapter 73. **FOGSI Imaging Science Committee: Training Guidelines** 751
- Guidelines for Recognition of the Center 751
- Theoretical Training Program 751
- Practical Training 753

Chapter 74. **Prenatal Diagnostic Techniques Act—Salient Features** 755
RN Goel
- Why this Act 755
- Prenatal Diagnostic Techniques 755
- Registration of Genetic Counseling Center, Genetic Laboratory, Ultrasound Clinic, and Genetic Clinic 759
- Central Supervisory Board 760
- State Supervisory Board 760

- Appropriate Authority and Advisory Committee—As Per Rule 17 760
- District Advisory Committee 760
- Appropriate Authority 760
- Offences and Penalties 761
- Duties of Registered Center 761
- Search 762

Chapter 75. **Fetal Rights** 776
Reena J Wani, Niraj Mahajan

- Fetal Rights 776
- Fetal Protection in Law 777
- Abortion in India 778
- Drug Use by the Mother 779
- Behavioral Intervention 779
- Forced Cesarean Sections 780
- Forcing Pregnant Women to Do As They are Told: Maternal Versus Fetal Rights 781
- Research Issues 781
- Future of Fetal Rights 782

Chapter 76. **Ultrasound and Consumer Forum** 784
Reena J Wani

- Competence 784
- Disclosure 785
- Routine Prenatal Screening 785
- Hazards of Interventional Ultrasound 785
- Legal Redressal 787

Chapter 77. **Legal Aspects of Obstetric Ultrasound** 789
Narendra Malhotra, Kuldeep Singh, Jaideep Malhotra

- Medical Malpractice 789
- Legal Actions in Diagnostic Ultrasound 790
- Medical Malpractice Claim 791
- Statistics on Malpractice 793
- Standards of Care 793
- Training Parameters in Ultrasound in Obstetrics and Gynecology 794
- Who Can Conduct Obstetrical Ultrasound (Prenatal Diagnostic Test) 796
- Advanced Antenatal Practice 797
- Sonography-related Issues 800
- Countersuit 800
- What to do if You are Sued? 801
- Law and Ultrasound and Medical Termination of Pregnancies 802
- Pre-1971 Laws on Abortion: Section 312–316 of the IPC, 1860 802
- Suggestions for Better Implementation of the Law 803

Appendices

1. **Language of Ultrasound: Recommended Terminology for Ultrasound** 809
2. **History of Ultrasound** 831
3. **Performance of Antepartum Obstetrical Ultrasound** 833
4. **ACR-ACOG-AIUM-SRU Practice Guideline for the Performance of Obstetrical Ultrasound** 835
5. **AIUM Practice Guideline for the Performance of Obstetric Ultrasound Examinations** 843
6. **Thomas Jefferson University Protocols for Ultrasound Procedures** 850
7. **ICOG Diploma in Obstetric and Gynecological Ultrasound** 856

Index 863

CHAPTER 2

Rishabh Bora, Narendra Malhotra

Physics and Machines

Chapter Overview

- Requirements of an Obstetrician
- Machines Available
- What to Expect?
- Assessment
- Development of Various Types of Transvaginal Probes and the Clinical Evolution
- Color Flow Imaging in Obstetrics: Understanding its Art, Science, and Technology

Introduction

For an obstetrician and a gynecologist, an ultrasound machine has today become a must like the stethoscope for a cardiologist. The doctors are confused by the menu of machines offered by various companies.

Ultrasonography has been the finding of the century—a technology introduced to the medical world by a gynecologist, the great Ian Donald. It has become indispensable to all fields of medicine. The great revolutionary milestone in our specialty, comparable to anesthetics by Simpson, Forceps by Chamberlain, was the introduction of ultrasound to obstetrics in the late 1950s.

Ultrasound scanning during 1960s was generally regarded as a kind of art-form, which was nice to have if the local expertise was available.

The development of real-time scanner was the desperately needed breakthrough: equipment became cheaper, lighter, and smaller (and, therefore, could be moved to the patient); most importantly scanning was technically easier and, therefore, the training time shorter. Technicians and radiographers who had perhaps struggled with the larger equipment were amazed at how quickly they could achieve reproducible fetal measurements with a good quality linear-array scanner.

A further technical innovation, the combination of the real-time scanner with pulse Doppler ultrasound, made possible the measurement of fetal and uteroplacental blood flow.

A final, perhaps unexpected, benefit of the real-time revolution was that parents, on seeing their fetus moving on the screen, were delighted, and indeed, the ultrasound session became a family event. Maternal–fetal bonding was accelerated.

The impact of diagnostic ultrasound on gynecology was initially less dramatic, because until recently, it was felt that laparoscopy was a more exact diagnostic test when a small pelvic mass was suspected while larger masses, which could be felt abdominally, would be more appropriately investigated by exploratory laparotomy. This attitude was changed virtually overnight when it was demonstrated that ultrasound specially in the form of the real-time mechanical sector scanner and transvaginal probes could be used to monitor ovarian follicular development and more recently to guide direct aspiration of the ovum under local analgesia, a technique, which could rapidly transform in vitro fertilization into an outpatient procedure.

In obstetrics and gynecology, the science of sonography is even more important and helpful, so much so that scientists are experimenting on devising a probe, which can fit over the finger during a per vaginal examination; and in the words of Goldstein, palpation and imaging will be married.

Requirements of an Obstetrician

Basically, the obstetric practice can be divided into the following sections:

- Clinics, i.e. consultation practice
- Small nursing homes doing both obstetric and gynecological work

JAYPEE BROTHERS

- Nursing homes and institutions doing specialized work in infertility follicle monitoring and also interventional sonography
- Clinics and hospitals doing or planning to do *in vitro* fertilization and gamete intrafallopian transfer.

Machines Available

- Portable scanners with M-mode (linear or sector)
- Scanners with newer curved linear probe
- Combined scanners with M-mode (linear sector/convex)
- Phased array technology
- Annular phased array with dynamic focusing
- Scanners with Doppler and color Doppler
- Transvaginal probes.

What to Expect?

Whenever one goes in for an ultrasound machine one must be sure of what he/she expects out of the equipment; of course, the preference of the user is of priority. A proper market is necessary before deciding on the equipment. As there are more than 100 different models available, but only a few of these are ideal for the demands of modern-day scanning. By the time, author could go through the procedure of financial arrangements for ordering the actual equipment, there were 10 newer updated models in the western market. This makes the availability of upgradable instrument of interest and importance.

The most obvious division in machine design is between "real-time" and static scanners. Real-time produces moving images or cine ultrasound, whereas static scanners produce stills. In practice, the disadvantages of a static scanner outweigh the advantages.

To create a real-time image, pulses of sound must be launched automatically into each part of the anatomy to be scanned. A linear array probe uses large number of transducer crystals switched on, in turn, into a circuit to produce its pulse. This results in a rectangular image. A sector (fan-shaped) image is generated by phased array and mechanical scanners. The beams are swept across the anatomy like entering a dark room with a torch and swinging it side-to-side to see what is there **(Fig. 2.1)**. A curved probe is a modified linear array probe **(Figs 2.2A and B)**.



Figure 2.1: Sector transducer mechanical rotating type

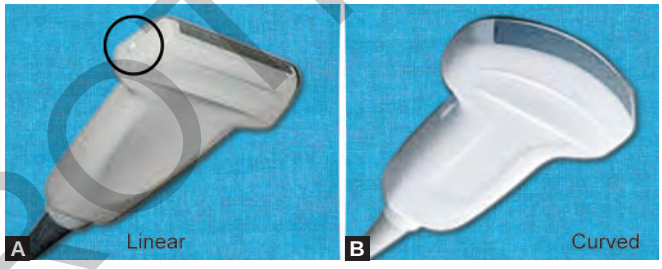

Figures 2.2A and B: (A) Linear and (B) Curved array probes

Assessment

The various areas of importance in the assessment of a scanner are as follows:

- *Image quality*: Probe design and signal processing
- *Ergonomics*: Image format, probe types, and control layout
- *Measurement facilities*: Caliper types, accuracy, look up tables
- Last but not the least, achieving safety, upgradability, and reliability.

Image Quality

Objective areas for consideration are resolution, textural contrast, and penetration. For all these qualities, we must consider the proper design and signal processing of the machine.

Resolution

Probe is a device which converts energy from one form to another. An ultrasound probe converts electrical

JAYPEE PROOFS

voltage into ultrasound pulses and vice versa. The probe element, made out of piezoelectric material, performs this function.

A sector probe produces a fan-shaped image, which can be generated by phased array and mechanical scanners. This probe is much lighter and smaller. The ease with, which this probe can be rapidly manipulated increases the diagnostic range.

Array probes are usually directly in contact with the patient's skin. Linear arrays are formed by a line of some hundreds of matchstick-shaped transducers laid side by side to produce a 100 mm long and 100 mm wide picture. The face may be curled rather than flat, so that each beam is produced at a slight angle to its neighbors to give a sector like image (curved linear probes).

Annular array probes are made from a series of ring-shaped transducers fitting one inside another. Phased array probes are small and particularly suited for cardiac imaging. They have a square cross section with a side of some 15 mm and yet contain about 60 narrow transducer elements in an array. This design enables the direction of the beam to be varied electronically according to the way the trigger pulses.

Probe design: A probe producing narrow sound beam is the best. This is achieved by focusing the beam, which can be done by three ways: (i) mechanical focus, (ii) dynamic focus, and (iii) focus on receive.

- *Mechanical focused probe*: In this, a rotating wheel probe may be driven by a motor in the handle; the transducers pointing through the acoustic window are selected. The other popular alternative is an oscillating transducer probe. The transducer here is driven through a linkage by a loudspeaker coil. If the beam emerges from the end of the probe, it is called "in line".
- *Dynamic focused probe*: Once constructed a mechanically focused system will only allow the beam to be focused at one depth. However, it is possible to produce a focus at any desired depth by electronic controls of an array of transducer elements. This is called dynamic focus.

  Recent development has been to build up a real-time image one depth layer at a time using a separate series of pulses for each depth. The beam is first focused to image superficial structures. Only echoes arising from the near to the probe are accepted for display. A second pass with the sound beam focused at the central region of the image is made and echoes from this region are accepted by "range gating". A range gate is an electronic switch, which allows echo signal through to the amplifiers for a short time. Typically, six levels of focusing may be used. Instruments with this facility allow the operator to select or focus at any given or to use all levels together.
- *Focus on receive*: This is used with array transducers. It allows the beam to be effectively focused at many depths from any single transmitted pulse.

Signal processing: The next most important aspect after focus is signal processing by the machine, the image may be manipulated to make certain features, such as organ outlines and textural changes, more obvious. It is also processed so that it can be handled easily by standard devices, such as videorecorders. These functions are given the general description of signal processing. This includes digitization, pixel size and line interpolation, and gamma correction.

Digitization or Digital scan converter (DSC): Digital processing provides convenience, flexibility, signal stability, and economy, which could not otherwise be reasonably achieved.

Pixel size and line interpolation: The reconstituted image is composed of a mosaic of small rectangular elements called pixels. The gray level assigned to each pixel represents the echo amplitude for the corresponding point in the section scanned. For this reason, the number and size of pixels in the image is important. A large number of small pixels in the image is desirable. Most images are composed of about 512 × 512 pixels.

Gamma correction: The digital signal is of value in gamma correction. The characteristic response of the eye to range of brightness values (its gamma curve) is different from that of a film. If the TV screen is photographed directly, the shades of gray on the film do not seem to correspond exactly with those seen on the screen. When the image is photographed the distribution of grays needs to be adjusted so that the film image corresponds to that what the eyes saw on display, and this is done by the gamma correction switch.

Scan conversion: One advantage of storing the image is that of scan conversion. A scan converter is a device which will allow the scan to be built up in one format and displayed in another. The image is stored in the converter memory, line by line as it is generated by the scanner but displayed on a television monitor in the horizontal form with which we are familiar. Displaying the image on video form has the advantage that high quality, low cost monitors, developed for the entertainment market,

JAYPEE BROTHERS

may then be used for display. By means of using a digital memory, the scan may be recorded at the same time as it is displayed. This is known as direct video. Displaying the image in a video format has further advantage that video tape and other video storage and display media can be used.

Textural Contrast

Tissue characterization: This is a development of textural contrast. It is an attempt to identify the type or state of tissue from the way in which it interacts with ultrasound pulse. Good machines will have a selector switch for textural contrast, and this is known as "post-processing" facility.

Penetration/Sensitivity

It is judged by the depth into the image at which resolution and textural contrast degrade significantly. Good sensitivity is achieved by using low frequency probes while good resolution depends on high-frequencies. Some machines are fitted with a sliding filter by which the superficial image is generated from the high frequency part of the pulse and deeper levels are generated by the more penetrating low frequencies.

Doppler Analysis

There has been recent interest in use of duplex probes. These contain a standard real-time mechanism in addition to Doppler transducer, which constrains the Doppler beam to the plane of the scan. The B scan is used to locate a moving structure or a blood vessel, such as fetal-aorta or the uterine arteries (**Figs 2.3A to C**).

Ergonomics (Adaptive Time Gain Compensation)

This is the skill, which the operator has to acquire, but now there are four systems for adjusting time gain compensation automatically. Each method has its drawbacks, and none gives consistently better results than can be obtained by a skilled operator using the manual controls.

Measuring Facilities

The essential accessories to a scanner are frame-freeze, measurement calipers, and microprocessor.

Frame-freeze

It is required to maintain the quality of original scan.

Measurement Caliper

It should allow simple and accurate measurement of length, circumference, and area from the display screen.

Joysticks: Calipers are often positioned by joysticks. The caliper spot is on the display so that its position corresponds to the position of the stick. Alternatively, stick may be sprung to self-center. The spot then can be moved across the image at a velocity corresponding to the displacement of the stick from its central position. There are advantages and disadvantages of both systems, and the choice is a matter of personal preference.

Light pens: Caliper may also put in position by a light pen, which operates directly on the display monitor. Although more expensive than joystick system, most operators find that for area and circumference measurement, the light pen is much easier to handle and less prone to error.

Microprocessor

This is most desirable in the equipment, as it enables to translate the measurements into mean growth value immediately.

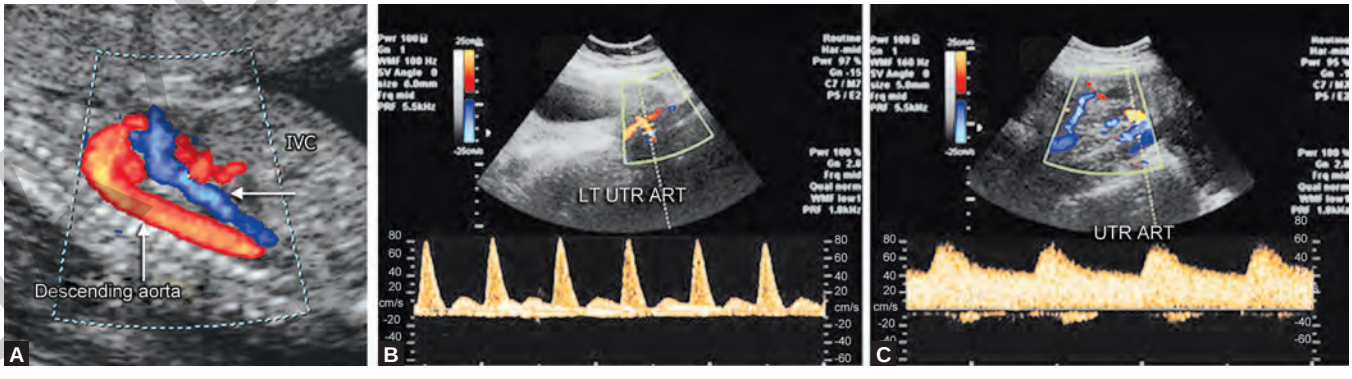

Figures 2.3A to C: (A) Color Doppler showing descending aorta; (B and C) Flow velocity wave showing flow in the uterine arteries in two different patients

JAYPEE BROTHERS

Other Features to Consider

Safety

It is widely assumed that manufacturers of ultrasound machines design their equipment to be as safe as possible both from electrical and mechanical hazards point of view and from the ultrasound intensity used. Whilst the first aspect is generally satisfactory, there is a temptation to improve the image quality by increasing the pulse intensity levels used. High intensity levels are undesirable. The problem may particularly occur when range-gated Doppler is used in a duplex scanner.

Design Upgradation

With rapid development of equipment, it is important to consider whether the equipment may be upgradable at a later date. Until the extensive use of microprocessors and digital processing, almost all significant developments require a complete redesign of the equipment. However, it is now probable that many improvements will be software based. In this case, it is reasonable to expect the instruments to be capable of upgradation.

New Addition

We all know that an abdominal sector probe is more convenient for gynecological scanning and early pregnancy, but it has a limited lateral field of view close to the transducers. But now recently, transvaginal sonography using a 5–8 MHz probe is replacing the original abdominal sector scan. There have been a number of studies to prove the superiority of vaginal approach of the pelvis over the abdominal one in terms of image clarity and higher resolution of anatomical details and accuracy of measurement. Another application of sector probe with modified design is for rectosonography useful for carcinoma of cervix, uterus, and to detect recurrent cases.

Development of Various Types of Transvaginal Probes and the Clinical Evolution

It is needless to say that transvaginal sonography is very useful diagnostic method in gynecological and obstetrical practices. Various types of transvaginal probes are being developed. At first, a cylindrical-shaped hand piece type probe was designed, which had a mechanically rotating transducer (5 MHz) with a radiating angle of 80°. The second one is a small round-shaped probe on which linear transducers (6.5 MHz) are arranged on a circle of 10 mm diameter giving a radiating angle of 82°. The probe is attached at the distal end of an angled hand-held stick. These two types of hand probes are easy to introduce into the vagina.

The third one is a type of the finger-tip probe, which has linear transducers (5 MHz) arranged on an area of a circle of 40 mm diameter giving 40° sector view. This probe is very easy to manipulate but rather difficult to have a good view in the direction of longitudinal axis of the examination finger. Therefore, the fourth type of probe has been designed as a real finger-cap type probe. The finger-cap probe is so small that it permits examiner to use it in the process of bimanual palpation.

In the words of Dr Goldstein at the recent World Congress at Washington, "We have to marry ultrasonography with palpation, and we can, in near future, hope to keep machines right next to our gynecological examination table, fit the finger-cap probe on our right index finger, and instead of feeling the uterus and adnexa for disease, we can actually visualize the pelvis at the first visit and examination of the patient."

Color Flow Imaging in Obstetrics: Understanding its Art, Science, and Technology

The latest advance in diagnostic ultrasound is color flow imaging, and the message today seems to be coming loud and clear "for more information turn on the color and look at what you were missing", "Use color to improve your image and to see what you have never seen before". It becomes of paramount importance to understand how colored images are formed. This technology of color presents an image in gray scale and blood flow in color. Although this began with echocardiography, but the latest development, points specifically at the vascular system.

The technology of color flow imaging deals with two points: (i) fundamental problems of imaging and (ii) clinical needs.

Imaging Problem

When the first color flow imaging was used, the images were so fascinating and different from the gray scale and duplex that many thought it was not ultrasound. Still like duplex and B-mode, imaging color flow has its own problems, despite the bright and dynamic images. These are as follows:

JAYPEE BROTHERS

- *Tissue attenuation*: Muscle, fat, plaque, connective tissue all rapidly attenuate signals, though these signals are very small but the echo signals from blood vessels are smaller to where our color flow is aimed
- Accurate blood flow sampling will depend upon pulsed Doppler simple volume geometry. The same flow will have a different frequency mix as the sample volume shape changes
- A color flow imaging system detects moving blood in color. This is easy to do when blood is the only echo source within the scanning field, which obviously is not leading to a complex mixing of signals at blood-vessel interface, strong tissue signals mix with weak blood signals and more so the vessel walls are not always still either. The technology must be able to adequately separate moving blood from the sometimes moving soft tissue. It must also separate different patterns in blood movement.

Color flow scanning takes us away from conventional imaging approaches to vessels and organs in the sense that B mode imaging traditionally seeks out the specular reflections of a structure. For color Doppler, the ultrasound beam is allowed to hif the vessels at an angle of less than 60° preferably less than 30°.

Clinical Uses

Color flow imaging points specifically at the vascular system. The word "vascular" will not mean only heart, carotids, or aorta but a huge system spread all over the body with systemic, neural, and hormonal controls. This vascular system of the body responds to stress, trauma, and drugs and hosts a very complex biochemistry for clot and thrombus formation. A successful vascular imaging system must be able to portray changes due to normal regulation, drugs, and disease. It must also do more than just put color on the display. Hence, if a color flow imaging system has to function as an effective clinical tool, it must be able to detect diseases and evaluate the extent of the disease.

Hence, in the arterial and venous system, color flow imaging should be able to tell us wall condition, lumen condition (stenosis), and intimal condition, should be able to detect plaque, predict the blood flows, and over and above it should be able to identify any neovascularization.

How the Color Image is Formed?

Color images are formed by two types, asynchronous and synchronous imaging. Asynchronous means, the gray scale and Doppler information are gathered at different times. In contrast, synchronous information is gathered simultaneously.

Asynchronous Color Flow Imaging

Two images are produced during scanning and are later superimposed. The gray scale comes from dynamically focused to form a real-time image. The Doppler image comes from steering another ultrasound beam at an angle to the array (0°–45°). The image is composed in a digital scan converter. Two different frequencies can be used for the two image components, e.g. system could have gray scale at 5 MHz and color at 3 MHz.

Synchronous Color Flow Imaging

This is simultaneous processing for amplitude, phase and frequency from the same echo signal. The technology is so different that it is known as angiodynography.

The linear array sends a dynamically focused beam, which is perpendicular to the vessels, good for imaging but not for Doppler. To provide the Doppler angle needed to visualize blood flow, a wedge stand-off sit between the array surface and skin surface.

The image is divided into a set of sample sites, which are same in the field of view. Within this site the system looks at the echo signal amplitude in one path and at the phase and frequency in the other. The machine now builds the image on a pixel basis, testing first for evidence of motion and its direction. If motion exists at pixel, it is colored, otherwise it takes on a gray scale proportionate to the echo signal strength. Having set out the image formation, the next step is color coding the pixels in which motion was detected.

Color Coding the Information

"Gray's Anatomy" color code is used by all of the color flow imaging systems. Flow in one direction is red and in opposite direction is blue. Now, because all of us are turned to the fact that all red vessels are arteries and blue are veins, it is all too easy to read the image wrong way. Even the most skilled readers fall prey to this reading error from time to time. It is to be noted and clarified that color indicates and represents existence of motion and direction of flow and not the vessel type.

Conclusion: Ideal Equipment

There is no such thing as the perfect ultrasound scanner, just as there is no perfect car. It all depends on what you

JAYPEE BROTHERS

want to do with it and how good a driver you are. There are a good number of machines, which are suitable for obstetric scanning. If you wish to use duplex scanning your choice may be different and more limited. The list below covers a number of points, ignoring cost which you should consider before selecting a machine:

- Always ask the agent to let you try the equipment in your clinic on your patients. Do not go on what you see at exhibitions
- Assess the images obtained for:
  - Good resolution between about 20 mm and 150 mm depth. To do this, look for some of the less obvious fetal structures. The range of structures which you could reasonably expect to see in good equipment is probably greatest in a late second or early third trimester pregnancy. If, for instance, you can see the lens of the fetal eye, the vessels of the umbilical cord and the epiphyses of long bones, then you are almost certainly using an adequate instrument.
  - Low noise and freedom from artifact. Be careful, if there are more than a minimal amount of spurious echo in the fetal and maternal bladder, or if there is an artifactual echo curving away from the sacral promontory or the fetal skull.
  - Acceptable contrast resolution: Determine whether the fetal kidney is easily seen and see, if it is possible to discriminate between the fetal liver and lung. Look for structures in the placenta of a pregnancy near term.
  - Good detail in the image it has been zoomed.
- Use the calipers
  - Do the marker pips remain in position when the image is frozen and unfrozen?
  - Can the pips be moved in a fixed relationship to each other by a single control?
  - Is it possible to display the reading with a precision of better than 1 mm?
  - Can areas be outlined easily or is an unusually steady hand required?
  - Is it possible to determine the area of a reportedly involuted section? Try measuring the area of an imaginary capital E.
  - Is it possible to correct outline error without starting again?
  - Are adequate tables converting measurements into fetal age or weight available from the keyboard?
- Consider the ergonomics
  - Is the probe tiring to use or difficult to hold?
  - Is the probe simple to orient so that you are sure of the scan plane at all times?
  - Can a needle be used?
  - Will the layout of the controls drive you to distraction?
  - Is it possible to move the equipment easily without steering it into doorposts or corridor walls and breaking off vital parts or shaking the electronic components out of place?

Summary

The advancement has been so fast that within a decade, we have the evolution from a static scanner to a real-time machine to today's technology and from huge linear probes to fingertip probes.

Before buying a machine, we should study our needs carefully and our future plans on upgradation, and then it is advisable to do a proper market survey. In this, we should actually handle the machine according to our cost effectiveness.

"Practice better medicine through better images."

Bibliography

1. Callen PW. Ultrasonography in Obstetrics and Gynecology. Philadelphia: WB Saunders Company Ltd; 1983.
2. Goldstein SR. Endovaginal Ultrasound. New York: Alan R Liss, Inc.; 1988.
3. Gynaecologic ultrasound course. American Institute of Ultrasound in Medicine, 1993.
4. Journal of Diagnostic Medical Sonography, Sep/Oct 1988.
5. Official proceedings, 1988 World Federation for Ultrasound in Medicine and Biology Meeting. J Ultrasound Med. 1988;7(10):S39-283.
6. Kurjak A, Zalud I. Doppler and color flow imaging. Transvaginal Ultrasound. Mosby Year Book; 1992: pp 285-94.
7. Pearce JM (Ed.). Doppler Ultrasound in Perinatal Medicine. Oxford: Oxford University Press; 1992.
8. Ultrasound in Obstetrics and Gynaecology: Recent Advances. In: Stuart Campbell (Ed.). Clinics in obstetrics and gynaecology. W.B. Saunders Ltd; 1983.
9. Wells PN. Doppler Instrumentation including color flow mapping. KJ Taylor, PN Burns, PN Wells (Eds). Clinical Applications of Doppler Ultrasound. New York: Raven Press; 1988.

JAYPEE BROTHERS

detailed information on obstetrics & gynecology books, visit our website www.jaypeebrothers.com, for detailed information on obstetrics &

Ultrasound in Obstetrics & Gynecology

Ultrasound is the find of the century. Ultrasound imaging has affected diagnosis in all specialties. This single, simple, realistic, reproducible, cost-effective test has revolutionized practice in all the branches of medicine.

The effect of ultrasound and its usefulness in obstetrics is paramount. Ultrasound is and will remain a modality for monitoring normal and abnormal pregnancy.

This revised textbook of *Ultrasound in Obstetrics and Gynecology* brings to you contributions from experts of the world. We are sure this book will be useful to students and practitioners also. Happy reading.



Narendra Malhotra



PK Shah



Pratap Kumar



Prashant Acharya



Sonal Panchal



Jaideep Malhotra

Available at all medical book stores
or buy directly from Jaypee Brothers through online shopping
at www.jaypeebrothers.com

JAYPEE BROTHERS
Medical Publishers (P) Ltd.
www.jaypeebrothers.com

Shelving Recommendation
OBSTETRICS & GYNECOLOGY

ISBN 978-93-5152-158-7