CONTENTS

1. Congenital Anomalies of Kidney and Ureter 1

1.1 Antenatal Pelviureteric Junction Obstruction 1
1.2 Bilateral Pelviureteric Junction Obstruction 3
1.3 Circumcaval Ureter 6
1.4 Crossed Renal Fused Ectopia 11
1.5 Retroiliac Ureter with Contralateral Transverse Malrotation of Kidney 14
1.6 Double Moiety with Pelviureteric Junction Obstruction Lower Moiety 17
1.7 Ectopic Pelvic Kidney 21
1.8 Ectopic Ureter 23
1.9 Equivocal Pelviureteric Junction Obstruction 27
1.10 Extrarenal Pelvis and Calyces 29
1.11 Incomplete Duplication of Ureter 32
1.12 Megapelvis 34
1.13 Primary Megaureter 38
1.14 Parapelvic Cyst 43
1.15 Pelviureteric Junction Obstruction with Ectopic Kidney 45
1.16 Persistent Umbilical Artery Causing Ureteral Obstruction 47
1.17 Pelviureteric Junction Obstruction with Calculi 50
1.18 Pelviureteric Junction Obstruction with Malrotated Kidney 53
1.19 Pelviureteric Junction Obstruction with Megapelvis 55
1.20 Pelviureteric Junction Obstruction with Single Kidney 57
1.21 Pelvic Ectopic Kidney 58
1.22 Ureterocele 60
1.23 Vesicoureteral Reflux 69

2. Congenital Anomalies of Lower Urinary Tract 71

2.1 Chordee without Hypospadias 71
2.2 Complete Duplication of Urethra 73
2.3 Penile Duplication 75
2.4 Bladder Exstrophy in Adult Males 77
2.5 Epispadias 80
2.6 Incomplete Duplication of Urethra 83
2.7 Megalourethra 86
2.8 Posterior Urethral Valve 88
2.9 Parameatal Cyst 91
2.10 Paraureteric Bladder Diverticulum 92
2.11 Undescended Testis 94
2.12 Penoscrotal Transposition 96
2.13 Webbed Penis 97

3. Adrenal Gland 98

3.1 Adrenal Pheochromocytoma 98
3.2 Adrenal Adenoma 101
3.3 Adrenal Cortical Adenoma Mimicking Pheochromocytoma 105
3.4 Adrenal Cyst 108
3.5 Conn's Syndrome 110
3.6 Castleman's Disease Mimicking Adrenal Tumor 111
3.7 Multiple Pheochromocytoma 114
3.8 Pheochromocytoma Involving Right Renal Artery 116
3.9 Pheochromocytoma with Calcification 118
3.10 Recurrent Pheochromocytoma 121

4. Kidney Tumors 126

4.1 Angiomyolipoma 126
4.2 Divergent Differential Pelvic Tumor 131
4.3 Hydatid Cyst of Kidney 135
4.4 Incidental Large Renal Tumors 139
4.5 Incidental Renal Cell Carcinoma with Adrenal Hyperplasia 141
4.6 Left Renal Cell Carcinoma with IVC Thrombus 143
4.7 Mucinous Adenocarcinoma of Renal Pelvis 147
4.8 Primary Malignant Neuroepithelial Tumors of the Kidney 152
4.9 Renal Cell Carcinoma—Partial Nephrectomy 156
4.10 Sarcomatoid Renal Cell Carcinoma 158
4.11 Cystic Renal Cell Carcinoma 161
4.12 Renal Cell Carcinoma Mimicking Adrenal Tumors 163
4.13 Renal Cell Carcinoma with Cholelithiasis 165
4.14 Renal Cell Carcinoma with Hypercalcemia 167
4.15 Renal Cell Carcinoma with Inferior Vena Cava Thrombus 172
4.16 Renal Cell Carcinoma with Metastasis 175
4.17 Pyrexia of Unknown Origin as Presentation for Renal Cell Carcinoma with Lung Metastasis 180
4.18 Renal Cell Carcinoma with Renal Calcification 184
4.19 Renal Cell Carcinoma with Calculi 185
4.20 Renal Pseudotumor 193
4.21 Renal Tumor with Renal Cyst 199
4.22 Splenic Tumor Mimicking Renal Cell Carcinoma 204
4.23 Incidental Detection of Transitional Cell Carcinoma of the Renal Pelvis 210
4.24 Von Hippel-Lindau Disease 216

5. Upper Tract Urothelial Tumor 221

5.1 Bilateral Transitional Cell Carcinoma of the Upper Tract 221
5.2 Small Superior Calyceal Tumor 229
5.3 Transitional Cell Carcinoma of the Renal Pelvis 232

6. Urolithiasis 237

6.1 Bilateral Renal Stones 237
6.2 Crossed Renal Ectopia with Calculi 241
6.3 Eggshell Calcification of Kidney 246
6.4 Endemic Calculi 249
6.5 Horseshoe Kidney with Calculi 253
6.6 Matrix Calculi 256
6.7 Megaureter with Calculi 258
6.8 Milk of Calcium in Kidney 261
6.9 Postnephrectomy Residual Ureteric Calculi 263
6.10 Prostatic Calculi 264
6.11 Steinstrasse Following Extracorporeal Shock Wave Lithotripsy 266
6.12 Ureteric Calculus—Abnormal Shape 269
6.13 Ureteric Stricture Following Ureteroscopy 271

7. Genitourinary Tuberculosis 273

7.1 Genitourinary Tuberculosis —Augmentation Cystoplasty 276
7.2 Genitourinary Tuberculosis—Gastric Augmentation Cystoplasty with Trans-uretero-ureteral Anastomosis 278
7.3 Genitourinary Tuberculosis—Renal Failure 283
7.4 Genitourinary Tuberculosis with Congenital Single Kidney 285
7.5 Genitourinary Tuberculosis with Replacement of Ureter 287
7.6 Genitourinary Tuberculosis with Renal Calcification 289
7.7 Genitourinary Tuberculosis with Multiple Organ Involvement 292
7.8 Genitourinary Tuberculosis with Nonfunctioning Kidney with Thimble Bladder 294
7.9 Genitourinary Tuberculosis—Partial Nephrectomy 296
7.10 Tubercular Ureteric Stricture 297
7.11 Tubercular Bladder 299
7.12 Tubercular Epididymitis 302
7.13 Tubercular Prostatitis 304

8. Neurovesical Dysfunction 307

8.1 Neurogenic Bladder with Sphincteric Weakness 307
8.2 Neurogenic Bladder with Urethral Diverticulum 314
8.3 Pine Tree Appearance with Neurogenic Bladder 315
8.4 Neurogenic Bladder with Vesicoureteral Reflux and Chronic Kidney Disease 317
8.5 Neurogenic Bladder with Incontinence of Urine 319

9. Urinary Bladder Diseases 321

9.1 Bladder Cancer with Parotid Metastasis 321
9.2 Bladder Dysplasia 325
9.3 Bladder Pheochromocytoma 328
9.4 Cloacal Anomaly with Bladder Tumor 331
9.5 Cystitis Cystica Glandularis 335
9.6 Foreign Body—Urinary Bladder 340

9.7 Paraureteric Diverticulum with Tumor 344
9.8 Bladder Diverticulum in Adults 348
9.9 Carcinoma Urinary Bladder in a 128-Year-Old Man 351
9.10 Carcinoma Bladder with Renal Stone 353

10. Prostatic Diseases 356

10.1 Benign Prostatic Hyperplasia with Bladder Diverticulum 356
10.2 Benign Prostatic Hyperplasia with Chronic Renal Failure 359
10.3 Carcinoma Prostate with Family History 361
10.4 Carcinoma Prostate with Metastasis in Bladder 363
10.5 Concurrent Carcinoma Prostate and Pancreatic Cancer 366
10.6 Granulomatous Prostatitis 368
10.7 Large Prostate with No Obstruction 370
10.8 Malakoplakia Prostate 372
10.9 Metastasis Lower Ureter from Cancer Prostate 376
10.10 Peau D'orange from Prostate Cancer 379
10.11 Postradiation Hemorrhagic Cystitis for Cancer Prostate 381

11. Urethral Diseases 384

11.1 Congenital Anterior Urethral Obstruction 384
11.2 Continent Diversion for Stricture Urethra 386
11.3 Foreign Body in Urethra 392
11.4 Gunshot Injury with Stricture Urethra and Recto-urethral Fistula 395
11.5 Lateral Perineoscrotal Flap Urethroplasty 399
11.6 Neophallus with Urethral Fistula 406
11.7 Post-hypospadias Stricture Urethra 408
11.8 Stricture Urethra—Syringocele 410
11.9 Supraprostatic Stricture Urethra 412
11.10 Transitional Cell Carcinoma of the Male Urethra 416
11.11 Complex Urethral Stricture in Children 421
11.12 Congenital Urethral Diverticulum 426
11.13 Post-urethroplasty Urethral Diverticulum with Calculi 428

12. Testicular Tumors 433

12.1 Non-Hodgkin's Lymphoma of Testis 433
12.2 Post-orchidopexy Testicular Tumor 442
12.3 Nonseminomatous Germ Cell Tumor 444

13. Penile Diseases 451

13.1 Corporal Abscess 451
13.2 Fracture Penis 455
13.3 Penile Strangulation 457
13.4 Peyronie's Disease 460
13.5 Penile Carcinoma In Situ 466

13.6 Preputial Tumor 468
13.7 Penile Melanoma 470
13.8 Lateral Curvature of the Penis 472

14. Female Urology 475

14.1 Bladder Stone Over Tension-free Vaginal Tape 475
14.2 Choriocarcinoma Urethra 478
14.3 Female Epispadias in Adults 480
14.4 Failed Tension-free Vaginal Tape 483
14.5 Female Exstrophy Bladder and Complete Urethral Epispadias in Adult 485
14.6 Malignant Melanoma Female Urethra 487
14.7 Gartner's Cyst 489
14.8 Paraurethral Cyst 491
14.9 Vault Recurrence Following Carcinoma Cervix 493
14.10 Ureterovaginal Fistula 497
14.11 Female Urethral Carcinoma 501
14.12 Urethral Caruncle 503
14.13 Uterovesical Fistula 505
14.14 Vesicovaginal Fistula with Bladder Calculi 507
14.15 Post-hysterectomy Bilateral Ureteric and Bladder Injury 509
14.16 Ureterovaginal Fistula with Ureteral Duplication 513

15. Miscellaneous 515

15.1 Chyluria 515
15.2 Filarial Scrotum 517
15.3 Intersex—True Hermaphrodite 519
15.4 Pelvic Lipomatosis 522
15.5 Postnephrectomy Residual Kidney 526
15.6 Renal Artery Aneurysm 532
15.7 Renal Lymphangioma 534
15.8 Retroperitoneal Fibrosis 539
15.9 Retrovesical Hydatid Cyst 542

Index 545

Chapter
2

Congenital Anomalies of Lower Urinary Tract

JAYPEE BROTHERS

2.1 CHORDEE WITHOUT HYPOSPADIAS

INTRODUCTION

Chordee is the congenital curvature of the penis. Usually, it is associated with hypospadias. "Chordee without hypospadias" is rare. This is also known as "congenital short urethra" or "congenital ventral curvature of the penis". Chordee without hypospadias is classified as: (A) Cutaneous chordee; (B) Fibrous chordee; (C) Corporocavernosal chordee; (D) Urethral tethering with hypoplastic urethra; (E) Congenital short. Surgery has to be modified according to the classification.

CLINICAL CASES

Case 1

A 24-year-old male presented with abnormal curvature of the penis. On examination, he had prepuce in normal position with ventral chordee (Figs 2.1.1A and B). The penile skin was not tethered. On exploration, urethra was found short. Division of the urethra and dorsal preputial graft urethroplasty was done in single stage.

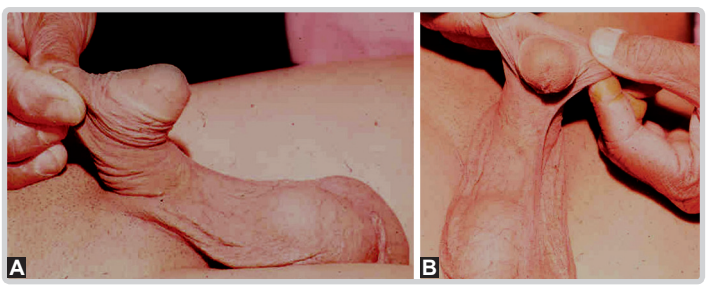

Fig. 2.1.1A and B: Case 1—Clinical pictures

Case 2

A 6-month-old child was brought by parents for abnormal curvature of penis. On examination, dorsal hood of the prepuce was well developed (Fig. 2.1.2). The meatus was of normal size and normal position. Dorsal chordee was present. The parents were counseled and advised for surgery at the age of 1 year.



Fig. 2.1.2: Case 2—Clinical picture

COMMENTS

Chordee without hypospadias is a rare condition. According to etiology and classification, surgery should be planned. Surgery can be done in one or two stages.

BIBLIOGRAPHY

1. Dipaola G, Spalletta M, Balducci T, et al. Surgical treatment of chordee without hypospadias. Eur Urol. 2000;38(6):758-61.

JAYPEE BROTHERS

2.2 COMPLETE DUPLICATION OF URETHRA

INTRODUCTION

Duplication of urethra is an uncommon anomaly. Most duplications occur in the same sagittal plane, on top of the other. In the dorsal variety, the normal urethra is in the ventral position and the channel normally ends in a normal meatus of the glans. The accessory (abnormal) channel opens on the shaft in an epispadic position anywhere from the glans to the base of the penis. Often, dorsal chordee is present and foreskin may be infused dorsally.

Complete duplication of the urethra with a single bladder is an exceptional finding. The anomalous urethral canal originates from the bladder separately, runs parallel and usually dorsal to the normally situated urethra, and opens on the dorsum of the penis. Conservative therapy is the treatment of choice, and that surgery should be reserved for incontinent patients only. Because the normally positioned urethra has a normal bladder neck and sphincter mechanism, excision of the abnormal, epispadiac urethra will usually cure any incontinence affecting the patient.

CLINICAL PRESENTATION

A 25-year-old male presented with abnormal opening in the penis and incontinence of the urine. Examination revealed normal urethral meatus with abnormal opening dorsally (Fig. 2.2.1). A ureteric catheter could be passed in the abnormal urethra. Cystoscopy was done and cystoscope could be passed in both urethra (Fig. 2.2.2). Excision of the accessory dorsal urethra was done.

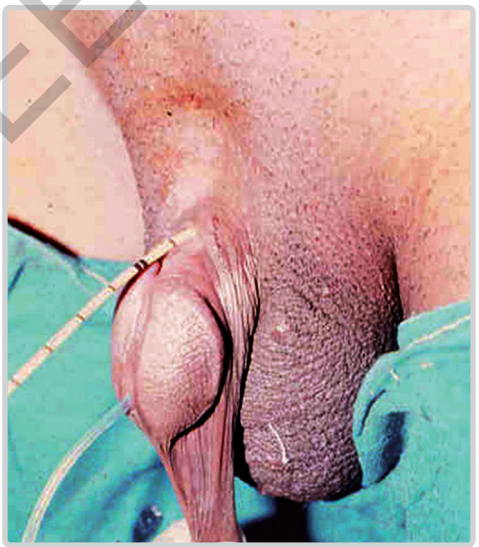

Fig. 2.2.1: Clinical picture

JAYPEE BROTHERS



Fig. 2.2.2: Cystoscope in both urethra

COMMENTS

Complete duplication of urethra is a very rare anomaly, but can be managed successfully.

BIBLIOGRAPHY

1. Alanee S, Gupta P, Gleich P, et al. Complete urethral duplication: description of surgical approach mimicking distal epispadias repair. J Pediatr Urol. 2012;8(4):343-7.
2. Susan LP, Roth RB, Kaminsky AF. Complete duplication of urethra. Urology. 1975;05(3):390-3.

JAYPEE BROTHERS

2.3 PENILE DUPLICATION

INTRODUCTION

Diphallia, penile duplication (PD), diphallic terata, or diphallasparatus, is a rare medical condition in which a male infant is born with two penises. It has a spectrum from a small accessory penis to a complete duplication. The first reported case was by Johannes Jacob Wecker in 1609. Its occurrence is one in 5,500,000 men in the United States.

When diphallia is present, it is usually accompanied by other congenital anomalies such as renal, vertebral, hindgut or anorectal duplication. There is also a higher risk of spina bifida. Treatment must be individualized to attain a satisfactory functional and cosmetic result.

CLINICAL PRESENTATION

A 5-year-old male presented with history of double penis. There were no urinary complaints.

EXAMINATION

Examination revealed two well-developed, equal size penises (Fig. 2.3.1). There was no other congenital anomaly. The parents were counseled, but they refused for any treatment.



Fig. 2.3.1: Clinical picture showing double penis

JAYPEE BROTHERS

COMMENTS

Complete duplication of the penis is a very rare condition and should be managed according to merit.

BIBLIOGRAPHY

1. Fowler MF. Double penis: report of a case with surgical management. Am Surg. 1963;29:555-6.
2. Hollowell JG Jr, Witherington R, Ballagus AJ, et al. Embryologic consideration of diphallus and associated anomalies. J Urol. 1977;117(6):728-32.

JAYPEE BROTHERS

2.4 BLADDER EXSTROPHY IN ADULT MALES

INTRODUCTION

Bladder exstrophy, cloacal exstrophy and epispadias are variants of exstrophy-epispadias complex. The etiology of this complex has been attributed to the failure of the cloacal membrane to be reinforced by in-growth of mesoderm.

The incidence of bladder exstrophy is between one in 10,000 to one in 50,000 live births. Usually these birth defects are noticed immediately after birth and managed accordingly. It is rare to see an adult presenting with exstrophy of bladder but in India, due to unawareness, poverty and lack of medical care, the patients present late in life. Due to prolonged exposure of bladder mucosa, malignant changes can occur and bladder loses its pliability and patient may require cystectomy.

The primary objectives of the management are: (1) Secure abdominal wall closure; (2) Urinary continence with preservation of renal function and; (3) Reconstruction of functional and cosmetically acceptable external genitalia.

CLINICAL CASES

Case 1

A 20-year-old male presented with a defect in lower abdominal wall and genitalia, continuous leak of urine from same site since birth. He was operated for right inguinal hernia at the age of 6 years. He had no other surgical intervention. Examination revealed exposed bladder with epispadias (Fig. 2.4.1).



Fig. 2.4.1: Case 1—Clinical picture

JAYPEE BROTHERS

Investigations

Plain X-ray of the pelvis revealed widening of the symphysis pubis and soft tissue shadow of the penis (Fig. 2.4.2). Intravenous urogram revealed normal upper tracts and no contrast in the bladder (Fig. 2.4.3). Bladder biopsy showed squamous dysplasia.



Fig. 2.4.2: Case 1—Plain X-ray of the pelvis



Fig. 2.4.3: Case 1—Intravenous urogram

JAYPEE BROTHERS

Treatment

In view of changes in the bladder, cystectomy and continent diversion was done followed by correction of the epispadias.

Case 2

A 26-year-old male presented with similar complaints as in case 1 (Fig. 2.4.4) and same treatment was done.



Fig. 2.4.4: Case 2—Clinical picture

COMMENTS

Bladder exstrophy in adult males is very rare. Due to unawareness and poverty, such patients present with it in adult age in developing countries. Due to dysplastic changes in the exposed mucosa, the risk for malignancy increases, and bladder closure with continence chances are less. In view of this, cystectomy and continent diversion is advisable.

BIBLIOGRAPHY

1. Nerli RB, Kamat GV, Alur SS, et al. Bladder exstrophy in adulthood. Indian J Urol. 2008;24(2):164-8.

JAYPEE BROTHERS

2.5 EPISPADIAS

INTRODUCTION

Epispadias is a rare defect that is present at birth (congenital). It varies from a glandular defect in a covered penis to the penopubic type with incontinence, to the complete variety associated with bladder exstrophy.

The causes of epispadias are not known. It may occur because the pubic bone does not develop properly. Epispadias can occur with bladder exstrophy. In this rare birth defect, the bladder is inside out and sticks through the abdomen wall. Epispadias can also occur with other birth defects. Epispadias occurs in one out of every 117,000 newborn boys and one in 484,000 newborn girls. The condition is usually diagnosed at birth or soon afterwards.

Males usually have a short, wide penis with an abnormal curve. The urethra usually opens on the top or side of the penis instead of the tip. However, the urethra may be open along the whole length of the penis.

Signs include abnormal opening from the bladder neck to the area above the normal urethra opening, backward flow of urine into the kidney (reflux nephropathy), urinary incontinence, urinary tract infections and widened pubic bone.

Patients who have more than a mild case of epispadias will need surgery. Leakage of urine (incontinence) can often be repaired at the same time. However, second surgery may be needed in some cases.

CLINICAL CASES

Case 1

A 21-year-old male presented with abnormal urethral opening over the dorsum of the penis. He was continent with no operative intervention in past. Examination revealed short, wide penis with abnormal opening of the urethra at the dorsum of the penis (Fig. 2.5.1). There was no chordee. Double layered urethroplasty was done.

Case 2

A 24-year-old male presented with abnormal urethral opening over the dorsum of the penis. Examination revealed similar finding as in Case 1 (Fig. 2.5.2). Urethral reconstruction was done.

JAYPEE BROTHERS

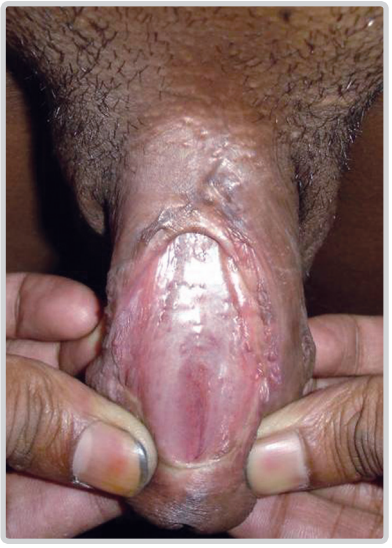

Fig. 2.5.1: Case 1—Clinical picture



Fig. 2.5.2: Case 2—Clinical picture

Case 3

A 26-year-old male presented with ectopia vesicae with epispadias since birth. First stage closure of ectopia vesicae was done during childhood. He presented with short penis and abnormal curvature towards abdomen during erection. He also had stress incontinence. Examination revealed short, wide penis with ventral chordee (Figs 2.5.3 and 2.5.4). Young-Dees-Leadbetter bladder neck reconstruction and urethral reconstruction was done. Figure 2.5.5 shows clinical picture after surgery.



Fig. 2.5.3: Case 3—Clinical picture

JAYPEE BROTHERS

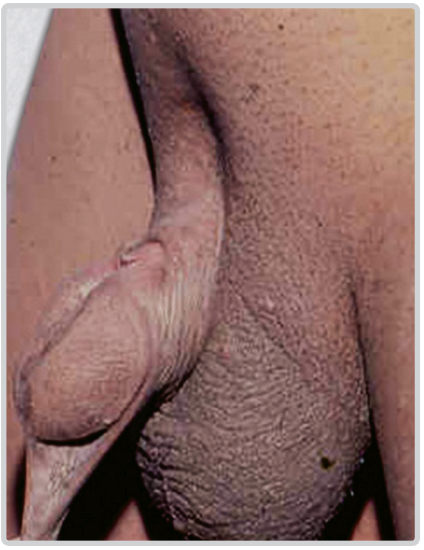

Fig. 2.5.4: Case 3—Clinical picture



Fig. 2.5.5: Case 3—Clinical picture after surgery

Follow-up

His incontinence improved and had straight erect penis, but size remained short.

COMMENTS

Incomplete epispadias has good outcome after surgery, whereas in the complete variety of epispadias, the outcome may not be satisfactory.

BIBLIOGRAPHY

1. Dees JE. Congenital epispadias with incontinence. J Urol. 1949;62(4):513-22.
2. Kramer SA, Kelalis PP. Assessment of urinary continence in epispadias: review of 94 patients. J Urol. 1982;128(2):290-3.

JAYPEE BROTHERS