r website www.jaypeebrothers.com, for detailed information on radiology books, visit our website www.jaypeebrothers.com

ATLAS OF MAGNETIC RESONANCE IMAGING

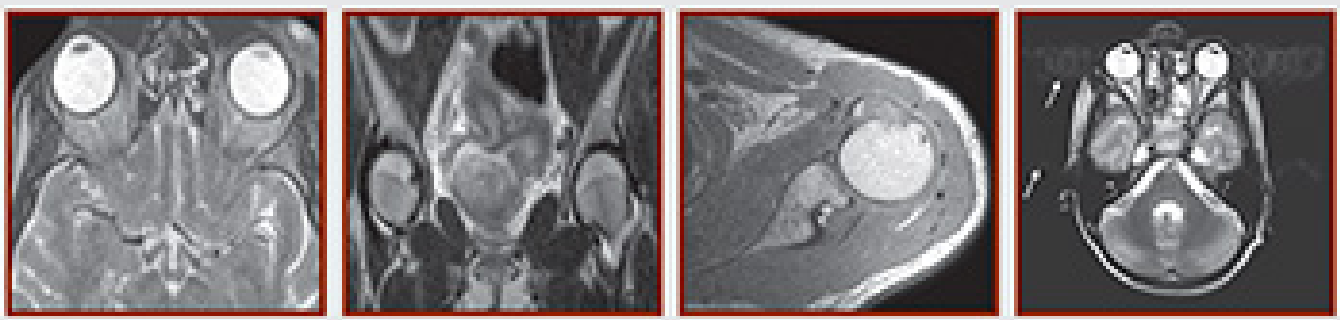

Hariqbal Singh
Vikash Ojha
Santosh Konde

JAYPEE

Contents

1. **Physical Principle of Magnetic Resonance Imaging** **1**
   Parvez Sheik

2. **Brain** **4**
   Hariqbal Singh, Vikash Ojha

3. **Orbit** **98**
   Aditi Dongre

4. **Spine** **106**
   Varsha Rangankar

5. **Pelvis** **185**
   Abhijit Pawar

6. **Musculoskeletal System** **203**
   Santosh Konde, Hariqbal Singh

7. **Miscellaneous** **299**
   Sikandar Sheikh

8. **Self Assessment** **311**
   Amol Sasane

9. **MRI Artifacts** **338**
   Manisha Hadgaonkar

10. **MRI Contrast** **342**
    Subodh Laul

11. **Glossary of MRI Terms** **344**

12. **MRI Acronyms** **348**

Index ***351***

2 Brain

Hariqbal Singh, Vikash Ojha

ANATOMY OF BRAIN

The human brain is most complex organ in the body. It develops from the neural tube, undergoes complex divisions (Flow chart 1) to form the forebrain (prosencephalon), midbrain (mesencephalon) and hindbrain (rhombencephalon) (Figs 1A to P).

The forebrain or prosencephalon consists of

- The telencephalon which comprises of the cerebral cortex, basal ganglion, corpus striatum and olfactory bulb
- The diencephalon, which is made up of the thalamus, subthalamus, hypothalamus epithalamus and metathalamus.

Cerebral hemispheres are on either side of the cranial cavity above the tentorium cerebelli. On MRI, the axial, coronal and sagittal sections provide excellent view of the various cerebral lobes and their pathology. The cerebral hemisphere is separated from each other in midline by the interhemispheric fissure. The interhemispheric fissure extends from the floor of anterior cranial fossa to the posterior cranial cavity. In the middle part of the interhemispheric fissure lies

Flow chart 1: Brain structure and their divisions

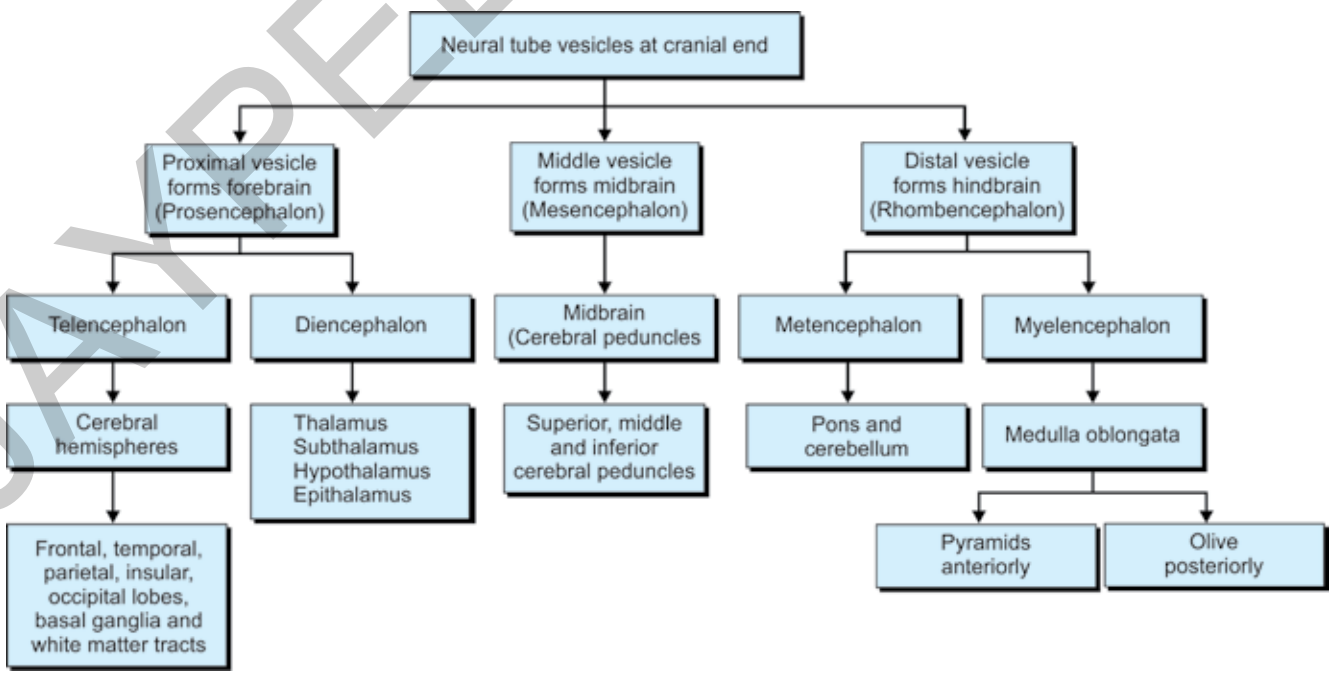

JAYPEE BROTHERS

the corpus callosum which connects the two cerebral hemispheres in midline.

The gray matter and white matter are appreciated on axial, coronal and sagittal T1W images. The gray matter on cerebral hemispheres is located on the outer aspect while the white matter also called as centrum semiovale is located deep in cerebral hemispheres. Some white matter extends from centrum semiovale into the cortical gyri; these are called subcortical white matter. The cortical gyri are separated from each other by cleft like involutions known as cortical sulci.

The cortical sulci help in subdividing the cerebral hemispheres for descriptive purposes into:

- *Frontal lobe* (Figs 1L to O, 2C, and 3A and B) is the anterior part of cerebral hemisphere, it is limited posteriorly by the central sulcus (of Rolando) and inferiorly by the Sylvian fissure. The frontal lobe has prominent gyri like the superior frontal gyrus, medial frontal gyrus and lateral frontal gyrus appreciated on T1W sagittal and coronal sections.
- *Parietal lobe* (Figs 1L to P) lies posterior to the central sulcus (of Rolando) and extends up to the parieto-occipital sulcus beyond which the occipital lobe begins. The inferior border of parietal lobe is related to the Sylvian fissure.
- *Insular region* (central lobe) (Figs 1L, 2F and 3I) is a submerged area of cortical tissue in the posterior ramus of the Sylvian fissure (lateral sulcus). The insular region is appreciated on axial, coronal and sagittal sections on T1W and T2W images. The insular region receives contributions from the temporal, frontal, and parietal lobes. The insular region is surrounded by the circular sulcus (of Rolando). The insular region is supplied by branches from the middle cerebral artery. Middle cerebral artery infarcts characteristically reveal a hyperdense thrombus on axial T1W images in insular region (known as the "Insular ribbon sign").
- *Temporal lobe* (Figs 1E to I) is located below the sylvian fissure. It is visualized on T1W images in axial, coronal and sagittal sections. It has superior, middle and lower temporal gyri. The temporo-occipital gyrus is seen posterior aspect of temporal lobe. The hippocampal gyrus is seen on sagittal T1W sections. The upper part of the superior temporal gyrus contains the transverse temporal gyri of Heschl—the main auditory areas, Brodmann areas 41, 42. Lesions in the auditory areas usually do not lead to complete deafness because each auditory area receives auditory impulses from both the ears-each lateral lemniscus in the brainstem contains fibers derived from both the cochlear nuclei.
- *Occipital lobe* (Figs 1F, G, M and O) is located at the posterior aspect of cerebral hemisphere; it is limited anteriorly by the parieto-occipital sulcus. It is well visualized on T1W images in axial, coronal and sagittal sections. The tentorium cerebelli on its inferior aspect separates the occipital lobe from cerebellar hemispheres.

Basal ganglia are central gray matter nuclei in each cerebral hemisphere and consist of the caudate nucleus, lentiform nucleus, claustrum and amygdala. The basal ganglia are seen on T1W and T2W images in axial, sagittal and coronal sections. Corpus striatum is a collective term for the caudate nucleus and lentiform nucleus. The anterior and posterior limbs of internal capsule lie between the basal ganglia and thalamus.

The basal ganglia is subdivided for descriptive purposes into:

- *Caudate nucleus* (Figs 1K, 2F, G and 3G) has a head, body and tail. The head and body of caudate nucleus is seen on T1W axial, coronal and sagittal sections. The head of caudate nucleus abuts the frontal horn of lateral ventricle. The body of caudate nucleus lies along the periventricular region of lateral ventricles. The tail of caudate nucleus is seen on T1W sagittal and coronal images. The tail of caudate nucleus is narrow; it is superolateral to the thalamus.
- *Lentiform nucleus* (Figs 1K and 2G) appears as a wedge shaped nucleus. It is located lateral to the caudate nucleus and thalamus on T1W images in axial and coronal MRI sections. The lentiform nucleus is separated from the caudate nucleus by the anterior limb of internal capsule.

The posterior limb of internal capsule separates the lentiform nucleus from thalamus. The lentiform nucleus has two components, an outer putamen and an inner globus pallidus. The sublentiform part of the internal capsule passes

JAYPEE BROTHERS

under the lentiform nucleus to the auditory cortex. The main afferent fibers come from the cortex, substantia nigra and thalamus. Fibers from the putamen mostly end in the globus pallidus. Efferent fibers from globus pallidus reach thalamus, subthalamic nuclei, hypothalamus, red nucleus, substantia nigra and reticular formation. The final outflow tracts reach the spinal cord via the rubrospinal and rubro-reticulospinal tracts. Lesions of the basal ganglia lead to extra-pyramidal effects such as dyskinesias, rigidity and tremor.

- *Claustrum* (Fig. 3I) is a thin strip of saucer-shaped nucleus which is located lateral to the putamen. It is easily seen on axial and coronal section in T1W images.
- *Amygdala* is located in the roof of the temporal horn of lateral ventricle. It contains nuclei which are connected to the tail of caudate nucleus and the limbic system. Stria terminalis is the efferent connection of amygdala connecting the amygdala to the anterior hypothalamus.
- *Internal capsule* (Figs 1L, 3G and H) is seen on axial and coronal sections on MRI. It is a compressed white band of projection fibers going to and from

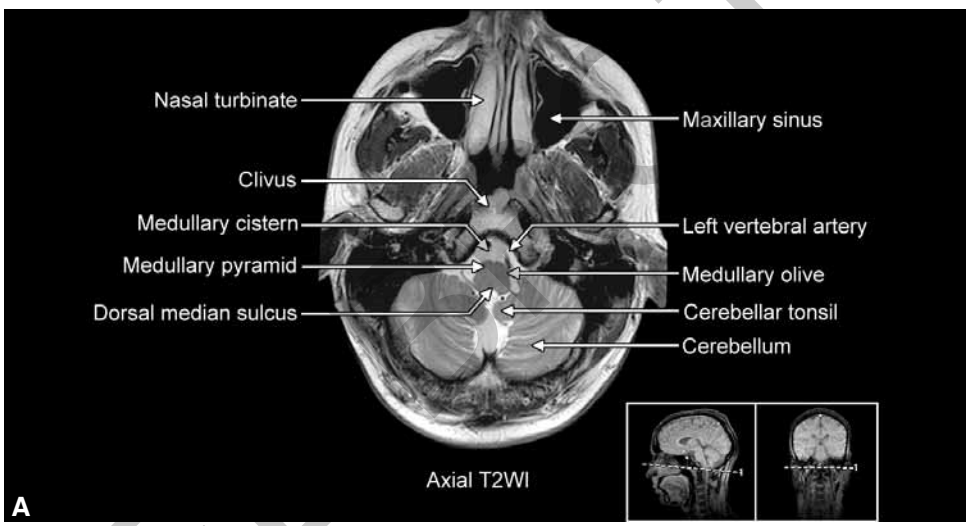

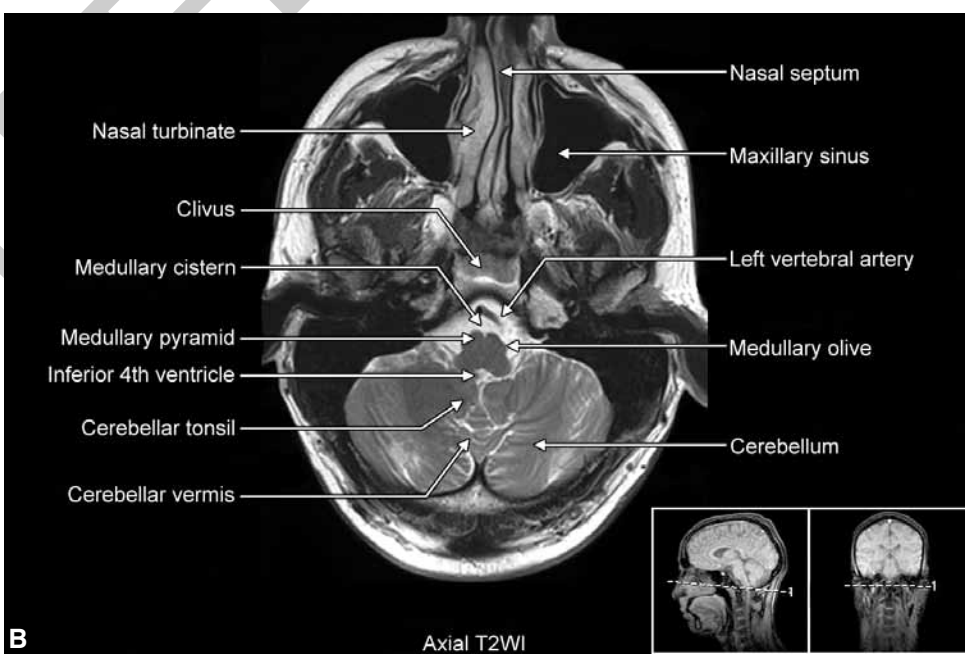

JAYPEE BROTHERS

the brain. It lies medial to the lentiform nucleus and lateral to the caudate nucleus and thalamus. It has five parts: (1) Anterior limb; (2) Genu; (3) Posterior limb; (4) Retrolentiform part and (5) Sublentiform part.

The anterior limb, genu and posterior limb contain frontopontine fibers.

The retrolentiform part contains the occipitopontine fibers and a few parietopontine fibers.

The sublentiform part contains the parietopontine and the temporopontine fibers. The corticonuclear fibers are located in the genu of the internal capsule. The posterior limb contains corticospinal and corticorubral fibers. Vascular lesions of the internal capsule can cause extensive damage. Lesions of the genu can cause paralysis of face of the opposite side due to involvement of corticonuclear fibers for head and neck. Lesions of the posterior limb can cause extensive contralateral hemiplegia and loss of sensations on the opposite side of the body. Lesions of the retrolentiform and sublentiform parts can cause visual and auditory defects. By far the commonest cause of lesions is the rupture of one of the branches of the middle cerebral artery (Lenticulostriate arteries – Charcot's artery of cerebral hemorrhage).

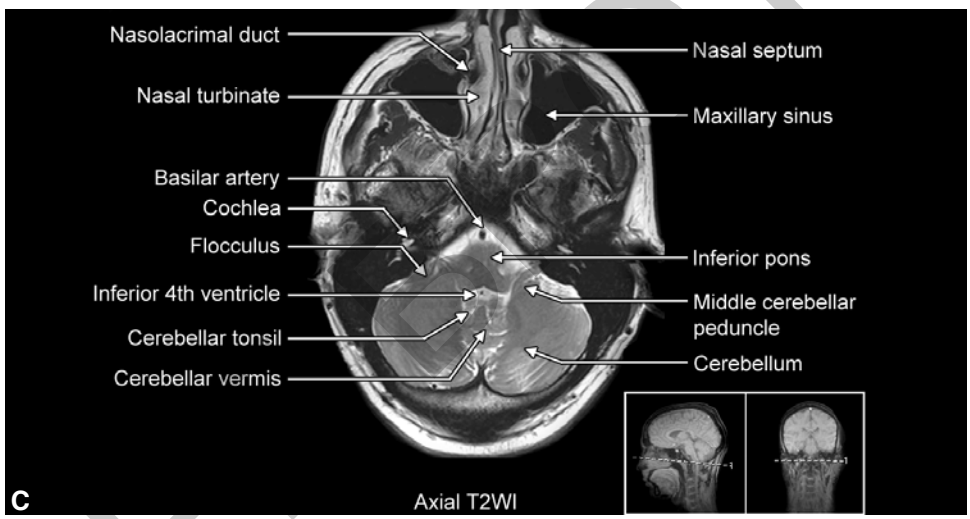

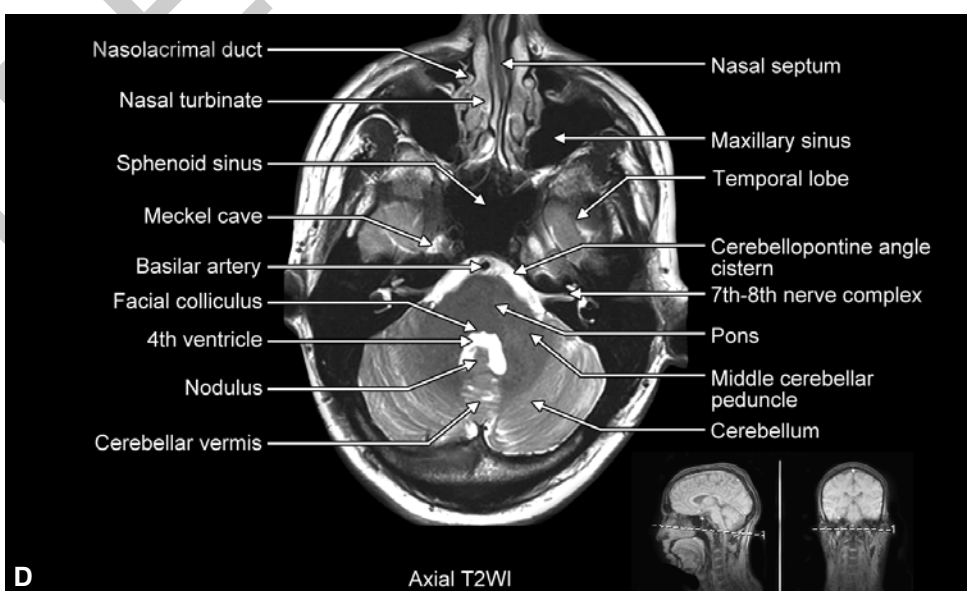

JAYPEE BROTHERS

White matter tracts consist of corpus callosum, commissural fibers and corona radiata. The perivascular spaces (of Robin Virchow) surround the striatal vessels and appear as oval areas of bright signal intensity. The white matter tracts are subdivided for descriptive purposes into:

- *Corpus callosum* (Figs 1L to N, 2A and 3G) is the largest commissural white matter tract of the brain. It connects the two cerebral hemispheres. It consists of rostrum, genu, trunk and splenium.

The large rounded splenium forms the posterior end of corpus callosum. The corpus callosum develops in an anterior to posterior end, the genu forms first followed by the body and splenium, the rostrum is the last to develop. On MRI images the genu and rostrum show slightly lower signal intensity as compared to the body and splenium. The rostrum of corpus callosum continues inferiorly to join the lamina terminalis. The body of corpus callosum lies over the roof of

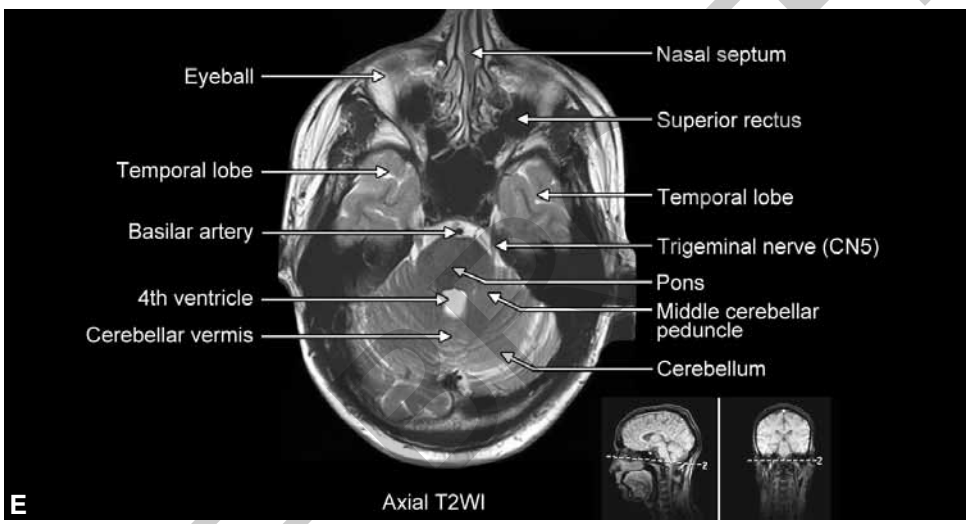

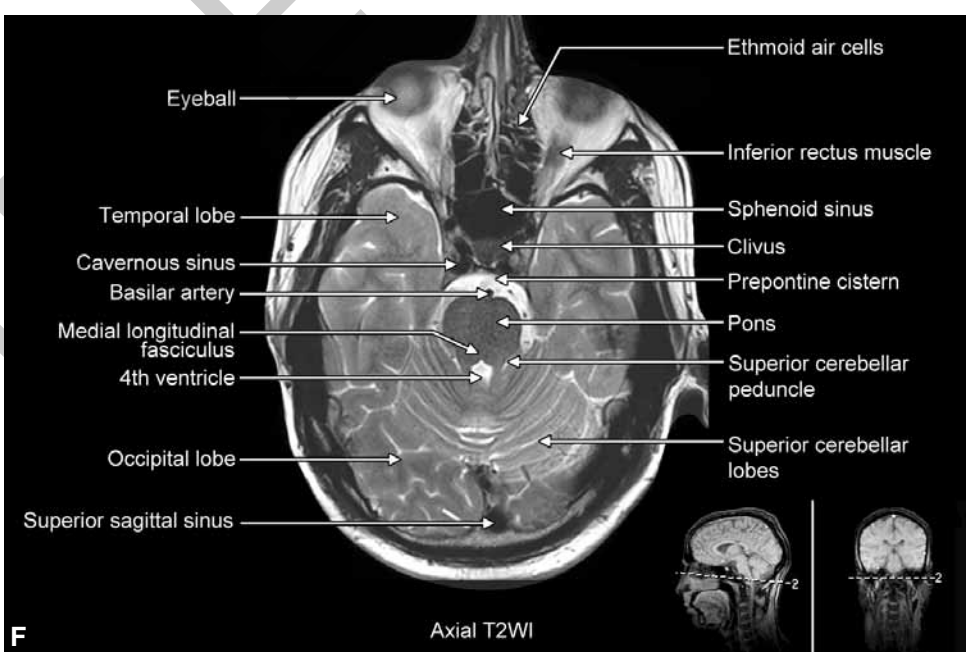

JAYPEE BROTHERS

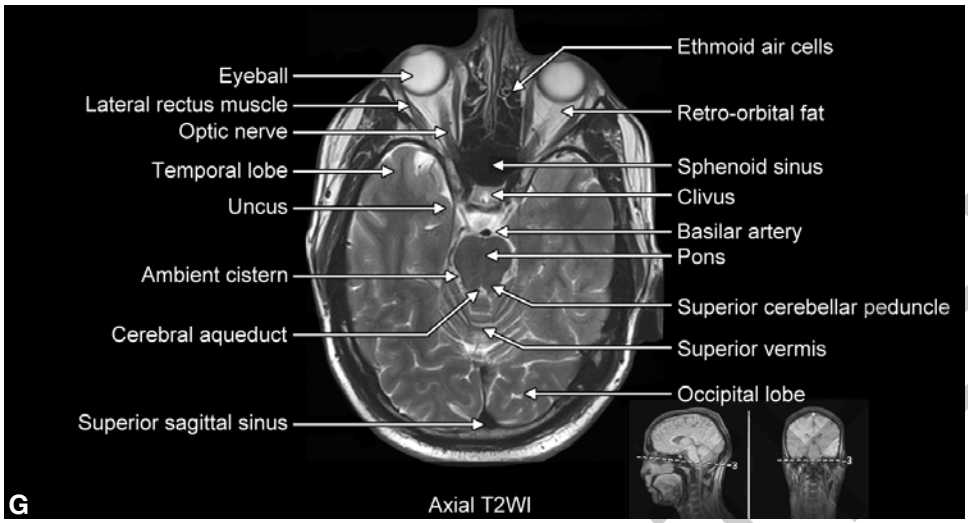

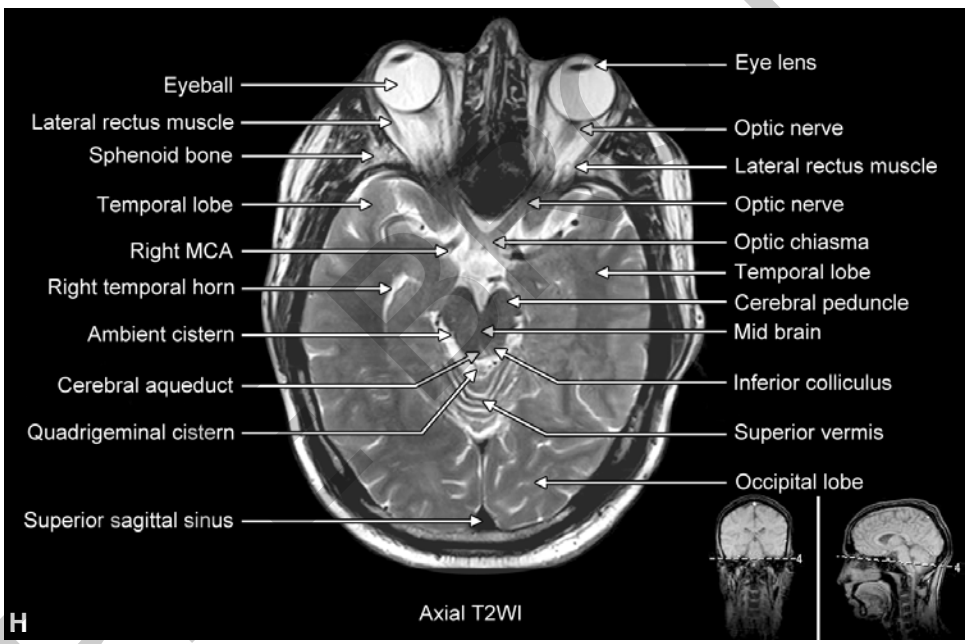

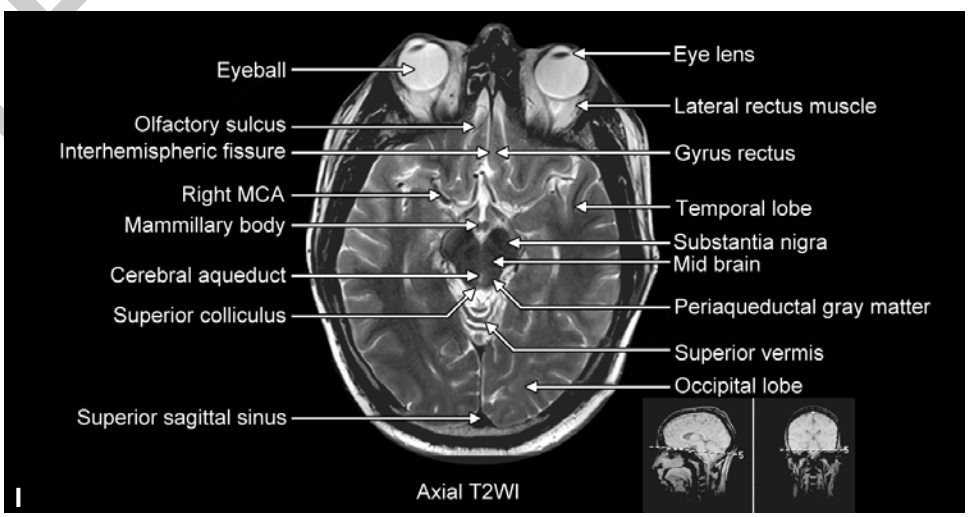

JAYPEE BROTHERS

lateral ventricle. The splenium of corpus callosum overlies the pineal body and colliculi. Fibers from the occipital lobes run forwards, cross to the opposite side in the splenium and reach the occipital lobe of the opposite side forming forceps major.

- *Forceps major* (Fig. 2F) are commissural fibers that run from the occipital lobe and loop through the splenium of corpus callosum to the opposite occipital lobe.
- *Forceps minor* (Fig. 2F) are commissural fibers that run from the frontal lobe and loop through the anterior part of corpus callosum to the opposite frontal lobe.

Diencephalon consists of the thalamus, hypothalamus, subthalamus, epithalamus and metathalamus.

- *Thalamus* (Figs 1L, 2B and D) is an ovoid structure of brain seen on axial, sagittal and coronal MRI sections. The thalamus lies lateral to the third ventricle and medial to the posterior limb of

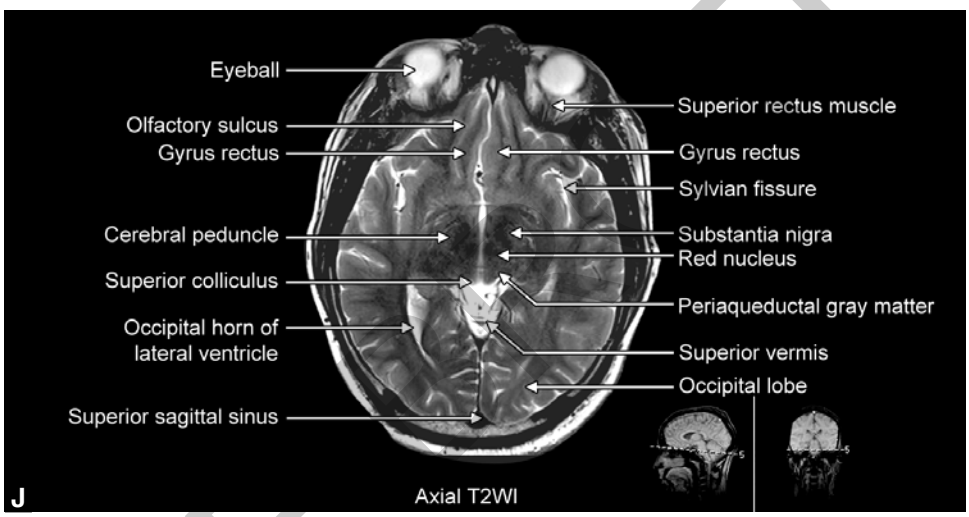

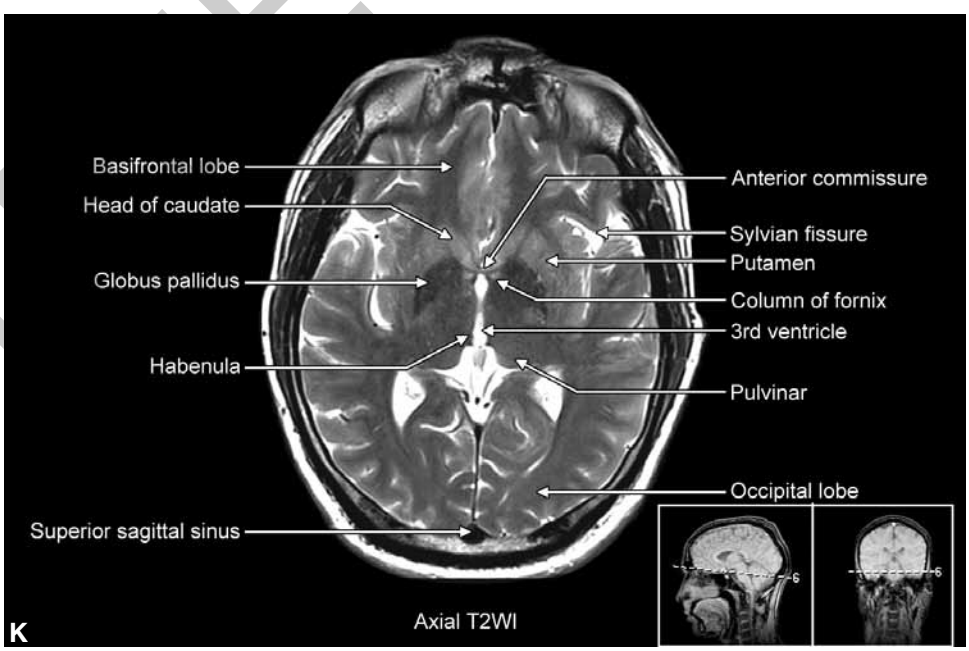

JAYPEE BROTHERS

internal capsule. The thalamus contains a large number of nuclei. The important nuclear groups are lateral, medial and anterior nuclei. The ventral posterior nucleus is a part of the lateral nuclear group and receives inputs from medial, spinal and trigeminal lemniscus. Fibers from here pass to the sensory part of the cerebral cortex. Some parts of lateral nucleus receive fibers from the dentate nucleus of the cerebellum and globus pallidus. The fibers project to the motor areas of the cerebral cortex. The medial group of thalamic nuclei receives fibers from the hypothalamus, corpus striatum and frontal lobes. The medial group of nuclei appears to be concerned with emotions and memory. The anterior group of thalamic nuclei receives fibers mainly from the hypothalamus via

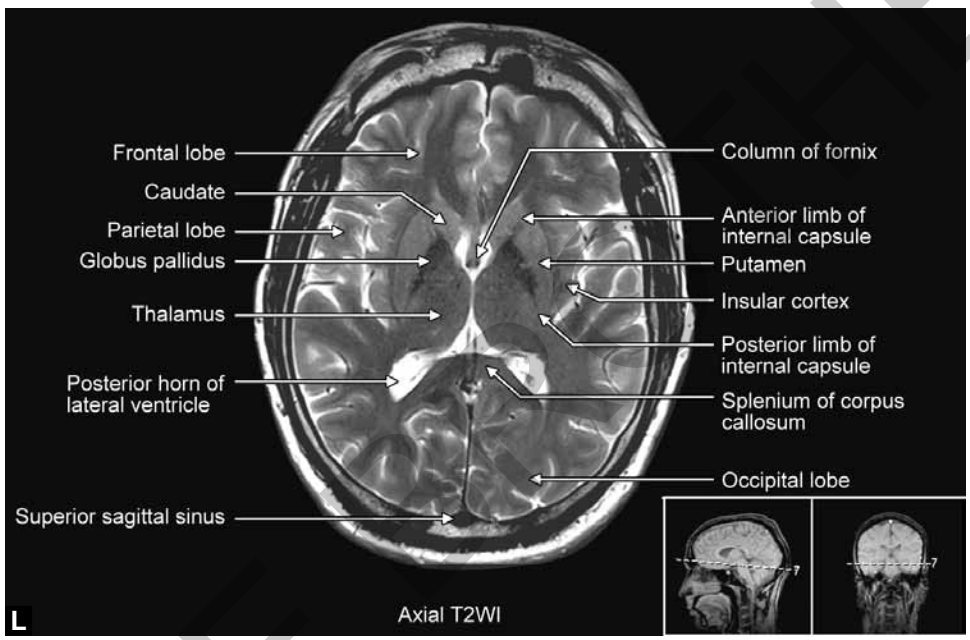

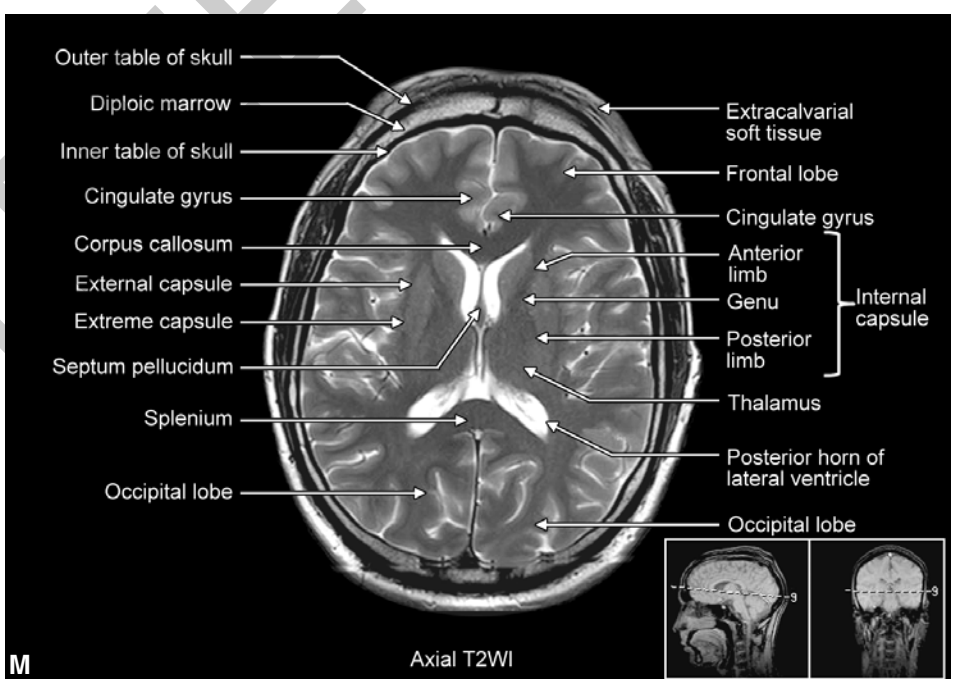

JAYPEE BROTHERS

the mamillothalamic fasciculus. Most ascending tracts pass through and relay in the thalamus as they proceed towards the cortex of the cerebral hemispheres. Fibers from anterior nuclei project to cingulate gyrus—part of the limbic system. The geniculate bodies, medial and lateral are two rounded bodies forming the posterior aspect of the thalamus. The medial geniculate body is a relay station in the auditory pathway; the lateral geniculate body is a relay station in the visual pathway.

- *Metathalamus* is formed by the medial and lateral geniculate bodies. The geniculate bodies' main function is to serve as relay stations for the visual and auditory pathways. The medial geniculate body is a part of the auditory pathway; the inferior brachium connects the medial geniculate body to the inferior colliculus. The medial geniculate

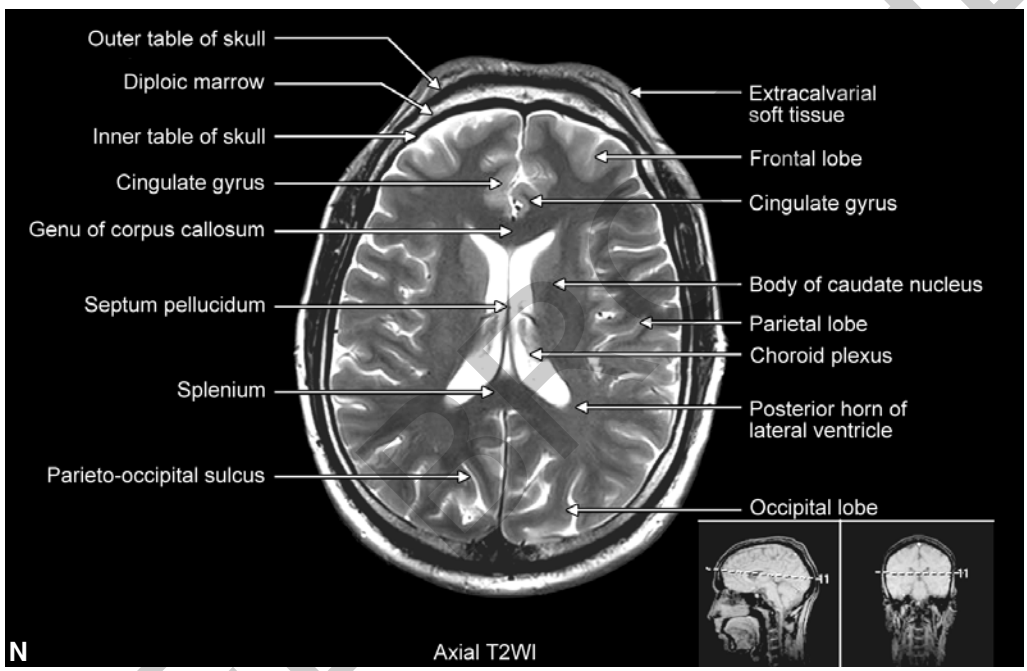

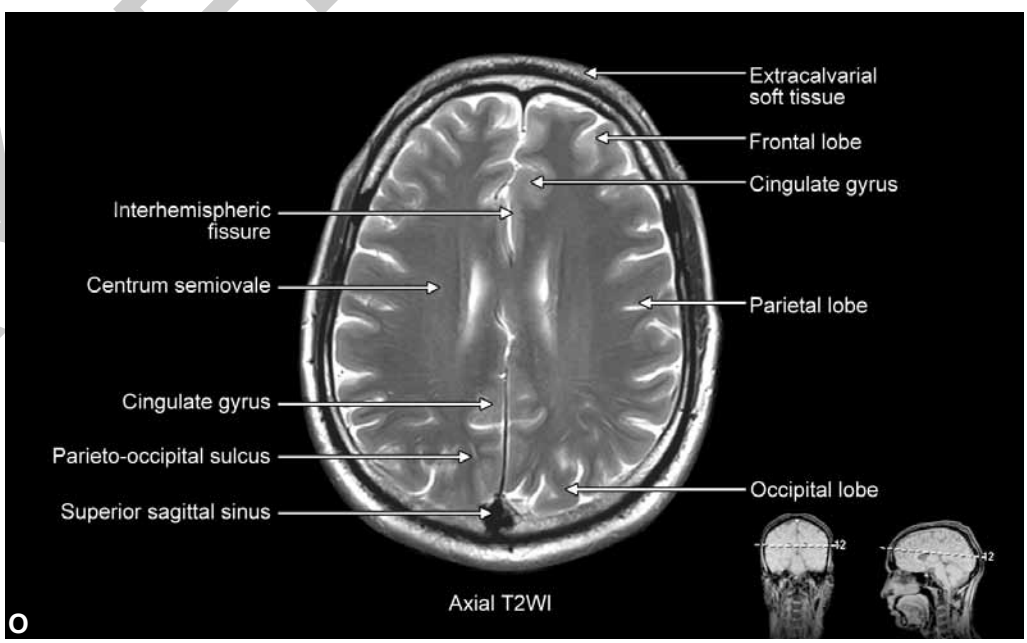

body relays the information to the auditory cortex located on the superior temporal gyrus. The lateral geniculate body is a part of the visual pathway; the superior brachium connects the lateral geniculate body to superior colliculus. The lateral geniculate body relays the information to the visual cortex located in occipital lobe.

- *Epithalamus* is formed by the habenula, pineal body and posterior commissure seen on T1W and T2W images in axial, coronal and sagittal sections. The pineal stalk has a superior and inferior lamina. The habenula forms the superior lamina. The posterior commissure forms the inferior lamina. The pineal recess is located between the superior and inferior lamina.

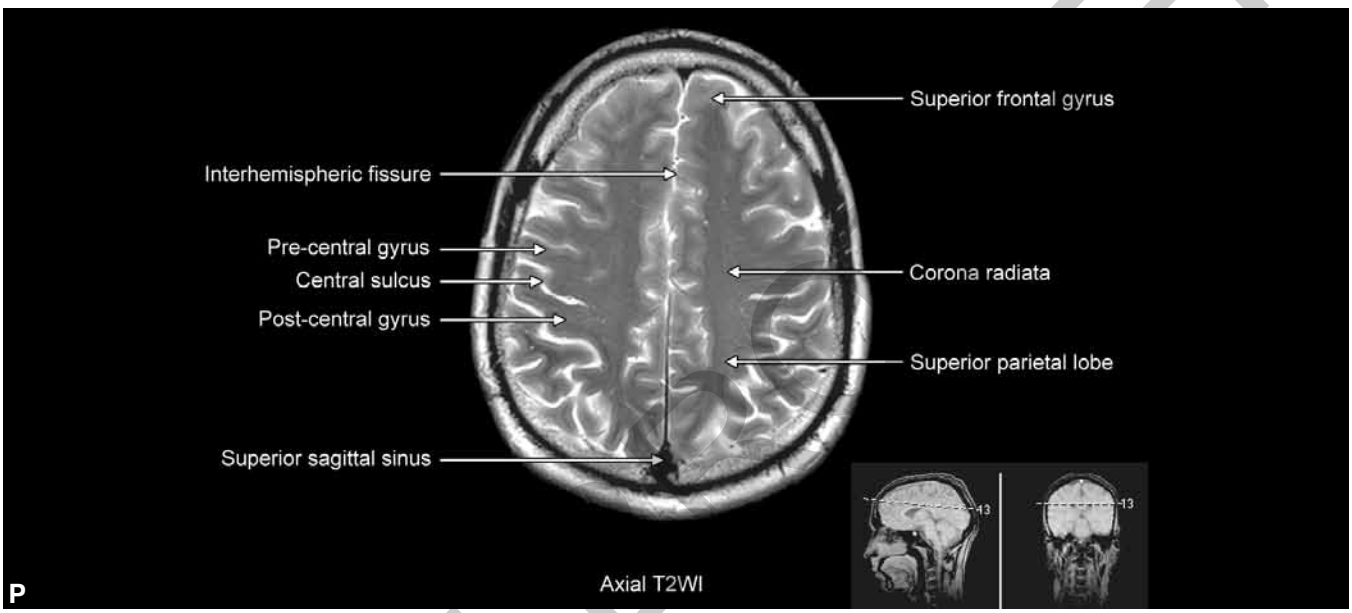

Figs 1A to P: MRI head axial section T2 weighted images

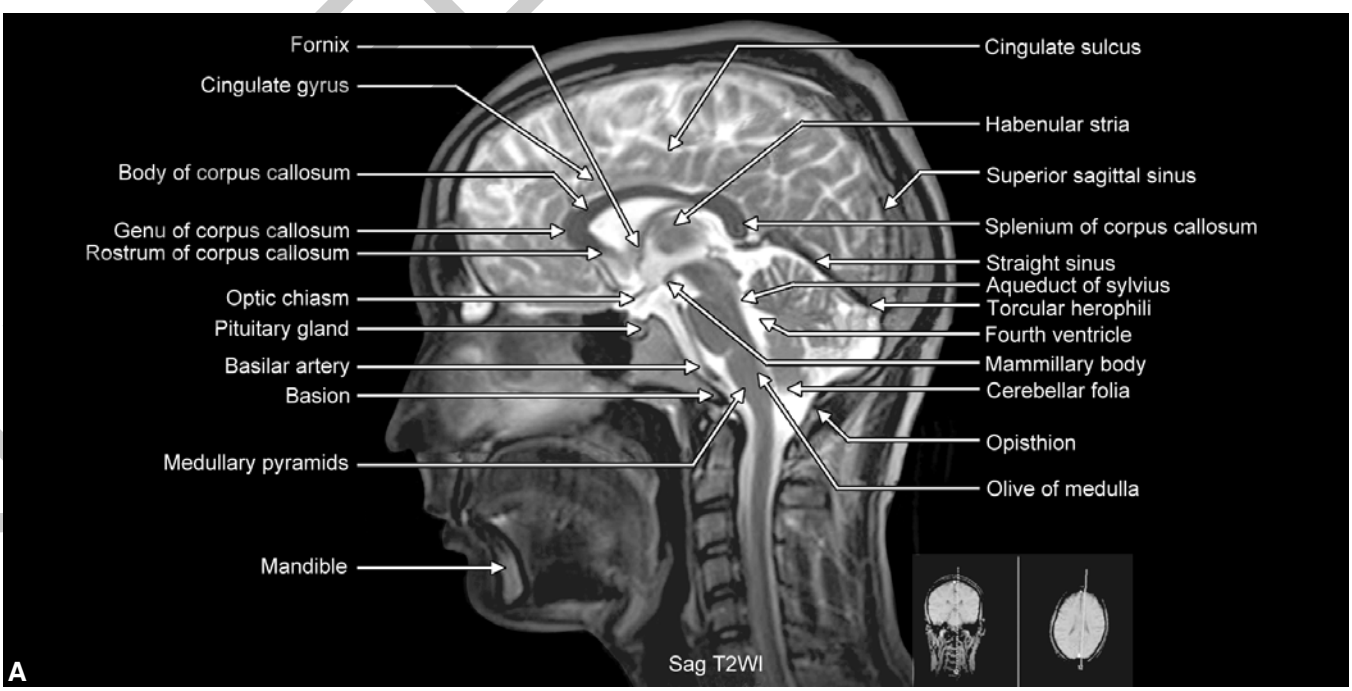

- *Hypothalamus* (Fig. 2D) is a triangular brain structure inferior to the anterior part of the thalamus is seen on sagittal and axial MRI sections. It consists of the mammillary bodies, tuber cinereum, infundibulum, hypophysis and optic chiasm. In a sagittal MRI section, the hypothalamus is separated from the thalamus by an oblique hypothalamic sulcus which extends from the aqueduct of Sylvius to the interventricular foramen of Monro. The anterior part of the hypothalamus is connected to the infundibular stalk of pituitary. The mammillary bodies form the most posterior part of the hypothalamus. The hypothalamic groove is seen on the lateral walls of the third ventricle and extends from the aqueduct of Sylvius to the interventricular foramen. The hypothalamus has important roles in autonomic functions (modulation of visceral activities like thermoregulation, appetite, thirst, sexual responses and emotions), endocrine

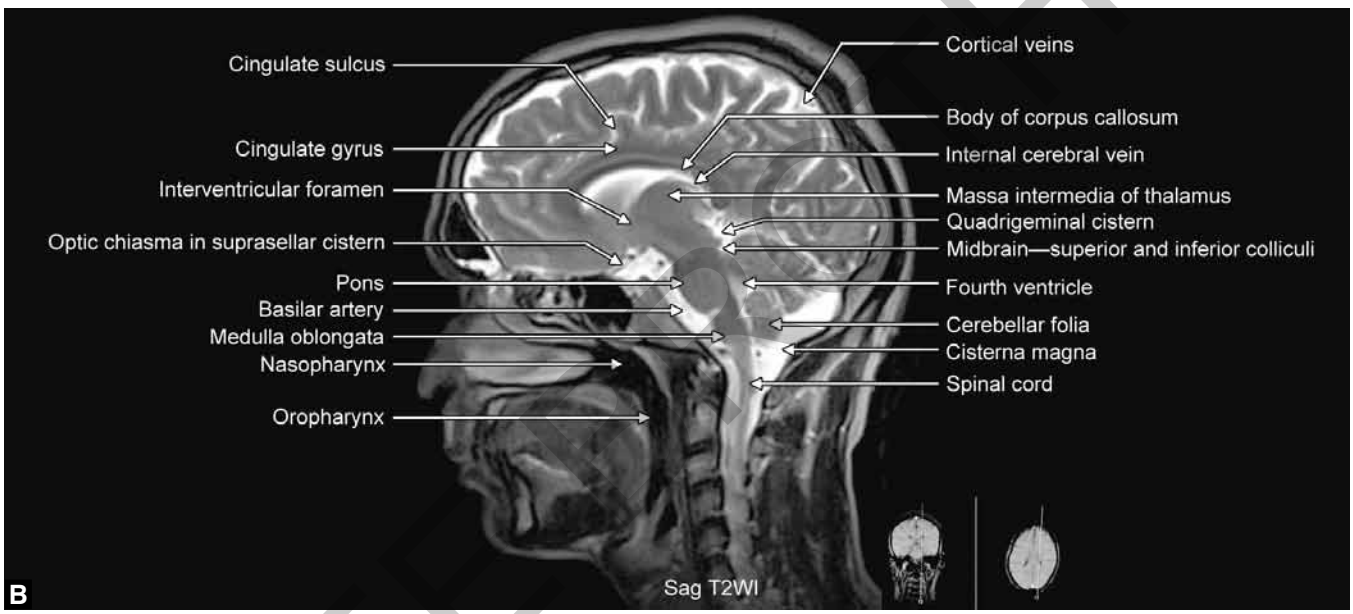

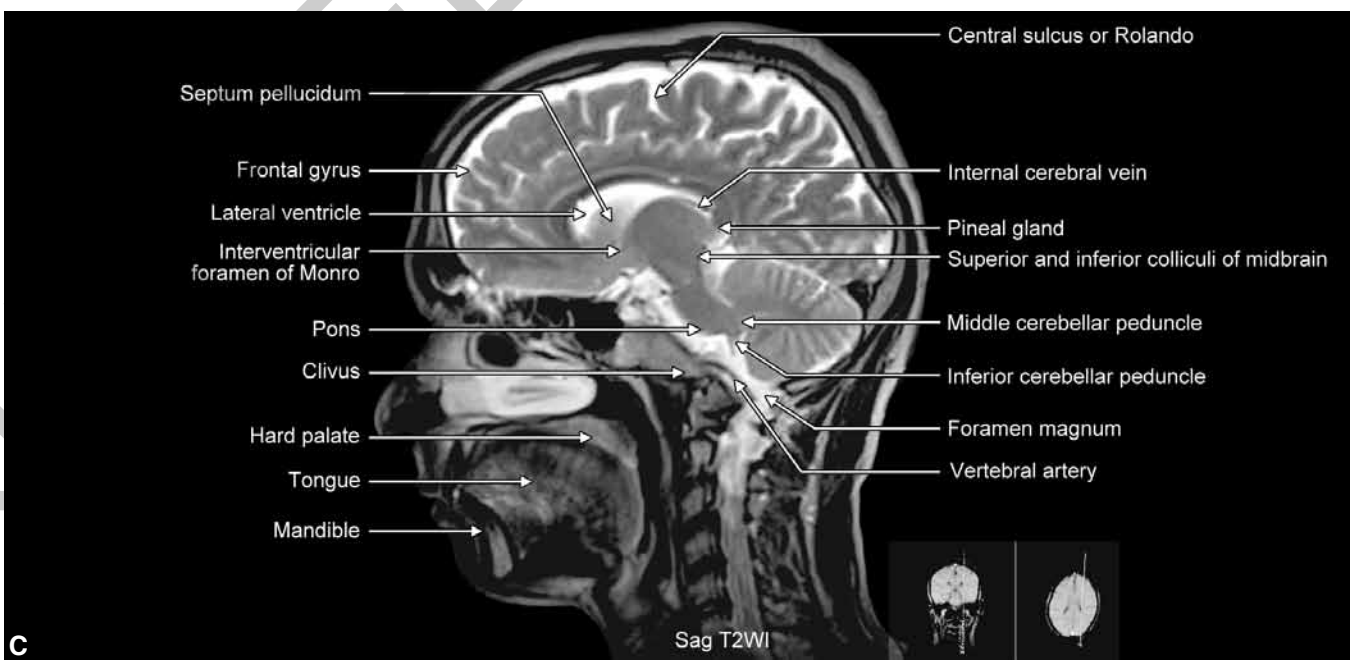

functions (regulates release of hormones from the pituitary gland) and pain response such as blunting of painful stimuli by releasing endorphins and encephalin.

- *Subthalamus* is seen on T1W and T2W images on sagittal and coronal sections as a thin zone of transition between the thalamus and tegmentum of the midbrain.

Limbic System

The limbic system is concerned with emotional and personality aspects of each individual. The limbic system is made up of various nuclei and interconnecting fibers. The olfactory nerves, olfactory bulb and tract, hippocampal gyrus, fornix, fimbriae, dentate gyrus, mammillary body, uncus, cingulate and parahippocampal gyri, amygdaloid body, septal

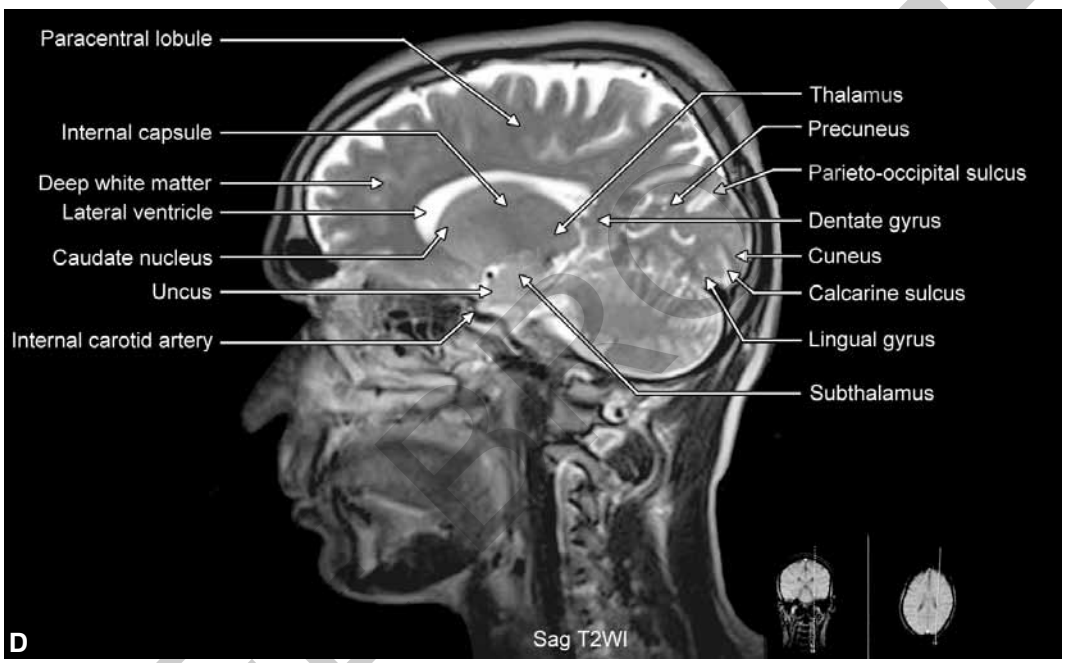

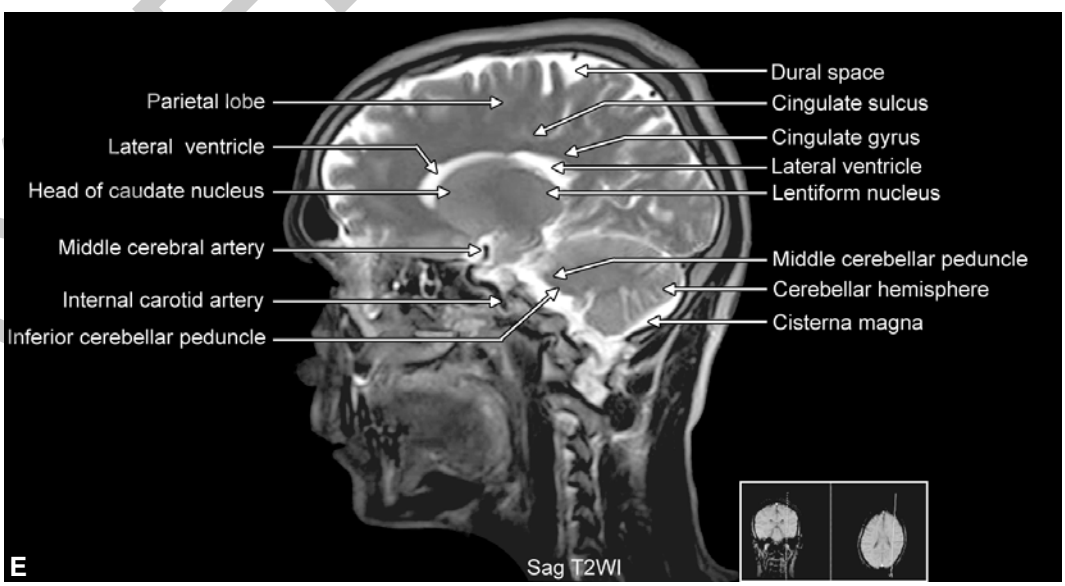

JAYPEE PROOFERS

for detailed information on radiology books, visit our website www.jaypeebrothers.com, for detailed information on radio

ATLAS OF MAGNETIC RESONANCE IMAGING

Atlas of Magnetic Resonance Imaging permits acquaintance to normal MR anatomy of structures and change in their morphology on pathology with clarity. The book aims at easy, ready and convenient peep in introducing the medical fraternity to the fascinating pathological changes on MR imaging. The book will prove to be a handy manual for a systematic entry into the beautiful world of MR imaging. This assemblage of images is meant to assist as a companion to MR imaging department for their routine day-to-day course of work.

Salient Features

- *Provides a large bank of MRI images and most imaging solutions routinely required at any imaging establishment and will be a handy reference.*
- *Helpful for residents, radiologists and practitioners to interpret images and conclude a possible diagnosis during their routine practice.*
- *Includes a chapter on Self-Assessment to make it more interesting to the reader.*
- *A complete inclusion of normal anatomy and a wide range of pathology.*

Hariqbal Singh is currently Head, Department of Radiology, Smt Kashibai Navale Medical College and General Hospital, Pune, Maharashtra, India. He has technical expertise as radiologist in managing equipment, personnel and resources. He is an effective administrator, communicator and team leader. He has a large number of publications in countrywide and global medical journals. He has authored few books in radiology. He has been a postgraduate teacher, examiner and guide since 1989 with University of Pune, Pune, Maharashtra, India; University of Health Sciences and Diplomate National Board.



Vikash Ojha is working as Consultant, Department of Radiology, Apollo Jehangir Hospital, Pune, Maharashtra, India. He is a keen radiologist and zealous observer.



Santosh Konde is working as Associate Professor, Department of Radiology, Smt Kashibai Navale Medical College and General Hospital, Pune, Maharashtra, India. He has several publications in medical journals to his credit.



Available at all medical book stores
or buy directly from Jaypee Brothers through online shopping
at www.jaypeebrothers.com

JAYPEE BROTHERS
Medical Publishers (P) Ltd.
www.jaypeebrothers.com

Shelving
Recommendation
RADIOLOGY

