thalmology books, visit our website www.jaypeebrothers.com, for detailed information on ophthalmology books

OPTICAL COHERENCE TOMOGRAPHY

in Current GLAUCOMA *Practice*

Pearls and Pitfalls

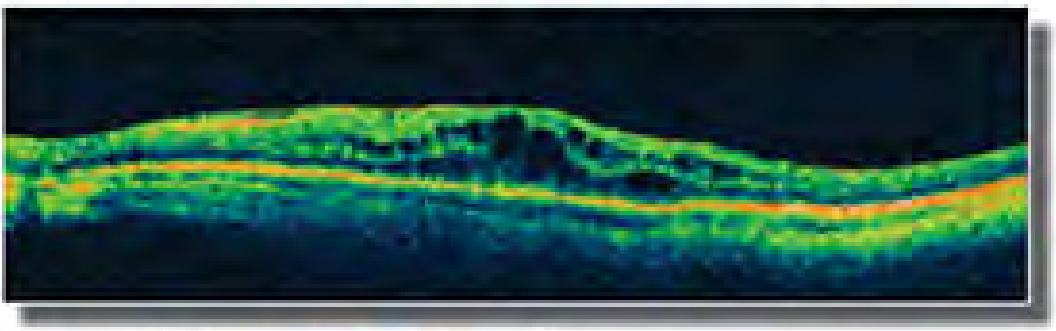





Digvijay Singh
Ajay Sharma
Dewang Angmo
Tanuj Dada

Contents

1. Introduction **1**

2. Principle of Optical Coherence Tomography **9**

3. Optical Coherence Tomography in Glaucoma **13**

Optic Nerve Head Analysis 13
Retinal Nerve Fiber Layer Analysis 14
Guided Progression Analysis 16
Ganglion Cell Analysis 17
Macular Analysis 17
Anterior Segment Evaluation 17
Anterior Segment *Visante* OCT 17
Lamina Cribrosa Imaging 20

4. Optic Nerve Head Analysis **24**

Technology 25
Method 25
Analysis 25

5. Retinal Nerve Fiber Analysis **33**

Method 34
Technology 34
Analysis 34
Interpretation 35

CASES
Case 1: Structure Correlates with Function 43
Case 2: Preperimetric and Perimetric Glaucoma 45
Case 3: Structural Change Correlates with Function (Ignore Artifacts) 47
Case 4: RNFL Thinning could be due to Nonglaucomatous Causes 49
Case 5: Understanding the TSNIT RNFL Profile 50
Case 6: Qualitative Analysis 52

6. Progression Analysis **55**

Technology 55
Method 57
Interpretation 58

CASES
Case 1: OCT versus Fundus Photography 61
Case 2: Pseudoprogression 68
Case 3: Variability on OCT 76
Case 4: True Progression: OCT Correlates with Visual Fields 80

7. Ganglion Cell Analysis 87

Technology 88
Method 88
Analysis 88

CASES
Case 1: Understanding the Ganglion Cell Analysis. Always Compare with RNFL Analysis 92
Case 2: Advanced Glaucoma 94
Case 3: Preperimetric and Perimetric Glaucoma 96

8. Macular OCT 100

Technology 100
Method 103
Analysis 103

9. Anterior Segment Analysis 106

Technology and Use 106

10. Limitations of OCT and Imaging Artifacts 113

Acquiring a Good Scan: Pearls 113
Pitfalls in OCT Imaging 115
High Myopia 118

Index 125

CHAPTER

3

Optical Coherence Tomography in Glaucoma

Optical coherence tomography has been used in various aspects of diagnosis and follow-up in glaucoma patients. The various facets of glaucoma evaluated by OCT include:[1,2]

- Optic nerve head analysis
- Retinal nerve fiber layer thickness measurement
- Guided progression analysis
- Ganglion cell layer thickness
- *Macular analysis:* Thickness and profile
- Anterior Segment examination
- *Anterior Segment-OCT:* Visante OCT
- Lamina cribrosa.

This book predominantly focuses on the posterior segment OCT and the modules available for commercial use. The chapters in this book discuss in detail each of the important aspects that may be studied using the posterior segment OCT (*Stratus* and *Cirrus* OCT).

OPTIC NERVE HEAD ANALYSIS

Changes in the optic nerve head is the mainstay for the clinical diagnosis of glaucoma. The prominent components of the optic nerve head analysis (Figure 3.1) which are seen clinically include the neuro-retinal rim profile and thickness and the amount of cupping. Even on the OCT, the primary parameters seen are the neuro-retinal rim area, cup area, integrated rim area and the cup volume among other parameters. It is important to understand that these parameters are entirely objective and are average values, not defined by quadrant or sector unlike a clinical examination. Qualitative assessment of rim notches or depth is not accurately possible. The optic nerve head along with advances in the form of three dimensional reconstruction and progression analysis forms an integral part of the role of OCT in glaucoma. More details on optic nerve head analysis are in chapter 4.

JAYPEE BROTHERS

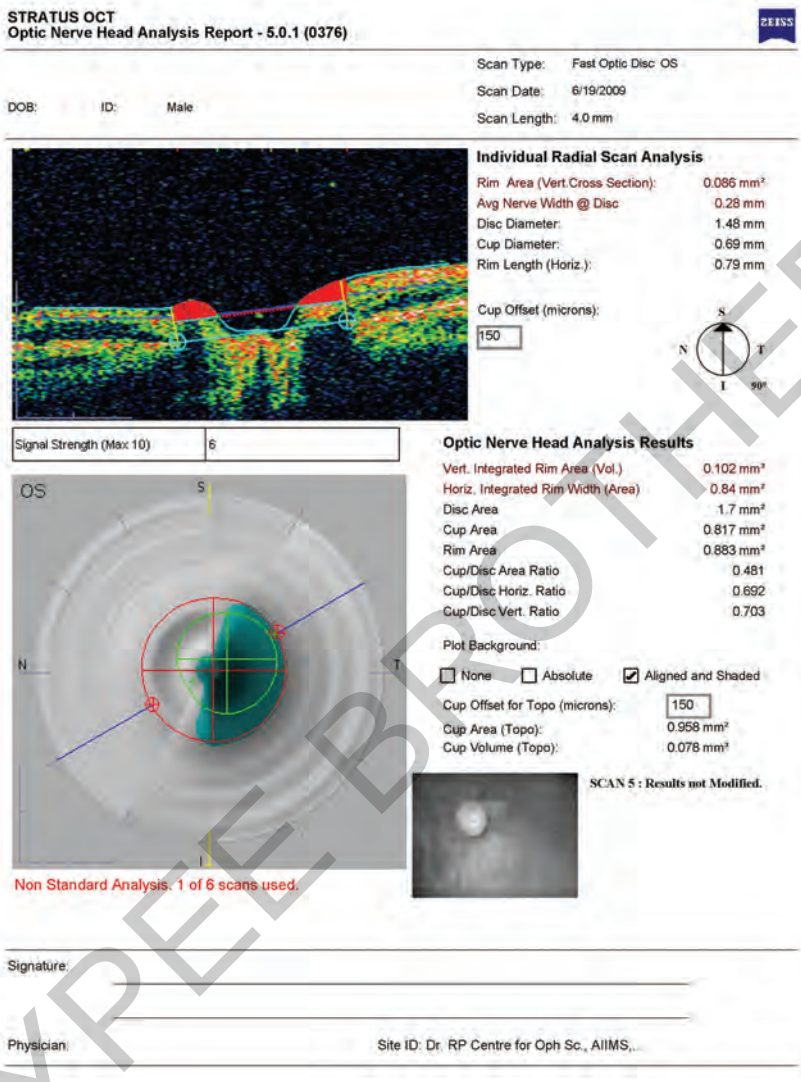

Fig. 3.1 Typical printout of an optic nerve head analysis

RETINAL NERVE FIBER LAYER ANALYSIS

Probably the most important role of the OCT in diagnosing and following up glaucoma has been its ability to qualify RNFL and progressively follow its changes. It has been seen that RNFL change has preceded field change and this enables early diagnosis. This parameter is accuartely measured and has been shown to be highly reproducible and reliable for follow-up. The importance of sector-wise and quadrant-wise analysis was understood when studies demonstrated certain sectors or clock hours to get affected preferentially in glaucoma, particularly

JAYPEE BROTHERS

in progressive disease. The important aspects of RNFL studied include RNFL thickness, its deviation from the normative database and its profile over the temporal, superior, nasal and inferior quadrants (TSNIT profile) (Figure 3.2). Infact, the OCT RNFL analysis has become such an important tool to enhance our diagnostic ability of glaucoma that over time, it given rise to the term red disease referring to glaucoma diagnosed on optical coherence tomography (OCT) but not on clinical or functional tests. A wide variety of studies has compared optical coherence tomography (OCT) to other imaging modalities.

Further details on RNFL analysis are given in chapter 5.

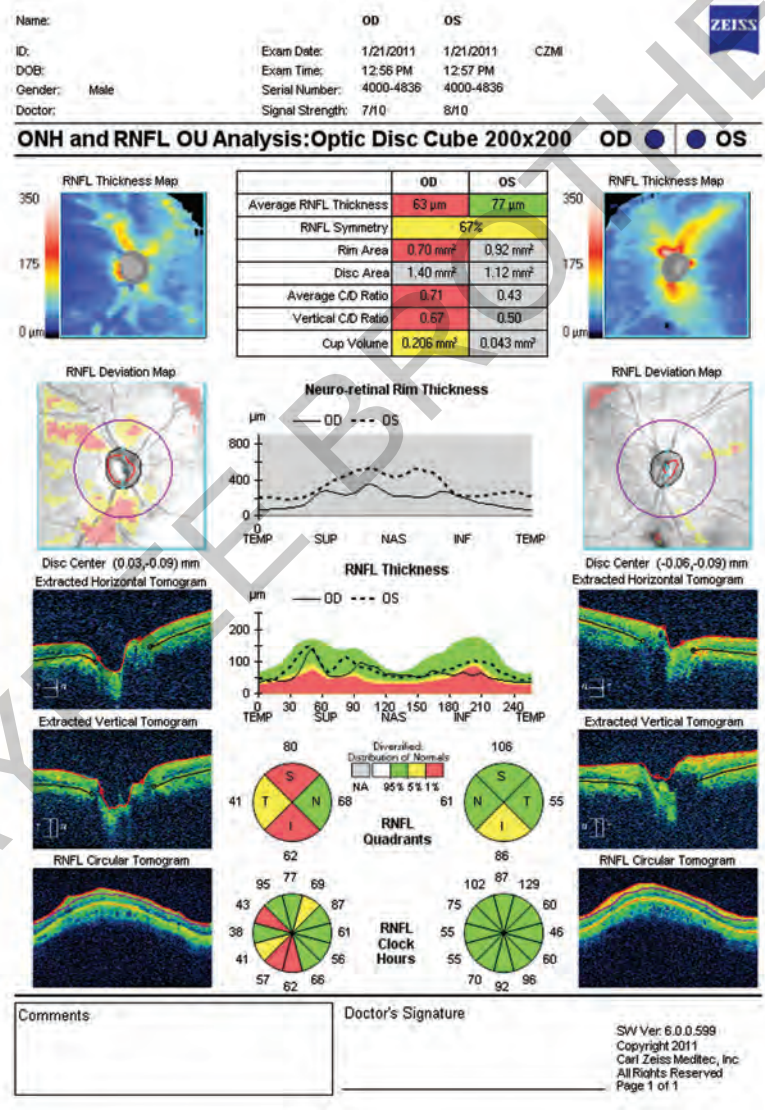

	OD	OS
Average RNFL Thickness	63 µm	77 µm
RNFL Symmetry	67%	
Rim Area	0.70 mm²	0.92 mm²
Disc Area	1.40 mm²	1.12 mm²
Average C/D Ratio	0.71	0.43
Vertical C/D Ratio	0.67	0.50
Cup Volume	0.206 mm³	0.043 mm³

Fig. 3.2 Typical printout of a RNFL analysis

JAYPEE BROTHERS

GUIDED PROGRESSION ANALYSIS

One of the main advantages the OCT has provided over progressive fundus images is the ability to measure and quantify change. This quantification has been useful as it has enabled a statistical test to determine whether progression has occurred and its significance. There are many cases, particularly in early glaucoma where progression is diagnosed only on structural change as these are preperimetric. Further, the ability to differentiate pathologic change from the normal physiologic change is not possible on serial fundus examinations. The GPA printout can be intimidating to read and understand and is often misinterpreted (Figure 3.3).

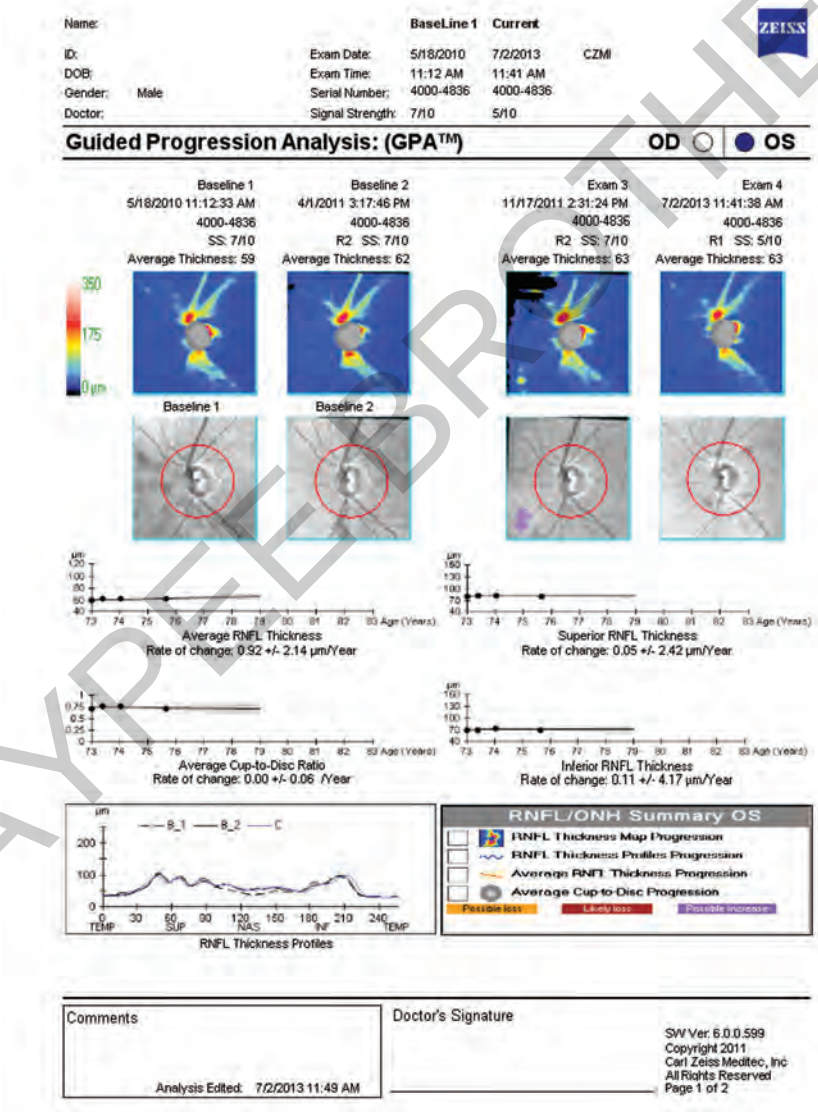

Fig. 3.3 Typical printout of guided progression analysis

JAYPEE BROTHERS

Therefore chapter 6 discusses the guided progression analysis module of the OCT and provides a step by step guide to interpreting a GPA printout.

GANGLION CELL ANALYSIS

The ganglion cell analysis is a relatively recent concept that helps in measuring in an indirect manner the quantity of ganglion cells in the retina. This concept behind this module is that optic neuropathies, including glaucoma are primarily affecting the axons of the ganglion cell, therefore a measure of these would be a direct indication of glaucomatous damage. This parameter has shown a sensitivity similar to RNFL changes for most cases, but has better sensitivity for structural changes resulting in paracentral visual field loss. The ganglion cell analysis is acquired from the macular cube scan through a special software module and currently lots of research is ongoing on this aspect (Figure 3.4). Ganglion cell analysis is discussed in detail in chapter 7.

MACULAR ANALYSIS

It might seem that the macula does not have much role in glaucoma evaluation and its management but studies have shown otherwise. The important parameters evaluated is the macular profile where hypotonic maculopathy or cystoid macular edema (post-glaucoma surgery or secondary to prostaglandins) may be diagnosed and macular thickness which has been shown to correlate with presence of glaucoma. Macular scanning may be done using either a macular cube or a 5-line raster method and both provide important information relevant to glaucoma (Figure 3.5). The macular OCT is discussed in detail in chapter 8.

ANTERIOR SEGMENT EVALUATION

Glaucoma assessment involves two components. The first are the changes in the posterior segment including optic nerve head changes, nerve fiber changes and macular evaluation. The second is the assessment of the anterior segemnt to a evaluate the angle and cornea. The latter can also be performed using the OCT whereby a non-invasive imaging of the angle and the cornea or sclera can be done (Figure 3.6). This is possible due to a special anterior segment module in the machine software. The images are excellent and are free from any manipulation as may happen in gonioscopy or ultrasound biomicroscopy. While this is not the mainstay for the OCT in glaucoma assessment, it is an added feature that can often be helpful for an accurate diagnosis. This module is discussed in greater detail in chapter 9.

ANTERIOR SEGMENT *VISANTE* OCT

The anterior segment OCT (ASOCT) is one of the latest arsenal in glaucoma imaging and has enabled high resolution images of the cornea, angle, part of the iris and ciliary body with the aid of a super luminescence diode having an infrared wavelength of 1310 nm.[3,4] The major advantages of the ASOCT over

JAYPEE BROTHERS

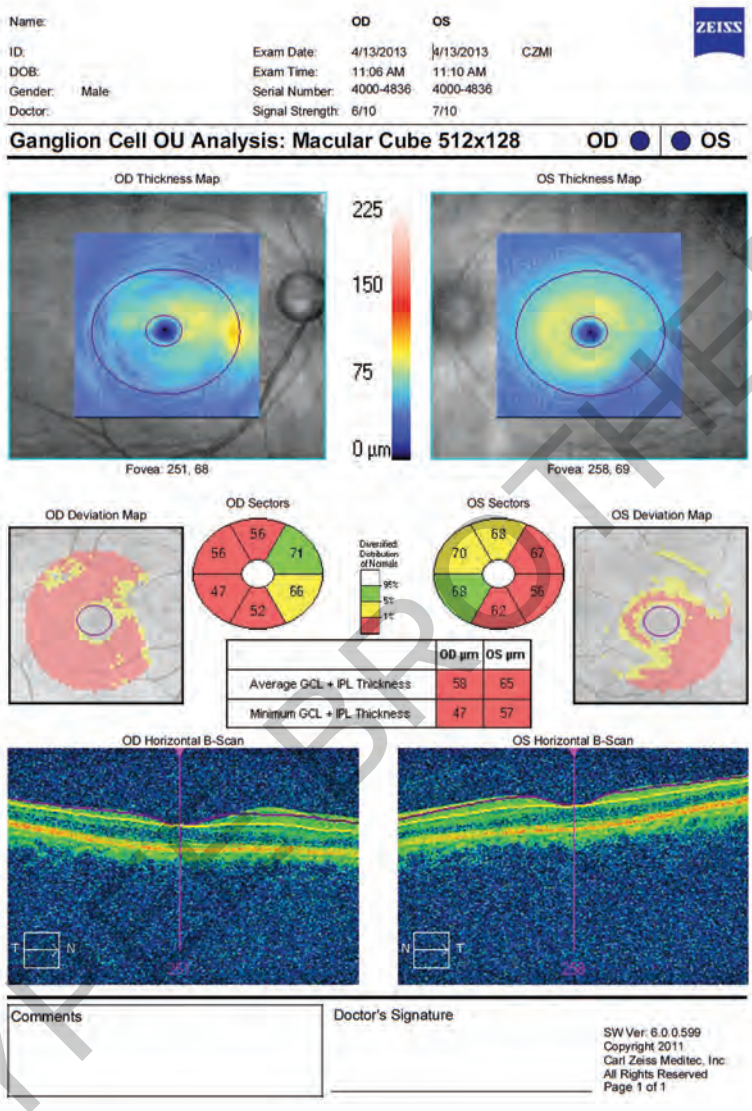

Fig. 3.4 Typical printout of a ganglion cell analysis

other forms of anterior segment imaging includes the ability to image a nascent angle unaffected by light (since it employs non-visible EM waves), the ability to image the anterior segment structures in sitting position, the ability of being more reproducible and above all being a non-invasive (hence enabling imaging in a postoperative patient). The drawbacks of the machine include the need for a reasonable clear medium for the IR rays to pass through for imaging and the need for the eye to be held still. Patients who can't be made to sit for an adequate period are also difficult to image.

JAYPEE BROTHERS

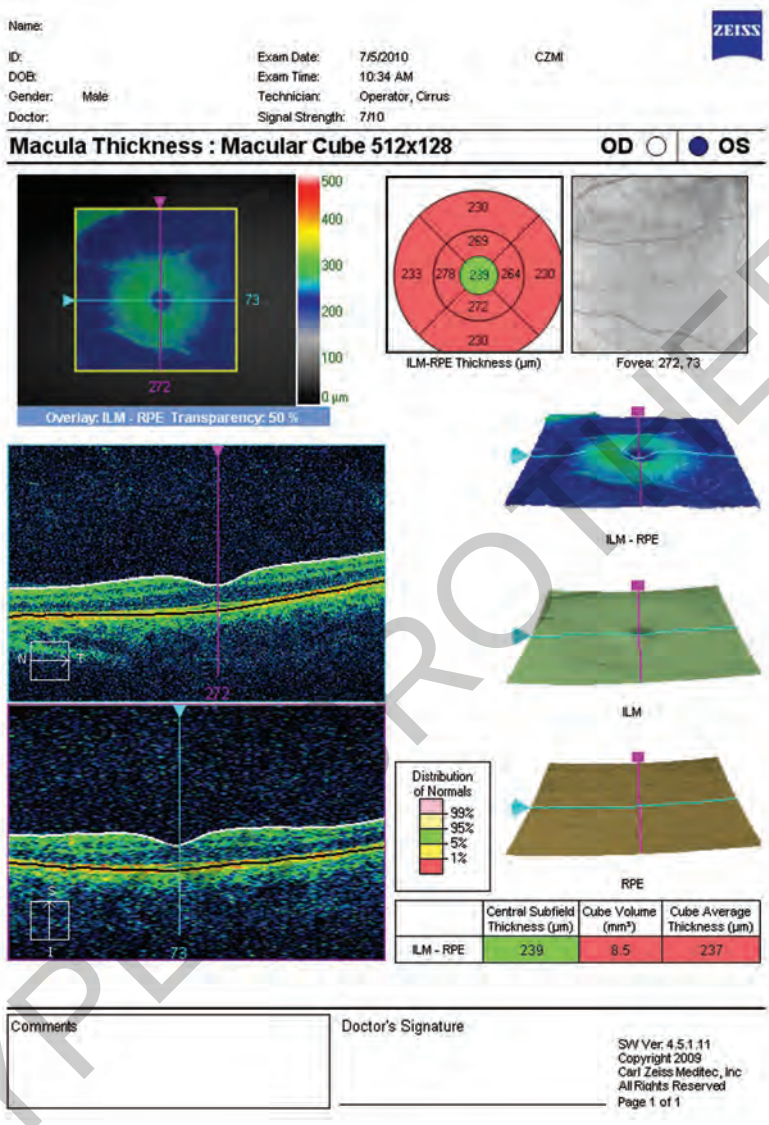

Fig. 3.5 Typical printout of a macular analysis

In glaucoma, the ASOCT can be used to determine angle closure including the degree of synechial closure versus appositional closure; it can determine the patency of the peripheral iridotomy and the affect it had on the angle; it can help diagnose tricky situations such as plateau iris or aqueous misdirection; it can help plan surgery in the preoperative period and in the postoperative period it can determine causes of failure or evidence of surgical success.[5] Detailed discussion and exemplification are beyond the scope of this book. Typical printout of a Visante OCT is shown in Figure 3.7.

JAYPEE BROTHERS

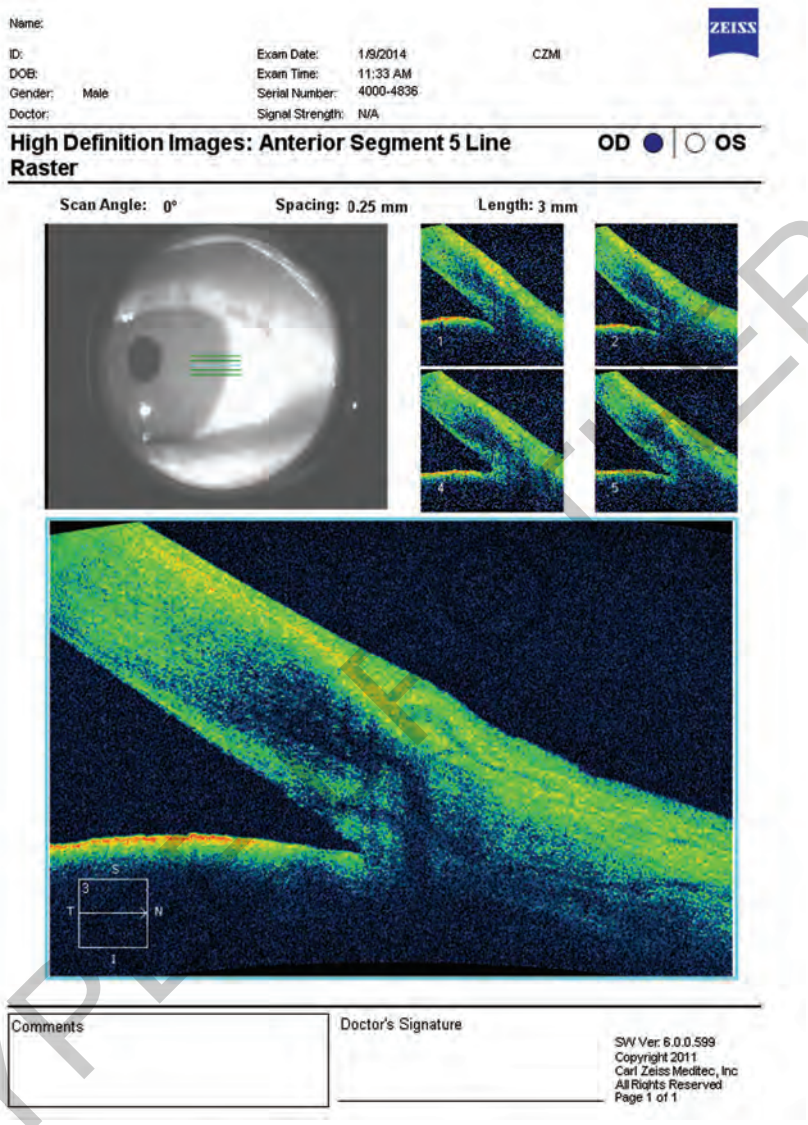

Fig. 3.6 Typical printout of an anterior segment analysis

LAMINA CRIBROSA IMAGING

The swept source OCT or OCT with in depth imaging or HR OCT have been used in the field of glaucoma research to view the lamina cribrosa for changes which may predispose an individual to glaucoma.[6,7] Viewing of the lamina cribrosa may aid in the early diagnosis of glaucoma or progression and this structure of the eye is now gaining importance as a site of pathophysiological changes in glaucoma.

JAYPEE BROTHERS

While not yet in commercial use, recent literature has shown micro-architecture changes in which reflect beams'remodeling and axonal loss leading to reduction in pore size and increased pore size variability of the lamina cribrosa of glaucoma patients as compared to healthy controls and this showed a correlation with worse visual fields.[8] Postoperatively after glaucoma surgery, lamina cribrosa depth has shown to decrease and the prelaminar neural tissue has shown to get thickened in correlation to the decrease in intraocular pressure.[9] Other studies have found disc hemorrhage, a diagnosis of normal tension

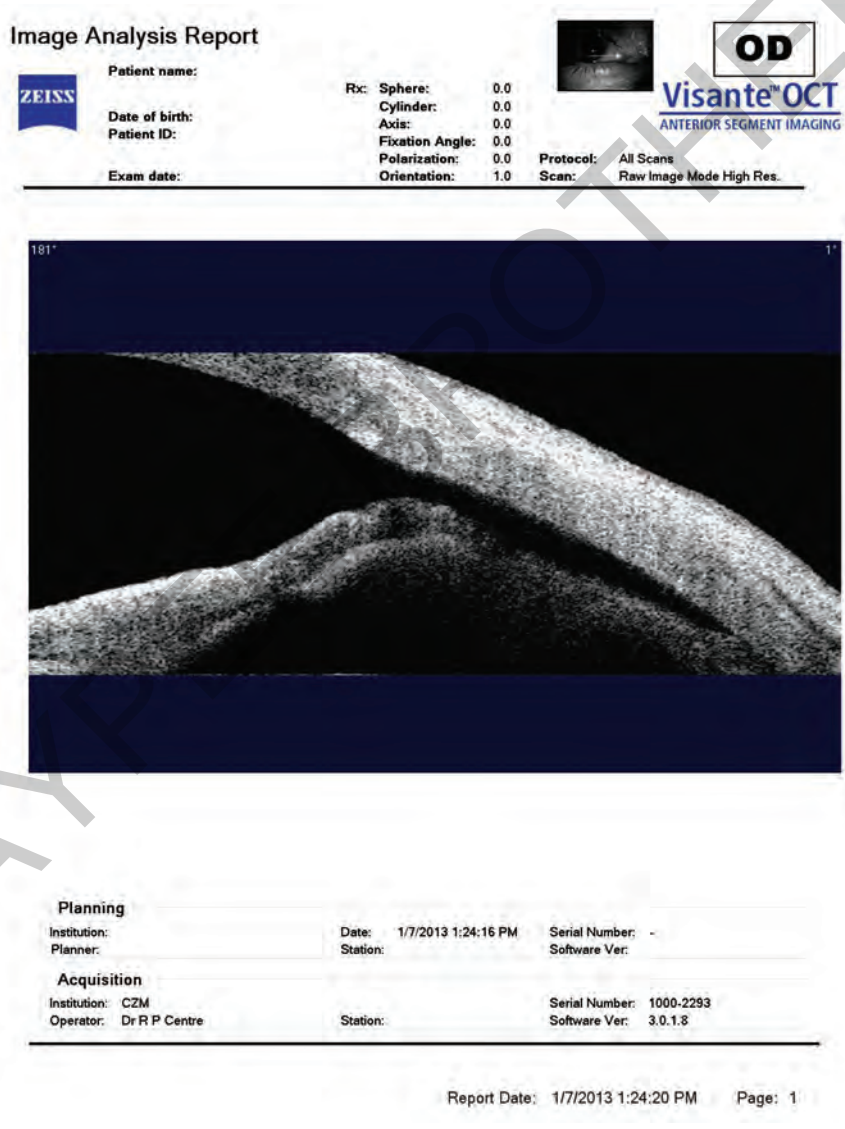

Fig. 3.7A

JAYPEE BROTHERS

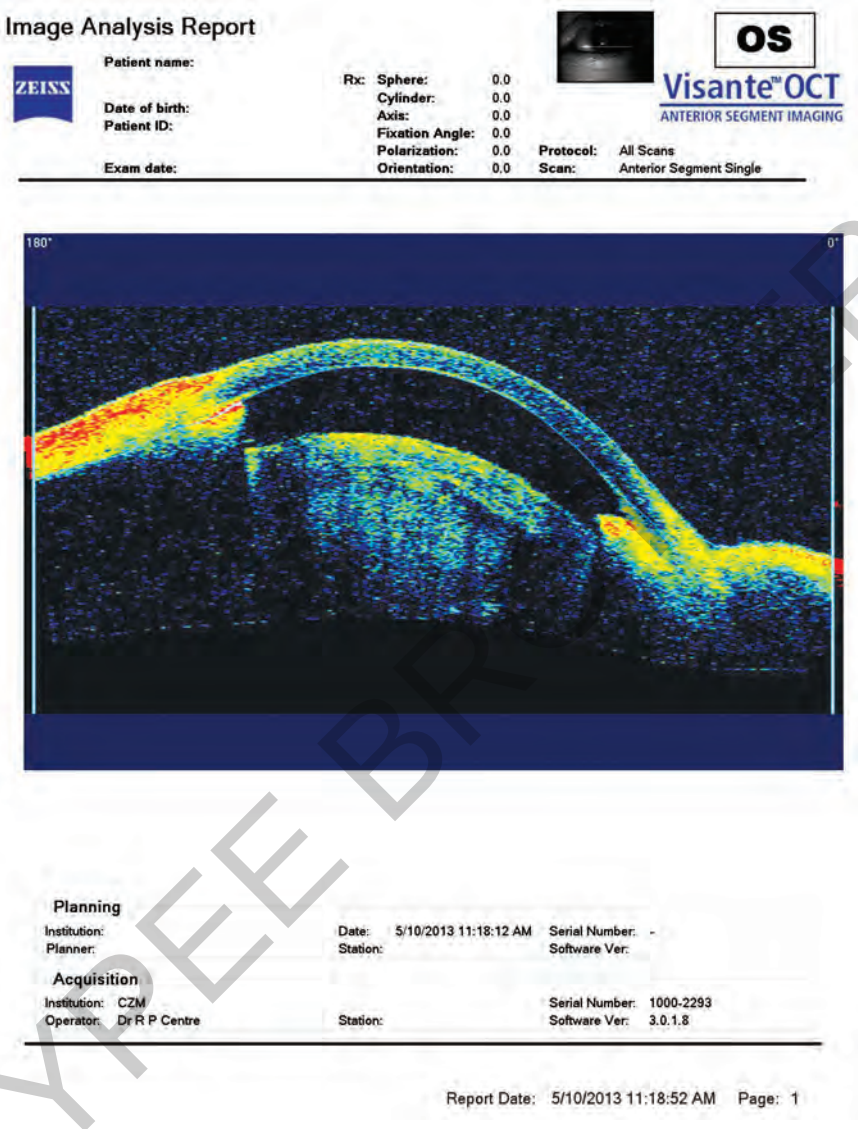

Fig. 3.7B

Figs 3.7A and B Typical printout of a Visante OCT anterior segment analysis. (A) Shows high resolution imaging of the anterior chamber angle using the Visante OCT. Note the high resolution and details; (B) Shows a lower resolution imaging of the cornea, anterior chamber and anterior surface of lens

glaucoma, RNFL defects and more advanced glaucoma status to be associated with focal lamina cribrosa defects.[10,11] A detailed discussion on this new facet of imaging is beyond the scope of this book.

The OCT has been an important tool to enhance our diagnostic ability of glaucoma and over the time, OCT and other imaging modalities has given rise to

JAYPEE BROTHERS

the term red disease referring to glaucoma diagnosed on OCT but not on clinical or functional tests.[12]

Key Points

- Structural progression is the gold standard for glaucoma diagnosis and progression
- OCT is best method for RNFL analysis
- Optic nerve head analysis, RNFL analysis and Ganglion cell analysis are the main stay for use of OCT in glaucoma
- Macular scan and anterior segment scans provide additional information in glaucoma cases.

REFERENCES

1. Bussel II, Wollstein G, Schuman JS. OCT for glaucoma diagnosis, screening and detection of glaucoma progression. Br J Ophthalmol. 2013.
2. Geimer SA. Glaucoma diagnostics. Acta Ophthalmol. 2013.
3. Sharma R, Sharma A, Arora T, Sharma S, Sobti A, Jha B, Chaturvedi N, Dada T. Application of anterior segment optical coherence tomography in glaucoma. Surv Ophthalmol. 2013.
4. Pekmezci M, Porco TC, Lin SC.Anterior segment optical coherence tomography as a screening tool for the assessment of the anterior segment angle. Ophthalmic Surg Lasers Imaging. 2009;40(4):389-98.
5. How AC, Baskaran M, Kumar RS, He M, Foster PJ, Lavanya R, Wong HT, Chew PT, Friedman DS, Aung T. Changes in anterior segment morphology after laser peripheral iridotomy: an anterior segment optical coherence tomography study. Ophthalmology. 2012;119(7):1383-7.
6. Miki A, Ikuno Y, Jo Y, Nishida K. Comparison of enhanced depth imaging and high-penetration optical coherence tomography for imaging deep optic nerve head and parapapillary structures. Clin Ophthalmol. 2013;7:1995-2001.
7. Lopilly Park HY, Shin HY, Park CK. Imaging the Posterior Segment of the Eye using Swept-Source Optical Coherence Tomography in Myopic Glaucoma Eyes: Comparison With Enhanced-Depth Imaging. Am J Ophthalmol. 2013.
8. Wang B, Nevins JE, Nadler Z, Wollstein G, Ishikawa H, Bilonick RA, Kagemann L, Sigal IA, Grulkowski I, Liu JJ, Kraus M, Lu CD, Hornegger J, Fujimoto JG,Schuman JS. *In vivo* lamina cribrosa micro-architecture in healthy and glaucomatous eyes as assessed by optical coherence tomography. Invest Ophthalmol Vis Sci. 2013;54(13):8270-4.
9. Yoshikawa M, Akagi T, Hangai M, Ikeda HO, Takayama K, Morooka S, Kimura Y, Nakano N, Yoshimura N. Alterations in the Neural and Connective Tissue Components of Glaucomatous Cupping after Glaucoma Surgery using Swept Source Optical Coherence Tomography. Invest Ophthalmol Vis Sci. 2014.
10. Park SC, Hsu AT, Su D, Simonson JL, Al-Jumayli M, Liu Y, Liebmann JM, Ritch R. Factors associated with focal lamina cribrosa defects in glaucoma. Invest Ophthalmol Vis Sci. 2013;54(13):8401-7.
11. Tatham AJ, Miki A, Weinreb RN, Zangwill LM, Medeiros FA. Defects of the lamina cribrosa in eyes with localized retinal nerve fiber layer loss. Ophthalmology. 2014;121(1):110-8.
12. Kiddee W, Tantisarasart T, Wangsupadilok B. Performance of optical coherence tomography for distinguishing between normal eyes, glaucoma suspect and glaucomatous eyes. J Med Assoc Thai. 2013;96(6):689-95.

JAYPEE BROTHERS

Optical Coherence Tomography *in* Current Glaucoma Practice

Pearls and Pitfalls

A Practical Manual with Case Studies

Includes:

- Principle and indications for optical coherence tomography (OCT) imaging
- Pearls for acquiring a high-quality scan
- Interpretation of OCT images
- Evaluation of Retinal Nerve Fiber Layer (RNFL)
- Ganglion cell complex and macular imaging
- Optic nerve head analysis
- How to use OCT to diagnose glaucoma?
- Evaluation of disease progression
- Anterior segment imaging
- Review of relevant published literature
- Limitations of using OCT for glaucoma diagnosis

Available at all medical book stores
or buy directly from Jaypee Brothers through online shopping
at www.jaypeebrothers.com

JAYPEE BROTHERS
Medical Publishers (P) Ltd.
www.jaypeebrothers.com