Volume 1

Volume 2

Ramamurthi & Tandon's

MANUAL OF NEUROSURGERY



PRAKASH NARAIN TANDON
RAVI RAMAMURTHI
PRADEEP KUMAR JAIN N

CONTENTS

Volume 1

SECTION I: DIAGNOSTICS

1. **Electrodiagnosis** 1
   Manjari Tripathi, Priya Gupta, Sarat Chandra P
2. **Intracranial Pressure** 13
   Ravi Ramamurthi, Nigel Peter Symss
3. **Neuro-ophthalmology** 19
   Tandon R, Saxena R, Phuljhele S
4. **Neuro-otology** 27
   Sathiya Murali, Srividya, Mohan Kameswaran, Kiran Natarajan
5. **Neuroendocrinology** 38
   Ravi Ramamurthi, Ravindranath Kapu
6. **Intra-operative Monitoring** 45
   Babu KS, Rajasekar V
7. **Conventional Radiology** 53
   Ravi Ramamurthi, Goutham Cugati
8. **Basic Principles of CT Scan and MRI Scan** 60
   Veena Norhona
9. **Radiology: Intracranial Tumours** 70
   Kesavdas
10. **Radiology: Intracranial Infections** 84
    Bejoy Thomas

SECTION II: CONGENITAL

11. **Embryology: Skull and Vertebral Column** 95
    Muthukumar N
12. **Embryology: Brain and Spinal Cord** 101
    Muthukumar N
13. **Congenital Malformations of Cerebrum** 110
    Venkatramana NK, Ravi Shankar S
14. **Encephalocoeles** 119
    Ashok Kumar Mahapatra
15. **Intracranial Arachnoid Cysts** 127
    Chidambaram Balasubramaniam, Vani Santosh
16. **Craniofacial Deformities (Craniostenosis)** 137
    Uday Andar, Nitin Mokal
17. **Spinal Dysraphic States** 142
    Venkatramana NK
18. **Hydrocephalus** 152
    Venkatramana NK

19. **Endoscopic Management of Hydrocephalus** 161
Aaron Mohanty

20. **Normal Pressure Hydrocephalus** 167
Sanjay Behari, Das NK, Vimal Kumar V

21. **Bony Anomalies of the Craniovertebral Junction** 178
Sanjay Behari, Rabi N Sahu, Vijendra Kumar Jain

22. **Syringomyelia** 182
Suresh Nair, Girish Menon, BRM Rao

SECTION III: HEAD INJURIES

23. **Biomechanics of Head Injury** 192
Deepak Agrawal, Ashok Kumar Mahapatra

24. **Pathology** 196
Sankar SK, Anita Mahadevan

25. **Concussion Brain** 215
Sandeep Vaishya, Khan Z

26. **Cerebral Contusions** 219
Ravi Ramamurthi, Nigel Peter Symss

27. **Diffuse Axonal Injury** 224
Rajkumar, Vivek Kumar Vaid, Ashok Kumar Mahapatra

28. **Fat Embolism** 229
Krishna Reddy A

29. **Paediatric Head Injuries** 233
Chidambaram Balasubramaniam, Ramachandran B

30. **Clinical Assessment of a Head Injured Patient** 244
Rajkumar, Samir Kumar Kalra, Ashok Kumar Mahapatra

31. **Fluid and Electrolyte Balance in Head Injury** 250
Sharma RR

32. **Scalp Injuries** 263
Krishna Reddy A

33. **Acute Subdural Haematomas** 270
Sanjay Behari, Anuj Chaitley, Manish Singh Sharma, Ashok Kumar Mahapatra

34. **Extradural Haematomas** 274
Ashok Kumar Mahapatra, Vivek Kumar Vaid, Rajkumar

35. **Traumatic Intracerebral Haematomas** 278
Ravi Ramamurthi, Nigel Peter Symss

36. **Traumatic Brainstem Haemorrhage** 285
Ashok Kumar Mahapatra, Deepak Agrawal

37. **Complications and Sequelae of Head Injuries** 288
Khosla VK, Gupta SK, Mukherjee KK, Chhabra R

38. **Cranioplasty** 297
Ramesh Kumar Sharma, Mathuriya SN

39. **Maxillofacial Injuries** 303
Arun Kumar Singh, DN Upadhyay

40. **Traumatic Cerebrospinal Fluid Fistulae** 309
Ravi Ramamurthi, Amit Kapoor

41. Missile Injuries of the Brain 315
Harjinder S Bhatoe

42. Endocrine Abnormalities Following Traumatic Brain Injuries 321
Deepak Kumar Gupta, Ashok Kumar Mahapatra

43. Optic Nerve Injury 325
Ashok Kumar Mahapatra, Deepak Kumar Gupta

SECTION IV: SPINAL INJURIES

44. Assessment and Emergency Management of Acute Spinal Injuries 332
Anil Pande, Pradeep Kumar Jain N

45. Biomechanics of the Spine 349
Anil Pande, Goutham Cugati

46. Injuries of the Craniovertebral Junction and Upper Cervical Spine 359
Sarat Chandra P, Vamsi Yerramani

47. Injuries of Subaxial Cervical Spine 371
Anil Pande, Ravindranath Kapu

48. Whiplash Injury 380
Harjinder S Bhatoe

49. Thoracic and Thoracolumbar Injuries 383
Ramakrishna Easwaran

50. Lumbar and Lumbosacral Injuries 393
Ramakrishna Easwaran

51. Penetrating Injuries of the Spine 397
Harjinder S Bhatoe

SECTION V: PERIPHERAL NERVE

52. Anatomy and Physiology of the Peripheral Nerve 402
Sharma M, Gupta A, Mehta VS

53. General Principles of Management of Peripheral Nerve Injuries 409
David A Omahen, Hazem Eltahawy, Abhit Guha

54. Surgical Anatomy and Management of Brachial Plexus Injuries 416
Venkataswami R, Purushothaman V

55. Management of Injuries to Specific Peripheral Nerve 422
Gupta A, Ahmad FU, Mehta VS

56. Entrapment Syndromes 425
Gupta A, Ahmad FU, Mehta VS

SECTION VI: INFECTIONS

57. Brain Abscess 437
Dharkar SR, Sardana VR, Purohit D

58. **Scalp and Skull Infections** 446
Ravi Ramamurthi, Goutham Cugati

59. **Subdural Empyema** 450
Mathuriya SN, Pathak A, Khandelwal N

60. **Spinal Epidural and Intramedullary Abscess** 453
Ashish Suri, Shashwat Mishra, Ajay Garg

61. **Tuberculosis of the Central Nervous System** 459
PN Tandon, Anil Pande

62. **Tuberculous Meningitis** 466
PN Tandon, Anil Pande

63. **Tuberculosis of the Spine** 475
Sridhar K

64. **Surgery for Leprosy** 484
Sridhar K

65. **Cysticercosis** 489
BS Sharma, Sarat Chandra P

66. **Hydatid Disease** 499
Dharkar SR, Vikram M

67. **Other Parasitic Infestations of the Brain** 503
Sridhar K, Vikram M

68. **Spinal Hydatidosis** 505
Harjinder S Bhatoe

69. **Fungal Infections** 511
Anil Pande

70. **Viral Infections** 522
Ravi Ramamurthi, Ramamurthi B, Ravindranath Kapu

71. **Acquired Immunodeficiency Syndrome and the Neurosurgeon** 529
Sarat Chandra P, Vivek Tandon

SECTION VII: VASCULAR DISORDERS

72. **Subarachnoid Haemorrhage** 538
Chandramouli BA, Arivazhagan A

73. **General Principles of Management of Intracranial Aneurysms** 547
Tewari Manoj Kumar, Mathuriya SN, Khandelwal N

74. **Vasospasm and its Management** 559
Anil Pande, Ravi Ramamurthi

75. **Cerebral Protection** 573
Ravikant Palur, Ganesh K Murthy

76. **Paraclinoid Aneurysms** 586
Vijendra Kumar Jain, Sanjay Behari, Bernard Lyngdoh

77. **Internal Carotid Bifurcation Aneurysms** 591
Mathuriya SN, Tewari Manoj Kumar, Mukharjee KK, Paramjeet Singh

78 **Anterior Communicating Artery Aneurysms** 596
Mathuriya SN

79. **Distal Anterior Cerebral Artery Aneurysm** 606
Ravi Ramamurthi, Shivaram Bojja

80. Middle Cerebral Artery Aneurysms 608
Mathuriya SN, Pathak A, Gupta Vivek, Grover VK

81. Posterior Circulation Aneurysms 613
Ashish Suri, Sachin A Borkar, Nalin K Mishra

82. Giant Aneurysms 621
Sanjay Behari, Rabi Narayan Sahu, Rupant K Das, Vijendra Kumar Jain

83. Incidental Intracranial Aneurysms 629
Suresh Nair, A Mathew, G Menon

84. Multiple Intracranial Aneurysms 634
Mahmoud Rashidi, Anthony Sin, Anil Nanda

85. Intracranial Aneurysms of Infective Origin 638
Sanjay Behari, Vivek Vaid, Awadhesh K Jaiswal, Vijendra Kumar Jain

86. Intracavernous Aneurysms 642
BS Sharma, VS Mehta

87. Contemporary Endovascular Treatment of Intracranial Aneurysms 647
Uday Limaye, Anand S

88. Vascular Malformations of the Brain 652
Ravi Ramamurthi, Amit Kapoor

89. Surgical Management of Cerebral AVMs 661
Ravi Ramamurthi, Ravindranath Kapu

90. Embolisation of Intracranial Vascular Malformation 667
Anil Karapurkar, Nishant Aditya

91. Stereotactic Radiosurgery for Cerebral AVMs 672
Ganapathy K

92. Vein of Galen Malformations 677
Anil Nanda

93. Cavernomas of the Brain 682
CE Deopujari

94. Other Vascular Malformations of the Brain 688
Ravi Ramamurthi, Harinivas

95. Carotid Cavernous Fistula 693
Ravi Ramamurthi, Goutham Cugati

96. Dural Arteriovenous Malformations 700
Ravi Ramamurthi, Nigel Peter Symss

97. Embolisation of Spinal Vascular Malformations 705
Anil Karapurkar, Nishant Aditya

98. Spontaneous Intracerebral Haemorrhage 711
Ajaya Nand Jha, Vipul Gupta

99. Surgery for Stroke 718
Vincent Thamburaj A

SECTION VIII: TUMOURS OF THE SPINE AND SPINAL CORD

100. Clinical Features and Diagnosis 735
Ravi Ramamurthi, Santhosh Mohan Rao K

101. Vertebral Tumours 747
Deepu Banerji, Pallav Garg, Manoj Jain, Sanjay Behari

102. Spinal Schwannomas and Meningiomas 761
Trimurti D Nadkarni

103. Intramedullary Tumours 766
Bhawani S Sharma, Manish S Sharma

104. Congenital Tumours of the Spine 775
CE Deopujari, AB Kakani

105. Paediatric Spinal Tumours 782
Venkatramana NK

SECTION IX: DISC DISEASE AND OTHER SPINAL PATHOLOGIES

106. Pathophysiology of Disc Degeneration 790
Ramakrishna Easwaran

107. Cervical Disc Disease and Spondylosis: Clinical Features and Diagnosis 797
CE Deopujari, Rajiv Kumar

108. Cervical Disc Disease and Spondylosis Management 801
CE Deopujari, Rajiv Kumar, Rajan Shah

109. Cervical Ossification of Posterior Longitudinal Ligament 807
Anil Pande, M Vikram, Ravi Ramamurthi

110. Thoracic Disc Prolapse 817
Ravi Ramamurthi, Nigel Peter Symss

111. Lumbar Disc Disease 821
Manas Kumar Panigrahi, Rajesh Reddy S

112. Lumbar Canal Stenosis 831
Manas Kumar Panigrahi, Debabrat Biswal

113. Spondylolisthesis 839
Ramakrishna Easwaran

114. Fluorosis 847
Raja Reddy D, Srikanth R Deme

115. Osteoporosis 855
Ramakrishna Easwaran, S Sundarrajan

Volume 2

SECTION X: PATHOLOGY OF INTRACRANIAL TUMOURS

116. Classification of Tumours of the Nervous System 865
Vani Santhosh

117. Pathogenesis: Tumours of the Nervous System 872
Radhakrishnan VV

118. Germ Cell Tumours of the Central Nervous System 880
Vani Santhosh

119. Embryonal Tumours of the Central Nervous System 883
Chitra Sarkar, MC Sharma

120. Tumours of Meninges 892
Sundaram C, Shantveer G Uppin

121. Pituitary Tumours, Sellar and Suprasellar Lesions 904
Geeta Chacko

122. Lymphomas and Metastatic Tumours of Nervous System 918
Sundaram C, T Roshni Paul

123. Cerebral Oedema in Relation to Neoplasias of Nervous System 927
Shankar SK

124. Tumour Markers in Tumours of Nervous System 939
Chitra Sarkar, Vaishali Suri, MC Sharma

125. Tumours of Cranial and Peripheral Nerves 944
Sundaram C, Anita Mahadevan

126. Tumours of the Choroid Plexus 952
Yasha TC

127. Pineal Parenchymal Tumours 957
Vani Santhosh

128. Neuronal and Mixed Neuronal Glial Tumours 960
Sharma MC, Chitra Sarkar

SECTION XI: CRANIAL AND INTRACRANIAL TUMOURS

129. Clinical Features of Intracranial Tumours 967
Ravi Ramamurthi, Santosh Mohan Rao K

130. Supratentorial Astrocytomas 990
Ramakrishna Easwaran

131. Cerebellar Astrocytomas 1010
Ramakrishna Easwaran

132. Brainstem Gliomas 1016
Sarat Chandra P, VS Mehta

133. Hypothalamic-Optic Nerve Gliomas 1024
Ramakrishna Easwaran

134. Oligodendrogliomas 1032
Ravi Ramamurthi, Nigel Peter Symss

135. Ependymomas 1037
Harjinder S Bhatoe

136. Medulloblastomas 1043
BS Sharma

137. Metastatic Brain Tumours 1049
Ravi Ramamurthi, Harinivas

138. Radiation Therapy for Malignant Brain Tumours 1057
Julka PK, Haresh KP, Rath GK

139. **Adjuvant Therapies for Malignant Brain Tumours** 1065
Raj Kumar R, Ashok Kumar Mahapatra

140. **Colloid Cyst** 1071
Nigel Peter Symss, Ravi Ramamurthi

141. **Choroid Plexus Tumours** 1076
Vasudevan MC

142. **Pineal Region Tumours: Clinical Features and Management** 1080
Ramakrishna Easwaran

143. **Pituitary Tumours Overview** 1088
Ravi Ramamurthi

144. **Prolactinomas** 1094
Ravi Ramamurthi, Prasad AN

145. **Growth Hormone Secreting Adenomas** 1098
Ravi Ramamurthi, Goutham Cugati

146. **Cushing's Disease and Syndrome** 1102
Deepu Banerji, Sanjay Behari

147. **Other Secreting Adenomas of the Pituitary** 1109
Deepu Banerji, Archana Juneja

148. **Non-functioning Pituitary Adenomas** 1113
Manas Kumar Panigrahi, Naveen Mehrotra, Amit Kumar T

149. **Pituitary Apoplexy** 1118
Ravi Ramamurthi, Vikram M, Goutham Cugati

150. **Giant Invasive Pituitary Adenomas** 1121
Ravi Ramamurthi, Goutham Cugati

151. **Perioperative Endocrine Management of Pituitary Adenomas** 1125
Murthy S

152. **Empty Sella Syndrome** 1134
Ravi Ramamurthi, Murali Mohan S

153. **Diencephalic Syndrome** 1140
Anil Pande, Murali Mohan S

154. **Other Tumours of the Sellar Region** 1145
Sanjay Behari, Anooj Chatley, Abrar Ahad Wani, Manoj Jain

155. **Craniopharyngioma** 1164
SN Bhagwathi, Suresh Sankhla

156. **Dermoids and Epidermoids** 1174
Ravi Ramamurthi, Amit Kapoor

157. **Teratomas** 1182
Ravi Ramamurthi, Amit Kapoor

158. **Acoustic Schwannomas** 1186
Ravi Ramamurthi, Murali Mohan S

159. **Trigeminal Schwannomas** 1205
BS Sharma, Ramdurg S, Sarat Chandra P

160. **Jugular Foramen Lesions** 1210
Siddhartha Ghosh

161. **Other Intracranial Schwannomas** 1219
Ashish Suri, Shashwat Mishra, Ajay Garg

162. Phakomatoses 1225
Ashish Suri, Shashwat Mishra, Ajay Garg

163. Convexity Meningiomas 1231
Vasudevan MC

164. Parasagittal and Falx Meningiomas 1237
Vasudevan MC

165. Olfactory Groove Meningioma 1240
Ravi Ramamurthi, Nigel Peter Symss

166. Sphenoidal Wing Meningiomas 1246
Trimurti D Nadkarni

167. Tentorial Meningiomas 1251
Vijendra Kumar Jain, Sanjay Behari, Pramod Giri

168. Posterior Fossa Meningiomas 1258
Amitabha Chanda, Abhijit Guha

169. Petroclival Meningiomas 1267
Trimurti D Nadkarni

170. Foramen Magnum Meningiomas 1271
Shrivastava RK, Chandranath Sen

171. Intraventricular Meningiomas 1277
Harjinder S Bhatoe, Prakash Singh, Vibha Dutta

172. Haemangioblastomas 1281
Ravi Ramamurthi

173. Primary Central Nervous System Lymphomas 1286
Sanjay Behari, Punita Lal, Samir Kalra, Manoj Jain

174. Intracranial Melanomas and Other Tumours 1294
Bhawani S Sharma, Sumit Sinha

175. Benign Intracranial Tension 1299
Nigel Peter Symss, Ravi Ramamurthi

176. Tumours of the Cranial Vault 1304
Narayanan R, Ravi Ramamurthi

SECTION XII: SKULL BASE SURGERY

177. Clival Chordomas 1322
Chandranath Sen

178. Transfacial Transmaxillary Approaches to Anterior Skull Base 1326
Sojan Ipe, Bobby Jose

179. Approaches to the Lateral Skull Base 1333
Atul Goel, Muzumdar D

180. Transpharyngeal Approach to the Craniovertebral Junction 1341
AH Menezes

181. Reconstruction of the Skull Convexity and Base 1346
Atul Goel, Muzumdar D

182. Orbital Tumours 1353
Aadil S Chagla

SECTION XIII: STEREOTAXY

183. Stereotaxy: General Principles 1363
Ravi Ramamurthi, Vikram M

184. Stereotaxy: Brain Tumours 1370
Murali Mohan S, Ravi Ramamurthi

185. Involuntary Movements: Anatomy and Pathophysiology 1374
Srinivasan AV

186. Stereotaxy for Parkinson's Disease 1379
Dilip Panicker, Paresh K Doshi

187. Surgery for Movement Disorders 1384
Paresh K Doshi, Animesh Upadhyay

188. Gamma Knife Radiosurgery 1391
Manish Singh Sharma, BS Sharma

189. Psychosurgery 1397
Ramamurthi B, V Balasubramaniam, Ravi Ramamurthi, Santosh Mohan Rao K

190. Neural Transplantation and Stem Cell 1408
PN Tandon

SECTION XIV: PAIN

191. Pain: Anatomy and Physiology 1411
Ravi Ramamurthi, Santosh Mohan Rao K

192. Management of Pain 1425
Nigel Peter Symss

193. Trigeminal Neuralgia 1443
Ramakrishna Easwaran

194. Glossopharyngeal and Other Cranial Neuralgia 1450
Ravi Ramamurthi, Goutham Cugati

195. Microvascular Decompression 1456
Ravi Ramamurthi, Manish Singh

SECTION XV: EPILEPSY

196. Epilepsy: Overview 1462
Dinesh Nayak S, Radhakrishnan K

197. Epilepsy: Medical Management 1471
Ashalatha, Radhakrishnan K

198. Surgery for Epilepsy: General Principles 1475
Bhaskara Rao Malla, Jayanti Mani

199. Surgery for Temporal Epilepsy 1487
Bhaskara Rao Malla, Jayanti Mani

SECTION XVI: CEREBRAL PALSY

200. Stereotaxy for Cerebral Palsy 1495
Kanaka TS, Balasubramaniam V, Sampathkumar M

201. Surgery for Spasticity 1501
AK Purohit, Jagan Mohan Reddy K

SECTION XVII: MISCELLANEOUS

202. Anaesthesia for Neurosurgery **1512**
Gupta D, Srivastava S

203. Positioning in Neurosurgery **1531**
Indira Devi, Nitin Garg N, Shukla D

204. Operation Theatre for Neurosurgery **1534**
Rahmathulla G, Ajaya Nand Jha

205. Basic Neurosurgical Instruments **1538**
Sanjay Behari, Singh RK, Lyngdoh B, Jain S, Chhabra DK

206. Navigation in Brain and Spinal Surgery **1555**
Ajaya Nand Jha, Rahmathulla G

207. Endoscopy in Brain Tumour Surgery **1566**
Manas Kumar Panigrahi

208. Orthotics **1572**
PK Sethi

209. Principles of Physiotherapy **1577**
Sangeetha Ranganath

Index *1581*

CHAPTER 3

Neuro-ophthalmology

Tandon R • Saxena R • Phuljhele S

EFFECTS OF BRAIN TUMOURS ON VISUAL PATHWAYS

Direct effects:

- Direct compression.

Indirect effects: Papilloedema

- Impact of tumour resection
- Post-radiation neuropathy
- Toxic effects due to chemotherapy
- Metastatic lesions to retina or infiltration of optic nerve
- Haematological effects like ischemia, venous engorgement.

THE NORMAL FIELD OF VISION

- The visual field is a three-dimensional area which is visible through each eye when fixating at a central target.
- The field of vision is centred at a fixation point of each eye, as an asymmetric oval shape extending maximally on the temporal side for about 90 degrees.
- The superior and inferior fields have an extension of 40 and 60 degrees, respectively. Nasally it is restricted by the nasal bridge and measures up to 40 degrees.
- There is binocular representation of the visual fields for 60 degrees to the right and left of a common fixation point.

THE NORMAL VISUAL PATHWAY

- The visual pathway begins with stimulation of photoreceptors of the retina and processing in the ganglion cells. The axons of the ganglion cells converge to form the optic nerve.
- The nerve then travels through the optic canal and emerges in the intracranial cavity at the sellar region. At this juncture, the nasal fibres of the optic nerve cross to form the optic chiasm. The contralateral nasal fibres and ipsilateral temporal fibres continue together as the optic tract, which provides for one-half of the binocular visual field.
- The optic tract is relayed in the ipsilateral lateral geniculate body (LGB) where sorting of fibres occurs.
- The third order neurons commence from the LGB and continue as the optic radiation that terminates in the visual cortex (area 17) of the occipital lobe (Fig. 1).

JAYPEE BROTHERS

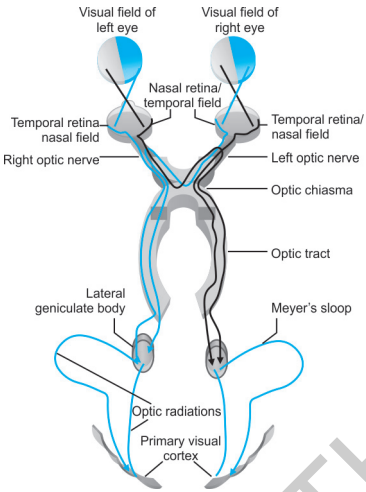

Fig. 1: Visual pathway

ASSESSMENT OF VISUAL FIELD

- The process of estimating and mapping the field of vision is called perimetry. The field of vision of a patient can be assessed by various methods; the easiest and convenient for bed-side examination is confrontation examination. This is a crude and subjective evaluation, wherein the examiner compares the visual field of the patient to his own field of vision.
- More sophisticated methods used routinely in clinical practice include Goldmann perimetry and automated perimetry, which are objective and, hence, more reliable methods. These techniques can precisely map and record the peripheral (full extent) as well as central (central 30°) field of vision, respectively.

INTERPRETATION OF VISUAL FIELD

Terminologies

Isopter: It is a line joining the retinal points of the same sensitivity.

Constriction: It implies that there is generalised decrease in sensitivity of the retina and, on kinetic perimetry, it encloses a smaller area than normal.

Hemianopia: When one-half of the visual field is involved either in one or both the eyes.

Homonymous: When the defects are present in the visual fields of both the eyes and are on the same side of the vertical meridian.

Heteronymous: When the defects are present in the visual fields of both the eyes but are on the opposite sides of the vertical meridian.

Scotoma: It is a localised area of decreased sensitivity. It may be absolute, when the patient cannot see even the brightest possible stimulus or it may be relative if some of the stimuli are seen. They can be classified either by their location or by shape.

Congruency: The extent to which the homonymous field defect in one eye resembles that in the other eye in terms of shape, size, depth and slope of the margins.

JAYPEE BROTHERS

Table 1: Visual field defects according to the location of the tumour

Location of tumours	*Structure involved*	*Type of field defect*
Orbit		
• Optic nerve glioma • Optic nerve meningioma	• Optic nerve	Total field loss (early lesions may present with central or centrocecal field defect)
Sella		
• Pituitary adenoma • Craniopharyngioma • Meningioma	• Chiasma • Chiasma • Willebrand's knee • Optic tract	• Bitemporal field defect • Bitemporal field defect • Junctional scotoma • Homonymous hemianopia (macular splitting)
Mid brain		
• Craniopharyngioma • Meningioma • Large pituitary adenoma • Aneurysms • Hamartomas	• Lateral geniculate body	• Sectoral defects
Parietal lobe		
• Meningiomas • Gliomas • Metastasis • Vascular	• Superior part of optic radiation	• Inferior quadrantic field defect • Homonymous hemianopia (macular splitting)
Temporal lobe		
• Gliomas • Metastasis • Vascular	• Inferior part of optic radiation	• Superior quadrantic field defect (usually incongruous in nature)
Visual cortex		
• Gliomas • Meningiomas • Metastasis • Vascular	• Occipital lobe	• Homonymous hemianopia sparing macula. (Complete or partial depending upon the size of the tumour)

VISUAL FIELD DEFECTS

- The arrangement of visual fibres in a particular region of the visual pathway determines the characteristics and shape of visual field defects.
- In general, lesions anterior to the optic chiasma produce monocular defects, while lesions affecting the chiasma and beyond are always bilateral.
- Heteronymous defects are seen in chiasmal lesions, while all lesions affecting the visual pathway beyond the chiasma produce homonymous lesions.
- The more posterior a lesion is in the visual pathway, the more congruent field defect it will produce. For example, a lesion of the occipital lobe will produce a more congruent field defect than that of the optic tract.

Retina

- The visual field and the retina have an inverted and reversed relationship. Thus, light rays from the temporal visual field stimulate the ganglion cells of the nasal retina. The axons of these ganglion cells form the nerve fibre layer and finally converge at the optic nerve head and exit as the optic nerve.
- The innermost layer of the retina, retinal nerve fibre layer (RNFL) bundles converge in a specific pattern to form the optic nerve head.
- The macular fibres are centrally placed, while fibres from the upper part of the retina lie superiorly and those from the lower retina are placed inferiorly in the optic nerve.

JAYPEE BROTHERS

- The layer of the retina that is affected by the disease process determines the pattern of field defect. Lesions in the outer retina have no particular definite boundaries, so they can produce field defects of varying shapes and sizes, while involvement of the RNFL produces a field defect corresponding to the particular pattern of the nerve fibre bundle affected.
- ***Papillomacular bundle*** involvement results in a central scotoma, centrocecal scotoma or paracentral scotoma.
- ***Arcuate nerve fibre bundle*** lesions may cause a variety of field defects like—Bjerrum or arcuate scotoma, Seidel scotoma, Nasal step of Ronne, depending on the site of the lesion. Arcuate field defect is seen in many conditions, apart from anterior optic nerve lesions (see the following box):

- Glaucoma
- Chorioretinal lesions
- Juxtapapillary choroiditis
- Myopia with peripapillary atrophy
- Central retinal artery occlusion
- Branch retinal artery occlusion
- Ophthalmic artery or carotid artery occlusion
- Drusen
- Optic nerve pit
- Chronic papilloedema
- Anterior optic nerve lesions
- Involvement of the nasal fibre bundle leads to temporal wedge-shaped defects.

Optic Nerve

- The optic nerve is formed by the axons of retinal ganglion cells that converge to form the nerve fibre bundles. It is about 50 mm in length and can be divided into four parts: optic nerve head (intraocular part 1 mm), intraorbital (25 mm), intracanalicular (10 mm) and intracranial (15 mm).
- The above described arrangement of the nerve fibres is maintained throughout the optic nerve, such that even lesions involving the posterior part of the optic nerve produce a pattern corresponding to the nerve fibre bundle involved (Fig. 2).
- In addition to the field defects described above, the involvement of axons at the superior or inferior pole of the optic disc produce *altitudinal defects*.

The Chiasma

- It is formed by the crossing of the nasal fibres of each optic nerve. It is located over the diaphragm sella and is posteriorly related to the wall of the third ventricle.
- In 80% located directly over the sella (central); in such cases, pituitary lesions involve the chiasma first. In about 10%, it is located more anteriorly over the tuberculum sellae (prefixed); here pituitary lesions will involve the optic tract first. In the remaining 10% of cases, it is located more posteriorly over the dorsum sella, where pituitary lesions involve the optic nerve first.

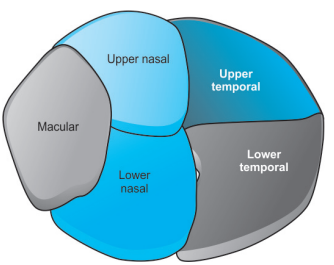

Fig. 2: Arrangement of nerve fibres in optic nerve

JAYPEE BROTHERS

- **Anteriorly**, the chiasma is related to the anterior cerebral arteries and their communicating branches. **Posteriorly**, it is related to the hypophyseal stalk and the pituitary body. It is immediately inferior to the floor of the third ventricle and lies above the hypophysis. **Laterally**, it is related to the internal carotid artery and the cavernous sinus.
- At the chiasma, the fibres representing the nasal visual field (temporal fibres) are present in the lateral part. The inferonasal fibres (superior temporal field) cross anteriorly in the chiasma and loop forward into the contralateral optic nerve, forming von Willebrand's knee and then continue in the contralateral optic tract. The nasal macular fibres decussate most posteriorly. The upper nasal fibres (inferior temporal field) cross in the middle (Fig. 3). Thus, the right optic tract constitutes the right nasal field (right temporal axons) and the left temporal field (left nasal decussated fibres) representing the left half of the visual space.
- A patient presents with varying signs and symptoms, depending upon the type, size and site of the lesion. Pituitary adenoma presents with signs of compression of the visual pathways, as well as other features of hormonal disturbance. There may be unilateral or bilateral loss of vision, as a result of concurrent compression of the optic nerve by the tumour. Relative afferent pupillary defect may be present in unilateral lesions. Lesions of the cavernous sinus and large pituitary adenomas compress the motor nerves of the eye, leading to ocular motility disorders. See-saw nystagmus and oscillopsia are features of tumour or trauma.
- **Field Defects:**
  - ***Bitemporal hemianopia:*** Lesions that affect the body of the chiasma produce bitemporal hemianopia. Lesions of the pituitary gland, i.e. tumours, inflammation or haemorrhage are the common conditions. Inferior bitemporal hemianopia is characteristic of craniopharyngioma. Saccular aneurysms of vessels in the circle of Willis can also lead to bitemporal hemianopia.
  - ***Junctional scotoma:*** It is produced when a lesion involves the junction of the optic nerve and chiasma, leading to an optic nerve defect in the ipsilateral eye and superior temporal (involvement of von Willebrand's knee) defect in the contralateral eye.
  - ***Binasal field defects:*** A large mass lesion compressing one side of the optic chiasma, on further enlargement, causes a midline shift of the chiasma with subsequent compression of the other side as well, leading to a binasal field loss presentation. This pattern of field loss

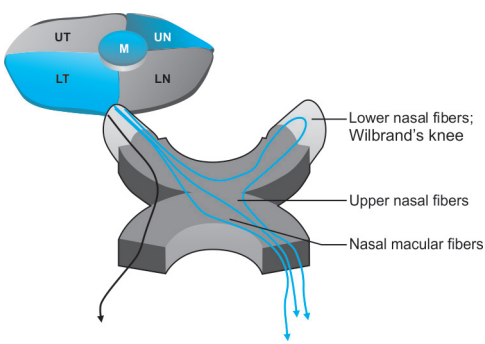

Fig. 3: Decussation of optic nerve fibres at the chiasma

JAYPEE BROTHERS

can also be seen with empty sella syndrome (ESSD), arachnoiditis and after surgery for pituitary tumours.

– ***Homonymous hemianopia:*** This type of field defect is commonly seen in cases where the chiasma is prefixed. Thus, any lesion which affects the chiasma can also affect the optic tract, leading to homonymous hemianopia. Large pituitary adenomas and craniopharyngiomas are the most common causes.
– Lesions that affect the posterior part of the chiasma cause *central bitemporal hemianopia*.

Optic Tract and Lateral Geniculate Body

- The optic tract runs superiorly and posteriorly from the optic chiasma and curves around the brainstem to terminate in the LGB. The LGB is a part of the thalamus and is situated along the lateral aspect of the midbrain. Each geniculate body consists of six layers of neurons and second order fibres, travelling through the optic tract, are relayed in different layers of the LGB. It receives dual blood supply from the anterior and lateral choroidal arteries, which nourish the fibres from the superior and the inferior homonymous quadrants of the retina, respectively. The optic tracts lie between the tuber cinereum and the anterior perforated substance.
- Each optic tract is formed by the temporal fibres of the ipsilateral eye and the nasal fibres from the contralateral eye.
- The axons from the ipsilateral eye are relayed in nuclei layers 2, 3 and 5, while the axons from the contralateral side relay in 1, 4 and 6 nuclei layer. The fibres from the upper part of the retina occupy the medial half of the anterior one-third of the LGB. The lower retinal fibres occupy the lateral half of the anterior one-third of the LGB, while the macular fibres are relayed in the posterior two-third of the LGB.
- The most useful sign of localising a lesion between the optic tract and LGB is involvement of the pupil. Optic tract lesions are associated with various pupillary abnormalities including RAPD on the contralateral side, Wernicke's hemianopic pupil and Behr's pupil, while in lesions of the LGB, pupillary reactions are spared.
- Lesions affecting the optic tracts are craniopharyngiomas, meningiomas, and large pituitary adenomas, demyelinating diseases, vascular lesions, such as aneurysms, arteriovenous malformations and hamartomas.
- Lesions affecting the LGB include infarction, tumours, trauma and inflammatory disorders.
- Complete optic tract disruption on one side leads to complete macular splitting homonymous hemianopia, while partial involvement will cause an incongruous field defect. Similarly, a defect in one LGB will produce complete homonymous hemianopia, while partial lesions of the LGB cause a sectoral field defect.

Optic Radiations

- The optic radiations are geniculocalcarine pathways that extend from the LGB to the visual cortex. They cross the Wernicke's area as optic peduncles and travel in the retrolenticular part of the internal capsule.
- The fibres, after exiting from the LGB, rotate by 90 degrees again to regain their original arrangement. Thus, the superior fibres lie in the upper part of the radiation, the inferior fibres in the lower part and the macular fibres lie in the centre.

JAYPEE BROTHERS

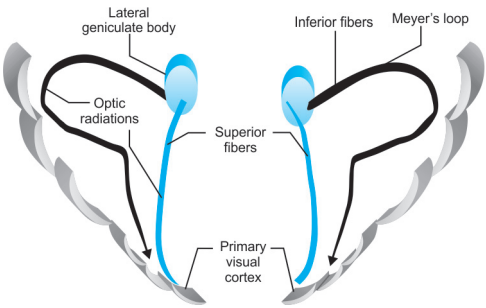

Fig. 4: Arrangement of optic radiations

- ***Arrangement of fibres in the temporal lobe:*** The inferior fibres from the corresponding superior visual fields of both eyes commence from the anterolateral part of the LGB, sweep anteriorly and then laterally along the temporal horn of the lateral ventricle to form Meyer's loop, then extend posteriorly to end in the area below the calcarine fissure of the occipital cortex (Fig. 4). The clinical features of temporal lobe lesions are seizures, paragnosia, involuntary movement of the mouth, and visual and auditory hallucinations. Aphasia is characteristic of left temporal lobe lesions. The most common temporal lobe lesions are tumours, which include glioma and metastasis. Surgical resection of the tumour (when more than 8 cm), itself may produce field defects. Anterior choroidal artery occlusion may affect the optic radiation in the temporal lobe and LGB. Other lesions are trauma, demyelination and abscess.
- ***Arrangement of fibres in the parietal lobe:*** The superior fibres that carry the inferior field travel directly through the lower portions of the parietal cortex to the occipital lobe area above the calcarine fissure (Fig. 4).

Clinical Features of Parietal Lobe Involvement

- The two most important localising signs of a parietal lobe lesion are loss of normal optokinetic response and conjugate deviation of the eyes. The involvement of the right parietal lobe leads to deficit of spatial orientation of the left space, thus the patient may neglect the left half of the body. Involvement of the left parietal lobe is associated with Gerstmann's syndrome (agraphia, acalculia and visual agnosia). The differential diagnosis of lesions involving the parietal lobe, include infarction, haemorrhage, AVM and tumours.
- Lesions involving the optic radiations produce field defects which are homonymous and more congruous. The involvement of the anterior temporal lobe will produce contralateral homonymous superior quadrantanopia. In more extensive lesions, the defect may extend inferiorly but the hemianopia will be denser superiorly. The defects are wedge shaped defects of varying sizes and are homonymous and incongruous.
- Lesions involving the parietal lobe produce an inferior homonymous field defect that is classically described as pie on the floor. These defects are usually more extensive and more congruous than temporal lobe defects. The homonymous hemianopia of the parietal lobe is always associated with macular splitting.

Visual Cortex

- The primary visual cortex (area 17) is located on the medial surface of the occipital lobe near the calcarine fissure. Brodmann's area 18 and

JAYPEE BROTHERS

19 are associated visual areas which help in further processing of visual information.

- The right visual cortex receives impulses from the left temporal field and the right nasal field. The orientation of fibres in the optic radiation is maintained in the visual cortex. The central field is represented at the occipital tip and is separated from the representation of peripheral fibres. The superior fibres (representing inferior field) are relayed in the area superior to the calcarine fissure while the inferior fibres (superior field) are projected to the area inferior to the fissure.
- Occlusion of the left posterior cerebral artery causes infarction of the left calcarine cortex, along with the splenium of the corpus callosum, which produces field defects in the right side and alexia without agraphia. Other signs include headache, visual agnosia and dyschromatopsia, which are mainly secondary to the infarction. Tumours lead to isolated visual field defects and palinopsia. Tumours affecting the occipital lobe are gliomas, meningiomas and metastasis. Bilateral occipital disease is usually due to vascular lesions which include thromboembolism, haemorrhage, hyperviscosity syndromes and vasculitis. This is also a feature following bilateral tentorial herniation, which results in bilateral occipital infarct resulting in blindness.
- **Field Defects:**
  - Occipital lobe lesions produce field defects that are homonymous and highly congruous.
  - ***Complete homonymous hemianopia sparing the macula:*** The macular area is a watershed zone of anastomoses between the middle and the posterior cerebral arteries. Ischaemia of the occipital lobe results in sparing of the central 3–5 degrees of the visual field due to its dual blood supply.
  - ***Central homonymous hemianopia:*** A lesion affecting the tip of the occipital lobe would produce a field defect in the macular area which is homonymous. In such cases, at least 5 degrees of the central field is spared in both eyes on the side of hemianopia.
  - ***Quadrantic field defects:*** Lesions of the area below the calcarine fissure would give rise to a homonymous superior quadrantic defect. Similarly, a lesion involving the area above the calcarine fissure would lead to an inferior homonymous defect.

Involvement of the occipital lobe bilaterally may lead to *bilateral homonymous hemianopia* with sparing of central tubular vision. This should be differentiated from other causes of constricted visual field like malingering, glaucoma and retinitis pigmentosa.

SPECIAL VISUAL FIELD DEFECTS

Baring of Blind Spot

- When a small degree of field is mapped, the isopter may be constricted and any scotoma outside the isopter may be continuous with the blind spot causing baring of the blind spot.

Binasal Hemianopia

- They are bilateral nasal defects usually caused by involvement of arcuate fibres of both eyes. Rarely, caused by pressure upon the temporal aspect of the optic nerve or anterior portion of the chiasma, as in cases of aneurysm, pituitary tumour and vascular infarction.

JAYPEE BROTHERS

for detailed information on neurosurgery books, visit our website www.jaypeebrothers.com, for detai

Salient Features

- This book is a companion to *Ramamurthi and Tandon's Textbook of Neurosurgery* (Third Edition)
- It has 17 sections and around 209 chapters covering all aspects of neurosurgery
- This book offers the reader comprehensive, concise, up-to-date and clinically-oriented coverage on all aspects of neurosurgery
- Comprises numerous illustrations, tables and diagrams
- Integrates the knowledge and experience of various Indian and International Neurosurgeons
- This book will be great value to medical students, postgraduates in neurology and neurosurgery (MD/MCh/DNB), neurologists, neurosurgeons, general surgeons and ENT surgeons
- A comprehensive coverage of treatment aspects of various neurosurgical diseases.



Prakash Narain Tandon MBBS MS FRCS DSc (hc) FNA FNASc FTWAS FAMS FRSM received his neurosurgical training at Oslo, Norway and Montreal Neurological Institute, Montreal, Canada. He established academic department of Neurosurgery in the All India Institute of Medical Sciences, New Delhi, India. His research contributions cover a wide range of basic and applied aspects of neurosciences. These included contributions on tuberculosis of the nervous system, developmental defects of the brain, head injury, spontaneous subarachnoid haemorrhage, brain tumours and neural transplantation. He has written over 220 scientific papers, 14 monographs and a number of invited contributions to national and international books, related to neuro-oncology, neuro-otology, neuronuclear medicine, epilepsy, etc. He has steered the establishment of a series of national facilities such as the Neuroinformatic Centre, Neural Transplant Unit, a Brain Bank, a national NMR facility for biomedical research, etc. He is the founder President of the NBRC Society and Chairman of its Scientific Advisory Committee. He has been elected as a Fellow/Member to serve on the policy-making bodies of various Scientific Academies, Research Councils and Government Departments, both nationally and internationally. He was nominated to deliver lectures under the India-ASEAN Eminent Persons lecture series 1999 and invited to the World Economic Forum in 1999 as one of the 10 distinguished scientists from around the world. He has been a recipient of a large number of awards and honours. These include BC Roy Award for developing a speciality (1980); BC Roy Award for Eminent Medical Scientist (1993); Sir CV Raman Medal (1997); Jawaharlal Nehru Birth Centenary Award (ISCA) 1999, etc. He was Honorary Surgeon to the President of India (1977–80) and Member of Science Advisory Council to the Prime Minister (1986–89). The President of India decorated him with Padma Shri in 1973 and Padma Bhushan in 1989.



Ravi Ramamurthi MS FRCS Ed (SN) is a reputed neurosurgeon from Chennai, and he was the Head of the Department of Dr Achanta Lakshmipathi Neurosurgical Centre, Voluntary Health Services, Chennai. He did his MBBS from Chennai in 1976, and subsequently his MS in neurosurgery from Madras Medical College and then his FRCS Ed (SN) from Edinburgh, UK in 1983. In the past he was holding eminent positions in various renowned institutions nationally as well as internationally. He was appointed as Guest Doctor, Justus Liebig University, Giessen, West Germany for training in microneurosurgery. He was assigned the designation of Registrar in Neurosurgery, Newcastle General Hospital, Newcastle UponTyne, UK. He was an Executive Member of Neurological Society of India from 1996–99 and was holding the position of Honorary Treasurer, Neurological Society of India from 2006–09. Among his many credentials, he has written a number of papers in national as well as international journals. He presented approximately 50 papers at prestigious conferences held in India and abroad. He has been continuously holding the position of Organising Secretary and Faculty of Microworkshop since 1994.



Pradeep Kumar Jain N MBBS DNB (Neurosurgery) is a senior resident in Department of Dr Achanta Lakshmipathi Neurosurgical Center, Voluntary Health Services, Chennai. He did his MBBS from JJM Medical College, Davangere in 2006. He Joined prestigious Voluntary Health Services, Chennai in 2007 and completed his five years DNB Neurosurgery training under Dr Ravi Ramamurthi and Dr MC Vasudevan. He has done research and thesis on anterior cervical microdiscectomy without fusion. He has platform presentations in NSI 2008, 2010 and 2012. He has organized workshops in Voluntary Health Services from 2009–12. He is an editorial assistant in *Ramamurthi and Tandon's Textbook of Neurosurgery* (Third Edition) and Co-author for one chapter. He has attended various workshops and national conferences. He co-authored six publications in various national and international journals. Currently, he is working on *Textbook of Operative Neurosurgery* (Second Edition) under Prof PN Tandon and Dr Ravi Ramamurthi.

Available at all medical book stores
or buy directly from Jaypee Brothers through online shopping
at www.jaypeebrothers.com

JAYPEE BROTHERS
Medical Publishers (P) Ltd.
www.jaypeebrothers.com

Join us on facebook.com/jaypeebrothers

Shelving
Recommendations
Neurosurgery
Neurology

ISBN 978-93-5152-192-1