ebsite www.jaypeebrothers.com, for detailed information on cardiology books, visit our website www.jaypeebrothers.com

Manual of CARDIAC DIAGNOSIS

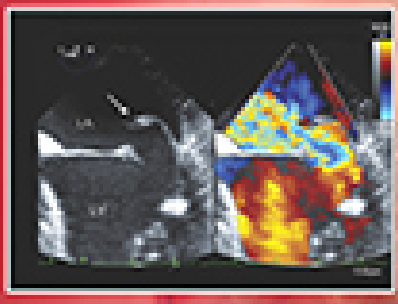

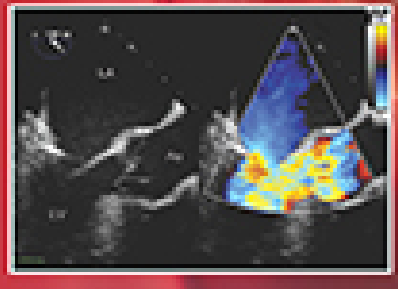

Kanu Chatterjee
Mark Anderson
Donald Heistad
Richard E Kerber

Contents

1. History **1**
Kanu Chatterjee
- *The History 1*
- *References 17*

2. Physical Examination **18**
Kanu Chatterjee
- *General Appearance 18*
- *Measurement of Arterial Pressure 23*
- *Auscultation 40*
- *References 68*

3. Plain Film Imaging of Adult Cardiovascular Disease **71**
Brad H Thompson, Edwin JR van Beek
- *Introduction 71*
- *Chest Film Technique 71*
- *Overview of Cardiomediastinal Anatomy 73*
- *Cardiac Anatomy on Chest Radiographs 75*
- *Cardiac Chamber Enlargement 76*
- *Radiographic Manifestations of Congestive Heart Failure 80*
- *Cardiac Calcifications 86*
- *Acquired Valvular Heart Disease 88*
- *Pericardial Disorders 92*

4. Electrocardiogram **96**
Donald Brown
- *Introduction 96*
- *Basis of Electrocardiography 96*
- *Component Parts of the Electrocardiogram 100*
- *Lead Systems Used to Record the Electrocardiogram 100*
- *Common Electrode Misplacements 103*
- *Other Lead Systems 107*
- *Identification of Atrial Activity 107*
- *Characterization of QRS Complex 121*
- *ST–T Wave Abnormalities 131*
- *"U" Wave 134*
- *QT Interval 134*

5. ECG Exercise Testing **137**
Abhimanyu (Manu) Uberoi, Victor F Froelicher
- *Introduction 137*
- *Before the Test 138*
- *Methodology of Exercise Testing 142*
- *During the Test 147*
- *After the Test 160*
- *Screening 166*

6. Left Ventricle **177**
Rakesh K Mishra, Nelson B Schiller
- *Introduction 177*
- *Systolic Function 178*

- *Contrast-Enhanced Echocardiography 197*
- *Other Echo-Derived Indices of LV Systolic Function 197*
- *Strain-Derived Indices 199*
- *Recognizing the Etiology of Cardiac Dysfunction 199*
- *Dilated Cardiomyopathy 200*
- *Hypertrophic Cardiomyopathy 201*
- *Restrictive Cardiomyopathy 203*
- *Left Ventricular Noncompaction 205*
- *Visual Qualitative Indicators of Systolic Dysfunction 205*
- *Diastolic Function 210*

7. Ventricular Function—Assessment and Clinical Application **233**

Kanu Chatterjee, Wassef Karrowni, William Parmley

- *Introduction 233*
- *Determinants of Left Ventricular Performance 233*
- *Left Ventricular Pump Function 240*
- *Heart Rate 247*
- *Diastolic Function 249*
- *Right Ventricular Function 251*

8. Transthoracic Echocardiography **261**

Byron F Vandenberg, Richard E Kerber

- *Introduction 261*
- *Chamber Quantitation 261*
- *Doppler Echo 271*
- *Diastolic Function 272*
- *Pulmonary Hypertension 277*
- *Pericardial Disease 279*
- *Valvular Heart Disease 285*
- *Infective Endocarditis 303*
- *Intracardiac Masses 304*
- *Contrast Echocardiography 305*
- *Cardiac Resynchronization Therapy 307*

9 Stress Echocardiography **316**

Ellen El Gordon, Richard E Kerber

- *Introduction 316*
- *Using Stress Echocardiography in Clinical Decisions 317*
- *Future of Stress Echo 348*

10. Transesophageal Echocardiography **357**

Seyed M Hashemi, Paul Lindower, Richard E Kerber

- *Introduction 357*
- *History 357*
- *Guidelines 358*
- *Performance 358*
- *Safety 359*
- *Views 359*
- *Major Clinical Applications 360*
- *Structural Valve Assessment 366*
- *Acute Aortic Dissection 371*
- *Procedural Adjunct or Intraoperative Transesophageal Echocardiography (TEE) 372*

11. Real-time Three-dimensional Echocardiography 377
Manjula V Burri, Richard E Kerber

- *Introduction 377*
- *Technique 379*
- *Clinical Applications 387*
- *Future Directions 420*
- *Limitations 423*

12. Intravascular Coronary Ultrasound and Beyond 433
Teruyoshi Kume, Yasuhiro Honda, Peter J Fitzgerald

- *Introduction 433*
- *Intravascular Ultrasound 433*
- *Optical Coherence Tomography 464*
- *Angioscopy 475*
- *Spectroscopy 482*

13. Cardiovascular Nuclear Medicine—Nuclear Cardiology 497
Elias H Botvinick

- *Introduction 497*
- *Pathophysiologic Considerations 498*
- *Myocardial Perfusion Imaging 505*
- *Risk Assessment of General and Specific Patient Populations 521*
- *Positron Emission Tomography Perfusion and Metabolism 524*
- *Imaging Myocardial Viability 526*
- *Imaging Perfusion 530*
- *Quantitation of Regional Coronary Flow and Flow Reserve 532*
- *Blood Pool Imaging—Equilibrium Radionuclide Angiography and First Pass Radionuclide Angiography 533*
- *First Pass Curve Analysis 535*
- *Equilibrium Gated Imaging—Erna 538*
- *The Value of Functional Imaging 540*
- *Phase Analysis 545*
- *Imaging Myocardial Sympathetic Innervation 545*
- *Radiation Concerns 547*

14. Cardiac Computed Tomography 557
Isidore C Okere, Gardar Sigurdsson

- *Introduction 557*
- *Technical Aspects 558*
- *Coronary Artery Disease 569*
- *Myocardium and Chambers 575*
- *Pulmonary Veins 578*
- *Cardiac Veins 580*
- *Valvular Disease 580*
- *Pericardium 582*
- *Masses 584*
- *Incidental Findings 587*
- *Future 588*

15. Cardiovascular Magnetic Resonance 602
Robert M Weiss

- *Introduction 602*
- *Diagnosis of Epicardial Coronary Artery Stenosis 603*

- *Assessment of Global and Regional Left Ventricular Function at Rest and During Inotropic Stress 604*
- *Myocardial Perfusion Imaging 605*
- *Cardiovascular Magnetic Resonance Coronary Angiography 606*
- *Unrecognized Myocardial Infarction 607*
- *Dilated Cardiomyopathy 607*
- *Hypertrophic Cardiomyopathy 612*
- *Restrictive Cardiomyopathy 616*
- *Cardiovascular Magnetic Resonance-Guided Therapy 618*
- *Valvular Heart Disease 618*
- *Diseases With Right Ventricular Predominance 620*
- *Miscellaneous Conditions 624*

16. Molecular Imaging of Vascular Disease 637
Eric A Osborn, Jagat Narula, Farouc A Jaffer

- *Introduction 637*
- *Molecular Imaging Fundamentals 637*
- *Molecular Imaging Modalities 643*
- *Molecular Imaging of Vascular Disease Processes 646*

17 Cardiac Hemodynamics and Coronary Physiology 676
Amardeep K Singh, Andrew Boyle, Yerem Yeghiazarians

- *Introduction 676*
- *Cardiac Catheterization—The Basics 676*
- *Catheterization Computations 680*
- *Cardiac Cycle Pressure Waveforms 684*
- *Hemodynamics In Valvular Heart Disease 686*
- *Hemodynamics In Cardiomyopathy 695*
- *Hemodynamics In Pericardial Disease 700*
- *Coronary Hemodynamics 703*
- *References 707*

18. Cardiac Biopsy 709
Vijay U Rao, Teresa De Marco

- *Introduction 709*
- *History and Devices 709*
- *Techniques 711*
- *Safety and Complications 713*
- *Analysis of EMB Tissue 714*
- *Indications 716*
- *Disease States 724*
- *Cardiac Transplantation 737*

19 Swan-Ganz Catheters: Clinical Applications 750
Dipti Gupta, Wassef Karrowni, Kanu Chatterjee

- *Introduction 750*
- *Historical Perspective and Evolution of Catheter Designs 750*
- *Placement of Balloon Flotation Catheters 751*
- *Normal Pressures and Waveforms 754*
- *Abnormal Pressures and Waveforms 758*
- *Clinical Applications 759*
- *Indications for Pulmonary Artery Catheterization 768*
- *Complications 769*

20. Coronary Angiography and Catheter-based Coronary Intervention 776

Elaine M Demetroulis, Mohan Brar

- *Introduction 777*
- *Indications for Coronary Angiography 778*
- *Contraindications for Coronary Angiography 780*
- *Patient Preparation 781*
- *Sites and Techniques of Vascular Access 782*
- *Catheters for Coronary Angiography 786*
- *Catheters for Bypass Grafts 788*
- *Arterial Nomenclature and Extent Of Disease 790*
- *Angiographic Projections 792*
- *Normal Coronary Anatomy 793*
- *Congenital Anomalies of the Coronary Circulation 801*
- *General Principles for Coronary and/or Graft Cannulation 806*
- *The Fluoroscopic Imaging System 814*
- *Characteristics of Contrast Media 816*
- *Contrast-Induced Renal Failure 817*
- *Access Site Hemostasis 819*
- *Complications of Cardiac Catheterization 821*
- *Lesion Quantification 824*
- *Degenerated Saphenous Vein Grafts 828*
- *Lesion Calcification 828*
- *Physiologic Assessment of Angiographically Indeterminate Coronary Lesions 829*
- *Clinical Use of Translesional Physiologic Measurements 830*
- *Non-Atherosclerotic Coronary Artery Disease and Transplant Vasculopathy 831*
- *Potential Errors In Interpretation of the Coronary Angiogram 834*
- *Percutaneous Coronary Intervention 838*
- *Pharmacotherapy for PCI 839*
- *Parenteral Anticoagulant Therapy 846*
- *Equipment for Coronary Interventions 848*
- *Percutaneous Transluminal Coronary Angioplasty 851*
- *Coronary Stents 852*
- *Types of Stents 852*
- *Stent Deployment 853*
- *Adjunctive Coronary Interventional Devices 854*
- *Embolic Protection Devices for Venous Bypass Graft PCI 856*
- *Clinical Outcomes 857*
- *Procedural Success and Complications Related to Coronary Intervention 862*
- *Complications Specific to PCI 862*

Index 881

Plain Film Imaging of Adult Cardiovascular Disease

CHAPTER 3

Brad H Thompson, Edwin JR van Beek

Chapter Outline

- Chest Film Technique
- Overview of Cardiomediastinal Anatomy
- Cardiac Anatomy on Chest Radiographs
- Cardiac Chamber Enlargement
  - Left Ventricular Enlargement
  - Right Ventricular Enlargement
  - Left Atrial Enlargement
  - Right Atrial Enlargement
- Radiographic Manifestations of Congestive Heart Failure
- Cardiac Calcifications
- Acquired Valvular Heart Disease
  - Aortic Stenosis
  - Aortic Insufficiency
  - Mitral Stenosis
  - Mitral Regurgitation
  - Pulmonary Valve Stenosis
  - Pulmonary Valve Insufficiency
  - Tricuspid Insufficiency
- Pericardial Disorders
  - Pericardial Effusion
  - Pericardial Cysts
  - Congenital Absence of the Pericardium

INTRODUCTION

Plain film radiography of the chest offers valuable information about the cardiovascular system and appropriately should serve as the initial investigative test in patients suspected of having cardiovascular disease, especially those with presenting with chest pain. Furthermore, by analysis of cardiac morphology, pulmonary vasculature and the vascular pedicle, chest films can provide additional semiquantitative information about heart function, pulmonary blood flow, and circulating blood volume. As such, serial chest films ideally serve as a noninvasive, inexpensive modality to monitor the efficacy of treatment regimens for conditions like heart failure and provide useful surveillance of the cardiovascular system in postsurgical patients following coronary bypass or heart transplantation. This chapter will cover the salient features of a variety of those cardiovascular diseases and anomalies, which are commonly encountered in adults.

CHEST FILM TECHNIQUE

Radiographic assessment of the thoracic cardiovascular structures ideally requires the acquisition of two projections of the chest. This is primarily due to the oblique position of the heart within the chest. Frontal chest radiographs can be obtained either with the ventral chest closest to the film (PA projection) or reversed (AP film). Conventionally, frontal radiographs of the chest obtained within the department are usually obtained in the PA projection while all portable films use an AP technique. Selection between these two options however is not entirely academic, as there are significant changes relating to heart size between these two examinations. Since the heart is located

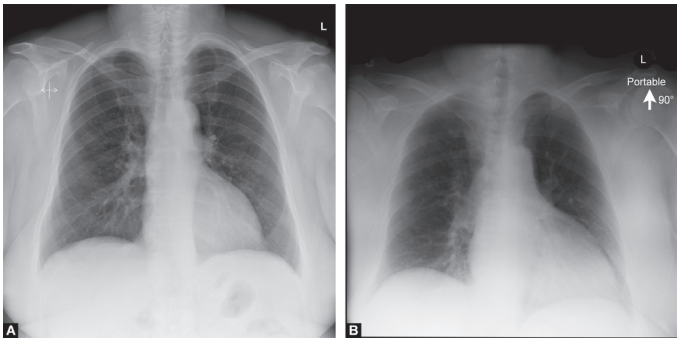

FIGURES 1A AND B: PA vs AP films: (A) PA film and (B) AP film on the same patient days apart. Note the significant increase in the size of the cardiac silhouette on the AP film due to magnification

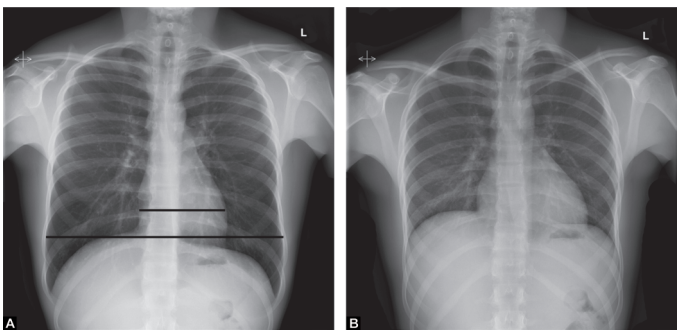

FIGURES 2A AND B: (A) Inspiratory vs (B) expiratory PA chest films. Horizontal lines reflect points of measurements for the cardiothoracic ratio (TR). Note the apparent increase in the size of the heart with expiration (B)

ventrally within the chest cavity, the divergence of the X-ray beam which occurs with AP films results in an undesirable artifactual magnification of the cardiac silhouette **(Figs 1A and B)**. Furthermore, portable AP films usually compound this problem in large part to associated recumbency and diminished lung volumes, which tend to further magnify the apparent size of the heart.

Qualitative assessment of cardiac enlargement can be quickly established radiographically by measuring the cardiothoracic ratio (CTR). This ratio, as measured on upright PA chest radiographs, refers to the ratio of the transverse diameter of the cardiac silhouette (measured horizontally) compared to the transverse chest diameter (as measured horizontally from inner margins of the ribs at the level of the right diaphragm). A normal CTR measured by this method should be 0.5 or smaller, provided there is good inspiratory effort. Decreases in lung volumes will produce an artificial increase in the systolic time ratio (STR), due the more horizontal axis of the heart along the left diaphragm **(Figs 2A and B)**. Due to magnification and

diminished lung volumes commonly encountered with AP chest films, the calculation of the STR is unreliable and should not be performed, especially on portable films.

Due to the oblique orientation of the heart within the chest, single frontal radiographs generally do not provide sufficient qualitative information about cardiac morphology, and as such complementary lateral films are desirable whenever possible. Normal anatomy of the heart on both frontal and lateral chest radiographs will be discussed later.

OVERVIEW OF CARDIOMEDIASTINAL ANATOMY

Located centrally within the chest, the cardiomediastinal silhouette comprises the heart, the central large vessels (aorta, pulmonary artery, superior and inferior vena cava and azygos vein), the tracheobronchial, esophagus and the adipose tissue of the mediastinum **(Figs 3A and B)**.

On either side of the central core structures are the hilar regions, which are composed of the central pulmonary arteries, mainstem bronchi, pulmonary veins and lymphatics. In general, the hila on chest films are largely composed of the pulmonary arterial shadows. The left hilum on the frontal radiographs is almost always higher in location than the right, reflecting the normal anatomical location of the left pulmonary artery, as it courses superior to the left mainstem bronchus. This anatomical relationship is inverted on the right side, i.e. the right mainstem bronchus is hyparterial. These relationships are also substantiated on the lateral film as well.

The assessment of the pulmonary vasculature should be performed on review of every chest radiograph as changes either in the vessel size or border definition provides excellent physiologic information both about the volume status of the patient as well as the severity of congestive heart failure. Normally, the pulmonary arteries should be sharply defined and

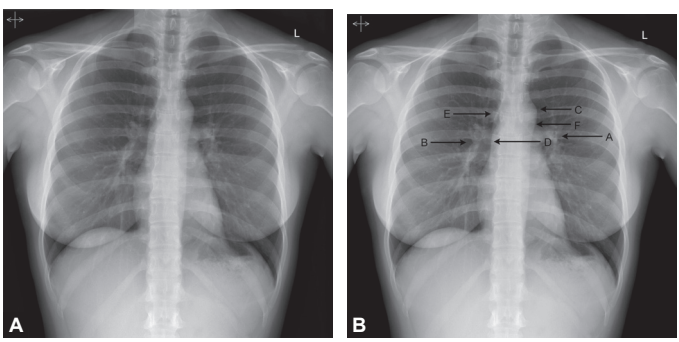

FIGURES 3A AND B: (A) Normal PA chest film with (B) annonations. (Abbreviations: A: Left hilum; B: Right hilum; C: Aortic knob; D: Superior vena cava (SVC); E: Azygous vein; F: AP window)

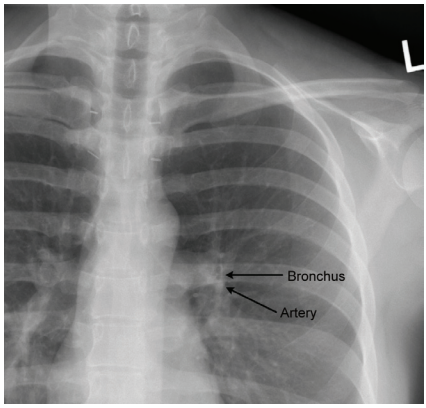

FIGURE 4: Normal arterial–bronchial relationship. Coned image from a PA chest film showing the normal 1:1 ratio of vessel size to adjacent bronchus (arterial–bronchus ratio). Also note the normal sharp definition of the arterial wall and thin bronchial wall

show a normal gravitationally dependent increase in lower lobe vascular conspicuity compared to the upper lobes **(Fig. 3A)**. This phenomenon, reflecting the increase in blood flow to the lower portions of the lungs can be demonstrated to good advantage by viewing an inverted PA chest film. With this maneuver, the observer will quickly appreciate the disparity of blood flow, i.e. vessel size and conspicuity between the upper and lower regions of the lungs. Furthermore, the observer should always evaluate the caliber of the pulmonary arteries. The normal caliber of normal pulmonary arteries should approximate the caliber of the adjacent bronchus. Determination of this arterial-bronchial ratio (A:B ratio) (normal = 1:1) is most easily performed evaluating the central-most vessels in the perihilar regions **(Fig. 4)**. An increase in the size of the upper lobe vessels indicating recruitment can be seen in left to right shunt lesions, high intravascular volumes/pregnancy and left heart failure or left heart obstructive lesions.

The thoracic aorta is visible in several regions on chest radiographs. Normally the ascending portion of the thoracic aorta is best demonstrated on the lateral projection residing in the retrosternal space. The ascending aorta is not usually apparent on frontal chest radiographs but with enlargement, the ascending aortic shadow may become visible along the right edge of the mediastinal silhouette above the right hilum. Conspicuous dilatation of the ascending aorta is seen in systemic hypertension, aneurysm, or aortic stenosis **(Figs 5 and 23A)**. The transverse portion of the thoracic aorta creates the aortic knob, which is visible at the top left portion of the mediastinum above the left hilar shadow **(Fig. 3B)**. On well-penetrated films, the descending aorta may be visible as a tubular opacity running inferiorly, parallel to the thoracic spine.

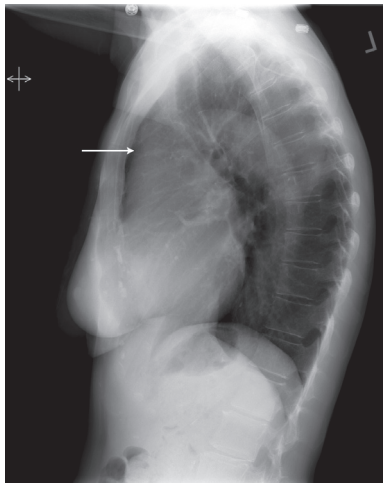

FIGURE 5: Patient with systemic hypertension. Lateral chest radiograph showing fusiform dilatation of the ascending thoracic aorta (arrow)

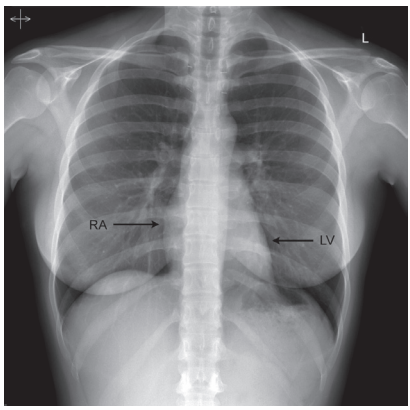

FIGURE 6: Normal PA chest film. The left ventricle (LV) forms the left heart border while the right heart border is composed of the lateral margin of the right atrium (RA)

On the lateral radiograph, the thoracic aorta will be seen as an arch, extending superiorly from the cardiac silhouette, arching backward and subsequently inferiorly along the ventral aspects of mid and lower portions of the thoracic spine. The descending thoracic aorta is usually poorly visualized on the lateral film, unless atherosclerotic calcifications exist.

CARDIAC ANATOMY ON CHEST RADIOGRAPHS

On the frontal radiograph **(Fig. 6)**, the heart is normally orientated slight to the left of midline with the interventricular septum normally orientated 30 degrees left anterior oblique (LAO). This orientation results in superimpositioning of the

right ventricle in front of the left ventricle. As such, the left heart border is composed entirely of the left ventricle. On the right side, the right atrium composes the right heart shadow **(Fig. 3B)**. The shadow of the superior vena cava (SVC) comprises the vertical right paramedian shadow coursing inferiorly from the upper mediastinum to the right atrium. In the middle of the SVC, directly superior to the proximal right mainstem bronchus lies the azygous vein, which appears as a teardrop vascular shadow reflecting the anterior course of this vein as it empties into the SVC. The left atrium, which is the most posterior cardiac chamber, is not normally visualized on frontal chest films, unless it is enlarged. Normally, the left heart border in adults should be concave on frontal radiographs.

On frontal radiographs, the concept of the three cardiac mogul shadows comprising the left cardiomediastinal silhouette needs to addressed. The superior most mogul reflects the aortic knob. Inferiorly, the left hilum (pulmonary artery) comprises the second mogul. While not normally present, the third mogul arises when there is enlargement of the left atrial appendage. This enlargement produces a conspicuous convexity along the normally concave left heart border **(Fig. 11A)**.

The aorticopulmonary window refers to the concave space, which is located immediately inferior to the aortic knob and just above the left pulmonary artery. Filling in or convexity of this space usually reflects either adenopathy or a mediastinal mass **(Fig. 3B)**.

On the lateral radiograph **(Fig. 7)**, the cardiac silhouette occupies the retrosternal region with the apex directly inferiorly toward the xiphoid process. Anteriorly, the right ventricle creates the anterior cardiac border. The left atrium forms the superior portion of the posterior aspect of the cardiac silhouette, with the mainstem bronchi immediately superiorly. The left ventricle forms the lower portion of the posterior margin of the heart shadow with the diaphragm immediately below it. With sufficiently good inspiration, the posterior border of the inferior vena cava (IVC) may be visualized on well positioned lateral films **(Fig. 7)**.

CARDIAC CHAMBER ENLARGEMENT

Left Ventricular Enlargement

Enlargement of the left ventricle will result in an enlargement of the cardiac silhouette, producing a bulbous left cardiac apex which is displaced down and out on the frontal radiograph **(Fig. 8)**. On the lateral projection **(Fig. 9)**, the left ventricular shadow will extend toward the thoracic spine away from the posterior border of the IVC. Normally, the posterior edge of the

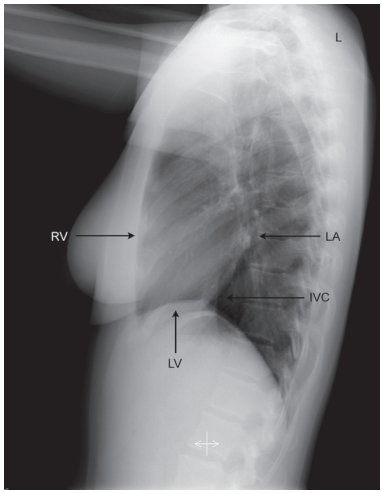

FIGURE 7: Normal cardiac anatomy on lateral radiograph. The right ventricle (RV) forms the ventral border of the cardiac silhouette while the inferoposterior border is composed of the left ventricle (LV). The left atrium (LA) composes the posterior-most border of the cardiac silhouette. The posterior border of the inferior vena cava (IVC) is also demonstrated to good advantage

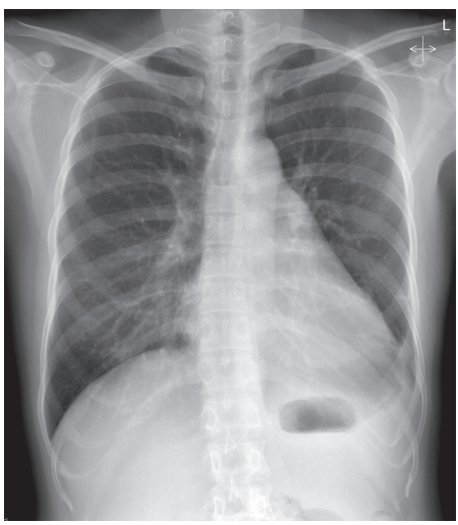

FIGURE 8: Left ventricular enlargement. PA chest film showing classic down and out configuration of the cardiac silhouette

left ventricular shadow should reside within two centimeters of the posterior edge of the IVC at a point two centimeters above the diaphragm (Rigler's rule). With left ventricular hypertrophy, cardiac morphology is generally preserved with no apparent increase in the overall size or change in the configuration of the left ventricle.

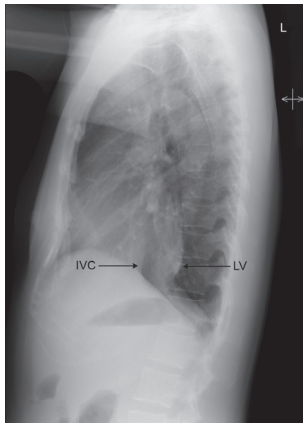

FIGURE 9: Left ventricular (LV) enlargement. Lateral film shows posterior displacement of the left ventricular shadow relative to the inferior vena cava (IVC) (arrows)

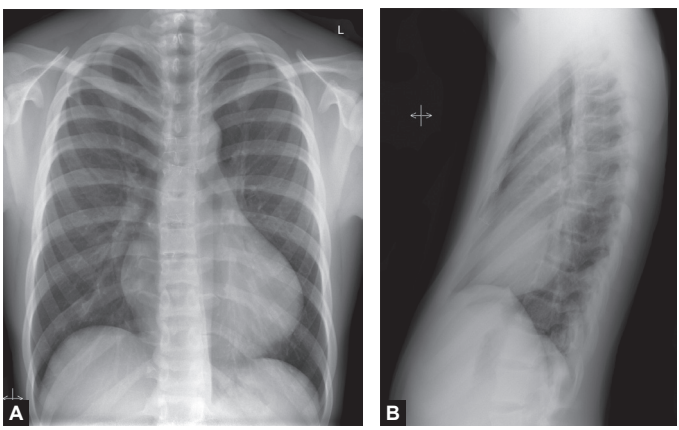

FIGURES 10A AND B: Right ventricular enlargement. PA and lateral films in patient with Tetralogy of Fallot. (A) The PA film shows the upturned ventricular shadow producing the "coer en sabot" or boot shaped heart. (B) The lateral film shows filling in of the retrosternal region by the enlarged right ventricle

Right Ventricular Enlargement

Right ventricular enlargement, although uncommon, is manifested by uplifting of the ventricular apex on frontal projections producing the "boot-shaped" heart or *coer en sabot* configuration. On the lateral film there should be corresponding encroachment toward the sternum with "filling in" the retrosternal clear space **(Figs 10A and B)**.

Left Atrial Enlargement

Left atrial/appendage enlargement will result in the formation of the third mogul as described above **(Figs 11A and B)**. With

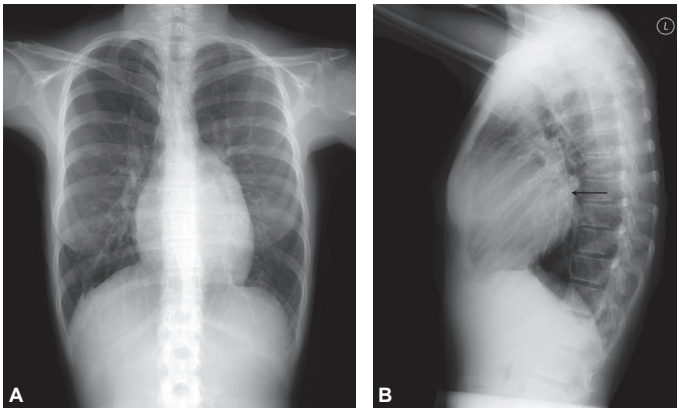

FIGURES 11A AND B: Left atrial enlargement. (A) PA and (B) lateral chest films showing classic cardiac silhouette of left atrial dilatation. On the PA film, there is bulging of the left cardiac border (third mogul). On the lateral film, note the conspicuous posterior displacement of the left atrial shadow (arrow). Also see Figure 25

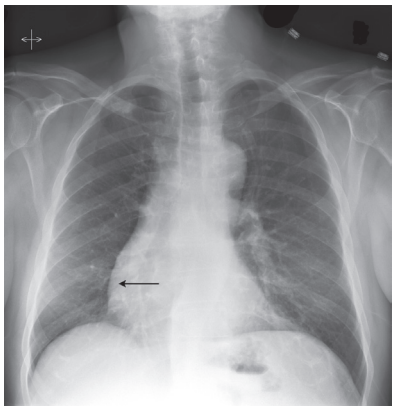

FIGURE 12: Right atrial enlargement. PA chest film showing lateral prominence of the right heart border (arrow) in patient with tricuspid insufficiency

progressive atrial enlargement the left atrial shadow may extend across midline to produce a second shadow overlapping upon the right atrium (double density sign) **(Figs 25A and B)**.

Soft tissue fullness in the subcarinal region which reflects enlarged atrial volume can occasionally produce uplifting of the left mainstem bronchus. On the lateral radiography, the posterior heart border will appear protruberant **(Fig. 25B)**.

Right Atrial Enlargement

Right atriual enlargement often goes relatively unnoticed, but will result in lateral displacement of the right cardiac border on the frontal radiograph **(Fig. 12)**. A sausage shaped density may become more evident as the atrial appendage enlarges.

RADIOGRAPHIC MANIFESTATIONS OF CONGESTIVE HEART FAILURE

Plain film radiography of the chest is an excellent modality to diagnose and measure the effectiveness of therapy in patients with congestive heart failure. In fact, it has been established that the characteristic stages of radiographic features of congestive heart failure on chest films correlate very well with hemodynamic measurements obtained with left atrial wedge pressures as determined with Swan Ganz catheterization.

The radiographic stages of congestive heart failure are well known, and relate to the physiologic changes and hemodynamic perturbations occurring along the capillary and venous regions of the pulmonary circulation. The physiologic factors that determine the quantity of extravascular fluid depend on several factors, namely intravascular hydrostatic pressure (promoting fluid escape from the intravascular space), plasma oncotic pressure and interstitial hydrostatic pressures (which acts to keep intravascular fluid within vessels), and interstitial oncotic forces (acting to pull fluid out of the intravascular spaces). Normally, these opposing forces result in a net positive fluid escape from the intravascular spaces into the interstitum, which is in turn returned to the central venous circulation via the lymphatics. In heart failure, as hydrostatic forces within the pulmonary arterial circulation increase, there are corresponding and predictable radiographic changes which reflect the increase of both increased pulmonary blood flow and eventual transudation of fluid out around the arterioles and capillaries into the perivascular interstitum and lymphatic spaces. The following discusses the characteristic radiographic manifestations of congestive heart failure as they correlate with capillary wedge pressures.

As was previously discussed, the normal pulmonary vascular pattern on upright chest radiographs exhibit the expected gravitational effects of increased blood flow to the lower lobes. Again, this can best be demonstrated by inverting the chest film upside down, which shows the conspicuous increase expected in the pulmonary vascular markings in the lower lobes compared to the upper lobes. It is also important to recognize that the pulmonary vessels should themselves be normally sharply defined throughout both lungs. Close inspection of the pulmonary arteries in the perihilar regions also reveal that the size of the pulmonary arteries closely approximate the caliber of the adjacent bronchus, both of which travel together in a common adventitial sheath. This relationship, known as the A:B ratio is essentially 1:1 **(Fig. 4)**. In the earliest stages of cardiac decompensation where there is only a modest increase in left atrial wedge pressures above normal (16–18 mm Hg),

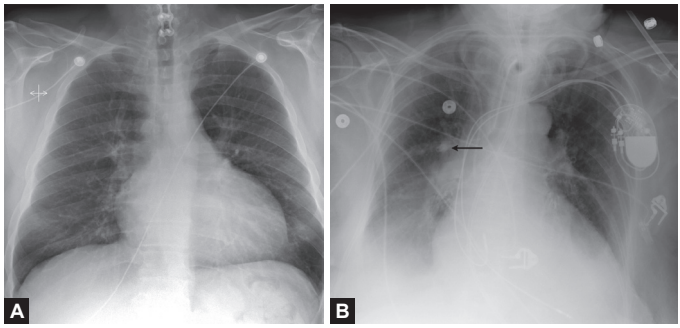

FIGURES 13A AND B: Cephalad redistribution of pulmonary blood flow in patient with mild left ventricular heart failure. (A) Note the increase in the size and conspicuity of the upper lobe vessels compared to normal. Also note the characteristic morphology of the heart reflecting left ventricular dilatation. (B) This figure shows the corresponding enlargement of the upper lobe arteries (arrow) with corresponding A:B ratio of 3:1. On both films, the vessel definition remains sharp

chest radiographs will demonstrate an increase in the size of the pulmonary vessels in the upper lobes reflecting shunting of blood flow to the upper lobes **(Fig. 13A)**. This recruitment phenomenon, known as cephalad redistribution, results in disruption of normal A:B ratio whereby the caliber of the vessel becomes larger than the adjacent bronchus **(Fig. 13B)**.

Despite this redistribution, the pulmonary vessels should remain sharply defined as should the associated bronchus. This recruitment of upper lobes vessels is felt to reflect a physiologic attempt to improve gas O_2–CO_2 exchange, i.e. oxygenation.

In the second stage of congestive heart failure, corresponding to wedge pressures around 18 mm Hg, there is enough intravascular hydrostatic force at the venule side of the capillary to increase or drive fluid out into the interstitial spaces surrounding the artery and bronchus. When this occurs, the increase in interstitial fluid essential creates a partial masking or silhouetting of the vessels which is known as vascular congestion **(Fig. 14)**.

Similarly, the increase in interstitial fluid surrounding to the airways produces a blurring of central perihilar vessels, and with time, a collar of haze may develop resulting in bronchial cuffing. Both of these observations collectively indicate an increase in interstitial fluid. It should be pointed out that in itself, peribronchial cuffing can also occur with bronchial inflammation, so if observed alone, peribronchial cuffing is not specific for early heart failure.

With further increases in vascular hydrostatic pressures, and as progressively more fluid accumulates in the interstium of the lungs, fine linear shadows develop which are known as Kerley lines **(Fig. 15)**. Radiographically, Kerley lines represent thickening (edema) of the intralobular septae that surround the secondary

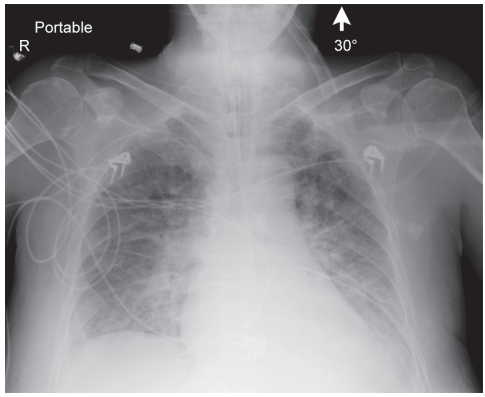

FIGURE 14: Pulmonary vascular congestion. AP radiograph of the chest showing indistinct margins of the pulmonary vasculature reflecting perivascular edema. Also note the fluid around the bronchi producing peribronchial cuffing

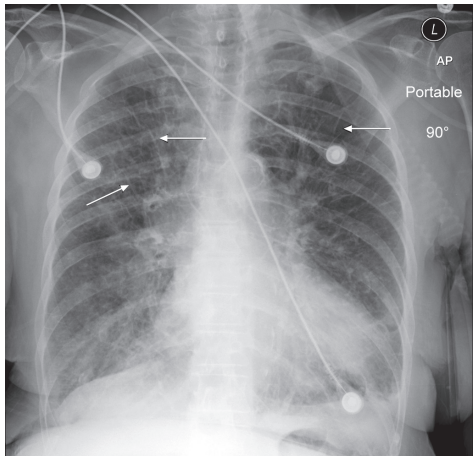

FIGURE 15: Interstitial edema. PA radiograph of patient in moderate congestive heart failure showing Kerley A (arrows) and parallel Kerley B lines in the lung bases reflecting interstitial edema

pulmonary lobule. Normally invisible on chest films, these septae histologically represent a part of the connective tissue supporting infrastructure of the lungs in which course the pulmonary veins and lymphatics. In congestive heart failure, the development of septal lines, which reflect both interstitial fluid and augmentation of lymphatic flow, become radiographically visible as either long linear shadows emanating out into the middle paracentral regions of both lungs (Kerley A lines) **(Fig. 15)** or as parallel shorter subpleural lines (Kerley B lines) running perpendicular to the pleural surface (usually in the midle and lower lung zones regions). Kerley C lines, which are believed to represent summation of Kerley B lines,

for detailed information on cardiology books, visit our website www.jaypeebrothers.com, for detailed information on car

Manual of CARDIAC DIAGNOSIS

Manual of Cardiac Diagnosis is an up to date and concise manual on cardiology. Three-dimensional echocardiography (3D ECHO), cardiac computed tomography, cardiovascular magnetic resonance, molecular imaging and intravascular coronary ultrasound (IVUS) have been discussed by the experts in their respective fields. The techniques and interpretation of transesophageal echocardiography (TEE) and stress echocardiography (Stress ECHO) have been discussed in details. SwanGanz catheters: Clinical applications, coronary angiography and catheter-based coronary intervention are other highlighting features of the book.



Kanu Chatterjee is currently Professor of Medicine, the Carver College of Medicine, University of Iowa and Emeritus Professor of Medicine, University of California, San Francisco, USA. He is an internationally recognized expert in heart failure and coronary artery disease. He has received numerous awards including "Gifted Teacher Award" of the American College of Cardiology; the Legacy Award, University of California San Francisco; Melvin Marcus Distinguished Fellowship Award, International Academy of Cardiology; Louis E Janssen Clinical Teaching Award, University of Iowa; Cardiovascular Distinguished Scientist Award, University of Iowa; and American Heart Association Professional Education Award. He is a Fellow of the Royal College of Physicians of London and of Edinburgh, American Heart Association, American College of Cardiology and a Master of the American College of Physicians. He is listed in the 'Best Doctors in America' and in 'America's Top Cardiologists'.



Mark Anderson is a Professor and Head of Internal Medicine, the Carver College of Medicine, University of Iowa, USA. He is an internationally recognized authority on cardiac arrhythmia and heart failure. Prior to becoming Head of Internal Medicine, Professor Anderson was the Director of Cardiovascular Medicine at the University of Iowa, in the Department of Internal Medicine where he held the Potter-Lambert Chair in Cardiovascular Medicine. Currently he is the François M Abboud Chair of Internal Medicine.



Donald Heistad is Zahn Professor of Cardiology and Professor of Internal Medicine and Pharmacology, the Carver College of Medicine, University of Iowa, USA and Deputy Director of the Cardiovascular Center. He has received several major research awards, including the Research Achievement Award of the American Heart Association; the Harry Goldblatt Award and Novartis Award from the Council for High Blood Pressure Research of the AHA; the Irving Sittright Award of the Stroke Council of the AHA; the Merck International Award of the International Society of Hypertension; Distinguished Alumni Award from the University of Chicago; the Carl J Wiggers Award of the American Physiological Society; and the Eugene M Landis Award of the Microcirculatory Society.



Richard E Kerber is Professor of Medicine and Emergency Medicine at the University of Iowa in Iowa City, Iowa, USA, and is Interim Director of the Cardiovascular Medicine Division. He has been a member of the Cardiovascular Division at the University of Iowa College of Medicine since 1975, and is Director of the University of Iowa Hospital's Echocardiography Laboratory. He is listed in the "Best Doctors in America" and "Who's Who in American Medicine". He has served two terms as Chairman of the American Heart Association's Emergency Cardiac Care Committee. He is a Past Chairman of the AHA's Cardiopulmonary and Critical Care Council, and also a Past President of the American Society of Echocardiography.

Shelving Recommendation
CARDIOLOGY

Available at all medical book stores
or buy directly from Jaypee Brothers through online shopping
at www.jaypeebrothers.com

JAYPEE BROTHERS
Medical Publishers (P) Ltd.
www.jaypeebrothers.com