ngology books, visit our website www.jaypeebrothers.com, for detailed information on otolaryngology books

SK Kaluskar

Diseases of the External Ear

(Including Step-by-Step Otoplasty)



Foreword

Mohan Kameswaran

Contents

1. Evolution of External Ear **1**

2. Embryology, Anatomy and Physiology **7**
- The Auricle *7*
- External Auditory Canal *9*
- The Tympanic Membrane (Eardrum) *10*

3. Congenital Anomalies of the Pinna **15**
- Otoplasty (Pinnaplasty) *15*
- History of Otoplasty (Pinnaplasty) *16*
- Surgical Technique of Otoplasty (Pinnaplasty) *19*
- Microtia *75*
- Preauricular Sinus *79*

4. Traumatic Conditions Affecting External Ear **101**

5. Inflammatory Conditions Affecting External Ear **112**
- Acute Inflammatory Conditions Affecting External Ear *112*
- Diseases of the External Auditory Canal *114*
- Inflammatory Diseases of the Ear Canal *118*
- Diseases of the Tympanic Membrane *121*

6. Neoplastic Lesions of the Pinna **171**

7. Miscellaneous Conditions of the Pinna **197**
- Malignant Otitis Externa (Necrotizing External Otitis) *211*

Index *225*

JAYPEE BROTHERS

CHAPTER

3

Congenital Anomalies of the Pinna

OTOPLASTY (PINNAPLASTY)

Introduction

The new technique in surgery brings with it the inherent risk of learning difficulties and sometimes complications. It takes a great deal of " learning curve" on the part of the surgeon to achieve expertise in the surgical field.

A plethora of books exists at the present time in the field of plastic surgery, which includes otoplasty. The standard textbooks usually describe various aspects of a particular deformity but lacks in the finer details in the field of operative steps and various tips and quips so as to help the surgeon to advance his/her skills to the patient in a given situation.

The author has been performing otoplasty surgery for the last three decades and as a result has learnt the various problems in correcting the deformity of the pinna.

JAYPEE BROTHERS

Being actively involved in the teaching surgical techniques to a "budding ENT" surgeon who have expressed many difficulties in dealing with the correction of this deformity. This in turn led to the author to produce a practical steps to the various techniques, so as to make the newly qualified surgeon more confident to deal with patient.

It is hoped that this chapter will give the novice a practical approach in dealing with the problem of deformity of the auricle in a step-by-step manner with relevant text description and profuse illustrations of intra-, peri- and post-operative photographs.

HISTORY OF OTOPLASTY (PINNAPLASTY)

Prominent ears or "bat ears" as commonly known, in a child is a common condition. These unnatural deformities of the auricle could be really distressing in children as this could lead to social phobias and behavioural disturbances. Many children refuse to go to school as they are constantly teased by fellow pupils.

Surgical treatment is well known for pinna for centuries. First available documentary evidence is from Sushrut Samhita a treatise written by Sushrut was regarded as "father of Surgery" who lived in ancient India (600 BC). He performed otoplasty for reconstructing ears, which were amputated as a punishment for crimes.

His procedure was based on techniques, which is still being practised today. A Kangra town in Northern India, is a

JAYPEE BROTHERS

place where operations on ears were performed in ancient India. ("Kan" mean ear).

No significant development occurred for centuries for pinna until in the middle of eighteenth century, Martino (1856) operated on two ears, performing wedge shaped excision. In 1881, Ely performed otoplasty introducing skin and cartilage excision. In 1886, Trendlenberg introduced excision of vertical and horizontal wedges. Following Ely and Trendlenberg, Roosa (1889), Keen (1890), Haugg (1894), Payr (1906) suggested modifications to their techniques.

Following first world war, a considerable development occurred in plastic surgery, which led to the revival of Sushruta's original techniques in reconstruction of the pinna. Few developed their new techniques while some contributed by suggesting changes in existing techniques. These facts suggest that no one technique is perfect and depending upon the degree of deformity , a "tailor made " approach is to be adopted.

During period of 1896–1911, Jack Joseph of Berlin, performed series of otoplasty, introducing excision of two wedges, vertical to edges of first wedge.

In 19th century, Luckett (1910) introduced a new technique, which was further modified by Converse (1955) and Erich (1958). They used two parallel incisions and a strip of cartilage to create a prominent antihelix. Edges of the cartilage were blunted and approximated by permanent sutures. These surgeons also recommended use of dye to mark the incision precisely.

JAYPEE BROTHERS

In spite of many techniques described, there were shortcomings in the ultimate results. They produced sharp edges on new antihelical fold and reduced dimensions of the ear anteroposteriorly. To improve these shortcomings, various modifications were used. Different surgeons used burrs, wire brushes, multiple parallel cuts or more recently diamond coated file to thin out the cartilage which was then folded to create antihelix.

In 1963, Mustarde described a technique, which was much simpler than other techniques. He folded the ear to make the prominent antihelical fold and marked the sites of mattress sutures with needle. Cartilage was tattooed with dye, following the excision of one centimetre strips of skin on posterior surface. He tightened the mattress sutures on cartilage. Skin was closed with continuous suture.

In 1968, Furnas introduced technique to reduce conchal bowl. He took away small part of conchal cartilage, which allowed the close approximation of proximal portion of auricle to mastoid process using conchomastoid sutures.

In 1969, Webster introduced technique, which included combination of skin excision, conchal resection, and cartilage scoring and mattress sutures to get more natural appearance.

Pitanguy technique (1982) further reduced the dimension of the cartilage flap and introduced conchal setback sutures.

Farrior (1985) further developed a technique by allowing gradual widening of the strip of cartilage. This modification gave gentler bend to antihelix.

JAYPEE BROTHERS

Most surgeons prefer principally relying on excision of some part of the cartilage depending upon the deformity and the suture technique.

SURGICAL TECHNIQUE OF OTOPLASTY (PINNAPLASTY)

Operation in children is performed under general anesthesia whereas adults can be operated under local anesthesia.

The patient is positioned in a supine position with the ear to be operated draped to expose the entire external ear. The ear is cleansed with the suitable antiseptic and normal saline and piece of wool is inserted in the external auditory meatus to prevent the blood trickling down into the ear canal.

Depending upon the severity of the absence of antihelix, the curvature of the antihelix to be desired is marked out with insertion of small needles stained with methylene blue or gentian violet through the skin.

An incision is marked out with the marker on the posterior aspect of the pinna making sure that the incision in the middle part is slightly narrow than in its upper and lower part. This is to ensure that when the skin wound is healed with fibrosis, it does not result in an uneven scar.

Infiltration of the skin at the previously marked site of incision is performed with a dental syringe containing 1% lignocaine with 1: 80,000 adrenaline. The incision is now placed excising the area of the skin and exposing the underlying cartilage with perichondrium. The hemostasis

JAYPEE BROTHERS

is achieved with the help of bipolar diathermy. The earlier marked points of the gentian violet is now identified and an incision is made on to the perichondrium, which is then elevated with a freer elevator. A small strip of cartilage is excised or alternatively a diamond paste burr is used to weaken the cartilage around the previously made gentian violet markings taking care not to damage the other side of the skin of the pinna.

Special care must be taken at the lower end of the cartilage around the tragus which may need to be excised in a situation where it shows a deep "hollow".

The incision is now sutured in three layers, the first being through the edges of the perichondrium, the second through the subcutaneous tissue and finally through the skin. The first two sutures are non-absorbable 4/0 silk on a cutting needle and the skin suturing being performed with the 4/0 absorbable rapid suture.

It is important that the sutures are *not tightened one at a time but are left until all sutures are in place beginning from Perichondrium to the skin and then tightened keeping a constant watch on the emerging shape of the antihelix.*

The ear is dressed now with the wool soaked in glycerine acriflavin molded to the shape of the pinna and a bandage is applied for one week. The bandage is then removed, the wound inspected and light bandage is applied for further two weeks. Routine antibiotics are not used unless there is a suspicion of wound being infected which is extremely rare.

JAYPEE BROTHERS

"Bat Ears"

Prominent Ears (Bat Ears)

The basic problem in bat ears is the absence of antihelix fold and sometimes very deep concha. It may be unilateral but is usually bilateral. Children are the most common patients as they are constantly teased by fellow pupils, at times very cruelly to the extent that the child refuses to go to school.

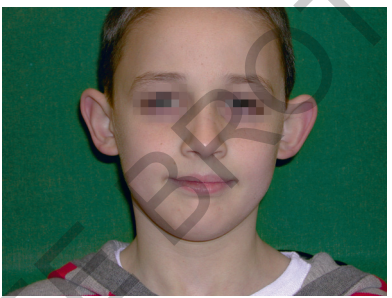

A six year boy with bilateral prominent ears due to absence of antihelix more pronounced on the left that the right side

JAYPEE BROTHERS

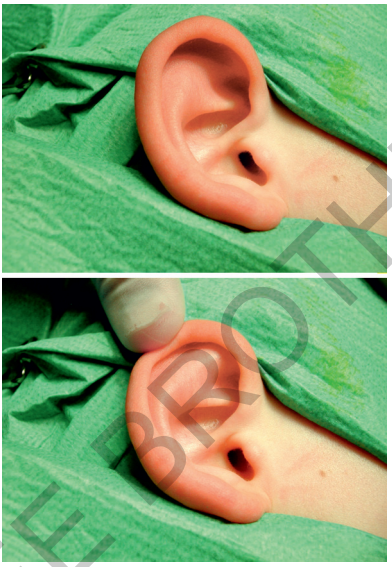

Right ear protrusion as seen on lateral view and proposed reconstruction of the antihelix

JAYPEE BROTHERS



Fine needles dipped in gentian violet 'or' methylene blue marking the proposed site of new antihelix

JAYPEE BROTHERS



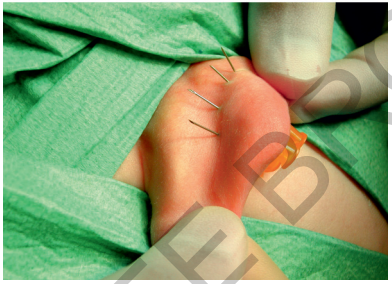

Fine needles dipped in gentian violet are placed through the skin in the line of the new proposed antihelix

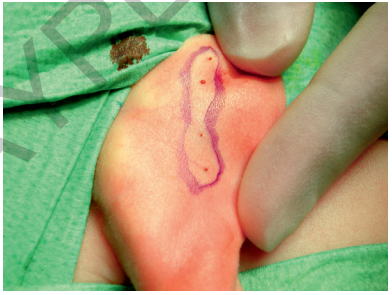

An elliptical incision is marked on the posterior aspect of the right pinna around new antihelix. Note excision of the skin is slightly narrow in the mid-portion of the incision. This is to achieve a minimal scar contracture at a later date when the healing of the wound is complete

JAYPEE BROTHERS

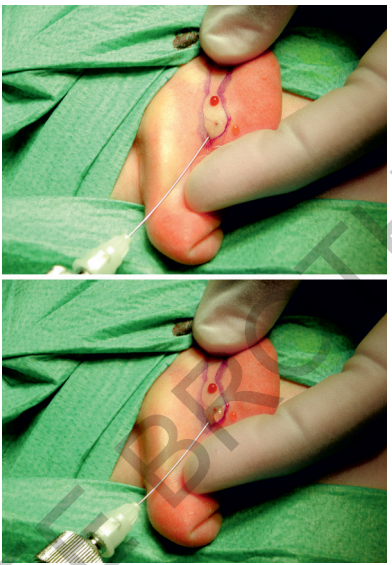

Injection of 1 % lignocaine with 1:80,000 adrenaline is made at the site of incision

JAYPEE BROTHERS

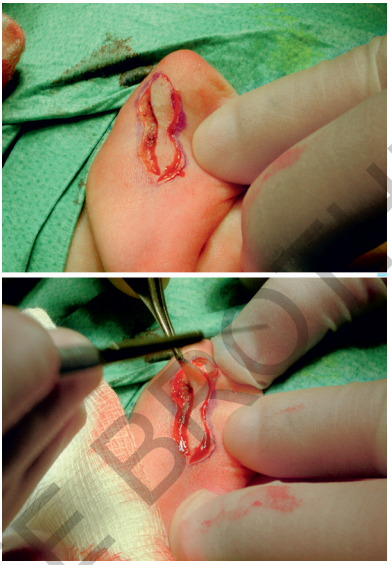

An elliptical piece of skin is excised meticulously to expose the underlying perichondrium and cartilage

JAYPEE BROTHERS

r detailed information on otolaryngology books, visit our website www.jaypeebrothers.com, for detailed inform

Diseases of the External Ear

Salient Features

- Diseases of the external ear are a day-to-day occurrence in any ENT surgeon's clinical practice
- The author has written this book from his vast clinical and operative experience over the last four decades in ENT surgery
- This book presents a large variety of pathologies affecting external ear in great detail in a concise, clear and easy-to-understand text along with superb preoperative, intraoperative, and postoperative photographs
- It consists of total 7 chapters starting from the evolution of the external ear, followed by embryology, anatomy and physiology, and wide range of pathologies from trauma, inflammatory, neoplastic conditions to certain interesting miscellaneous lesions affecting external ear
- The surgical details are laid out in a step-by-step configuration for a novice surgeon
- Special attention has been drawn to the details of the techniques for the common problem of bat ears both in children and adults.



SK Kaluskar MS (ENT) FRCS DLO (Eng) is an Emeritus ENT and Head & Neck Surgeon at the Tyrone County Hospital, Omagh, Northern Ireland, UK. He is a guest faculty in various national and international courses and continuing medical education programs and workshops. He is a recipient of several prestigious orations and awards from various universities and medical colleges. He was a postgraduate trainer for the Royal College of Surgeons and the Queen's University, Belfast, UK.

He has numerous publications in many national and international journals. He is an author of several books, such as *Clinical Atlas of Ear, Nose and Throat Diseases; Endoscopic Sinus Surgery—A Practical Approach; Complications in Endoscopic Sinus Surgery—Prevention, Diagnosis and Management*, and *Easy Guide to Ear, Nose and Throat Diseases*. He has contributed chapters in textbooks. He has produced a large number of educational videos and CDs.

Shelving
Recommendation
OTOLARYNGOLOGY

ISBN 978-93-5152-236-2

9 789351 522362

Available at all medical book stores
or buy directly from Jaypee Brothers through online shopping
at www.jaypeebrothers.com

JAYPEE BROTHERS
Medical Publishers (P) Ltd.
www.jaypeebrothers.com

Join us on facebook.com/jaypeebrothers