ebsite www.jaypeebrothers.com, for detailed information on surgery books, visit our website www.jaypeebrothers.com

JAYPEE

KIDNEY & PANCREAS TRANSPLANTATION











MOLMENTI

3 CHAPTER Respiratory System

ANATOMY AND PHYSIOLOGY OF RESPIRATORY SYSTEM

Thorax (Fig. 3.1)

It is superior part of the trunk between neck and abdomen.

Thoracic cavity contains heart and great vessels, lungs, thymus, distal part of trachea and most of the esophagus.

Thoracic cavity is bounded:

- Anteriorly by sternum and ribs
- Laterally by ribs
- Posteriorly by ribs and vertebrae
- Inferiorly by diaphragm and ribs margins
- Superiorly by clavicles and soft tissues of the neck.

Thoracic wall consists of:

- Skin
- Fascia
- Muscles
- Nerves
- Vessels
- Bones.

Functions of Thoracic Wall

- Protections of thoracic and abdominal organs
- Resists intrathoracic pressure generated by elastic recoil of lungs and respiratory movements
- Provides attachment for supporting the weight of the upper limbs
- Provides attachment for many of the muscles of upper limbs, neck, abdomen, back and muscles of the respiration.

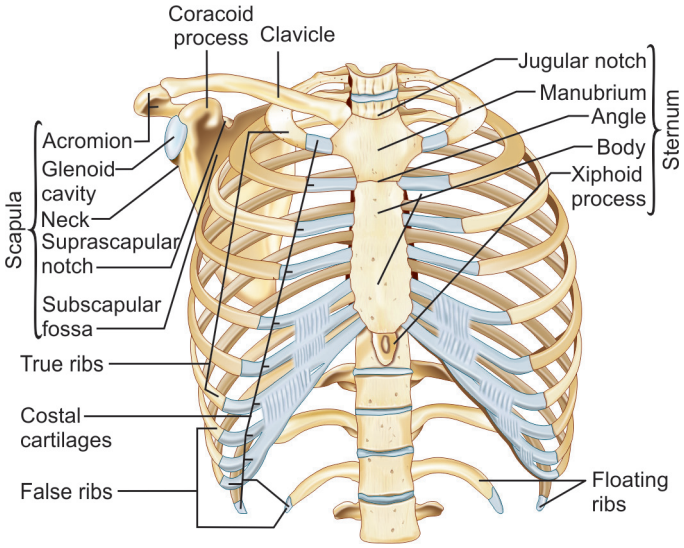

FIG. 3.1 Thoracic cavity

Thoracic Aperture

Thoracic cavity communicates with neck and upper limb through superior thoracic aperture called thoracic inlet.

- Structures entering and leaving the inlet are trachea, esophagus, nerves, and vessels
- Its anteroposterior diameter is 6.5 cm and transverse diameter is 11 cm
- It slopes anteriorly downwards.

Thoracic cavity communicates with abdomen through inferior thoracic aperture called thoracic outlet.

- Thoracic outlet is being separated from abdomen completely by the diaphragm
- The structures pass out and enter into thoracic cavity through the thoracic outlet by perforating the diaphragm.

Surface Anatomy of the Thoracic Wall (Figs 3.2A to C)

Several imaginary lines on the thoracic wall:

- *Anterior midsternal line:* It indicates the intersection of the medial plane with anterior chest wall
- *Midclavicular line:* This line passes through the midpoints of clavicle parallel to anterior midsternal line
- *Anterior axillary line:* This line passes along the anterior axillary fold, formed by border of the pectoralis major muscle.

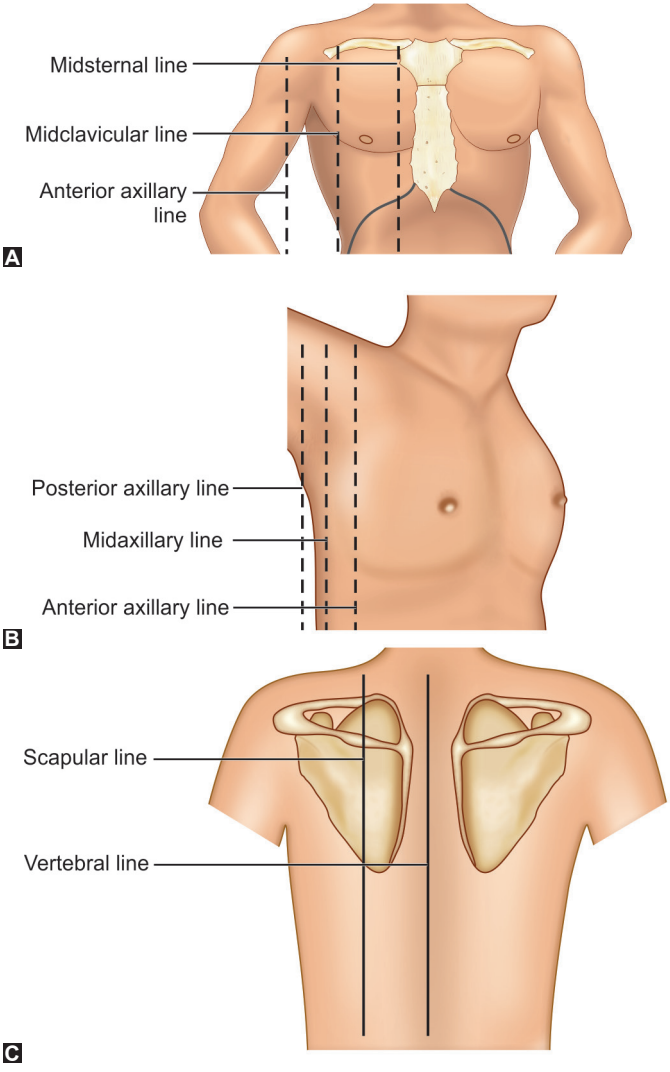

FIGS 3.2A TO C Surface anatomy of thoracic wall

- *Midaxillary line:* This line passes along the posterior axillary fold, formed by latissimus dorsi and teres major muscles, as they span back to humerus
- *Posterior median line:* It is a vertical line at the intersection of median plane with vertebral column
- *Scapular line:* It is parallel to posterior median line and cross the inferior angle of the scapula.

Bones of the Thorax: Sternum (Fig. 3.3)

- *Three parts are:*
  i. Manubrium
  ii. Gladiolus
  iii. Xiphoid.

  Manubrium is joined with gladiolus by fibrocartilage, mobility of this joint is slight.

  Gladiolus is joined with xiphoid cartilage may be calcified at later life.
- *Shape:* Looking like ancient Greek sword—manubrium is the handle, gladiolus is the blade, xiphoid cartilage is the tip
- *Shape of the xiphoid cartilage:* Lance-shaped or bifid, angulates forward.

Ribs (Fig. 3.4)

- It is flattened bone
- Its vertebral end has head, neck and double tubercle
- Its sternal end has costal cartilage
- Its head produces bipartite arthrodial (gliding) joint with two adjacent vertebral bodies and adjacent intervertebral disc
- Its neck tubercle produces arthrodial joint with transverse process of upper vertebra

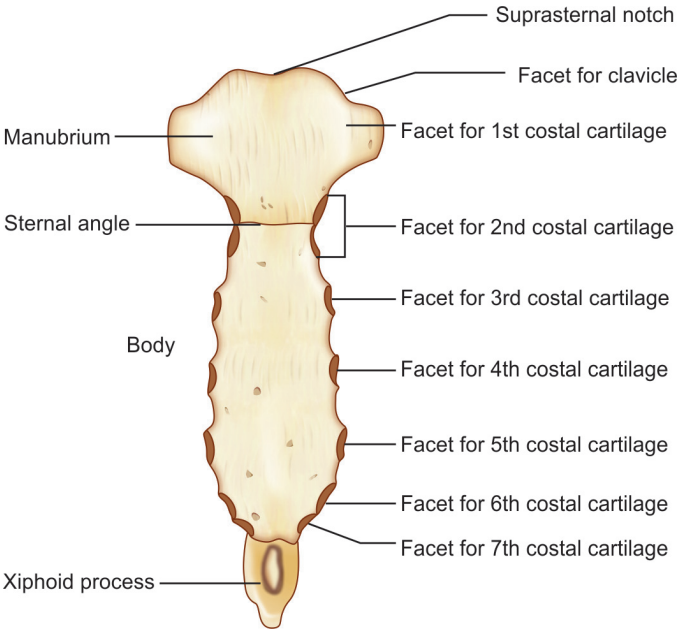

FIG. 3.3 Sternum

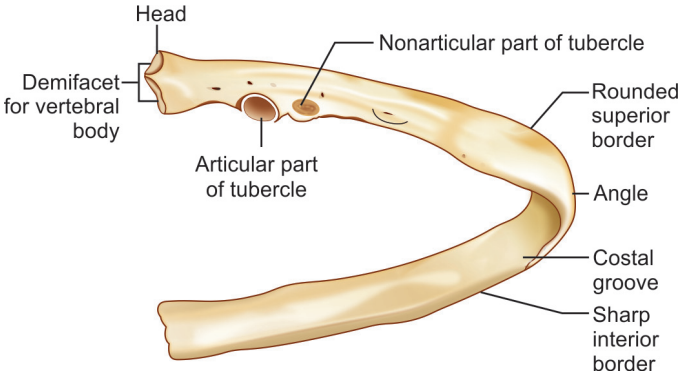

FIG. 3.4 Rib

- Sternal edges of first to seventh ribs join with sternum—they are true vertebrosternal joints
- 8th to 10th ribs are vertebrochondral; their sternal ends join with costal cartilage of the above adjacent ribs
- 11th and 12th ribs, because their anterior edge is free
- Joint of sternal edge of 1st rib with sternum is synarthrodial, because it is fixed. Other joints (2nd to 7th ribs) are arthrodial, these are mobile
- 2nd rib at its sternal edge joins with interface of manubrium and gladiolus—fibrocartilage.

Importance of Sternal Angle

- 2nd pair of ribs attach here with costal cartilage. So ribs can be counted from here, since 1st rib is deep to the clavicle, so cannot be counted
- Trachea bifurcates here
- It demarcates the division between superior and inferior mediastinum
- It denotes the beginning of the arch of aorta.

Infrasternal angle: It is formed by converging costal margins. This angle is used for cardiopulmonary resuscitation for proper position of the hand on the inferior part of the body of sternum.

Muscles of thoracic wall helpful for respiration

- *Intercostals:* Internal intercostals and external intercostals, transversus thoraces (continuous with tranversus abdominis), subcostal, levator costarum, serratus posterior muscles are the muscles of the thoracic wall
- Pectoralis major and pectoralis minor, inferior part of serratus anterior—act as accessory muscles of respiration—expands the thoracic cavity during forceful respiration

- The scalene muscles of respiration—fix these ribs and help the muscles connected below to be more effective in elevating lower ribs during forceful inspiration.

Respiratory passage: It consists of:

- Nose
- Nasopharynx
- Mouth
- Oropharynx
- Larynx
- Trachea
- Bronchial tree supplying the alveoli.

Description of Bronchial Tree (Fig. 3.5)

- Trachea bifurcates at the level of manubrium sterni by a dividing septum called carina
- Right bronchus is more vertical than left bronchus—hence more vulnerable to lodge the foreign body
- Right bronchus divides into three lobar bronchi, supplying three lobes of the lung:
  1. Upper lobe
  2. Middle lobe
  3. Lower lobe.
- Left bronchus divides into two lobar bronchi, upper lobe and lower lobe

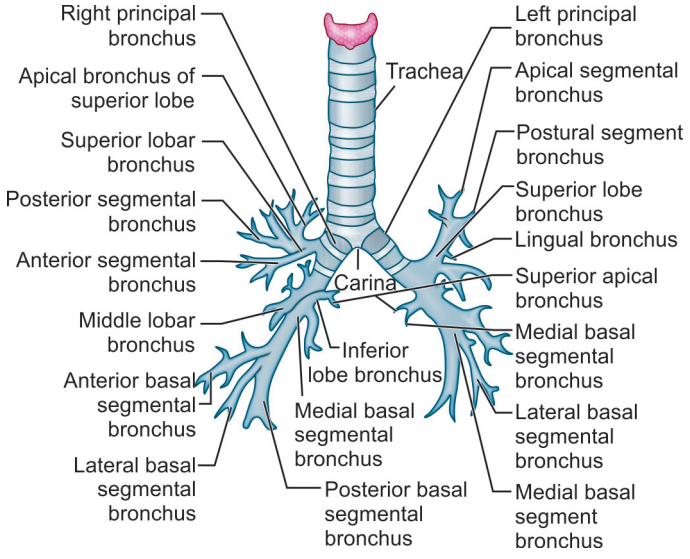

FIG. 3.5 Bronchopulmonary segment

- Each main bronchus is divided into segmental bronchi supplying the respectable bronchopulmonary segments
- The segment is pyramidal in shape with its apex towards the root and base towards the pleura. These segments are:
  - *Right upper lobe bronchus:*
    - Right upper lobe apical
    - Right upper lobe anterior
    - Right upper lobe posterior.
  - *Right middle lobe bronchus:*
    - Right middle lobe medial
    - Right middle lobe lateral.
  - *Right lower lobe bronchus:*
    - Right lower lobe anterior basal
    - Right lower lobe posterior basal
    - Right lower lobe lateral basal
    - Right lower lobe superior.
  - *Left upper lobe bronchus:*
    - Left upper lobe apical
    - Left upper lobe anterior
    - Left upper lobe posterior
    - Left upper lobe superior
    - Left upper lobe inferior.
  - *Left lower lobe bronchus:*
    - Left lower lobe anterior basal
    - Left lower lobe posterior basal
    - Left lower lobe lateral basal
    - Left lower lobe medial basal
    - Left lower lobe superior.
- Aorta arches over the left bronchus from front to back
- Left recurrent laryngeal nerve descents in front of the aortic arch, hooks under it and ascends besides the trachea to the neck. Dilated aorta may compress the left recurrent laryngeal nerve against left main bronchus
- Each segmental bronchus ends into 6 to 10 terminal bronchioles
- Each terminal bronchiole gives rise to several generations (5 to 10) respiratory bronchioles
- Each respiratory bronchiole gives rise to 2 to 11 alveolar ducts
- Each alveolar duct gives rise to 8 to 10 alveolar sacs—this is the basic structural unit of gas exchange.

Lungs (Figs 3.6A and B)

It is tough, elastic, spongy, light in weight and crepitant (Figs 3.6A and B).

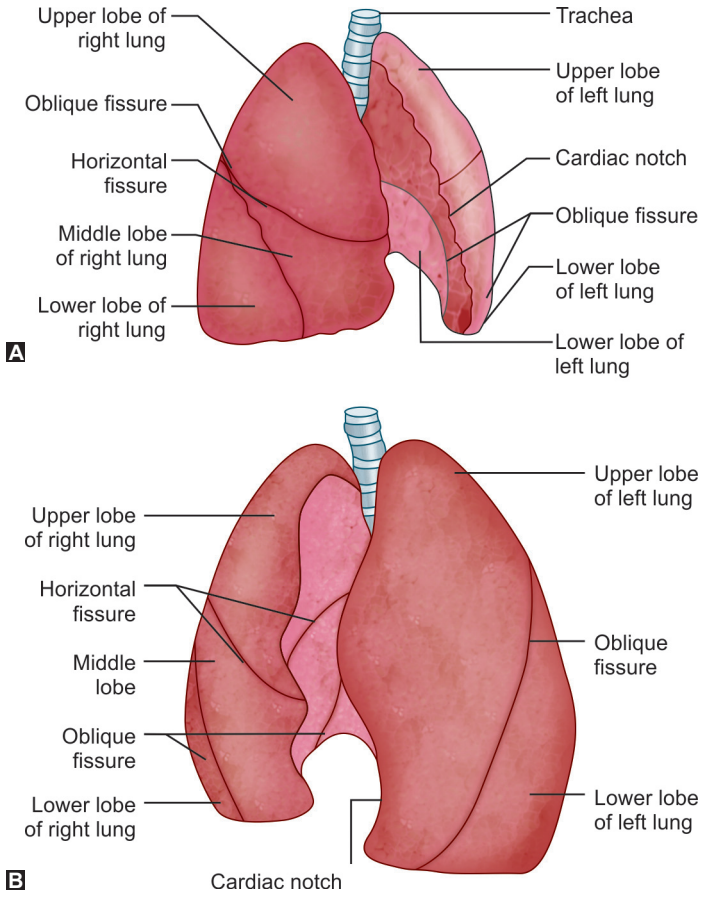

FIGS 3.6A AND B (A) Lungs viewed from right; (B) Lungs viewed from left

Right lung is divided into three lobes:

1. Upper lobe
2. Middle lobe
3. Lower lobe.

Left lung is divided into two lobes:

1. Upper lobe
2. Lower lobe.

Each lobe is separated from the other of the same lung by lobar fissure—infolding of the visceral pleura.

Shape of both the lungs are similar, but medial edge of left lung has an inferior indentation—cardiac notch.

Pleura (Fig. 3.7)

Lungs are enclosed by serous pleural sac—consist of two continuous membranes:

1. *Visceral pleura:* It covers and adheres to lung surfaces including the surfaces of the fissures—horizontal and oblique. This pleura cannot be peeled out from the lung surface.
2. *Parietal pleura:* It consists of four parts:
   - *i. Costal pleura:* Covers the internal surface of thoracic wall
   - *ii. Mediastinal pleura:* It covers the lateral wall of the mediastinum
   - *iii. Diaphragmatic pleura:* It covers the thoracic surface of the diaphragm
   - *iv. Cervical pleura:* It extends through the superior thoracic aperture into root of the neck, 2 to 3 cm superior to the level of medial third of clavicle at the level of the neck of the 1st rib.

Two potential recesses:

1. *Costodiaphragmatic recess:* Pleural-lined gutters surrounding convexity of diaphragm including the thoracic wall
2. Smaller pleural recesses are located posterior to the sternum where the costal pleura are in contact with mediastinal pleura—costomediastinal recess.

Functions of the Pleural Fluid

- Lubricates the layers, allow to glide smoothly over each other during respiration

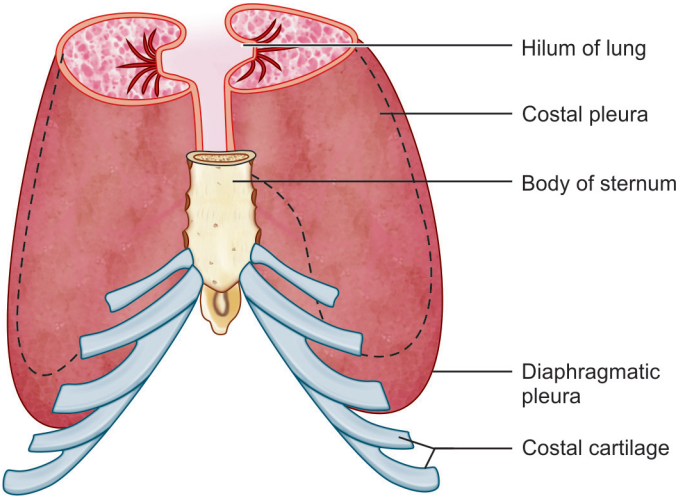

FIG. 3.7 Pleura

- Its surface tension so that the lungs fill with air, when thorax expands.

Root of the lung
The root of the lung is formed by the structures entering into and emerging from the lung, consists of:
- Pulmonary artery
- Superior and inferior pulmonary vein
- Bronchus.

Mediastinum

It occupies center of thorax, bounded laterally by mediastinal pleura and contains all thoracic viscera and structures except the lungs.

It extends from superior thoracic inlet to the diaphragm below, anteriorly sternum and costal cartilage to posteriorly thoracic vertebrae.

It is arbitrarily divided by an imaginary plane extending anteriorly from the sternal angle to 4th intervertebral disc posteriorly into:
- *Superior mediastinum:* It contains:
  - Superior vena cava
  - Brachiocephalic vein
  - Arch of aorta
  - Thoracic duct
  - Trachea
  - Esophagus
  - Thymus
  - Vagus nerve
  - Left recurrent laryngeal nerve
  - Phrenic nerve.
- *Inferior mediastinum* is subdivided by pericardium into:
  - *Anterior mediastinum:*
    - Remnant of thymus
    - Lymph nodes
    - Fat
    - Connective tissue.
  - *Middle mediastinum:*
    - Pericardium
    - Heart
    - Root of great vessels
    - Arch of azygos vein
    - Main bronchi.
  - *Posterior mediastinum:*
    - Azygos and hemiazygos veins
    - Esophagus
    - Thoracic aorta

- Vagus nerve
- Sympathetic trunk
- Splenic nerves.

Ventilation and Lung Mechanics

- Ventilation is defined as exchange of air between atmosphere and alveoli
- Flow of air is directly proportional to difference between atmospheric pressure and alveolar pressure, and inversely proportional to resistance to airflow, i.e.
- *Flow of air (F)*/(P_{atmos} – P_{alv})/Resistance (R)
- Atmospheric pressure is 760 mm Hg at sea level
- Alveolar pressure is less than atmospheric pressure during inspiration
- Alveolar pressure is higher than atmospheric pressure during expiration.

Pleural pressure is also important.

1. Alveolar pressure—intrapleural fluid pressure (transpulmonary pressure) is the determinant of lung size.
2. Atmospheric pressure—alveolar pressure is the determinant of airflow.

During Inspiration

Diaphragm and inspiratory intercostals muscles contract
↓
Thorax expands
↓
Intrapleural pressure more subatmospheric
↓
Increased transpulmonary pressure
↓
Lung expands
↓
Alveolar pressure becomes subatmospheric
↓
Airflow into alveoli.

During Expiration

Diaphragm and intercostals muscles stop contracting
↓
Chest wall recoil inward
↓
Intrapleural pressure back towards the preinspiration value
↓

Transpulmonary pressure back towards preinspiration value

↓

Lung will recoil to preinspiration size

↓

Alveolar pressure becomes more than the atmospheric pressure

↓

Airflow out of the lungs.

Lung Volumes (Figs 3.8A and B)

- *Tidal volume:* During quiet breathing, the volume entering the lungs during inspiration is approximately equal to the volume of air leaving during expiration (450 mL)
- *Inspiratory reserve volume:* The maximal amount of air that can be inhaled above tidal volume during deep inspiration (amount – 3000 mL)
- *Expiratory reserve volume:* Maximal amount of air that can be exhaled during forced expiration after normal inspiration (amount – 1500 mL)
- *Residual volume:* Amount of air that is present after forceful expiration (amount – 1000 mL)
- *Functional residual capacity:* Expiratory reserve volume + Residual volume
- *Inspiratory capacity:* Tidal volume + Inspiratory reserve volume
- *Vital capacity:* Tidal volume + Inspiratory reserve volume + Expiratory reserve volume
- *Total lung capacity:* Tidal volume + Inspiratory reserve volume + Expiratory reserve volume + Residual volume.
  or
  Vital capacity + Residual volume.
  or
  Inspiratory capacity + Functional residual capacity.
- *Dead space air:* The amount of air present in the airways after full expiration (amount – 150 mL).
  So, fresh air entering the alveoli in one inspiration:
  450 – 150 mL = 300 mL.

Mechanism of Breathing

- *Muscles of respiration:*
  - Inspiration
  - Expiration.
- Elastic properties of the lung
- Elastic properties of the chest wall
- Airway resistance
- Tissue resistance.

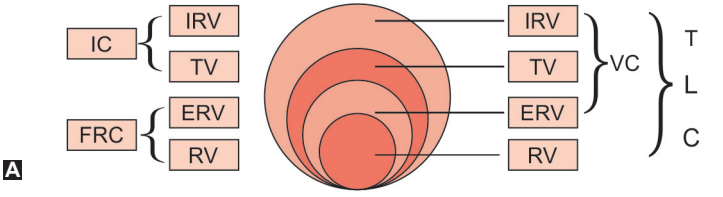

A

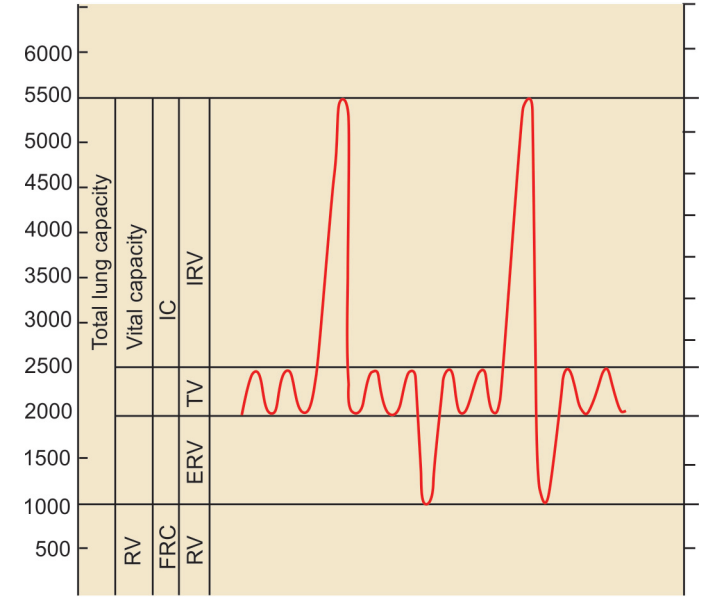

B

Pulmonary function test

FIGS 3.8A AND B Lung volume

- *Work of breathing:*
  - Work of breathing of lung
  - Total work of breathing.

Respiratory Expansion of Thorax

Anteroposterior Expansion of Thorax

- 1st rib and sternum are fixed by scalene muscles
- Contraction of external and internal intercostals muscles narrows the intercostals spaces at the costovertebral joints about an axis passing through neck of the ribs
- Ribs are pulled upwards and forward like pump handle

Contents

1. Art of Interviewing to a Patient **1**

Communication means good and successful interview 1; Approach to a patient for physical examination 20

2. Physical Examinations **27**

Temperature 27; Anthropometry 37; Posture 50; Apparent Age 50; Facies 51; Lymphn node 58; Clubbing 77; Cyanosis 84; Anemia 97; Nail 99; Hair 112; Edema 120; Neck vein 129; A wave 135

3. Respiratory System **146**

Anatomy and physiology of respiratory system 146; Thorax 146; Lungs 152; Ventilation and lung mechanics 156; Physiology of pleural fluid absorption and reabsorption 166; Vascular system 167; Symptoms of respiratory diseases 171; Cough 171; Sputum 175; Hemoptysis 176; Chest Pain 178; Breathlessness 181; Wheeze 188; Hoarseness 189; Other important points in history 190; Past history 192; Social history 192; Occupational history 193; Family history 194; Drug history 194; Personal history 194; Chest inspection 195; Abnormalities in respiration 195; Abnormalities in posture 198; Abnormalities in respiratory musculature 200; Asymmetry in thoracic expansions 201; Abnormalities of the sternum 204; Abnormality of the ribs 206; Abnormalities of chest surfaces 208; Palpation 211; Assessment of expansion of hemithoraces 216; Chest percussion 222; Auscultation 229; Pleural rub 250; Transmitted voice sounds 251

4. Cardiovascular System **255**

Anatomy of cardiovascular system 255; Gross anatomy 255; Symptoms related to cardiovascular systems 286; Chest pain 286; Palpitation 296; Syncope 302; Claudication 318; Breathlessness 320; Hemoptysis 327; Cardiovascular system examinations 330; Body appearance and facies 330; Arterial pulse 347; Precordial movement of impulse 381; Apical area of chest 381; Heart sounds 385; Inspection 386

5. Gastroenterology and Urinary System **467**

Anatomy and physiology of gastrointestinal and urinary systems 467; Mouth and oral cavity 468; Stomach 476; Phase of gastric secretion 481; Small intestine 485; Large intestine 491; Spleen 495; Liver 496; Gallbladder 499; Pancreas 503; Kidney—anatomy and physiology 508; Basic structure of nephron 513; Symptoms and physical examination 525; Abdominal pain 528; Vomiting 534; Diarrhea 550; Constipation 553; Jaundice 566; Physical examinations 582; Umbilicus 616; Palpations 621; Stomach 641; Pancreas 643; Kidneys 644; Urinary bladder 646; Palpation of aorta 647; Ascites 648; Hernia 656; Rectum and anal canal 659; Prostate gland 660

6. Eye Disease **668**

Eye 668; Orbit 668; Structures of eye 671; Symptoms of eye disease 683; Presenting problems 683; Discharge 685; involvement of one or both eyes 685; History of photophobia 685; Disturbance in vision 685; Drug 688

7. Nose **734**

External nose 734; Saddle nose 735; Structures of internal nose 736

8. Oral Cavity and Pharynx **741**

Pharynx 741; Cleft palate 741; Uvula 741; Scarlatina (Scarlet fever) 744; Vincent's angina 746; Oral mucosa 747; Tongue 755; Anatomy of the tongue 755; Tongue Abnormalities 755; Lips 765; Cheilosis 765; Cheilitis 765; Angioedema 765; Pigmented areas of lip 767; Gum and teeth 768; Parulia 768; Epulis fissuratum 768; Causes of thickening of gum 768; Scurvy 768; Causes of tooth loss 769; Blue line in the gum 770; Hutchinson's teeth 771; Halitosis 771

9. Ear **772**

Examination of ears 772; Components of ear 772

10. Skin **781**

Anatomy 781; Appendages of skin 783; Color of skin 783; Functions of the skin 783; Diagnosis of skin disease 784

11. Neurology **860**

Anatomy of nervous system 860; Diencephalon 860; Hypothalamus 862; Cerebral hemisphere 865; Basal ganglia 870; Arterial supply 872; History taking and symptoms 879; Neurological examination 879; Gait 891; Dizziness and vertigo 906; Physical examination 914; General examination 914; Outline of neurological clinical examination 921; Language 939; Aphasia 941; Cranial nerves 957; Functional components of

cranial nerves 957; Olfactory cranial nerve 960; Optic nerve 965; Fifth cranial nerve 995; Facial nerve 1017; Eighth cranial nerve 1037; Ninth cranial nerves 1058; Tenth cranial nerve (vagus nerve) 1063; Eleventh cranial nerve (spinal accessory nerve) 1070; Hypoglossal nerve (XII cranial nerve) 1077; Convergenic—accommodation reflex pathway 1101; Motor system 1103; Involuntary movement 1103; Opisthotonos 1106; Chorea 1107; Athetosis 1108; Hemiballismus 1109; Idiopathic generalized torsion dystonia 1109; Truncal athetoid movements 1110; Involuntary movements of face and neck 1110; Muscle tone 1122; Muscle power 1130; Muscles of head and neck 1131; Muscles of lower leg and ankle 1156; Motor power and strength 1162; Posture and stance 1167; Deep tendon reflexes 1172; Clonus 1196; Associated movement 1199; Symmetric associated movements (mirror movement) 1200; Cerebellar function 1201; Autonomic nervous system 1211; Sensory system 1220; Cerebral sensory system 1234; Sensory localization 1238; High level of bladder control 1239; Nystagmus 1241; Oscillopsia 1241; Opticokinetic drum 1241; Normal nystagmus 1241; Types of nystagmus 1244; Examination of patient in coma 1251; Lowering of consciousness 1251; Mode of onset of unconsciousness 1252; Miscellaneous neurological signs 1268; Signs of meningeal irritation 1268; Nuchal rigidity 1268; Cervical radiculopathy 1272

12. Thyroid Gland **1281**

Relation of thyroid lobe to the other neck structure 1281

13. Musculoskeletal System **1296**

Bone 1296; Cartilage 1298; Joints 1299; Ligaments 1305; Muscles 1308; Symptoms related to bone pain 1309; Symptoms related to joint pain 1310; Symptoms related to muscles pain 1311; Hip joint 1359; Knee joints 1368; Ankle joint 1382

14. Genitalia **1397**

Male genitalia 1397; Female genitalia 1399; Genital symptoms for male 1402; Genital symptoms for female 1421; Signs 1426

Index *1437*

for detailed information on surgery books, visit our website www.jaypeebrothers.com, for detailed information on surge

KIDNEY & PANCREAS TRANSPLANTATION

- The most comprehensive illustrated book published on the topic of Kidney and Pancreas Transplantation.
- Text covers the entire gamut of considerations for Kidney and Pancreas Transplantation, from evaluation to follow-up.
- Presents practical and focused information in a concise format for easy consultation and rapid reading.
- Multidisciplinary, featuring contributions from all involved specialties.
- Unique topics include pancreatic islet cell transplantation, epigenetics, imaging, complications, pathology, dermatologic manifestations, quality management, immunology, pharmacology, vaccinations, obesity and metabolic syndromes, and robotic surgical techniques.
- Seventy two chapters richly illustrated with full color illustrations.

Kidney and Pancreas Transplantation, offering practical guidance and information, will fulfill the needs of a diverse audience of physicians.

Contents

1. Kidney Transplantation
Overview
Recipient Evaluation
Pre- and Post-Transplant Medical Considerations
Donor Evaluation
Immunology
Pharmacology
Anesthesia
Operative Techniques
- Donor
- Recipient

Post-Transplant Considerations
Quality Management
Basic Science
Pediatric Kidney Transplantation
Pathology
Radiology
- Pre-Transplant
- Post-Transplant

Cutaneous Manifestations

2. Pancreas Transplantation
Overview
Operative Technique
Complications
Pathology
Radiology

3. Islet Cell Transplantation

Available at all medical bookstores
or buy directly from Jaypee Brothers
at www.jaypeebrothers.com



JAYPEE BROTHERS
Medical Publishers (P) Ltd.
www.jaypeebrothers.com
Join us on facebook.com/jaypeebrothers

Shelving Recommendations
GENERAL SURGERY
TRANSPLANTATION

ISBN 978-93-5152-339-0

