d information on dermatology books, visit our website www.jaypeebrothers.com, for detailed information on dermatology books, visit our website www.jaypeebrothers.com

JAYPEE

Hair and Hair Disorders

Diagnosis & Management



Chief Editor
S Sacchidanand

Co-editors
Savitha AS
Lakshmi DV

Contents

1. Evolution of Hair 1
Lakshmi DV, S Sacchidanand

- Convergent Evolution *1*
- Scale as a Basal State for Hair Follicle *1*
- Molecular Evolution of α- and β-keratin *3*
- Relative Hairlessness in Humans *3*

2. Hair Anatomy 5
Shilpa K, S Sacchidanand

- Types of Hair *5*
- Morphological Variants of Hair *7*
- Composition of Hair *8*
- Development of Hair Follicles *8*
- Anatomy of the Hair Follicle *9*
- Hair Shaft *14*
- Hair Cycle *16*
- Functions of Hair *20*

3. An Approach to a Patient with Hair Disorder 24
S Sacchidanand, Archana L

- History *24*
- Daily Hair Count Test *30*
- Standardized Wash Test *31*
- 60-Second Hair Count Test *31*
- Hair Pull Test *32*
- Global Photography Technique *32*
- Dermoscopy and Videodermoscopy *32*
- Hair Pluck Test/Trichogram *33*
- Unit Area Trichogram (UAT) *33*
- Phototrichogram (PTG) *33*
- Scalp Biopsy *35*

4. Genetic Hair Disorders 39
Arun C Inamadar, Vishalakshi S Pandit, Aparna Palit

- Monilethrix (Synonym: Beaded Hair) *39*
- Pseudomonilethrix *41*
- Pili Torti (PT) (Synonym: Twisted Hair, Corkscrew Hair) *41*
- Menkes Disease (Synonyms: Kinky Hair Disease, Trichopoliodystrophy, Steely Hair Disease) *44*
- Netherton Syndrome (Synonyms: Netherton's Disease, Bamboo Hair) *47*
- Trichothiodystrophy (Acronyms: PIBIDS, IBIDS and BIDS) *50*
- Ectodermal Dysplasia *53*

5. Hair Shaft Disorders 57
Savitha AS, S Sacchidanand
- Classification of Hair Shaft Disorders *57*
- Infections *68*
- Applications of Wood's Lamp in Hair Shaft Disorders *69*

6. Bacterial Infections of Hair and Scalp 72
Leelavathy B, Eswari L
- Classification *72*
- Diseases of the Scalp Due to Presumed Bacterial Etiology *80*
- Disorders of the Scalp in Other Bacterial Infections *84*

7. Fungal Infections of Hair and Scalp 86
R Madhu, C Janaki, G Sentamil Selvi
- Trichomycoses Caused by Dermatophytes *86*
- Pathogenesis *88*
- Piedra *94*
- Pityriasis Capitis Simplex/Seborrheic Dermatitis *96*

8. Pediculosis Capitis 99
Savitha AS
- Structure *99*
- Life Cycle *99*
- Epidemiology *99*
- Risk Factors for Transmission *100*
- Clinical Features *100*
- Differential Diagnosis *101*
- Treatment *101*
- Complications *103*
- Prognosis *103*

9. Scalp Disorders: Itchy and Scaly Scalp 105
Manjunath Shenoy M
- Pathophysiology of Itch (Pruritus) *105*
- Clinical Characteristics *107*
- Lichen Planus *109*
- Lichen Simplex *110*
- Diagnosis *111*
- Treatment *111*

10. Alopecia Areata 115
Eshini Perera, Rodney Sinclair
- Epidemiology *115*
- Etiology *115*
- Clinical Presentation *116*
- Differential Diagnosis *117*
- Physical Examination *117*
- Investigations *118*
- Histopathology *118*
- Management *118*
- Course of Disease *124*

11. Androgenetic Alopecia 128
Eshini Perera, Rodney Sinclair

- Epidemiology *128*
- Clinical Presentations *128*
- Etiology *128*
- Pathogenesis *129*
- Evaluation of Hair Loss *131*
- Serial Photography *133*
- Scalp Biopsies *133*
- Histopathology *134*
- Management *134*

12. Hair Loss in Women 141
Ralph M Trüeb

- Pathologic Dynamics of Hair Loss *141*
- Etiologies and Clinical Presentations *142*
- Dystrophic Anagen Effluvium *143*
- Telogen Effluvium *144*
- Androgenetic Alopecia *145*
- Postpartum Hair Loss *146*
- Menopause *146*
- Senescent Alopecia *146*
- Seasonality of Hair Growth and Shedding *147*
- Inflammatory Phenomena and Scarring *148*
- Postmenopausal Frontal Fibrosing Alopecia *148*
- Fibrosing Alopecia in a Pattern Distribution *148*
- Acute Diffuse and Total Alopecia of the Female Scalp *149*
- Psychogenic Pseudoeffluvium *150*
- Tonsure Trichotillomania *150*
- Adjustment Disorders *150*
- Quantitating Hair Loss *151*
- Value of Trichoscopy for Differential Diagnosis *151*
- Treatment *152*
- Value of Oral Supplementation Therapy *153*
- Treatment of Female Androgenetic Alopecia *153*
- Value of Hair Care *155*
- Autologous Hair Transplantation *156*
- Hair Prosthesis *156*
- Psychological Counseling *157*

13. Telogen Effluvium 162
Neelima Sharma, S Sacchidanand

- Definition *162*
- Burden *162*
- Impact on the Individual *162*
- Triggers *162*
- Physiological Condition *162*
- Dietary Triggers *164*
- Stress *166*
- Endocrine Dysfunction *166*
- Inflammatory Scalp Diseases *166*

- Drugs and Supplements *166*
- Pathogenesis *167*
- Classification *167*
- Diagnosis *169*
- Physical Examination *169*
- Treatment *171*
- Patient Education *171*
- Management of Triggers *171*
- Specific Treatments *172*
- Camouflage and Scalp Prosthesis *173*
- Surgery *173*

14. Hair and Endocrine System 175

Neelima Sharma

- Androgens *176*
- Estrogen *181*
- Thyroid Hormones *182*
- Vitamin D *183*
- Prolactin *184*
- Growth Hormone and Insulin-like Growth Factor *185*
- Insulin *185*
- Parathyroid Hormone *186*
- Melatonin *186*
- Glucocorticoids *187*
- Corticotropin-releasing Factor *187*
- Erythropoietin *187*

15. Cicatricial Alopecia 190

Ashok Kumar Jaiswal, TS Nagesh

- Epidemiology *190*
- Classification *190*
- Primary Cicatricial Alopecia *192*
- Secondary Cicatricial Alopecia *202*
- Cicatricial Alopecia: At a Glance *207*

16. A. Hirsutism 209

KC Nischal, Urmila Nischal

- Epidemiology *209*
- Etiopathogenesis *209*
- Clinical Features *215*
- Investigations *216*
- Management of Hirsutism *219*
- Treatment *220*

B. Hypertrichosis 228

S Sacchidanand, Divya Gorur

- Definition *228*
- Hypertrichosis of Lanugo Hair *228*
- Hypertrichosis of Vellus Hairs *230*
- Hypertrichosis of Terminal Hairs *230*

17. Hair and Nutrition 235
Shashikumar BM
- Protein-Energy Malnutrition (PEM) *235*
- Deficiency of Vitamins *236*
- Essential Fatty Acids (EFA) *238*
- Deficiency of Micronutrients *238*
- Treatment *239*

18. Cultural Influence on Hair Disorders 241
D Dinesh Kumar, Anoosha P
- Structural Evaluation *241*
- Hair Care Practices Among Different Cultures *242*
- Association of Hair and Scalp Disorders with the Prevailing Cultural Trends *244*

19. Canities 247
Asha GS, Lakshmi DV
- Epidemiology *247*
- Pathophysiology *247*
- Pattern of Graying *249*
- Characteristics of Gray Hair *249*
- Classification *249*
- Primary Diffuse Hypopigmentation of Hair *249*
- Poliosis *253*
- Alteration of Hair Color Due to Exogenous Agents *255*
- Management *255*

20. Follicular Tumors 259
Rajiv Sharad Joshi
- Functional Anatomy of the Hair Follicle *259*
- Keratinization of Various Follicular Structures *260*

21. Psychosomatic Hair Disorders 273
Smitha Prabhu, Sudhir Nayak UK, Shrutakirthi D Shenoi
- Primary Psychotrichological Conditions *273*
- Primary Trichological Condition with Secondary Psychological Impact *276*
- Multifactorial Diseases Affecting the Scalp *277*

22. Shampoos and Conditioners 285
Anil Abraham
- 'Genealogy' of the Current Day Shampoo *285*
- Definition *285*
- Shampoos that Address Specific Needs *287*
- Adverse Reactions to Shampoos *288*

23. Follicular Unit Transplantation 290
Manoj Khanna, Dolly Gupta
- History and Evolution of Hair Transplantation *290*
- Theory of Donor Dominance: Basis of Hair Transplantation *290*
- Mini-micro Grafting *291*
- Follicular Units and Follicular Unit Transplantation *292*

- Hair Transplantation in Females *300*
- Hair Transplantation under Special Situation *300*
- Limitations of Follicular Unit Transplantation *301*

24. Recent Advances in Hair Transplantation 303
Venkataram Mysore, Raghini Ghiya
- Improving Donor Scar *303*

25. Laser Hair Removal 311
Sanjeev J Aurangabadkar
- Definition *311*
- Hair Growth Cycle *312*
- Principle of Laser Kinetics and Dynamics for Hair Reduction *312*
- Types of Lasers for Hair Removal *312*
- Indications *313*
- Contraindications *314*
- History and Examination *314*
- Preprocedure Workup *314*
- Laser Hair Removal Procedure *314*
- Hair Reduction Systems *315*
- Newer Concepts in Laser Hair Removal *317*
- Choosing Appropriate Patients *317*
- Complications *318*

26. Mesotherapy for Hair and Scalp Disorders 320
Maya Vedamurthy
- Principle of Mesotherapy *320*
- Techniques used in Mesotherapy for Hair *321*
- Ingredients used in Mesotherapy for Hair Loss *323*
- Indications *323*
- Treatment Protocol and Procedure *323*
- Postmesotherapy Instructions/Care *323*
- Contraindications *323*
- Adverse Effects *324*
- Position of Mesotherapy *324*
- Advantages of Mesotherapy *324*

27. Hair Cosmetics 325
Malavika Kohli, Sheena Bansal
- Hair Treatments *325*
- Styling Aids *326*

28. Platelet Rich Plasma in Trichology 333
S Sacchidanand, Lakshmi DV
- Definition *333*
- Mechanism of Action *333*
- Growth Factors of Platelet Rich Plasma *333*
- Classification of Platelet Concentrates *333*
- Method of Preparation of Platelet Rich Plasma (PRP) *335*
- Factors Affecting Platelet Yield and Viability *335*
- Indications for Platelet Rich Plasma *335*
- Advantages of Platelet Rich Plasma *338*

29. Stem Cell Therapy in Hair Restoration 340
Eswari L, S Sacchidanand

- Stem Cells *340*
- Hair and Stem Cells *340*
- Human Induced Pluripotent Stem Cells *341*
- Human Hair Follicle Stem Cells (HFSCs) *342*
- Heterologous Mesenchymal Stem Cells *342*
- Criteria to Define Mesenchymal Stem Cells *342*
- Therapeutic Effects of Mesenchymal Stem Cells *343*
- Limits of Mesenchymal Stem Cells *343*

30. Overview of Management of Disorders of Hair and Scalp.....345
Prabhakar M Sangolli

- Alopecia *345*
- Scaling Disorders *348*

Index 353

2

Hair Anatomy

Shilpa K, S Sacchidanand

"The hair is the richest ornament of women."

—Martin Luther

Introduction

Hair has no vital function in humans, yet its psychological functions are extremely important, which brings one's self-image into focus. The human hair follicle (HF) is a sophisticated miniorgan, composed of multiple mesenchymal and epithelial cell layers, consisting of more than 20 different cell populations in total. Together with the arrector pili muscle and the sebaceous gland, the hair follicle forms the pilosebaceous unit **(Box 2.1)**. It has the extraordinary capability of self-renewal. Understanding the complex biology and function of the hair follicle requires familiarity with its anatomy, especially of the bulge region, the putative residence of the hair follicle stem cells, and the dermal papilla, which are believed to be responsible for the regulation of the hair cycle. Although the exact role of each part of the hair follicle has for long been a mystery, recent advances in hair follicle research have given us better insight on their function in maintaining hair follicle growth and cycle.[1]

Types of Hair (Box 2.2)

There are different types of hair on human body and different types of hair can be produced by any particular follicle under the influence of hormones or advancing age.[2] There are four different types of hair.

Box 2.1: Components of a pilosebaceous unit

- Hair follicles
- Arrector pili muscle
- Sebaceous gland

Lanugo Hairs (Latin: Lana-Wool) (Figure 2.1)

Lanugo hairs are the prenatal coat of hair consisting of fine, soft, unmedullated and usually unpigmented hair, which covers the entire body in humans in utero and is normally shed in the eighth to ninth month of gestation and are replaced by vellus hairs by 36–40 weeks. The presence of lanugo hairs at birth may indicate prematurity.[3] Lanugo

Box 2.2: Types of hair

- Prenatal—lanugo
- Postnatal—
  - Vellus
  - Terminal
  - Intermediate

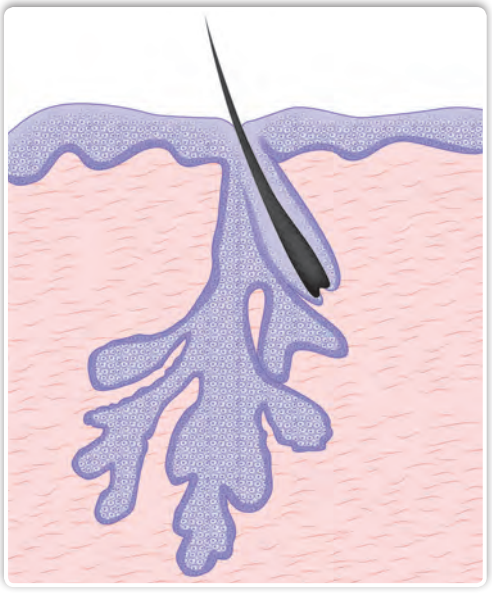

Fig. 2.1: Unmedullated lanugo hair

Box 2.3: Causes of persistent lanugo hairs

- Congenital hypertrichosis lanuginosa
- Acquired lanugo hair
  - Anorexia nervosa
  - Bulimia nervosa
  - Hypertrichosis lanuginosa acquisita—aero digestive tract malignancy

Box 2.4: Areas devoid of vellus hairs

- Lips
- Back of the ear
- Palms and soles
- Navel
- Some parts of external genitalia

hairs have been reported to occur in adults in psychiatric conditions like anorexia nervosa and bulimia nervosa and their occurrence in these conditions has been explained as an attempt to prevent heat loss from the body which can occur due to loss of subcutaneous fat in these patients.[4] In congenital hypertrichosis lanuginosa, the fetal pelage is not replaced by vellus and terminal hair but persists, grows excessively and is constantly renewed throughout life.[5] Hypertrichosis lanuginosa acquisita is a very rare condition characterized by the rapid growth of long, fine, lanugo-type hair particularly around the eyebrows, forehead, ears and nose seen with aero digestive tract malignancy as a cutaneous marker of internal malignancy **(Box 2.3)**.[6]

Postnatal hair may be divided into three kinds: Vellus, terminal, and intermediate hairs.

Vellus Hairs (Latin: Vellus-Fleece) (Figure 2.2)

The vellus hair is soft, unmedullated, occasionally pigmented and seldom grows more than 2 cms long and present over much of the body area, exceptions include lips, back of the ear, palm, sole, some external genital areas, the navel and scar tissue **(Box 2.4)**. After puberty, under the influence of androgen, vellus hairs are replaced by 'terminal' hairs in certain areas like beard, axilla, pubic area, etc.

Vellus hairs help in preventing heat loss from the body. An entity called eruptive vellus hair cyst has been reported in children.[7] Vellus hairs are resistant to laser hair reduction procedures.[8]

Terminal Hairs (Figure 2.3)

Terminal hair is the pigmented, longer, coarser hair and consistently possess a medulla. Till puberty, distribution of terminal hair is normally limited to the eyebrows, eyelashes and the scalp. After puberty they replace vellus hairs in areas like beard, axilla and pubic area, etc. Pubic and axillary hair will develop in both men and women, and they are considered as a secondary sex characteristics[9] although, males will develop terminal hair in more areas. This includes facial hair, chest hair, abdominal hair, leg and arm hair, and foot hair. Females, on the other hand retain more of the vellus hairs.[10]

Hypertrichosis is the term used for excessive hair growth on any part or whole body as compared to persons of the same age, sex and race.[11] Hypertrichosis must not be confused with hirsutism, which is defined as androgen-induced growth of terminal hair in women and children, in a male pattern distribution. Hirsutism is androgen-dependent while hypertrichosis is not.[12] In hirsute women, vellus follicles manufacture terminal hairs in certain areas of the body like cheeks, chin, chest, lower back and abdomen in response to increased circulating androgen levels.[13] Permanent reduction of pigmented terminal hairs can be done using laser **(Table 2.1)**.[14]

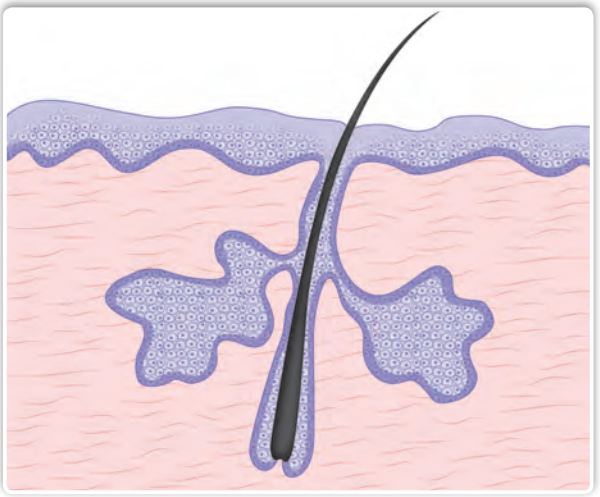

Fig. 2.2: Short unmedullated vellus hair

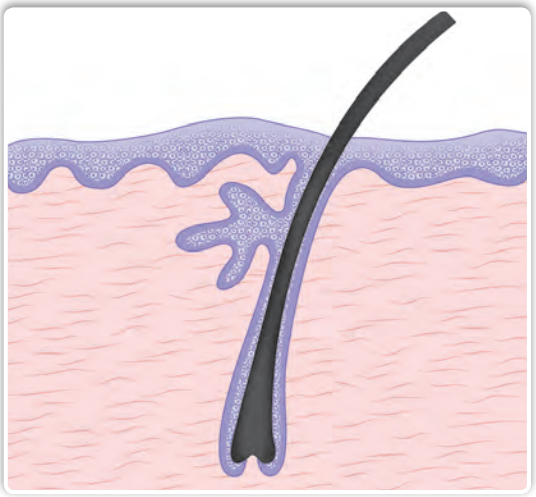

Fig. 2.3: Coarse thick medullated terminal hair

Table 2.1: Characteristics of hypertrichosis and hirsutism

	Hypertrichosis	*Hirsutism*
Definition	Excessive hair growth on any part or whole body in comparison to persons of same age, sex and race	Androgen induced growth of terminal hair
Sex predilection	No	Seen in women and children
Androgen dependency	Absent	Present
Areas affected	Generalized	Cheeks, chin, chest, lower back, abdomen

Intermediate Hairs

There is another variant of postnatal hair called as intermediate hair. It shows the characteristics of both vellus hairs and terminal hairs. Intermediate hairs have a medulla and contain a moderate amount of pigment, less than that found in the terminal hair type.

During the balding process terminal hair follicles and intermediate hair follicles change in such a way, that they no longer produce terminal hairs. In these areas, hair follicles grow vellus hairs rather than terminal hairs resulting in androgenic alopecia.[15]

Morphological Variants of Hair (Box 2.5)

Morphologically, hairs can be divided into four categories:

Spiral Hairs

Hairs in Blacks are spiral because the hair follicles are curved and the bases of their bulb are oriented somewhat horizontal to the skin surface. In addition, different rates of growth of matrical cells along the side of the bulbs may be responsible for the spirals. It is hypothesized that curly hair impedes the passage of UV light into the body relative to straight hair, thus curly or coiled hair would be particularly advantageous for dark-skinned hominids living at the equator.[16]

Straight Hairs

Hairs in Asians are straight because the follicles are straight and oriented vertically to the skin surface. Straight hair would have been an adaptive liability as hominoids traveled farther from Africa or the equator. Straight hair may have (initially) evolved to aid the entry of UV light into the body during the transition from dark, UV-protected skin to pale-white skin.[16]

Box 2.5: Morphological variants of hair

- Spiral hair
- Straight hair
- Helical hair
- Wavy hair

Helical Hairs

It can be seen in Whites. Helical hair accompanying trichorrhexis invaginata and pili torti in an infant with Netherton's syndrome has been reported.[17]

Wavy Hairs

Hair in Whites may be any of these four types, but most are wavy or straight.

Woolly hair is the tightly coiled hair occurring over the entire scalp or part of it, in an individual of non-Negroid origin.[18]

Hair Thickness

Hair thickness can vary tremendously depending on race, continent, varies from person to person, day to day, year to year. It also depends on anatomical site-body hair or head hair and gender. Hair from a human head is normally between 0.04 and 0.25 mm, averaging normally 0.1 mm.[19] The term anisotrichosis has recently been proposed to describe diversity of hair shaft diameter. Anisotrichosis more than 20% on trichoscopy is diagnostic of female androgenetic alopecia (FAGA) **(Box 2.6)**.[20]

Hair Shape and Texture (Figure 2.4)

The shape of the hair strand when cut in cross-section varies depending on the race. It is round in shape in Asians, slightly less round in Caucasians and oval or elliptical in African hair.[21] However, nutritional status and intentional alteration (heat curling, "perms") can affect the physical appearance of hair.

Box 2.6: Anisotrichosis

- Refers to diversity in hair shaft diameter
- Average hair thickness 0.1 mm (0.04–0.25 mm)
- More than 20% anisotrichosis on trichoscopy implies FAGA

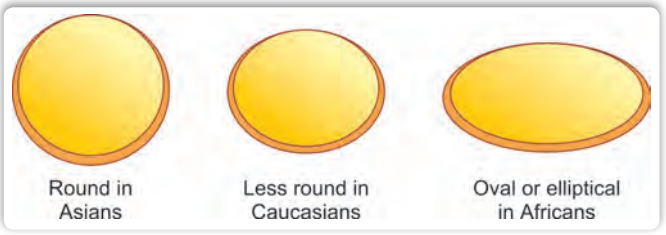

Fig. 2.4: Cross-section of terminal hair. It is round in shape in Asians, slightly less round in Caucasians and oval or elliptical in African hair

Hair shine is an optical phenomenon that depends on the light reflected by outer layers of the cuticle, higher the number of layers, the higher the ratio of the reflected light and the more intense is the luster. Luster may be affected by hair surface damage, hair color and their morphology. Other factors that influence luster include the presence of sebum, which eliminates this shine and renders the hair dull and unattractive by an interference mechanism.[22]

Composition of Hair

In terms of raw elements on an average hair is composed of 50% carbon, 20% oxygen, 17% nitrogen, 6% hydrogen and 5% sulfur. Hair also contains trace amounts of magnesium, arsenic, iron, chromium and other metals and minerals **(Table 2.2)**.[23]

Development of Hair Follicles

During embryonic development human hair follicles appear at about 9 weeks. First it emerges in the regions of the eyebrows, upper lip and chin, and by fourth month covers the entire body.[24] In humans, the full complement of hair follicles is probably established by the time of birth. New hair follicles are never formed after birth.

In many cases, areas on the human body that contain vellus hair will begin to produce darker, thicker body hair. An example of this is the growth of an adolescent's beard on a once smooth chin. Androgenic hair follows the same growth pattern as the hair that grows on the scalp, only the anagen phase is shorter, and the telogen phase is longer.

Follicle Density

There are approximately 100,000 hair follicles on the scalp.[25] It varies with the age, sex, race and area of the body. Follicle density is defined as number of hair follicles per unit area of skin. It is highest in the fetus, and is uniform across the skin surface because of the smaller body surface area. As the child grows there is a progressive reduction in follicle density, as skin surface area increases.

The forehead and cheeks have the highest hair follicle densities, which is approximately 800/cm^2 and in women on cheeks it is 400–450/cm^2.[26] Chest and back show lower hair densities of 50–100/cm^2,[26,27] and, follicle densities on the thigh and leg is around 50/cm^2.[28] Hair density on scalp varies between 250–320 hairs/cm^2.[29]

Density of scalp hair varies between various races, in Africans it is 187/cm^2,[30] in African Americans it is 171/cm^2,[31] and in Koreans 128/cm^2.[32]

On the scalp, and some other regions of the skin, hair follicles are arranged in groups of three or more follicles known as follicular units. The follicular unit is defined as a group of one to three hairs that grow naturally together, also includes one to two fine vellus hair, glands, muscle, nerves and blood vessels.[33] Several follicles within a follicular unit may coalesce so that hairs emerge through a common infundibulum **(Figure 2.5)**.

By keeping the transplanted micrografts to the size of a naturally occurring follicular unit, it is possible to provide hair restoration that is natural looking and undetectable.

Rate of Hair Growth

The rate of hair growth varies from species to species and within one species from region to region, as well as with sex and age. While there is some variation, human hair generally grows at a rate of 1 cm per month or 0.35 mm/day. According to a study done with graduated capillary tubes being fitted around the growing hairs, the average growth in males was as shown in **Box 2.7**.[34]

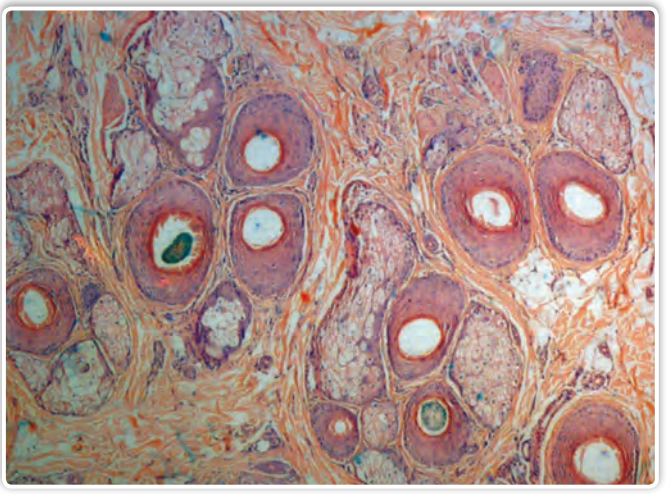

Fig. 2.5: Horizontal section of scalp specimen showing follicular unit

Table 2.2: Composition of hair

Carbon	50%
Oxygen	20%
Nitrogen	17%
Hydrogen	6%
Sulfur	5%
Traces of magnesium, arsenic, iron, chromium and other metals	

Box 2.7: Rate of hair growth

- 0.35 mm/day or 1 cm per month
- Vertex 0.44 mm/24 hours
- Temple 0.39 mm/24 hours
- Beard 0.27 mm/24 hours
- Chest 0.44 mm/24 hours in males

Hair Color

Hair color is determined by the melanocytes found in the matrix area of the follicle at the base of the cortex directly above the follicular papilla. Melanocytes transfer melanosomes to cortical cells during anagen. Eumelanin is the dominant global pigment and confers black or brown hair. Pheomelanin, a mutation of eumelanin, is the predominant pigment found in blond hair.[35] The proportions of eumelanin and pheomelanin and the total amount of melanin determine the hair color.[36] Graying of hair is a normal manifestation of ageing and illustrates progressive reduction in melanocyte function.

Just as epidermal keratinocytes incorporate melanosomes by clipping off the ends of melanocytic dendrites by apocopation, matrix cells of the follicle do the same to dendrites of melanocytes situated within the follicular bulb. The ratio of follicular cells to melanocytes in hair bulb is 1:1.[37] Cells of the cuticle of the hair do not contain melanosomes **(Table 2.3)**.

Black and dark brown are the prevalent natural hair colors of the people of all regions accounting for more than 90% of all human hair. Dark hair is characterized by very high levels of the dark pigment eumelanin. Blond hair is characterized by very low levels of the dark pigment eumelanin and very high levels of the pale pigment pheomelanin. Red hair (rutilism) is associated with the melanocortin-1 receptor gene anomaly, which is found on chromosome 16.[38] Red hair is an example of incomplete dominance **(Box 2.8)**. When only one copy of the red hair allele is present, red hair may blend with the other hair color, resulting in different types of red hair including strawberry blonde (red blonde) and auburn (red brown).

Anatomy of the Hair Follicle

Human hair is a filamentous outgrowth of the skin which grows from hair follicles deep in the skin dermis and projects out above the epidermis. The follicles are sloped in the dermis, and longer follicles extend into the subcutaneous layer. An oblique muscle, the arrector pili, runs from the mid-region of the follicle wall to a point in the papillary dermis close to the dermal epidermal junction. Above the muscle, one or more sebaceous glands and in some regions of the body an apocrine gland also, opens into the follicle.

Broadly, the structure of hair is divided into two components: the hair shaft and hair root.

The hair root may be divided anatomically into four parts from below upwards **(Figure 2.6)**.

1. The bulb consisting of the dermal papilla and matrix
2. The suprabulbar area from the matrix to the insertion of the arrector pili muscle
3. The isthmus that extends from the insertion of the arrector pili muscle to the sebaceous gland
4. The infundibulum that extends from the sebaceous gland to the follicular orifice.

Table 2.3: Factors determining the hair color

- ❑ Ratio of follicular cells to melanocytes in hair bulb (normal 1:1)
- ❑ Total amount of melanin in the follicular matrix at the base of cortex
- ❑ Dominant pigment : Eumelanin or pheomelanin
- ❑ Proportions of eumelanin and pheomelanin
- ❑ Melanosome transfer mechanisms in cortical cells
- ❑ Hair cycle stage: Anagen phase

Box 2.8: Rutilism

- Refers to presence of red hair
- Incomplete dominant pattern of inheritance
- Melanocortin 1 receptor gene anomaly found on chromosome 16
- Presence of one red allele copy may lead to strawberry blonde or Auburn hair

Hair Bulb (Figures 2.7 and 2.8)

The lowest part of a hair follicle is called the bulb because it resembles the bulb of a tulip or an onion. In large terminal follicles, the hair bulb is situated in the subcutaneous fat. The hair bulb encloses the dermal papilla which invaginates its base and is connected to the perifollicular dermal sheath by a narrow stalk.

The boundaries of a pear shaped follicular bulb are the base of a follicle below and the summit of the high arched curve of the "keratogenous zone" that ends at the distinct border known as Adamson's fringe **(Box 2.9)**.

The site at which Huxley's layer loses its trichohyalin granules and begins to cornify defines both Adamson's fringe and the upper boundary of the bulb. The epithelial

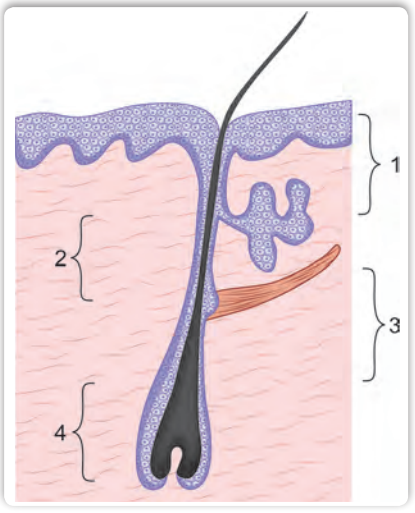

Fig. 2.6: Different parts of the hair bulb: 1. Infundibulum; 2. Isthmus; 3. Suprabulbar region; 4. Bulb

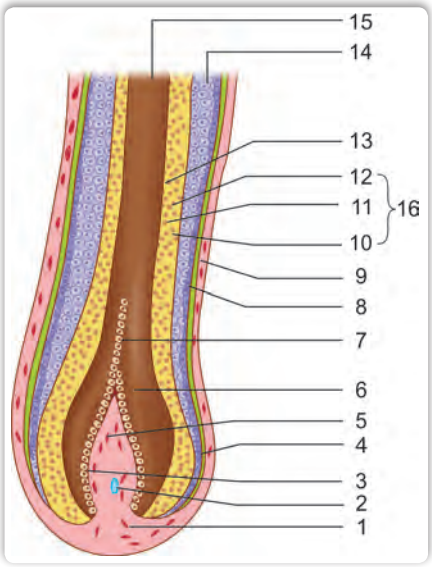

Fig. 2.7: Vertical section of the hair bulb: 1. Connective tissue of the cutis; 2. Blood vessel; 3. Glassy layer of the hair bulb; 4. Hair bulb; 5. Hair papilla; 6. Cortical substance of hair; 7. Medulla of the hair; 8. Basal cells of outer root sheath; 9. Glassy layer; 10. Henle's layer; 11. Huxley's layer; 12. Cuticle of inner root sheath; 13. Cuticle of the hair; 14. Stratum malphigii of outer root sheath; 15. The hair; 16. Inner root sheath

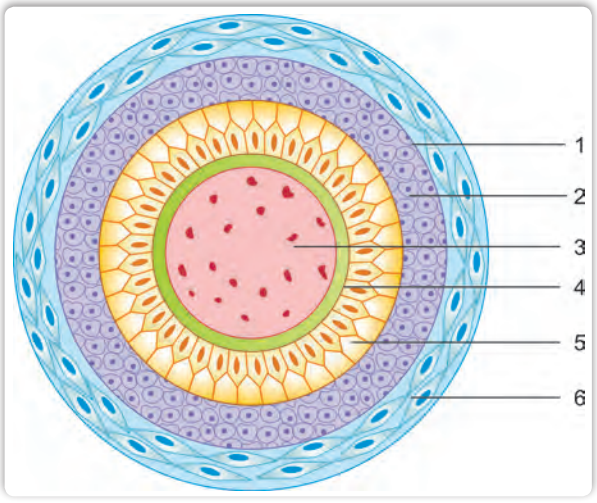

Fig. 2.8: Horizontal section of hair root: 1. Glassy layer; 2. Outer root sheath; 3. Cortex of the hair; 4. Cuticle of the inner root sheath; 5. Henle's layer; 6. Fibrous tissue sheath

Box 2.9: Adamson's fringe

- Imaginary border that marks the summit of keratogenous zone
- Huxley layer loses its trichohyalin granules and begins to cornify
- Layers lack complete cornification
- Keratinophilic dermatophytes fail to descend below this line

cells in the keratogenous zone are all nucleated, i.e. from the outside in, the pale and clear cells of the outer root sheath, trichohyalin granules containing cells of the inner root sheath, and the cells of the future hair. It is at Adamson's fringe that cornification of the viable keratinocytes can first be recognized, cells of the inner root sheath lose their trichohyalin granules and become bluish gray, and compactly arranged corneocytes and cells of maturing hairs lose their nuclei and come to resemble fully cornified hairs. The process of keratinization proceeds apace in pyriform bulb of a follicle, but complete cornification does not occur here. It is for this reason that dermatophytes, dependent on cornified cells to live never descend a follicle below Adamson's fringe.[39]

The hair bulb matrix or germinal epithelium constitutes epithelial cells surrounding the dermal papilla with a high mitotic rate and a rate of cell turnover similar to that in the bone marrow. The progeny of the dividing cells migrate upwards and differentiate in a highly ordered fashion to form the concentric layers of the inner root sheath and the hair shaft. The inner root sheath is derived from cells in the lower, more lateral part of the matrix, whereas the hair shaft is formed from the upper, centrally situated cells.

In pigmented hair follicles, highly melanized melanocytes are situated amongst cells destined to form the hair cortex.[34] Occasional Langerhans' cells may also be found in the matrix region.

The germinative (matrix) cells of follicular bulbs differentiate along seven separate pathways that, in part may be related to the distance of matricial cells from the center of the papilla. These morphological changes in follicular epithelium are discernable first near the base of the bulb where the outer root sheath, the three layers of the inner root sheath, and the three layers of the hair begin to be formed.

From outside, the seven components of the bulb are:

1. The outer root sheath filled with glycogen during anagen and therefore composed of pale and clear cells.
2. Henle's layer of the inner sheath, one cell thick with prominent trichohyalin granules and the first to cornify.
3. Huxley's layer of the inner sheath, two cells thick and characterized by numerous brightly eosinophilic trichohyalin granules.
4. Cuticle of the inner sheath, one cell thick.
5. Cuticle of the hair composed of a single layer of imbricated squames that wrap around the hair.
6. Cortex of the hair that constitutes the bulk of it.
7. The medulla of the hair, the last to cornify.

Dermal Papilla

The dermal papilla is a flask-shaped structure that invaginates the base of the hair follicle, derived from a condensation of mesenchymal cells. It is made up of specialized fibroblast-like cells embedded in an extracellular matrix rich in basement-membrane proteins and proteoglycans, and contains a loop of capillary blood

vessels in large follicles. It is connected to the dermal sheath surrounding the follicle by a narrow stalk. The dermal papilla itself is not the source of the hair, the active germinal epithelium lying over it is. The presence and close proximity of the dermal papilla to the germinal matrix induces it to proliferate by sending chemical signals. When the signal is received, the germinal matrix proliferates and produces the hair and the inner root sheath. The triggering of hair growth by proximity of the dermal papilla is a classic example of the phenomenon of induction, the response of one cell population to signals from a second population.[40]

The bulbs and papillae in a given section of skin are not all the same size. In anagen, the growing phase, a well developed flask shaped dermal papilla is seen. In catagen phase, the dermal papilla shrinks and withdraws away from the bulb. This removes the necessary induction and the hair stops growing. The dermal papillae are smaller in hairs which are being shed (telogen hair).

The dermal papilla is the primary target of androgen action in the hair follicle. Androgen receptor expression in the lower part of the follicle is restricted to dermal papilla cells.[41,42] The size of the hair follicle is probably determined by the volume of the dermal papilla.[43] Dermal papillae express 5α-reductase type 2 whereas hair follicle epithelium expresses only 5α-reductase type 1 **(Box 2.10)**.[42]

Functions

1. Dermal papilla plays an essential part in the induction and maintenance of follicular epithelial differentiation.[40]
2. It is responsible for determining the follicle type.
3. The volume of the dermal papilla may also be responsible for controlling the size of the hair follicle, and that of the hair fiber.[44]

Suprabulbar Region

It is the longest section of terminal hair follicle in anagen. Isthmus and hair bulb form the upper and lower boundary of the suprabulbar region respectively. It is comprised of three layers from innermost to outermost: hair shaft, inner root sheath and outer root sheath. The outer root sheath is a multilayered epithelium enclosing the inner root sheath which, at this level, is a fully keratinized structure. Cells of the hair shaft, at the center of the follicle, undergo terminal differentiation within the keratogenous zone in the middle part of the suprabulbar region.

Isthmus

The isthmus extends from the opening of the sebaceous gland duct to the insertion of the arrector pili muscle. It consists of a multilayered outer root sheath that is continuous with the infundibulum but differs in its structure. The innermost cells undergo trichilemmal keratinization, a pattern of differentiation characterized by deposition of compact eosinophilic keratin without an intervening granular layer **(Box 2.11)**.[45] The keratinized inner root sheath, which lies within the outer root sheath, disintegrates at or about the level of the sebaceous duct. The bulge region below the isthmus, which allows insertion of arrector pili muscle also harbors a specialized compartment of outer root sheath, which form the niche for epithelial and neuroectodermal stem cells as well as various immature cell population including immature Langerhans cell and mast cell.

The stem cells were first described by Cotsarelis G [46] et al. These hair follicle stem cells are highly pluripotent which can proliferate and differentiate into various cell lines like neurons, muscles, etc.[47] In hair, these stem cells proliferate only during the onset of anagen. These dividing hair follicle stem cells, known as transient amplifying cells, migrate downwards and enter the hair bulb matrix where they proliferate and undergo terminal differentiation to form the hair shaft and inner root sheath. Not only the hair follicle, they also migrate distally to form the sebaceous gland and under certain circumstances such as wound healing, the epidermis **(Figure 2.9)**.[48]

The hair follicle stem cells may become the stem cells of choice in the future for regenerative medicine[47] since, (1) They are readily available from essentially anyone, (2) They are easily cultured and expanded, (3) They are highly pluripotent, (4) They have been demonstrated to be able to support the regrowth of nerves, (5) They do not carry the ethical issues that embryonic stem cells and fetal stem cells do. The near future should be an exciting time in stem cell.

Box 2.10: Dermal papillae

- Specialized fibroblast like cells embedded in extracellular matrix, mesenchymal in origin
- Rich in basement-membrane proteins and proteoglycans
- Contains a loop of capillary blood vessels
- Flask shaped in anagen while shrinks during catagen phase
- Primary target of androgen action in the hair follicle as they express 5α-reductase type 2
- Triggers hair growth by proximity of the dermal papilla (phenomenon of induction)

Box 2.11: Trichilemmal keratinization

- A pattern of differentiation characterized by deposition of compact eosinophilic keratin without an intervening granular layer
- The trichilemmal keratinization of ORS starts at the level of isthmus where the IRS disintegrates. At the level of the infundibulum, keratinization of the outer root sheath changes to normal epidermal keratinization
- Cysts arising from the isthmus portion of the hair follicle showing trichilemmal mode of keratinization termed as trichilemmal cysts/isthmus-catagen type of follicular cysts/pilar cysts

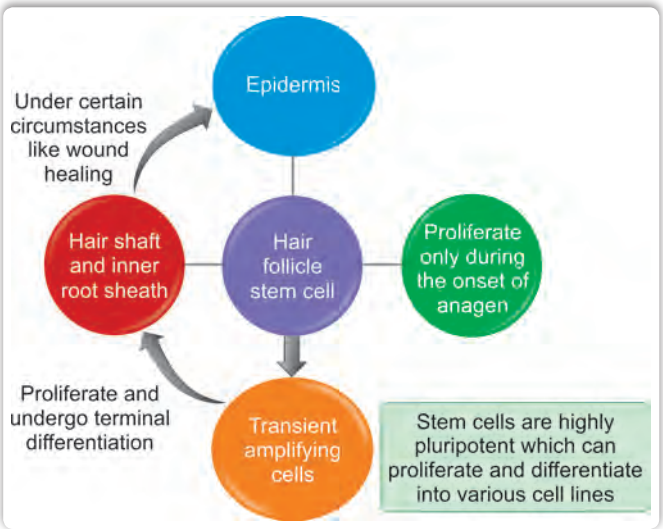

Figure 2.9: Schematic representation of hair follicle stem cell functions

Cysts arising from the isthmus portion of the hair follicle showing trichilemmal mode of keratinization termed as trichilemmal cysts or isthmus-catagen type of follicular cysts or pilar cysts has been reported.[49]

Arrector Pili Muscle (Box 2.12)

The arrector pili muscle associated with each follicle is a band of smooth muscle whose origin is in the fibrils of the dermis. It inserts onto the connective tissue investment of the follicle. Unlike the hair, which is ectodermal in origin, and part of the epidermis, the arrector pili is a true dermal structure and derived from embryonic mesoderm. Arrector pili muscle is absent in eye lashes.[20]

When the arrector pili contracts, it elevates the hair. This phenomenon of piloerection can occur in response to a number of stimuli. Piloerection is a common response to cold; lifting the hair increases the air spaces and hence the insulating value of the hair coat. It also occurs in response to anger or fear, because of the adrenaline surge that these emotions involve.[50]

Infundibulum (In Latin: Funnel) (Box 2.13)

The infundibulum extends from the skin surface, where it merges with the epidermis, to the opening of the sebaceous duct at the junction with the isthmus. The funnel shaped infundibulum eventually passes through the epidermis, where it is known as acrotrichium.

Infundibular epithelium is nearly identical morphologically to the epidermis with which it is continuous, and it cornifies in the same manner. The corneocyte of the epidermis and infundibulum are arranged in basket weave pattern. A granular zone with numerous keratohyalin granules is present beneath the cornified layer of the infundibulum, including infrainfundibulum. Infundibular epithelium differs slightly from epidermal epithelium because it generally lacks rete ridges and is thinner. The epithelium of infrainfundibulum differs from that of an infundibulum by having walls that are parallel, a slightly thinner granular zone, and fewer corneocytes.

Follicular infundibula, especially on the scalp, face and upper part of the trunk, normally harbor a variety of bacteria (e.g. *Staphylococcus epidermidis*, *Propionibacterium acnes*), yeasts (e.g. *Pityrosporum orbiculare* and *P. ovale*) and mite, *Demodex folliculorum*. They are normal non pathogenic commensals, and do not cause skin diseases in persons who are competent immunologically.

Sometimes a cyst occurring on the face and lined by epithelium like that of follicular infundibulum termed as infundibular cyst has been reported.[51] Infundibular carcinoma has also been reported as a separate entity with distinct histopathological and immunohistochemical markers.[52]

Box 2.12: Arrector pili muscle

- Band of smooth muscle ectodermal in origin
- Inserts onto the connective tissue investment of the follicle
- Absent in eyelashes
- It contracts to elevate the hair, i.e. piloerection in response to adrenaline surge.

Box 2.13: Infundibulum

- Extends from the skin surface, where it merges with the epidermis, to the opening of the sebaceous duct at the isthmus
- Epidermal surface opening referred to as acrotrichium
- Infundibular epithelium lacks rete ridges and is thinner
- Infrainfundibulum epithelium differs from that of an infundibulum by having walls that are parallel, a slightly thinner granular zone, and fewer corneocytes
- Harbor a variety of bacteria (e.g. *Staphylococcus epidermidis*, *Propionibacterium acnes*), yeasts (e.g. *Pityrosporum orbiculare* and *P. ovale*) and mite *Demodex folliculorum*

Dermal Sheath

The dermal or connective tissue sheath envelopes the lower part of the hair follicle. The dermal sheath becomes less distinct, both structurally and functionally, as it is traced upwards as it merges with the interfollicular dermis above the level of the arrector pili insertion. They contain progenitor cells which are specialized fibroblasts that maintain and regenerate the dermal papilla, a key component for hair growth. They can become wound healing fibroblasts and perform an important function in the repair of skin dermis after injury. In experimental animals, cultured peribulbar dermal sheath cells can induce hair follicle development and contribute to the dermal sheath and dermal papilla.[53]

Inner Root Sheath

The inner root sheath (IRS) of the hair follicle is located between the outer root sheath and the hair shaft. It is made of three layers: Henle's layer, Huxley's layer, and the cuticle **(Figure 2.10)**.

Henle's layer is the outermost layer of the inner root sheath, consisting of a single row of cubical transparent cells that do not contain nuclei. Huxley's layer is in the middle, made up of approximately two rows of flattened cells with granular protoplasm. The cuticle of the root sheath is in the center, continuous with the outermost layer of the hair fiber. Flugzellen (winged cells) are specialized cells of Huxley's layer in the supra-bulbous portion of the follicle, which shows elongated cytoplasmic pseudopods that traverse the rigid cornified impermeable Henle's layer and connect with the innermost cells of the outer root sheath **(Box 2.14)**.[54]

Henle's layer is the first to cornify followed by the cuticle while, the cells of Huxley's layer cornify last of all. The cornification occurs through the formation of bright pink trichohyalin granules (the trichological counterpart of the keratohyaline granules of the epidermis and the follicular infundibulum). As the cells transform and get fully keratinized, the cytoplasm appears homogenous with filaments in a dense matrix. The trichohyalin granules and the nucleus disappear with scattered remnants of cytoplasmic organelles and nuclear ghosts in fully developed cornified cells.[55]

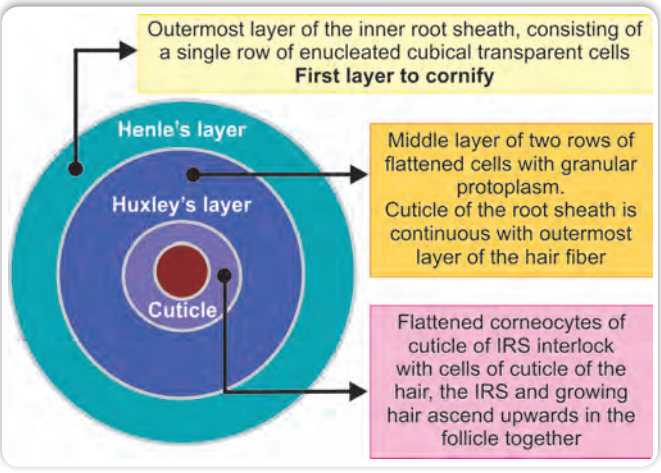

Fig. 2.10: Schematic representation of layers of inner root sheath

Box 2.14: Flugzellen cells (winged cells)

- Specialized cells of Huxley's layer in the supra-bulbous portion of the follicle, which shows elongated cytoplasmic pseudopod
- Cells traverse the rigid cornified impermeable Henle's layer and connect with innermost cells of ORS
- Function as nutritive canals between the not yet keratinized Huxley's layer and the ORS

Functionally, the inner root sheath serves as a rigid funnel-shaped protective covering around the hair and the flattened corneocytes of the cuticle of the inner root sheath overlap and interlock intimately with the cells of the cuticle of the hair ensuring that the inner root sheath and the growing hair that it protects, ascend upwards in the follicle together.[56] It is essential for the proper moulding, adherence, and keratinization of the growing hair. The Flugzellen of Huxley's layer are postulated to function as nutritive canals between the not yet keratinized Huxley's layer and the outer root sheath, bypassing the fully cornified and impermeable Henle's layer.[57] Premature keratinization of the inner root sheath has been implicated in the loss of the anchoring function and subsequent deformation of the hair shaft in loose anagen hair syndrome,[58] central centrifugal cicatricial alopecia (CCCA) and other cicatricial alopecia.[59]

Outer Root Sheath

The outer root sheath (ORS) is the outermost layer of hair follicle epithelium, enclosing the inner root sheath. Around the hair bulb it is a single layer of cuboidal cells, becomes multilayered in the region of the upper hair bulb. The outer root sheath cells appear as clear cells with routine histological stains as they are rich in glycogen.

The ORS does not consist of a homogeneous cell population. Ultrastructural studies have determined at least two distinct cell types in the ORS: (1) Multiple layers of cubical cells located at the outer surface, containing large quantities of glycogen, and (2) A single layer of flattened cells closely associated with the peripheral Henle's layer of the IRS. This single layer, referred by Ito as 'the innermost cell layer of the ORS', was named by Orwin[60] as the 'companion layer' because of its close association with Henle's layer cells. At the level of the companion layer is the slippage plane at which the IRS-packaged hair shaft moves distally up to the skin surface. The companion layer can be followed from the hair bulb up to the isthmus, moving in conjunction with the IRS **(Box 2.15)**. At the end of terminal differentiation, at the upper isthmus level, both the cells

Box 2.15: Companion layer

- The innermost single cell layer of the ORS
- Named by Orwin because of its close association with Henle's layer cells
- Slippage plane at which the IRS-packaged hair shaft moves distally upto the skin surface
- Calretinin, calcium-binding protein is a marker of the companion cell layer
- At the upper isthmus level, both the cells of the IRS and companion layer cornify, degrade and slough in the follicular lumen while other ORS cells undergo trichilemmal keratinization

of the IRS and the companion layer cornify, degrade and slough in the follicular lumen, whereas the ORS cells undergo trichilemmal keratinization. The calcium-binding protein, calretinin is a marker of the companion cell layer of the human hair follicle.[61]

There appear to be two forms of melanocytes in the hair follicle: (1) An amelanotic melanocyte and (2) A dendritic DOPA-positive melanocyte. Distinctive cells believed to be non-functioning amelanotic melanocytes are present along the periphery of the outer root sheath of the human hair follicle.[62] It is believed that DOPA-negative melanocytes in the outer root sheath of the human hair follicle are activated, become identifiable by DOPA staining and migrate into the epidermis during the repigmenting phase of vitiligo. These cells are difficult to identify, however and otherwise have not been characterized. These cells are readily identified by immunofluorescence, immunohistochemistry and immunoelectron microscopy using the antibodies NKI/beteb and A4F11, which recognize premelanosome-related antigens.[63] Noncultured extracted hair follicle outer root sheath cell suspension has been tried in vitiligo.[64]

The trichilemmal keratinization of the outer root sheath starts at the level of isthmus where the inner root sheath disintegrates. At the level of the infundibulum, keratinization of the outer root sheath changes to normal epidermal keratinization.

Hair Shaft (Figure 2.11)

The hair shaft is made up of three cell layers:

1. An outer cuticle
2. The cortex
3. A variable central medulla.

Cuticle (Figure 2.12)

Cuticle is the outermost layer of hair. It is made up of hard, transparent cells that overlap each other like the scales of a fish. It is formed initially as a single cell layer, but the cells become progressively imbricated (tile-like) as they move peripherally. The cells become flattened, and their outer edges point in an upward direction and interlock with the cuticle of the surrounding inner root sheath. In the fully formed hair shaft, the cuticle consists of 5–10 overlapping cell layers, each 350–450 nm thick. The cuticle cells may be elongated, acuminate (gradually tapering to a point), ovate (egg shaped), or flattened. Although the cuticle is the outermost layer of the hair, it does not give the hair its color because it has no melanin, which is found in the cortex.

Under electron microscopy, the mature cells of the cuticle consisting of compact cuticular keratin associated with ultra-high sulfur proteins show three distinct layers:

a. The outer a-layer, which is particularly rich in cysteine.
b. The exocuticle (also cysteine-rich). The exocuticle lies closer to the external surface and comprises of three parts; the b-layer, the a-layer and the epicuticle. The a- and b-layers are largely proteinaceous. The epicuticle is a hydrophobic lipid layer of 18-methyloctanoic acid on the surface of the fiber, or the f-layer **(Box 2.16)**.[51]
c. The inner endocuticle is virtually devoid of sulfur and has an irregular substructure of membrane-like elements which are probably the remnants of cytoplasmic structures.[65]

The cuticle has a smooth appearance and has important protective properties by limiting friction between the hair shafts, responsible for the luster, elasticity, resilience and

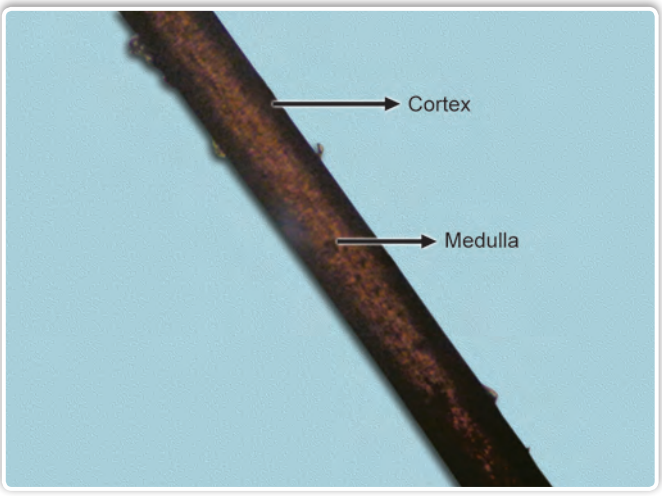

Fig. 2.11: Hair (terminal) shaft under light microscope showing cortex and medulla

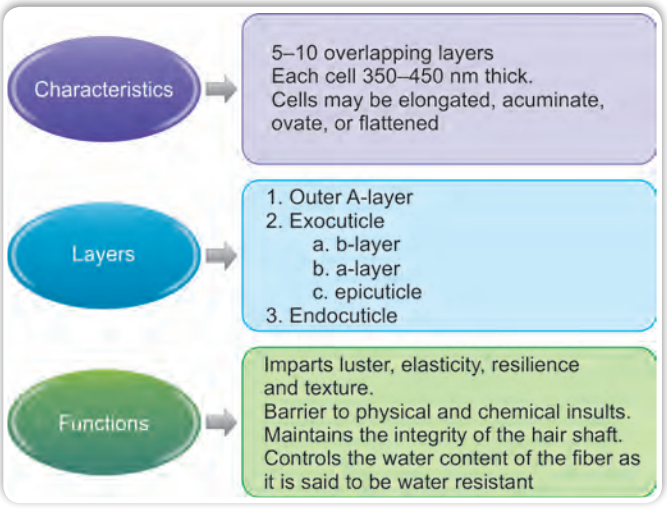

Fig. 2.12: Characteristics of cuticle of outer root sheath

Box 2.16: f- layer

- Epicuticle is a hydrophobic lipid layer of 18-methyloctanoic acid on the surface of the fiber, or the f-layer
- Chemical removal of the f-layer by oxidation eliminates the first hydrophobic defense and leaves hair more porous and vulnerable

texture, acts as a barrier to physical and chemical insults, also maintains the integrity of the hair shaft. The cuticle represents the structure that controls the water content of the fiber as it is said to be water resistant.

Brushing, using heat (like using curling irons) or chemical processing (like perms or texturizers), environmental factors such as the sun or wind can bring about wear and tear leading to gradual degradation of the cuticle which is called as' weathering', with breaking and lifting of the free margins of cuticular cells. Chemical removal of the f-layer particularly by oxidation eliminates the first hydrophobic defense and leaves the hair more porous and vulnerable. Cuticle disruption with alkaline chemicals is the first step in permanent hair styling.[22] This eventually leads to exposure of the cortex and fracture of the hair shaft resulting in dull lusterless hair.

Cortex (Figure 2.13)

Cortex forms the middle layer and makes for 90% of the hair's weight. The cortex is hydrophilic. As the cortical cells move upward they lose their nuclei and become more fusiform in shape. They develop a dense filamentous cytoskeleton in the upper hair bulb and become fully hyalinized in the suprabulbar region and they do not contain any keratohyaline or trichohyaline granules. The keratin of the cortex is hard in contrast to the soft keratin of IRS or epidermis. The cortex consists of closely packed spindle-shaped cortical cells rich in keratin filaments that are oriented parallel to the long axis of the hair shaft[66] and an amorphous matrix of high sulfur proteins. The intermediate filament hair keratin (40–60kDa), comprising 400–500 amino acid residues in heptad sequence repeats, form hard keratin polypeptide chains that pair together to form protofilaments, which make up a keratin chain.[22] The keratin chains have a large number of sulfur containing cysteine residues. Cysteine residues in the adjacent keratin filaments form covalent disulfide bonds, which create strong cross links between adjacent keratin filaments. The disulfide bonds confer shape, stability, and resilience to the hair shaft. Other weaker bonds such as van der Waals interactions, hydrogen bonds, and coulombic interactions known as salt links, link the keratin polypeptide chain.[67]

Recent genome analysis have increased the number of identified human keratins to 54; grouped into acidic type 1 and basic to neutral type 2 intermediate filaments, 11 of the 28 type 1 keratin and 6 of 26 type 2 keratin are hair keratin.[23] They are also classified into three major families: high sulfur, ultra-high sulfur and high glycine–tyrosine proteins.[68]

The cortex is responsible for providing hair its structure, strength, color, resistance, elasticity and texture. When the cuticle is damaged the cortex becomes weak and unraveled causing split-ends and damaged hair.

Medulla (Figure 2.14)

Medulla also called the marrow of the hair shaft is a variable structure, which may be continuous, discontinuous or absent. Lanugo and vellus hairs have no medulla. Large-diameter hairs are more likely to contain a medulla. The medulla develops quite abruptly around the upper pole

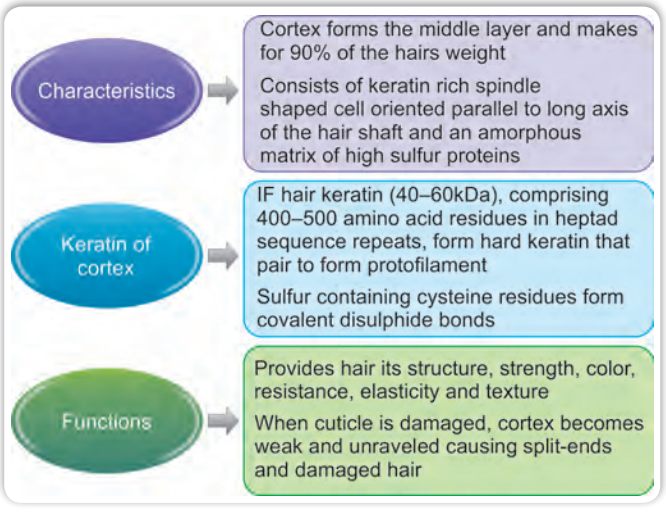

Fig. 2.13: Characteristics of the hair cortex of outer root sheath. IF—Intermediate filaments

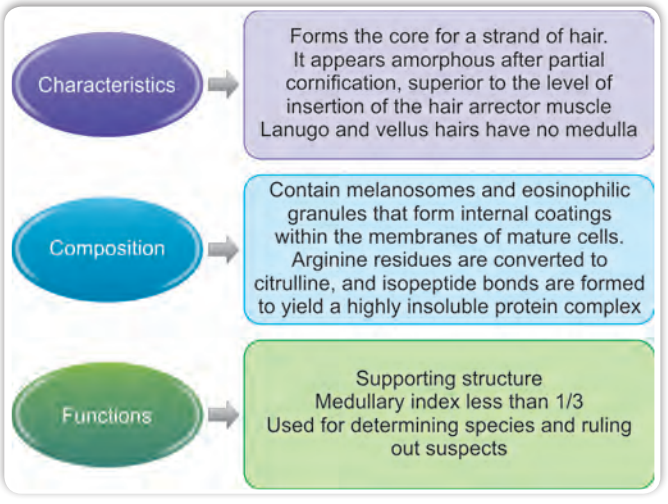

Fig. 2.14: Characteristics, composition and functions of medulla

of the dermal papilla, without any obvious precursor cell population.

When seen by electron microscopy, the medulla appears amorphous after partial cornification, superior to the level of insertion of the hair arrector muscle. The loosely aggregated cells of the medulla contain melanosomes and distinctive eosinophilic granules that eventually form internal coatings within the membranes of mature cells. As these cells develop, arginine residues are converted to citrulline, and isopeptide bonds are formed to yield a highly insoluble protein complex.[69]

It forms the core and is the supporting structure for a strand of hair. Human hairs are unique in that their medullary index (the fraction of the shaft's width that the medulla takes up) is small; generally less than 1/3. Other species will have ratios much larger, usually at least 1/2. Medulla patterns are not very good as individual evidence and are typically only used for determining species and ruling out suspects.[70]

Hair Follicle Innervations

There are two distinct neural networks that surround hair follicle. The first is located around the neck of the follicle just underneath the epidermis and contain sensory C fibers along with sympathetic fiber while the second is located around the permanent mid section of the hair follicle between the isthmus of sebaceous gland and insertion of arrector pili muscle and contain longitudinal A delta fiber and circular C fiber. Both the networks contain sensory nerve fiber, e.g. expressing calcitonin gene related peptide (CGRP) and autonomic nerves expressing choline acetyl transferase (ChAT).[23] Free nerve endings, pilo-Ruffini nerve endings and Merkel nerve endings are also found.[71] It has been postulated that Merkel cell secretions are involved in regulating the hair cycle.[72]

Hair Vasculature

During anagen phase rich vascular network surrounds lower end of the follicle. The network consists of parallel vessels connected by cross shunts extending between bulb and sebaceous gland. At the level of sebaceous gland the network terminate in loose network. The resting hair is supplied by palisade of capillaries connected by short transverse vessels. Vellus hair has very simple capillary system.[23]

Hair Cycle (Figures 2.15 and 2.16)

The hair follicle, a unique characteristic of mammals, represents a stem cell-rich, prototypic neuroectodermal-mesodermal interaction system. This factory for pigmented epithelial fibers is unique in that it is the only organ in the mammalian body which, for its entire lifetime, undergoes cyclic transformations from stages of rapid growth (anagen) to apoptosis-driven regression (catagen) and back to anagen, via an interspersed period of relative quiescence (telogen).[73]

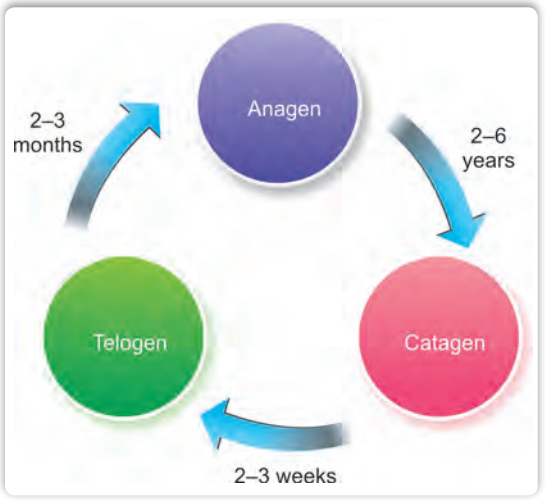

Fig. 2.15: Schematic representation of hair cycle

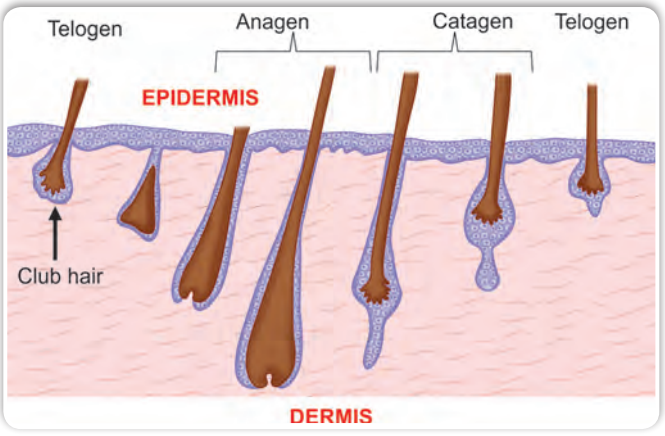

Fig. 2.16: Hair cycle-through anagen, catagen and telogen

Anagen

It is the period of active hair growth and the duration of this phase vary with age, sex and region. The duration of anagen phase determines the final length of the hair. In some hair follicles, such as those on human scalp, anagen may continue for several years, so that very long hairs are produced and in eyebrows and eye lashes, it is restricted to few days to month which explains their short length. At any one time normally 80–90% of hair follicles on the human scalp are in anagen phase.

When a resting hair follicle enters into early anagen phase, mitotic activity begins in the progenitor cells,

for detailed information on dermatology books, visit our website www.jaypeebrothers.com, for detailed information on dermatology books, visit our website www.jaypeebro

Hair and Hair Disorders
Diagnosis & Management

Salient Features

- Text boxes and illustrations in all the chapters to emphasize important points
- The chapters are based on presenting symptoms and signs, differential diagnosis, therapeutics and surgical modalities
- Recent advances in the field of trichology has been covered.



S Sacchidanand MD DVD DHA FRCP (Glasgow) is presently working as Registrar (Evaluation), Rajiv Gandhi University of Health Sciences, Bengaluru, Karnataka, India. He has worked formerly as Professor and Head, Department of Dermatology, STD and Leprosy at Bangalore Medical College and Research Institute, Bengaluru, Karnataka, India. His skills are spread across several domains and he has excelled in teaching, academics, administration, organization and research activities in the last 30 years. He has worked at various levels in Indian Association of Dermatologists, Venereologists and Leprologists (IADVL) and was its Honorary General Secretary (2002–2005) and President during 2008–2009. He has also served as Secretary General of South Asian Regional Association of Dermatologists (SARAD) during 2005–2007 and is currently its Vice-President (2013–2015). He had been Vice-President of Association of Cutaneous Surgeons of India (ACSI, 2011–2013). He is the founder President of Association of Facial Aestheticians and Aesthetic Surgeons of India (AFAASI) and Community Dermatology Society (CDS). He has been a guide to several young postgraduate students of various faculties like Dermatology, Medicine, Pathology, Microbiology, Pharmacology, Community Medicine, Dental and Pharmacy. He has been conferred a Fellowship (FRCP) from the University of Glasgow in 2012. He is a pioneer in starting fellowship courses in Dermatosurgery (2005), Medical Cosmetology (2007), Pediatric Dermatology (2010) and Trichology (2012) at Bangalore Medical College and Research Institute under the aegis of Rajiv Gandhi University of Health Sciences. He has published around 75 articles in indexed journals. He has conducted around 25 conferences so far both at national and international levels (DERMAVISION – 2000, DERMACON –2009 and PHOTOCON, TRICHOCON, ONYCHOCON, FOTOCON, COSMECON and FACETHETICS, etc.). He has authored several chapters in various textbooks and is currently the Chief Editor of the IV Edition of IADVL Textbook of Dermatology. He has edited and co-authored around 12 undergraduate and postgraduate books in dermatology. The present book on *Hair and Hair Disorders* is another addition to his illustrious career.



Savitha AS MD DNB FRGUHS (Dermatosurgery) has completed her undergraduation and postgraduation and her Fellowship in Dermatosurgery from Bangalore Medical College and Research Institute, Bengaluru, Karnataka, India. She is currently working as Senior Resident in the Department of Dermatology, STD and Leprosy at Bangalore Medical College and Research Institute, Bengaluru, Karnataka, India.



Lakshmi DV DVD FRGUHS (Pediatric Dermatology) has completed her graduation from Dr BR Ambedkar Medical College, and postgraduation and her fellowship in Pediatric Dermatology from Bangalore Medical College and Research Institute, Bengaluru, Karnataka, India. She is currently working as Senior Resident in the Department of Dermatology, STD and Leprosy at Bangalore Medical College and Research Institute, Bengaluru, Karnataka, India.

Available at all medical book stores
or buy directly from Jaypee Brothers through online shopping
at www.jaypeebrothers.com

JAYPEE BROTHERS
Medical Publishers (P) Ltd.
www.jaypeebrothers.com

Join us on facebook.com/jaypeebrothers

Shelving Recommendation
DERMATOLOGY

ISBN 978-93-5152-340-6

9 789351 523406