rmation on orthopedic books, visit our website www.jaypeebrothers.com, for detailed information on orthopedic books, visit our website www.jaypeebrothers.com,

JAYPEE

# COMPLEX SPINE CASES

## A Collection of Current Techniques



**Munish C Gupta**
**Alexander Richard Vaccaro**
**Sachin Gupta**

# Contents

## Section 1: Early Onset Scoliosis (EOS)


1. **Congenital Scoliosis Treated with Growing Rods and VEPTR** **3**
   *Lindsay Andras, David Skaggs*
   - Case Reports *3*
   - Case Summaries *7*
   - Discussion *7*

2. **Treatment of Lumbar Congenital Scoliosis with Bilateral Vertical Expandable Prosthetic Titanium Rib (VEPTR) in a Child with Central Core Disease** **10**
   *Koopong Siribumrungwong, Munish C Gupta*
   - Case Presentation *10*
   - Results *11*
   - Discussion *13*

3. **Iatrogenically Fused Ribs and Progressive Early Onset Scoliosis Following Repair of Congenital Diaphragmatic Hernia** **15**
   *George H Thompson, Robert M Campbell, Kaine C Onwuzulike, Connie Poe-Kochert*
   - Clinical Case *15*
   - Case Summary *16*
   - Discussion *18*

4. **Early Onset Scoliosis: Treatment with Dual Growing Rods** **22**
   *Jonatas Sanchez Fernandez, Nima Kabirian, Behrooz A Akbarnia*
   - Clinical Case *22*
   - Case Summary *24*
   - Discussion *26*

5. **Severe Scoliosis in Three Young Children Treated with Shilla** **28**
   *Richard E McCarthy*
   - Clinical Case 1 *28*
   - Clinical Case 2 *30*

6. **Progressive Congenital Kyphoscoliosis Treated with Vertebrectomy and a Posterior Growth Guidance Construct** **33**
   *Peter O Newton*
   - Clinical Case *33*
   - Case Summary *36*
   - Discussion *36*


## Section 2: Pediatric Spinal Deformity


7. **Congenital Scoliosis due to Unilateral Unsegmented Bar and Fused Ribs in Two 1-Year-Old Boys: Two Approaches with Two Different Results at a Mean 35-Year Follow-up** **41**
   *Robert B Winter*
   - Case 1 *41*
   - Case 2 *41*
   - Discussion *42*

8. **Severe Kyphoscoliosis of the High Thoracic Spine with Neurofibromatosis Treated with Traction and Posterior Surgery** 44
*Han Jo Kim, Keith H Bridwell*
- Clinical Case *44*
- Case Summary *45*
- Discussion *45*

9. **A Severe Kyphoscoliosis Deformity Treated by Preoperative Halo-Gravity Traction, Anterior Release Followed by Multilevel Ponte Osteotomies and Posterior Instrumentation** 49
*Ahmet Alanay, H Gökhan Demirkiran*
- Case Presentation *49*
- Discussion *50*

10. **Growing Rods in Neuromuscular Spinal Deformity: Successes and Challenges** 52
*Varun Puvanesarajah, Paul D Sponseller*
- Clinical Cases *52*
- Case Summary *56*
- Discussion *56*

11. **Staged Anterior Release and Posterior Instrumentation for Severe Rigid Adolescent Idiopathic Scoliosis** 58
*Pankaj Kandwal, Arvind Jayaswal*
- Case Study *58*
- Case Summary *60*
- Discussion *60*

12. **Thoracic Adolescent Idiopathic Scoliosis 3-Dimensional Operative Correction** 63
*Baron S Lonner, Courtney Toombs*
- Clinical Case *63*
- Case Summary *64*
- Discussion *64*

13. **Patient with Severe Scoliosis Treated with Intraoperative Traction and Posterior Instrumentation: A Case Presentation** 69
*Meric Enercan, Sinan Kahraman, Azmi Hamzaoglu*
- Clinical Case *69*
- Results *72*
- Case Summary 72
- Discussion 72

14. **Diastematomyelia in Severe Spinal Deformity: Treatment with Vertebral Column Resection** 76
*Elias Dakwar, James T Bennett, Amer F Samdani*
- Clinical Case *76*
- Case Summary *78*
- Discussion *78*

15. **Vertebral Column Resection for Severe Scoliosis with Spina Bifida: A Case Presentation** 81
*Srinivasu Kusuma, Jon Allen, Munish C Gupta*
- Clinical Case *81*
- Treatment *81*
- Case Summary *83*
- Discussion *83*

**16. Posterior Two-Level Vertebral Column Resection for Severe Spinal Deformity: A Case Report** **86**
*Sigurd H Berven, Mohammad Diab, Melissa Esparza*
- Case Report *86*
- Discussion *88*

**17. Late Treatment of Severe Progressive Early Onset Kyphoscoliosis with Halo-Gravity Traction and Posterior Vertebral Column Resection** **91**
*Michael J Faloon, Michael J Mendelow, Oheneba Boachie-Adjei, Munish C Gupta*
- Clinical Case *91*
- Case Summary *95*
- Discussion 95

**18. Total Spine Lordosis in Neuromuscular Disease: Rigid Spine Syndrome** **99**
*Andres Chahin, Catalina Larrain Birrell*
- Clinical Case *99*
- Case Summary *101*
- Discussion *102*

**19. Severe Deformity from Charcot Spine in a Patient with Spinal Cord Injury** **103**
*Randal R Betz*
- Case Report *103*
- Discussion *103*

**20. Thoracolumbar Deformities in Hurler's Syndrome Treated by Posterior Instrumented Fusion** **107**
*Carlos Villanueva, Mariano Reynier*
- Clinical Case 1 *108*
- Clinical Case 2 *108*
- Discussion *108*

**21. High-Grade Spondylolisthesis Treated with Transfixation** **111**
*Jon Allen, Srinivasu Kusuma, Munish C Gupta*
- Case Summary *112*
- Discussion *112*

**22. A Case of High Dysplastic Spondylolisthesis** **117**
*Harry L Shufflebarger*
- Case Summary *117*
- Results and Outcomes *121*

## Section 3: Adult Spinal Deformity

**23. Adult Scoliosis Treated with Anterior and Posterior Spinal Fusion: Two Cases** **125**
*Pirkka Mäkelä*
- Case 1: An Adult Degenerative Scoliosis *125*
- Case 2: An Unusual Complication—Adult Idiopathic and Degenerative Scoliosis *125*

**24. Severe Scoliosis in an Adult Treated with Posterior Fusion and Transforaminal Lumbar Interbody Fusion (TLIF)** **130**
*Jeffrey H Weinreb, Kristina L Bianco, Virginie Lafage, Frank Schwab*
- TLIF and Severe Adult Scoliosis: Case 1 *131*
- TLIF and Severe Adult Scoliosis: Case 2 *134*

**25. Sagittal Plane Deformity Correction in an Adult Patient** **139**
*Charles H Crawford III, Steven D Glassman*
- Clinical and Surgical Report, Case 1 *139*
- Case 1 Summary *141*
- Clinical and Surgical Report, Case 2 *141*
- Case 2 Summary *142*
- Discussion *142*

**26. Postoperative Fixed Lumbosacral Deformity with Sagittal Imbalance** **143**
*Sigurd H Berven, Morsi Khashan*
- Clinical Case *143*
- Case Summary *145*
- Discussion *146*

**27. Sagittal Imbalance due to Focal Kyphotic Deformity in an Adult: Less Invasive Surgical Treatment with Anterior Column Reconstruction (ACR)—A Case Presentation** **148**
*Paul Stanton, Nima Kabirian, Behrooz A Akbarnia*
- Clinical Case *148*
- Case Summary *148*
- Discussion *150*

**28. Less Invasive Anterior Longitudinal Ligament Release: Anterior Column Realignment (ACR) for the Treatment of Adjacent Segment Disease with Iatrogenic Fatback** **151**
*Eric O Klineberg*
- Clinical Case *151*
- Discussion *153*

**29. Post-Traumatic Lumbar Kyphotic Deformity: A Case Presentation** **156**
*Sang Do Kim, Lawrence G Lenke, Jacob M Buchowski*
- Clinical Case *156*
- Case Summary *158*
- Discussion *158*

**30. Treatment of Congenital Thoracic Lordoscoliosis with Posterior Vertebral Column Resection** **161**
*Meric Enercan, Sinan Kahraman, Azmi Hamzaoglu*
- Clinical Case *161*
- Surgical Technique *162*
- Discussion *164*

**31. Complex Spine Deformity Reconstruction using Posterior Vertebral Column Resection and Extensive Multilevel Vertebroplasty** **167**
*Sachin Gupta, Khaled Kebaish*
- Case Report *167*
- Operative Procedure *169*
- Clinical Result *170*
- Discussion *170*

**32. Minimally Invasive Treatment of Adult Scoliosis** **173**
*Michael Y Wang*
- Clinical Case and Discussion *173*
- Intervention and Outcome *174*
- Case Summary *177*

**33. Minimally Invasive Treatment of Degenerative Scoliosis** **178**
*Neel Anand*
- Case Presentation *178*
- Discussion *180*
- Concerns *181*

## Section 4: Trauma and Tumors

**34. Fracture-Dislocation with Incomplete Neurologic Injury: A Case Presentation** **185**
*Srinivasu Kusuma, Jon Allen, Munish C Gupta*
- Clinical Case *185*
- Treatment *186*
- Case Summary *187*
- Discussion *187*

**35. Complex Post-Traumatic Kyphosis and Flatback Deformity Treated by Smith-Petersen Osteotomies: A Case Presentation** **190**
*Purnendu Gupta*
- Clinical Case *190*
- Case Summary *192*
- Discussion *193*

**36. Traumatic Spinal Injury Treated with Minimally Invasive Stabilization** **195**
*Kelley Banagan, Steven C Ludwig*
- Clinical Case *195*
- Case Summary *196*
- Discussion *196*

**37. Complex Reconstruction of the Metastatic Spine Disease** **199**
*Ashish Upadhyay, Charles H Crawford III, John R Dimar II*
- Evaluation *199*
- Surgical Treatment *200*
- Case Summary 1 *201*
- Case Summary 2 *206*
- Discussion *208*

**38. Posterior-Only Resection and Instrumentation for a Tumor** **211**
*Han Jo Kim, Jacob M Buchowski*
- Clinical Case *211*
- Case Summary *214*
- Discussion *214*

## Section 5: Cervical Spine

**39. Ankylosing Spondylitis in the Cervical Spine: Treatment with C7 Pedicle Subtraction Osteotomy—A Case Presentation** **217**
*Justin K Scheer, Vedat Deviren, Christopher P Ames*
- Clinical Case *217*
- Case Summary *219*
- Discussion *219*

**40. Treatment of Malunion Odontoid Type III with Transoral Odontoid Osteotomy and Posterior Atlantoaxial Fixation: A Case Report** **224**
*Koopong Siribumrungwong, Munish C Gupta*
- Case Presentation *224*
- Discussion *224*

**41. Cervical Postlaminectomy Kyphosis, Suprajacent Atlantoaxial Stenosis with Recurrent Myelopathy: Treatment with Combined Posterior and Anterior Osteotomy via Posterior-Anterior-Posterior Approach** **230**
*Christopher Chambliss Harrod, Todd J Albert*
- Clinical Case *230*
- Case Summary *234*
- Discussion *234*

**42. Fixed Atlantoaxial Dislocation with Cord Compression: Treatment with C1-C2 Joint Distraction: A Case Presentation** **238**
*Luis Eduardo Carelli Teixeira da Silva, Gustavo Borges Laurindo de Azevedo, Bernardo JM Chaves*
- Clinical Case *238*
- Surgical Technique *238*
- Case Summary *241*
- Discussion *241*

**43. Complex Ankyloses of the Spine in a Teenager: Treatment with a Pedicle Subtraction Osteotomy—A Case Presentation** **245**
*Ilkka Helenius, Munish C Gupta*
- Clinical Case *245*
- Case Summary *247*
- Discussion *247*

*Index* *251*

CHAPTER

2

# Treatment of Lumbar Congenital Scoliosis with Bilateral Vertical Expandable Prosthetic Titanium Rib (VEPTR) in a Child with Central Core Disease

*Koopong Siribumrungwong, Munish C Gupta*

## CASE PRESENTATION

A 2-year-old girl presented with scoliosis without back pain. She was noticed to have truncal asymmetry by her parents. She had a history of proximal muscle weakness and mild hypotonia. Muscle biopsy was performed, which was consistent with central core disease. She had received occupational and hydrotherapy previously. Her family history was negative for scoliosis. The physical examination showed an asymmetrical waist, pelvic obliquity and torso decompensation without midline skin abnormalities. The shoulder was elevated on the left side (Fig. 1). Pathological reflexes such as ankle clonus and Babinski's signs were normal. Radiographic evaluation on the sitting position (Figs. 2A and B) revealed a left lumbar scoliosis of 115° due to two unilateral congenital bars involving T12–L2 and L3–L4 and a right thoracic scoliosis of 50°. The convex side had normal ribs and good vertebral development. Lateral plain radiography revealed a thoracic kyphosis of 38° and a lumbar lordosis of 45°. The remainder of the spine appeared normal, both proximal and distal to the involved area. Traction film was used to evaluate the flexibility of the curve. After traction, the Cobb angle was reduced to 75°, which represented some flexibility at the lumbar curve (Fig. 3). Magnetic resonance imaging (MRI) of the entire spine was performed as a screening test for neural axis abnormalities and showed no spinal dysraphism.

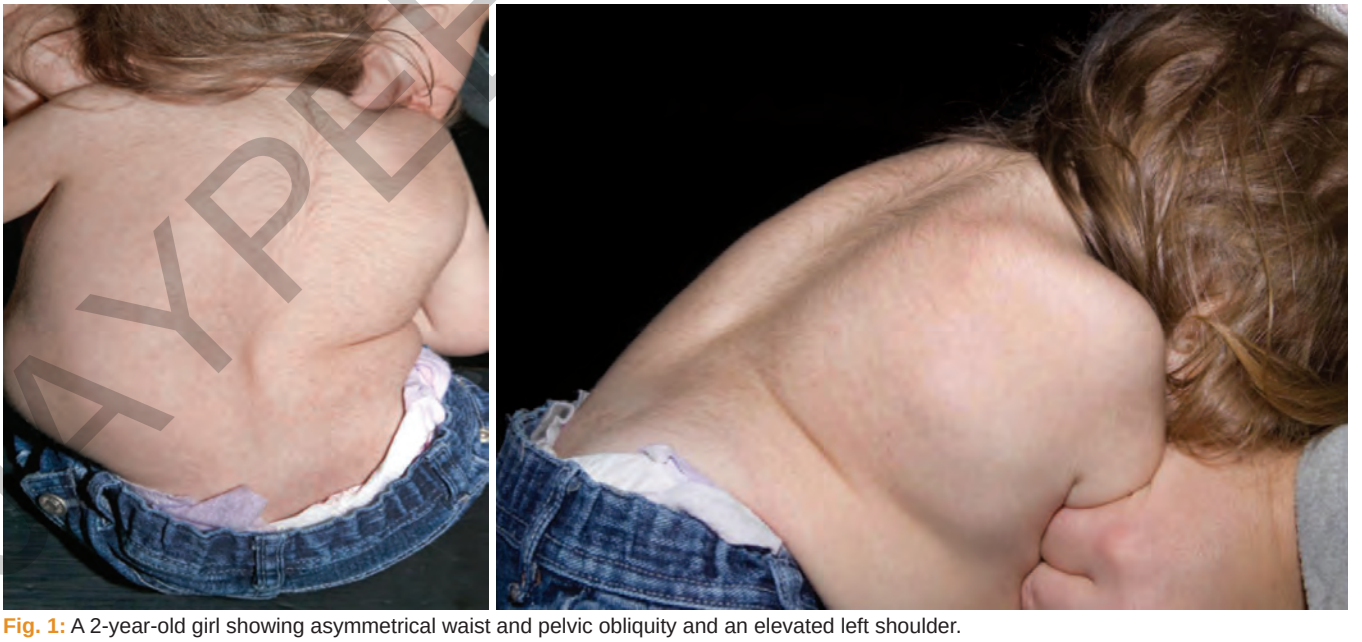

**Fig. 1:** A 2-year-old girl showing asymmetrical waist and pelvic obliquity and an elevated left shoulder.

JAYPEE BROTHERS

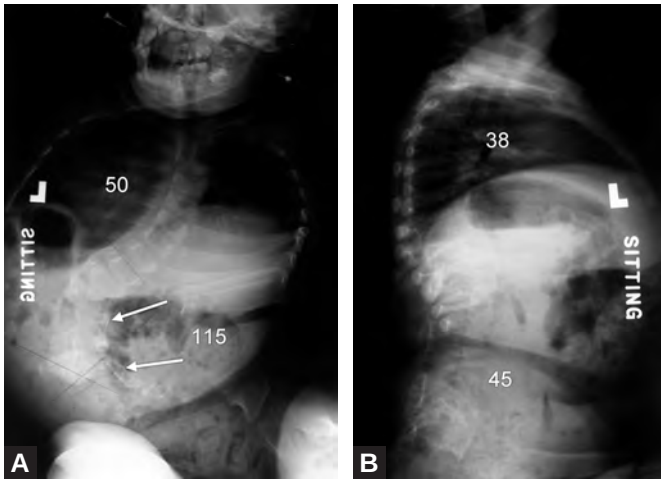


**Figs. 2A and B:** Plain radiography of thoracolumbar spine in the anteroposterior (A) and lateral (B) view showing left lumbar scoliosis of 115° due to two unilateral congenital bars (white arrows) involving T12–L2 and L3–L4 vertebrae.

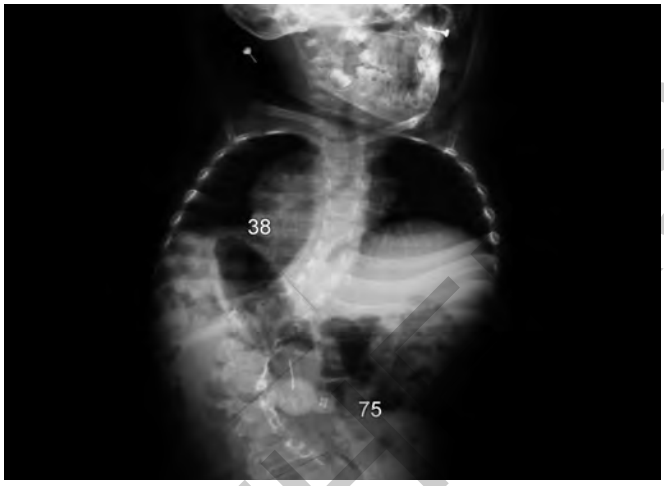


**Fig. 3:** Plain radiography of the thoracolumbar spine in traction view showing the Cobb angle reduced to 75° after traction.

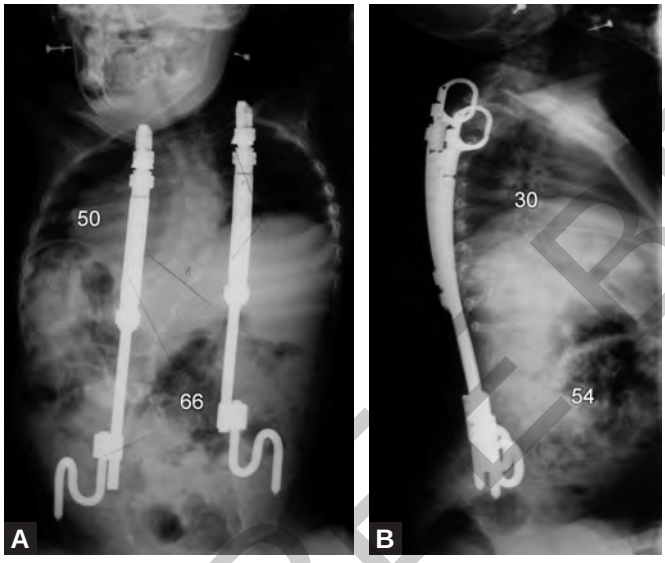


**Figs. 4A and B:** Plain radiography of the postoperative thoracolumbar spine in the anteroposterior (A) and lateral (B) view showing bilateral placement of VEPTR with improvement in the Cobb angle.

Because of the known prognosis of unilateral congenital bar formation and severe degree of the Cobb angle, surgery was planned. At the age of 30 months, she underwent placement of a bilateral vertical expandable prosthetic titanium rib (VEPTR; Synthes, Westchester, PA). The patient was positioned prone on the operating table. A single midline incision was performed and was dissected laterally over the ribs. The bilateral superior rib anchor sites were prepared at the upper thoracic ribs and superior cradles attached. Then other incisions were made just lateral to the posterior superior iliac spine for placement of the S-hook bilaterally. The ribs and ilium attachment sites were connected through a submuscular tunnel (Figs. 4A and B). Intraoperative neurological monitoring included somatosensory evoked potentials and motor evoked potentials. A gradual lengthening was performed every 6 months for a total of 13 times.

## RESULTS

Preoperative Cobb angles at the thoracic and lumbar spine were 115° and 50°, respectively. The lumbar Cobb angle was corrected to 66° immediately postoperatively, and this correction was maintained; at the most recent follow-up, the lumbar curve was 57° (Figs. 5A and B). Clinical presentation after surgery showed improved asymmetrical waist, pelvic obliquity and shoulder imbalance (Fig. 6). The preoperative thoracic kyphosis (T2–T12) angle measured 38° preoperatively, 30° immediately postoperatively and 34° at the most recent follow-up evaluation. Similarly, the preoperative lumbar lordosis (L1–S1) angle measured 45° preoperatively, 54° immediately postoperative and 46° at the most recent follow-up evaluation. Total spine length (T1–S1) increased from 196 mm preoperatively to 220 mm immediately postoperatively, and to 260 mm at the last follow-up evaluation. Thoracic spine length (T1–T12) increased from 115 mm preoperatively to 128 mm immediately postoperatively, and to 150 mm at the last follow-up evaluation. No serious complications were observed.

JAYPEE BROTHERS

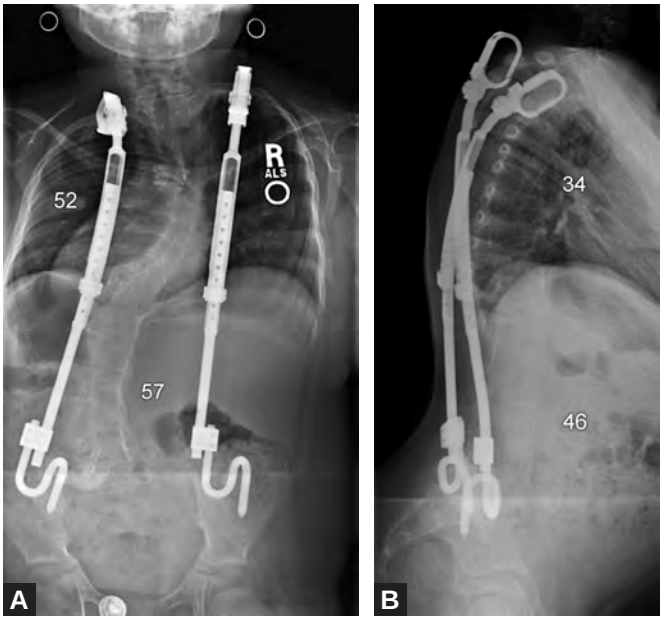


**Figs. 5A and B:** Plain radiography of the postoperative thoracolumbar spine in the anteroposterior view at the last follow-up (A) and lateral (B) view showing bilateral placement of VEPTR showing maintained of Cobb angle correction.




**Fig. 6:** Clinical presentation after surgery showing improved asymmetrical waist, pelvic obliquity and shoulder imbalance.

JAYPEE BROTHERS

## DISCUSSION

A rare case of central core disease with congenital scoliosis from the formation of two unilateral bars at the lumbar spine was observed. Central core disease, also known as central core myopathy, is an inherited neuromuscular disorder characterized by the appearance of a myofibril under the microscope.[1] The clinical aspects of central core disease can vary in severity. Clinical presentation usually involves hypotonia at birth and delayed child development and is characterized by predominantly proximal weakness pronounced in the hip girdle.[2,3] The diagnosis is made by the combination of typical clinical findings and the characteristic appearance on the muscle biopsy. Central core disease is usually inherited by the autosomal dominant pattern of inheritance. Most of the cases have demonstrable mutations in the ryanodine receptor type 1 (RYR1) gene,[4] which is usually newly developed. One of the most important complications in central core disease is malignant hyperthermia susceptibility during general anesthesia[3] due to mutations in the RYR1 gene, which encodes the skeletal muscle sarcoplasmic reticulum calcium channel release. Change in calcium regulation within the muscle cells due to mutation is considered to be the main mechanism responsible for causing malignant hyperthermia.[2]

Central core disease can cause neuromuscular scoliosis from muscle weakness and hypotonia, but in this case a congenital cause from the two ipsilateral unilateral bars was found. Treatment of congenital scoliosis with unilateral unsegmented bars remains a surgical challenge. Bracing is rarely indicated because it usually does not affect progression of the congenital curve.[5] Continued efforts of bracing may cause chest wall deformities in children.[6] Surgery is performed if there is curve progression, or as in this case, the severe curve is predicted to have a high risk of progression.[5] Due to the high association between congenital scoliosis and spinal dysraphism, MRI should be done in any child with congenital scoliosis who is to undergo surgery. Some studies showed that the incidence of spinal dysraphism in congenital scoliosis was as high as 32–37%.[7,8]

The principles of management of congenital scoliosis are to improve and prevent progression of spinal deformity, obtain a balanced spine and avoid or limit early spinal fusion. The surgical management of congenital scoliosis with unilateral unsegmented bar is still controversial. There are many types of fusion surgery such as in situ fusion (posterior only, combined anterior and posterior approach as for the prevention of crankshaft phenomenon),[9,10] correction and fusion with instrumentation for flexible curve and reconstructive osteotomies and instrumentation for rigid curve.[11] But fusion of the spine in very young child may lead to stunting of trunk height and also affect pulmonary function.[12] Therefore, fusionless instrumentations seem to be useful in controlling spinal deformity. Fusionless surgery also avoids fusion complications of growth and development of chest cage and the spine. Fusionless instrumentation systems or growth-friendly implants were categorized into three types based upon the forces of correction the implants exert on the spine: distraction-based system (i.e. growth rods, VEPTR), compression-based system (i.e. staples, tethers) and guided growth system (i.e. Luque trolley, Shilla).[13]

VEPTR is frequently used to treat young children with thoracic insufficiency syndromes related to congenital spine and rib anomalies.[14,15] The Federal Drug Administration approved VEPTR for the management of progressive scoliosis with "thoracic insufficiency" under humanitarian device exemption.[16] A multicenter study by John M. Flynn and others showed VEPTR insertion with expansion thoracoplasty to represent a successful treatment paradigm for nonsyndromic congenital spinal deformities in the thoracic spine.[17] But in this study, VEPTR insertion was performed for the treatment of congenital scoliosis from congenital bar formation at the lumbar spine. The Cobb angle at the main lumbar curve was corrected from 115° to 66°, and the correction was maintained to 57° at the last follow-up visit while the thoracic kyphosis and lumbar lordosis were maintained at anatomical normal values. The total spine was increased from 196 to 220 mm immediately after surgery which coming from Cobb correction at the first time expansion. After that the total spine height was increased from 220 to 260 mm during 36 months. The challenges of VEPTR, as demonstrated by previous studies, included device migration, skin complications and multiple procedures.[18–21] No serious complications were reported in this case.

## CONCLUSION

VEPTR can be used in the treatment of lumbar congenital scoliosis. This case demonstrates the treatment of lumbar congenital scoliosis with VEPTR in a child with central core disease. VEPTR can provide excellent Cobb angle correction and spine growth in a child.

JAYPEE BROTHERS

## REFERENCES


1. Dubowitz V, Pearse AG. Oxidative enzymes and phosphorylase in central-core disease of muscle. Lancet. 1960;2:23–4.
2. Heinz J. Central core disease. Orphanet J Rare Dis. 2007; 2:25–33.
3. Quinlivan RM, Muller CR, Davis M, et al. Central core disease: clinical, pathological, and genetic features. Arch Dis Child. 2003;88:1051–5.
4. Robinson RL, Brooks C, Brown SL, et al. RYR1 mutations causing central core disease are associated with more severe malignant hyperthermia in vitro contracture test phenotypes. Hum Mutat. 2002;20:88–97.
5. Hedequist D, Emans J. Congenital scoliosis. J Am Acad Orthop Surg. 2004;12:266–75.
6. Winter RB, Moe JH, MacEwen GD, et al. The Milwaukee brace in the nonoperative treatment of congenital scoliosis. Spine. 1976;1:85–96.
7. Basu PS, Elsebaie H, Noordeen MH. Congenital spinal deformity. A comprehensive assessment at presentation. Spine. 2002;27:2255–9.
8. Suh SW, Sarwark JF, Vora A, et al. Evaluating congenital spine deformities for intraspinal anomalies with magnetic resonance imaging. J Pediatr Orthop. 2001;21:525–31.
9. Winter RB, Moe JH, Lonstein JE. Posterior spinal arthrodesis for congenital scoliosis: an analysis of the cases of two hundred and ninety patients, five to nineteen years old. J Bone Joint Surg Am. 1984;66:1188–97.
10. Terek RM, Wehner J, Lubicky JP. Crankshaft phenomenon in congenital scoliosis: a preliminary report. J Pediatr Orthop. 1991;11:527–32.
11. Li C, Fu Q, Zhou Y, et al. Surgical treatment of severe congenital scoliosis with unilateral unsegmented bar by concave costovertebral joint release and both-ends wedge osteotomy via posterior approach. Eur Spine J. 2012;21: 498–505.
12. Vitale MG, Matsumoto H, Bye MR, et al. A retrospective cohort study of pulmonary function, radiographic measures, and quality of life in children with congenital scoliosis: an evaluation of patient outcomes after early spinal fusion. Spine (Phila Pa 1976). 2008;33:1242–9.
13. Skaggs DL, Akbarnia BA, Flynn JM, et al. A classification of growth friendly spine implants. J Pediatr Orthop. 2013; [Epub ahead of print].
14. Campbell RM Jr, Smith MD, Mayes TC, et al. The effect of opening wedge thoracostomy on thoracic insufficiency syndrome associated with fused ribs and congenital scoliosis. J Bone Joint Surg Am. 2004;88-A:1659–74.
15. Emans JB, Caubet JF, Ordonez CL, et al. The treatment of spine and chest wall deformities with fused ribs by expansion thoracostomy and insertion of vertical expandable prosthetic titanium rib: growth of thoracic spine and improvement of lung volumes. Spine (Phila Pa 1976). 2005;30:58–68.
16. Federal Drug Administration. Summary of safety and probable benefit data: vertical expandable prosthetic titanium rib (VEPTR). Available at: http:// www.accessdata.fda.gov/cdrh_docs/pdf3/ H030009b.pdf. Accessed September 26, 2011.
17. Flynn JM, Emans JB, Smith JT, et al. VEPTR to treat nonsyndromic congenital scoliosis: a multicenter, mid-term follow-up study. J Pediatr Orthop. 2013;33:679–84.
18. Ramirez N, Flynn JM, Serrano JA, et al. The vertical expandable prosthetic titanium rib in the treatment of spinal deformity due to progressive early onset scoliosis. J Pediatr Orthop B. 2009;18:197–203.
19. Hasler CC, Mehrkens A, Hefti F. Efficacy and safety of VEPTR instrumentation for progressive spine deformities in young children without rib fusions. Eur Spine J. 2010;19:400–8.
20. Samdani AF, St Hilaire T, Emans JB, et al. The usefulness of VEPTR in the older child with complex spine and chest deformity. Clin Orthop Relat Res. 2010;468:700–4.
21. Latalski M, Fatyga M, Gregosiewicz A. Problems and complications in VEPTR-based treatment. Ortop Traumatol Rehabil. 2011;13:449–55.


JAYPEE BROTHERS

for detailed information on orthopedic books, visit our website www.jaypeebrothers.com, for detailed information on orthopedic books, visit our website www.jaypee

# COMPLEX SPINE CASES

## A Collection of Current Techniques

This book is a collection of current techniques used to treat complex spine conditions. The format is easy-to-read case studies highlighting tips from the author. The authors include top surgeons from around the globe.



**Munish C Gupta** MD graduated from Northwestern University Honors Program in Medical Education where he received his Bachelors and Medical Degree in Chicago. He did his Orthopedic Residency training at Northwestern and Spine Fellowship at Leatherman Spine fellowship in Louisville, Kentucky. He has been in practice for the last 22 years developing expertise in the treatment of pediatric and adult spinal deformity. He is currently a Professor, Vice Chairman of the Department of Orthopedic surgery and Chief of Spine service at University of California at Davis. He is also the Director of Spine at the Shriners Hospital of Northern California. He is currently the treasurer of Federation of Spine Association and member of the Board of Directors of the Scoliosis Research Society. He has a passion for teaching students, residents and fellows. He has also volunteered in many countries including Ghana, China and India. He has numerous peer-reviewed articles and non-peer reviewed publications.



**Alexander Richard Vaccaro** MD PhD graduated Summa Cum Laude from Boston College in 1983 with a BS in Biology. He received his MD degree from Georgetown University School of Medicine where he was promoted with "Distinction". He earned membership in the Alpha Omega Alpha (AOA) Honor Society and graduated with honors in 1987.

He completed a year of Surgical Internship at Cedars-Sinai Medical Center in Los Angeles, California and his Orthopedic Surgery Residency was at Thomas Jefferson University where he graduated in 1992. Dr Vaccaro completed a Spine Fellowship at the University of San Diego, California. He earned a PhD in 2007 in the field of Spinal Trauma.

Dr Vaccaro is Richard H Rothman Professor and Chairman, Department of Orthopedic Surgery, Professor of Neurosurgery, Co-Director, Delaware Valley Spinal Cord Injury Center, Co-Chief of Spine Surgery, Sidney Kimmel Medical Center at Thomas Jefferson University and President, Rothman Institute, Philadelphia, Pennsylvania, USA. He was the recipient of the Leon Wiltse Award given for excellence in leadership and clinical research for spine care by the North American Spine Society (NASS). He is the past President of the American Spinal Injury Association and current President of the Association for Collaborative Spine Research.

He has over 560 peer-reviewed and 189 non-peer reviewed publications. He has published over 300 book chapters. He is the editor of over 47 textbooks and co-editor of OKU-Spine 1 and editor of OKU-8. Dr Vaccaro is the Co-Fellowship Director of the Spinal Service at Thomas Jefferson University Hospital where he instructs current fellows and residents in the diagnosis and treatment of various spinal problems and disorders.



**Sachin Gupta** BS is a medical student at The George Washington University. He has volunteered in hospitals around the world, in countries such as Ghana and Argentina. In the future, he hopes to pursue an academic career in medicine, where he can publish, teach, and perform surgery.

**Shelving Recommendations**
ORTHOPEDICS
NEUROSURGERY
SPINE

**Available at all medical bookstores or buy online at www.jaypeebrothers.com or www.jpmedpub.com**

**JAYPEE BROTHERS**
**Medical Publishers (P) Ltd.**
**www.jaypeebrothers.com**

Join us on facebook.com/JaypeeMedicalPublishers

ISBN 978-93-5152-386-4

9 789351 523864