ne books, visit our website **www.jaypeebrothers.com,** for detailed information on medicine book

MANUAL OF ICU PROCEDURES

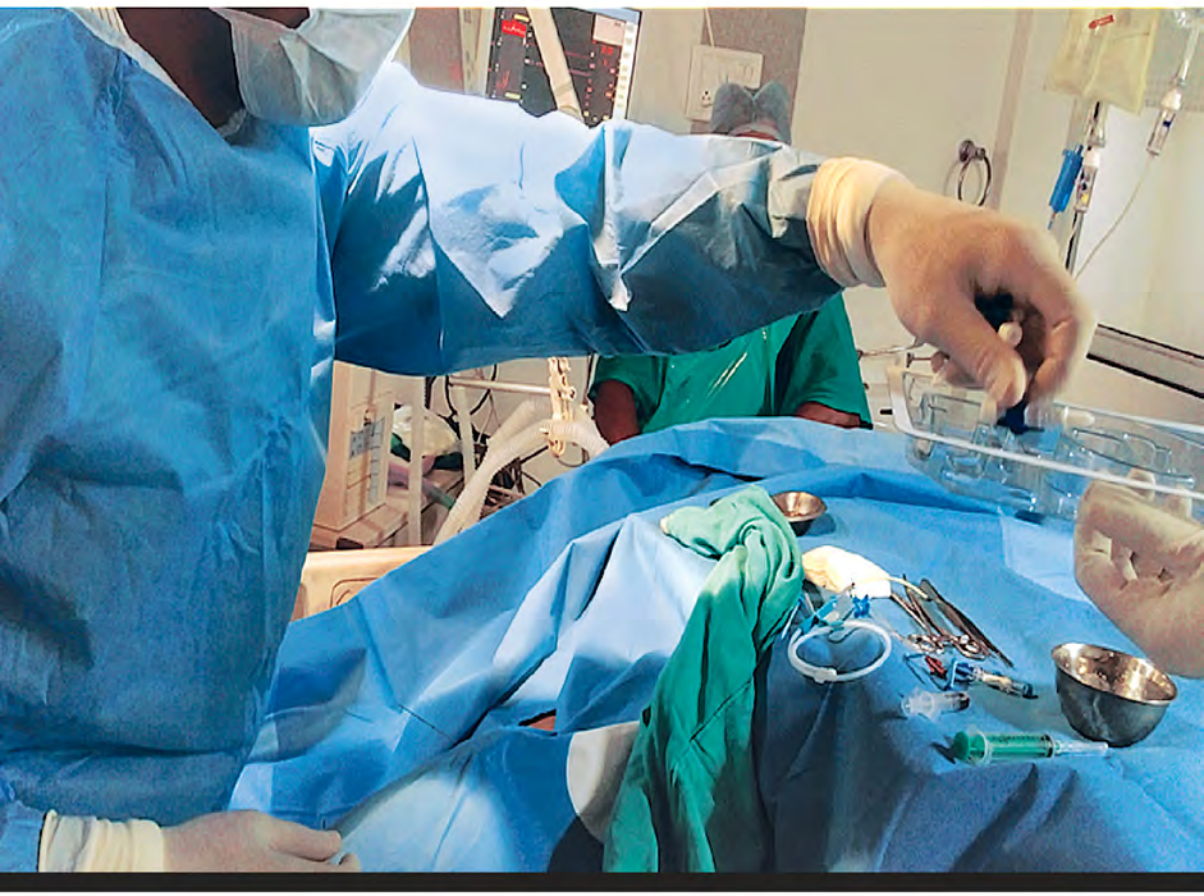

Editor
Mohan Gurjar

Foreword
Arvind Kumar Baronia

JAYPEE

Contents

Section 1 Airway and Respiratory Procedures

1. Bag-Mask Ventilation 3
Ravinder Kumar Pandey, Rakesh Garg, V Darlong

Indication *3* • Contraindication *4* • Applied Anatomy and Physiology *4* • Technique and Equipment *5* • Preparation *8* • Procedure *11* • Complication/Problem *15*

2. Endotracheal Intubation 17
Pradeep Bhatia

Indication *17* • Contraindication *17* • Applied Anatomy *18* • Technique and Equipment *18* • Preparation *20* • Procedure *24* • Post-procedure Care *27* • Complication/Problem *27*

3. Laryngeal Mask Airway Insertion 30
Neeta Bose

Indication *30* • Contraindication *30* • Applied Anatomy *31* • Technique and Equipment *31* • Preparation *40* • Procedure *41* • Post-procedure Care *45* • Complication/Problem *46*

4. Fiberoptic Intubation 49
Amol Kothekar, JV Divatia

Indication *49* • Contraindication *50* • Applied Anatomy *50* • Technique and Equipment *50* • Preparation *53* • Procedure *56* • Post-procedure Care *59* • Complication/Problem *59*

5. Video Laryngoscopy 62
Manish Paul, Banani Poddar

• Indication *62* • Contraindication *63* • Technique and Equipment *63* • Preparation *64* • Procedure *65* • Complication/Problem *68*

6. Double Lumen Endotracheal Tube Placement 71
Kamal Kishore

Indication *71* • Contraindication *71* • Applied Anatomy *72* • Technique and Equipment *72* • Preparation *73* • Procedure (For Left-Sided Double Lumen Tube) *74* • Post-procedure Care *76* • Complication/Problem *76*

7. Cricothyroidotomy 78
Kapil Dev Soni, Sanjeev Bhoi

Indication *78* • Contraindication *78* • Applied Anatomy *79* • Technique *80* • Preparation *80* • Procedure *81* • Post-procedure Care *88* • Complication/Problem *89*

8. Percutaneous Tracheostomy **90**
Devendra Gupta

Indication *90* • Contraindication *90* • Applied Anatomy *91*
• Technique and Equipment *92* • Preparation *102* • Procedure *103*
• Post-tracheostomy Care *110* • Complication/Problem *112*

9. Surgical Tracheostomy **117**
Kranti Bhavana, Amit Keshri

Functions and Indications of Tracheostomy *117* • Contraindication *119*
• Applied Anatomy *119* • Technique and Equipment *120* • Preparation *122*
• Procedure *122* • Post-procedure Care *125* • Complication/Problem *126*

10. Bronchoscopy **129**
Ravindra M Mehta, Rohan Aurangabadwalla

Indication *129* • Contraindication *132* • Anatomical Details and
Physiological Considerations *133* • Technique and Equipment *135*
• Preparation *137* • Procedure *139* • Post-procedure Care *142*
• Complication/Problem *144*

11. Bronchoalveolar Lavage (BAL) and Mini-BAL **146**
Sanjay Singhal

Indication *146* • Contraindication *147* • Technique *147* • Preparation *148*
• Procedure *150* • Post-procedure Care *151* • Complication/Problem *152*

12. Thoracentesis **153**
Pralay K Sarkar

Indication *153* • Contraindication *153* • Applied Anatomy *153*
• Technique and Equipment *154* • Preparation *155* • Procedure *157*
• Post-procedure Care *161* • Complication/Problem *161*

13. Tube Thoracostomy **163**
VN Maturu, Ritesh Agarwal

Indication *163* • Contraindication *164* • Applied Anatomy *165*
• Technique and Equipment *167* • Preparation *172* • Procedure *172*
• Post-procedure Care *180* • Complication/Problem *181*

14. Non-invasive Ventilation for Acute Respiratory Failure **187**
Raj Kumar Mani, Prashant Saxena

Indications of Non-invasive Ventilation *187* • Contraindications of
Non-invasive Ventilation *188* • Technique and Basic Principles of
Non-invasive Ventilation *188* • Preparation for Non-invasive Ventilation *194*
• Starting, Monitoring and Weaning of Non-invasive Ventilation *196*
• Complications of Non-invasive Ventilation *198*

15. Aerosol Drug Delivery **200**
Sanjay Singhal, Mohan Gurjar

Indications for Uses of Aerosol Therapy *200* • Contraindication *200*
• Principles of Aerosol Therapy *200* • Preparation *205*
• Procedures for Delivering Aerosol Therapy *205* • Post-procedure Care *208*
• Complication and Preventive Measures *209*

16. Prone Positioning **210**
Puneet Khanna, Girija Prasad Rath

Indication *210* • Contraindication *210* • Applied Anatomy and Pathophysiology *211* • Clinical Aspect and Technique *212* • Preparation *214* • Procedure *215* • Post-procedural Care *215* • Complication/Problem *216*

17. Manual Chest Physiotherapy in Ventilated Patients **218**
Rajendra Kumar

Indication *218* • Contraindication *219* • Applied Anatomy *219* • Technique *221* • Preparation *225* • Procedure *225* • Post-procedure Care *231* • Complication/Problem *232*

Section 2 Vascular and Cardiac Procedures

18. Venous Cannulation: Peripheral **237**
Nikhil Kothari, Arun Sharma

Indication *237* • Contraindication *237* • Applied Anatomy *238* • Technique and Equipment *239* • Preparation *241* • Procedure *241* • Post-procedure Care *242* • Complication/Problem *243*

19. Venous Cannulation: Central Venous Catheter **246**
Afzal Azim, Abhishek Kumar

Indication *246* • Contraindication *246* • Applied Anatomy *247* • Technique and Equipment *247* • Preparation *253* • Procedure *253* • Post-procedure Care *258* • Complication/Problem *258*

20. Venous Cannulation: Peripherally Inserted Central Catheter **261**
Vandana Agarwal, Atul P Kulkarni

Indication *261* • Contraindication *261* • Applied Anatomy *261* • Technique and Equipment *262* • Preparation *263* • Procedure *264* • Post-procedure Care *265* • Complication/Problem *266*

21. Tunneling of Central Venous Catheter **268**
Dharmendra Bhadauria, Vivek Ruhela

Indication *268* • Contraindication *268* • Applied Anatomy *269* • Technique and Equipment *270* • Preparation *270* • Procedure *271* • Complication/Problem *272*

22. Intraosseous Cannulation **276**
Nishant Verma, Rakesh Lodha

Indication *276* • Contraindication *276* • Applied Anatomy *277* • Technique and Equipment *277* • Preparation *279* • Procedure *280* • Post-procedure Care *286* • Complication/Problem *287*

23. Umbilical Vascular Catheterization **288**
Kirti M Naranje, Banani Poddar

Indication *288* • Contraindication *289* • Applied Anatomy *289* • Technique and Equipment *289* • Preparation *292* • Procedure *293* • Post-procedure Care *296* • Complication/Problem *296*

24. Arterial Blood Sampling and Cannulation **298**
Afzal Azim, Saurabh Saigal

Indication *298* • Contraindication *299* • Applied Anatomy *299*
• Technique and Equipment *299* • Preparation *302* • Procedure *303*
• Post-procedure Care *307* • Complication/Problem *308*

25. Pulmonary Artery Catheterization **309**
Puneet Goyal

Indication *309* • Contraindication *310* • Applied Anatomy *310*
• Technique and Equipment *311* • Preparation *312* • Procedure *314*
• Post-procedure Care *320* • Complication/Problem *320*

26. Transducer and Pressure Monitoring **322**
Jyoti Narayan Sahoo

Indication *322* • Technique and Basic Principles of Pressure Transducer *323*
• Transducer Preparation and Pressure Measurement *328*
• Troubleshooting *333*

27. Pericardiocentesis **336**
Jugal Sharma, Aditya Kapoor

Indication *336* • Contraindication *336* • Applied Anatomy and Physiology *336*
• Technique *338* • Preparation *339* • Procedure *340*
• Post-procedure Care *343* • Complication/Problem *344*

28. Electrical Cardioversion **345**
Saurabh Taneja, Sumit Ray

Indication *345* • Contraindication *345* • Applied Physiology and Anatomy *346*
• Technique and Equipment *346* • Preparation *349* • Procedure *350*
• Post-procedure Care *350* • Complication/Problem *352*

29. Temporary Cardiac Pacing **353**
Saswata Bharati, Nirvik Pal, Devesh Dutta

Indication *353* • Contraindication *354* • Technique and Basic Principles *355*
• Preparation *362* • Procedure *362* • Post-procedure Care *364*
• Complication/Problem *365*

30. Intra-aortic Balloon Pump Counterpulsation **367**
Virendra K Arya

Indication *367* • Contraindication *368* • Technique: Basic Principles *368*
• Technique: Insertion and Operation *374* • Main Points of Care *380*
• Weaning from Intra-aortic Balloon Pump Counterpulsation *381*
• Complication/Problem *381* • Special Situations *382*
• Permanent Intra-aortic Balloon Pump *383*

31. Tourniquet for Vascular Injuries **386**
Sushma Sagar, Kamal Kataria

Indication *386* • Contraindication *386* • Applied Physiology *387*
• Technique *387* • Preparation and Procedure *388*
• Post-procedure Care *389* • Complication/Problem *390*

Section 3 Neurological Procedures

32. Jugular Venous Oximetry **395**
Hemant Bhagat

Indication *395* • Contraindication *395* • Applied Anatomy *395*
• Technique and Basic Principles *396* • Preparation *397*
• Procedure *397* • Post-procedure Care *398*
• Complication/Problem *399*

33. Lumbar Puncture **401**
Bhaskar P Rao, Neha Singh

Indication *401* • Contraindication *402* • Applied Anatomy *402*
• Technique and Equipment *403* • Preparation *408*
• Procedure *408* • Post-procedure Care *411*
• Complication/Problem *412*

34. Epidural Analgesia **415**
Sanjay Dhiraaj

Indication *415* • Contraindication *416* • Applied Anatomy *416*
• Technique and Basic Principles of Epidural Analgesia *417*
• Preparation *421* • Procedure *421* • Post-procedure Care *427*
• Complication/Problem *427*

35. Cranial Burr Hole **430**
Rabi N Sahu, Kuntal Kanti Das, Arun K Srivastava

Indication *430* • Contraindication *430* • Applied Anatomy *431*
• Preparation *431* • Procedure *432* • Post-procedure Care *433*
• Complication/Problem *434*

36. External Ventricular Drainage **435**
Devesh K Singh, Arun K Srivastava, Kuntal Kanti Das, Rabi N Sahu

Indication *435* • Contraindication *436* • Applied Anatomy
and Physiology *436* • Technique and Basic Principles *439*
• Preparation *442* • Procedure *442* • Post-procedure Care *443*
• Complication/Problem *445*

37. Intracranial Pressure Monitoring **447**
Hemanshu Prabhakar

Indication *447* • Contraindication *448* • Applied Anatomy and Physiology *448*
• Technique and Equipment *449* • Preparation *451* • Procedure *452*
• Post-procedure Care *452* • Complication/Problem *453*

38. Nerve and Muscle Biopsy **454**
Sanjeev K Bhoi, Jayantee Kalita, Usha K Misra

Indication *454* • Contraindication *454* • Technique and
Basic Principles *455* • Preparation *456* • Procedure *456*
• Post-procedure Care *459* • Complication/Problem *459*

39. Spine Immobilization in Trauma Patient **460**
Sandeep Sahu, Indu Lata

Indication *461* • Contraindication of Spine Immobilization *461* • Applied Spine Anatomy *461* • Technique and Equipment *463* • Preparation *466* • Procedure Steps of Spine Immobilization and Logrolling *468* • Spine Immobilization During Imaging and Transport *470* • Post-procedure Care *470* • Complication/Problem *471*

Section 4 Gastrointestinal/Abdominal/Genitourinary Procedures

40. Nasogastric Tube Placement **477**
Bhuwan Chand Panday

Indication *477* • Contraindication *477* • Applied Anatomy *478* • Technique and Equipment *478* • Preparation *481* • Procedure *481* • Post-procedure Care *483* • Complication/Problem *483*

41. Nasojejunal Tube Placement **486**
Zafar Neyaz, Praveer Rai, Hira Lal

Indication *486* • Contraindication *486* • Applied Anatomy *486* • Technique and Equipment *487* • Preparation *488* • Procedure *489* • Post-procedure Care *494* • Complication/Problem *495*

42. Percutaneous Endoscopic Gastrostomy **497**
Samir Mohindra, Kundan Kumar

Indication *497* • Contraindication *498* • Technique and Equipment *498* • Preparation *499* • Procedure *500* • Post-procedure Care *502* • Complication/Problem *504*

43. Balloon Tamponade in Upper GI Bleed **506**
Praveer Rai

Indication *506* • Contraindication *506* • Technique and Equipment *506* • Preparation *508* • Procedure *508* • Post-procedure Care *509* • Complication/Problem *510*

44. Gastric Lavage **512**
Manish Gupta, Nitin Garg

Indication *512* • Contraindication *513* • Technique *513* • Preparation *515* Procedure *515* • Post-procedure Care *517* • Complication/Problem *518*

45. Intra-abdominal Pressure Monitoring **520**
RK Singh

Indication *520* • Contraindication *521* • Applied Pathophysiology *521* • Technique *521* • Preparation *522* • Procedure *522* • Post-procedure Care *525* • Complication/Problem *525*

46. Paracentesis **527**
Prasad Rajhans, Divyesh Patel

Indication *527* • Contraindication *527* • Applied Anatomy *528* • Technique *528* • Preparation *529* • Procedure *530* • Post-procedure Care *534* • Complication/Problem *535*

47. Percutaneous Abdominal Drain **537**
Hira Lal, Rajanikant R Yadav, Zafar Neyaz

Indication *537* • Contraindication *537* • Applied Anatomy *537*
• Technique and Equipment *538* • Preparation *540* • Procedure *541*
• Post-procedure Care *549* • Complication/Problem *549*

48. Bedside Laparoscopy **552**
Biju Pottakkat

Indication *552* • Contraindication *553* • Preparation *553*
• Technique and Equipment *553* • Procedure *554*
• Post-procedure Care *555* • Complication/Problem *555*

49. Dynamic Abdominal Wall Closure for Open Abdomen **556**
Fahri Yetisir, A Ebru Salman, Oskay Kaya

Indication *556* • Contraindication *556* • Technique *558* • Preparation *558*
Procedure *559* • Post-procedure Care *560* • Complication/Problem *561*

50. Urethral Catheterization **563**
Vijai Datta Upadhyaya, Eti Sthapak

Indication *563* • Contraindication *563* • Applied Anatomy *564*
• Technique and Equipment *564* • Preparation *566*
• Procedure (In Male Patient) *566* • Post-procedure Care *572*
• Complication/Problem *572*

51. Suprapubic Cystostomy **574**
Vijai Datta Upadhyaya

Indication *574* • Contraindication *574* • Applied Anatomy *575*
• Technique and Equipment *576* • Preparation *577* • Procedure *577*
• Post-procedure Care *578* • Complication/Problem *581*

52. Peritoneal Dialysis Catheter Placement **585**
Basant Kumar, MS Ansari

Indication *586* • Contraindication *586* • Applied Anatomy *587*
• Technique and Equipment *587* • Preparation *590* • Procedure *592*
• Post-procedure Care *595* • Complication/Problem *596*

53. Hemodialysis **598**
Harsh Vardhan, Dharmendra Bhadauria

Indication *598* • History and Basic Principle *598* • Modalities of Renal
Replacement Therapy *599* • Preparation *608* • Procedure *608*
• Post-procedure Care *610* • Complication/Problem *610*

Section 5 Miscellaneous

54. Bone Marrow Aspiration and Biopsy **615**
Gaurav Srivastava, Barnali Banik, Narendra Agrawal

Indication *615* • Contraindication *616* • Applied Anatomy *616*
• Technique and Equipment *616* • Preparation *618* • Procedure *619*
• Post-procedure Care *623* • Complication/Problem *623*

55. Postmortem Organ Needle Biopsy **625**
Rajanikant R Yadav, Namita Mehrotra

• Indication *625* • Contraindication *625*
• Applied Anatomy and Technique *626* • Preparation *626*
• Procedure *627* • Post-procedure Care and Problems *628*

56. Managing Pressure Ulcer **631**
Ankur Bhatnagar

Pathophysiology of Pressure Ulcer *631* • Prevention *632*
• Treatment of Pressure Ulcer *636* • Preparation *636* • Procedure *641*

57. Mobilization of Patient **646**
Abraham Samuel Babu, Vishal Shanbhag, Arun G Maiya

Indication for Early Mobilization *646* • Contraindication for Early Mobilization *646* • Technique and Basic Principles of Mobilization *647*
• Preparation and Assessment *650* • Physiotherapy Treatment *652*
• Post-procedure Care *655* • Complication/Problem *656*

58. Surveillance of ICU-acquired Infection **658**
Armin Ahmed, Richa Misra

Objective *658* • ICU-acquired Infection and Surveillance System *658*
• Method of Surveillance: Basic Principles *660*
• Surveillance for Specific ICU-acquired Infection *662*

59. Blood and Urine Sampling for Microbiology **667**
Armin Ahmed

Blood Sampling *667* • Technique and Basic Principles (Blood Sampling) *668*
• Preparation and Procedure (Blood Sampling) *669*
• Post-procedure Care (Blood Sampling) *671* • Urine Sampling *671*
• Technique and Basic Principle (Urine Sampling) *671*
• Preparation and Procedure (Urine Sampling) *671*
• Post-procedure Care (Urine Sampling) *673*

60. Blood Component Handling at Bedside **674**
Atul Sonker, Anju Dubey

Blood Components: Basic Properties *674* • Bedside Handling of Blood Components *678* • Adverse Reaction Due to Blood Components *684*

61. Managing Needle-stick Injury **690**
Puja Srivastava, Anupam Wakhlu, Vikas Agarwal

Definitions *690* • Prevention from Needle-stick Injury *691*
• Post-exposure Prophylaxis *692* • Post-exposure Counseling *699*

Index *703*

2

Endotracheal Intubation

Pradeep Bhatia

INTRODUCTION

Endotracheal intubation is the most commonly performed procedure in the intensive care unit (ICU), in which a tube is placed into the trachea to maintain an open airway, to allow the free flow of air to and from the lungs in unconscious patients and in trauma patients who cannot maintain a patent, protected airway; and also to support ventilation, who are unable to breathe adequately on their own. Airway control is vital to improve pulmonary gas exchange during hemodynamic instability and respiratory failure, as well as to protect the patient from aspiration. Oral or nasal airways are often used to keep the airway patent temporarily during preparation for endotracheal intubation. Oxygen, anesthetics or some medications can also be delivered through the tube.

INDICATION

- Cardiac arrest
- Respiratory arrest
- Airway obstruction
- Imminent risk of upper airway obstruction (e.g. upper airway burns)
- Facial injuries associated with compromised airway
- Altered mental status for protection from aspiration
- Head injury [Glasgow coma scale (GCS <8)]
- Need to control and remove pulmonary secretions
- Need for invasive ventilation in respiratory failure with inadequate oxygenation (which is not corrected by oxygen supplementation through mask/nasal cannula) or inadequate ventilation and hypercarbia
- Severe hemodynamic instability and shock
- General anesthesia with muscle relaxants.

CONTRAINDICATION

For Both Oral and Nasal Intubations

- Patients with an intact gag reflex
- Partial transection of the trachea (can lead to complete transection)
- Patients with high-risk of laryngospasm during intubation (e.g. children with epiglottitis)

JAYPEE BROTHERS

- Caution with unstable cervical spine that requires in-line cervical stabilization makes endotracheal intubation difficult (relative contraindication)
- Severe airway trauma or obstruction providing very small area to place the endotracheal tube (ETT) as attempts to intubate may worsen the condition resulting in severe respiratory obstruction. Emergency cricothyrotomy/tracheostomy is indicated in such cases (relative contraindication).

For Nasal Intubation

- Basilar skull fracture and cerebrospinal fluid (CSF) rhinorrhea
- Nasal polyp, abscess, adenoids or foreign body
- Bleeding disorders
- Previous nasal surgery is only relative contraindication.

APPLIED ANATOMY

The upper airway (Fig. 1) starts at the nostrils/oral cavity, to the hypopharynx and larynx. The high vascular areas of nasal and septal mucosa, the little's area and the Kiesselbach's plexus may bleed profusely during nasal route intubation especially in presence of bleeding disorder. The epiglottis is attached to the base of the tongue by a median and two lateral glossoepiglottic folds. The larynx is a 5–7 cm long structure. Its upper boundary starts at the tip of the epiglottis, opposite the third to fourth cervical vertebra. Its lower end is at the lower border of the cricoid cartilage, which lies at the level of sixth cervical vertebra. The structural rigidity of the larynx is provided by the three median cartilages: the epiglottis, thyroid cartilage and cricoid cartilage along with the hyoid bone. The six smaller cartilages of the larynx (3 pairs) are functionally involved with the movements of the vocal cords (Fig. 2). These are the arytenoids, the corniculates and the cuneiforms. The arytenoid cartilages are pyramid-shaped and articulate with the superior margin of the cricoid lamina. On their summit, are the corniculate cartilages; on their anterior aspect, the cuneiform cartilages. The vocal ligaments are attached posteriorly to the apex of the arytenoids and corniculates. The cuneiforms extend laterally, between the layers of the vocal cords, from the anterior aspect of the arytenocorniculate complex. The trachea is a membranous and D-shaped cartilaginous tube, with incomplete cartilaginous ring and extends from the lower part of the larynx, at the level with the sixth cervical vertebra, up to the upper border of the fifth thoracic vertebra, where it ends by dividing into the two bronchi, one for each lung. It is about 11 cm long and its diameter is greater in the male (25–27 mm) than in the female (21–23 mm).

TECHNIQUE AND EQUIPMENT

In 1885, Joseph O'Dwyer, an American pediatrician and obstetrician, inserted metal tubes between the vocal cords in patients with diphtheria and in patients requiring surgery. The first direct laryngoscopy was performed in 1895 by Alfred Kirstein with an external light source. In 1913, Chevalier Jackson designed a laryngoscope and was the first to perform intubation with it. Laryngoscope was later modified by Magill, Miller and Macintosh.[1,2]

The traditional and most commonly used method of intubation is oral intubation using direct laryngoscopy. Nasal intubation in ICU is better tolerated

JAYPEE BROTHERS

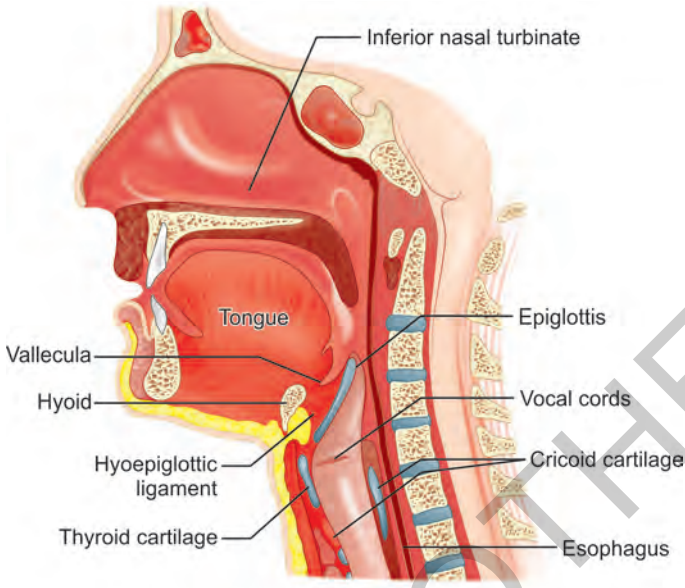

Fig. 1 Upper airway anatomy

Source: With permission from http://www.airwaycam.com

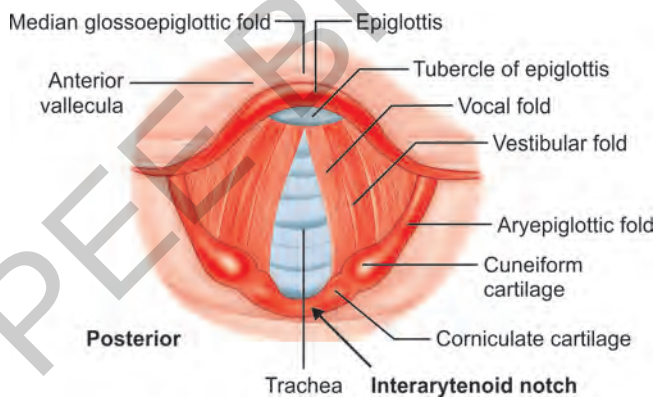

Fig. 2 Laryngoscopic view of glottis

Source: With permission from http://www.airwaycam.com

JAYPEE BROTHERS

than oral tube, requires less sedation and leaves the oral cavity clear to maintain oral hygiene. The disadvantages of nasal intubation are—it is more difficult than oral intubation and may result in bleeding due to the rich blood supply to the nasal mucosa. A nasal tube may create a false passage beneath nasal mucosa, or in patients with basal skull fractures, into the cranium. If kept for a long time, nasal tube may be associated with infection of the paranasal air sinuses. Other methods of intubation include blind nasal intubation, intubation using video laryngoscope, intubating laryngeal mask airway (LMA) and fiberoptic techniques.

Equipment

Most commonly used ETTs are made out of polyvinyl chloride and have a radiopaque line that helps verify the tube position by X-ray. To make it easier to pass through the vocal cords and to give you a better vision ahead of the tip, ETTs tip have a cut called a bevel. Some ETTs have an additional opening at the tip called a Murphy's, which provides an alternative channel for gas flow, if the main opening of the ETT gets blocked or placed against the tracheal wall. The ETT cuff forms a seal against tracheal wall that prevents gas leaking during positive pressure ventilation and also prevents aspiration of secretions and regurgitated gastric contents. There are two types of cuff. High-volume, low-pressure cuffs have a lower risk of tracheal wall ischemia and necrosis compared to low-volume high-pressure cuffs, particularly if used for a prolonged period of time. In long-term ventilated patients, subglottic secretions can accumulate above the cuff of the ETT that provides medium for bacterial growth and increases the risk of ventilator-associated pneumonia (VAP). Especially designed tubes are available that permits frequent or continuous elimination of subglottic secretions to decrease the risk of VAP.

PREPARATION

Adjunct Equipment

- Intravenous access
- Electrocardiography (ECG), pulse oximeter and end-tidal carbon dioxide ($EtCO_2$) monitors
- Suction machine and catheters
- Oropharyngeal, nasopharyngeal airways (Figs 3 and 4, respectively)
- Non-rebreathing mask
- Oxygen source (15 L/minute flow)
- Bag valve mask
- Appropriate size ETTs (*Adults:* 7.5 mm; *Children:* Size roughly equal to the diameter of little finger) (Fig. 5) and a 10-cc syringe
- Stylet, Magill's forceps, Bougie (Figs 6 to 8, respectively)
- Laryngoscope blades, different types (Figs 9A to C)
- Adhesive tape.



Fig. 3 Oropharyngeal airway

Source: Fexicare

JAYPEE BROTHERS



Fig. 4 Nasopharyngeal airway
Source: Fexicare

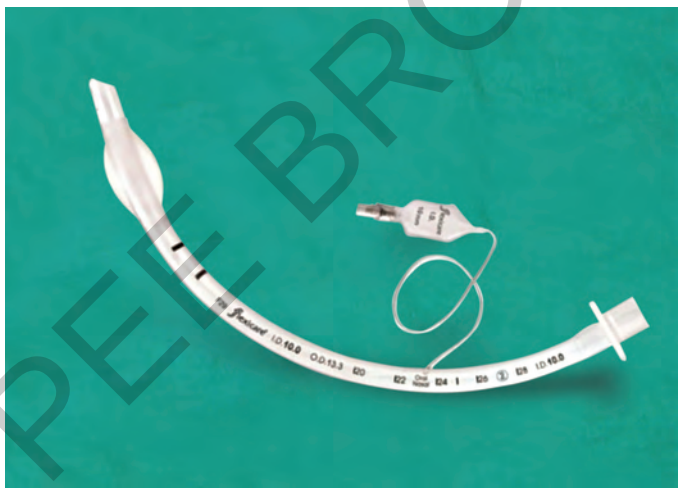

Fig. 5 Endotracheal tube
Source: Fexicare



Fig. 6 Stylet
Source: Fexicare

JAYPEE BROTHERS



Fig. 7 Magill forceps

Source: Fexicare



Fig. 8 Bougie

Source: Fexicare

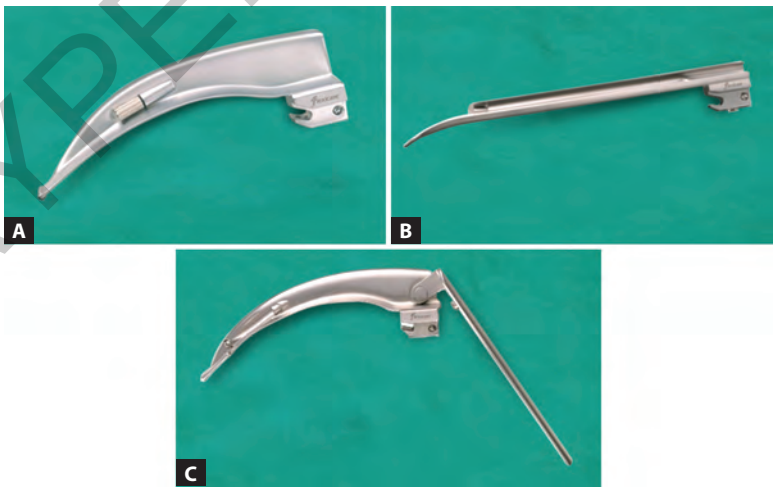

Figs 9A to C Different types of laryngoscope blades. (A) Macintosh; (B) Miller; (C) McCoy

Source: Fexicare

JAYPEE BROTHERS

Assess Airway

Carefully observe for the landmarks, swelling or any deformity. Assess tongue size, dental obstruction and the degree of neck mobility. Remove dentures.

Mallampati classification is generally performed to assess upper airway access. This test is performed while the patient is in the sitting position, awake and cooperative. This may not always be possible in the ICU settings.
Ask the patient to open mouth and protrude tongue.

Class I: Visualization of the soft palate, fauces, uvula and pillars. No anticipated difficulty.

Class II: Visualization of the soft palate, fauces, uvula. No anticipated difficulty.

Class III: Visualization of the soft palate and base of the uvula. Anticipate moderate difficulty.

Class IV: Soft palate is not visible. Anticipate severe difficulty.

A seven-item simplified score (MACOCHA score) for identifying patients with difficult intubation in the ICU and related complications is developed.[3] The main predictors of difficult intubation are related to patient (Mallampati score III or IV, obstructive sleep apnea syndrome, reduced mobility of cervical spine, limited mouth opening); pathology (severe hypoxia, coma); and operator (nonanesthesiologist).

Drugs

The patient in ICU may be restless, agitated and delirious and may require sedation/short anesthesia and relaxant for intubation. The commonly used drugs for intubation in ICU are:

- Propofol (2–2.5 mg/kg) causes bradycardia, myocardial depression and reduced systemic vascular resistance and is usually avoided in critically ill patients with potential hemodynamic instability.
- Etomidate (0.2–0.6 mg/kg) possesses the best hemodynamic profile of all the induction agents, has rapid onset and short half-life but may cause suppression of adrenocortical function.
- Ketamine (1–2 mg/kg) produces a state of dissociative anesthesia, profound analgesia, and amnesia but causes hallucinations, delirium, nausea and vomiting. Ketamine has been advocated for intubation in ICU.[4]
- Besides anesthetic agents mentioned above, midazolam (0.05 mg/kg), fentanyl (1–2 mg/kg) and dexmedetomidine (1 mg/kg) are also used for sedation/analgesia during endotracheal intubation.
- Succinylcholine (1 mg/kg) is a depolarizing muscle relaxant, has a rapid onset and short duration of action and is recommended for intubation in ICU settings provided there are no contraindications to its use like the possibility of cannot ventilate—cannot intubate situation and the risk of hyperkalemia.
- Rocuronium (0.6 mg/kg) is a nondepolarizing muscle relaxant and compared to succinylcholine, it has fewer side effects but is associated with less optimal intubation conditions and has a longer duration.
- The use of muscle relaxants for intubation is reported to be associated with fewer complications, including in patients with difficult airways.[5]

JAYPEE BROTHERS

Monitoring

Electrocardiogram (heart rate, rhythm, ST changes), blood pressure, pulse oximetry and $EtCO_2$.

PROCEDURE

Position of the Patient

- Maintain cervical spine stability, if necessary.
- The patient should lie supine with a pillow under the head.
- To visualize the larynx, all the three anatomic axes (oral, pharyngeal and laryngeal) should be aligned, which is done by extension of atlanto-occipital joint and flexion of lower cervical joints so that the ETT passes from the lips to the glottis opening in almost a straight line.
- *Unless contraindicated*, (i.e. suspected cervical injury) elevate the patient's head by approximately 10 cm with pads or a pillow under the occiput and extend the head into the sniffing position so as to align the oral, pharyngeal and laryngeal axes (Figs 10A to C).

Procedure

- The operator should wear gloves, a gown and goggles
- Stand at the supine patient's head end
- Preoxygenate with 100% oxygen to prevent arterial desaturation during intubation, if possible, should be done
- *Use artificial airways, if needed:* Oropharyngeal, nasopharyngeal during bag-mask ventilation
- Open the patient's mouth and remove foreign material, if any, manually or by suction. Perform chin lift and jaw thrust maneuver
- Separate lips and pull the upper jaw to open the patient's mouth
- Hold a laryngoscope in the left hand and gently insert the blade of laryngoscope into the mouth of the patient being careful not to break a tooth, directing the blade toward the right tonsil
- On reaching the right tonsil, sweep the laryngoscope blade to the midline and keep the tongue to the left to view the epiglottis
- Advance the laryngoscope blade up to the angle between the base of the tongue and the epiglottis
- Lift the laryngoscope upward and forward, without changing the angle of the blade, to expose the vocal cords. Often an assistant applies backward, upward rightward pressure (the BURP maneuver) on the cricoid cartilage to get the full view of the glottis
- Hold the ETT in the right hand keeping its concavity toward the right side. Insert the tube through the mouth opening
- Continue inserting the tube till it passes through the vocal cords which is approximately at 20–22 cm mark on the ETT
- Remove stylet
- Inflate the cuff with 5–10 mL air using a syringe allowing minimal leak on manual ventilation (cuff pressure should be kept between 20–30 cm H_2O, using a cuff pressure manometer to prevent tracheal ischemic changes).

JAYPEE BROTHERS

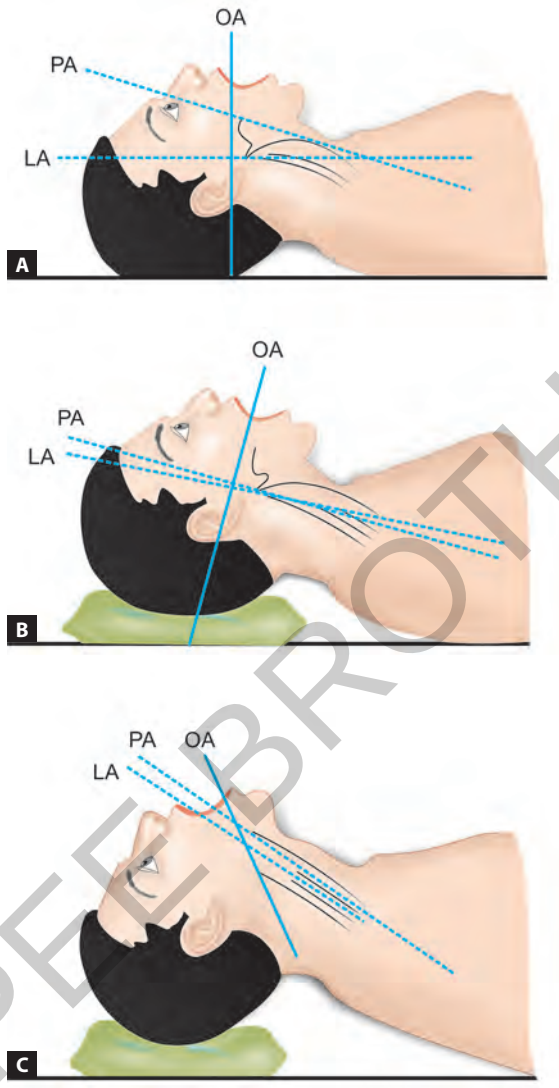

Figs 10A to C Alignment of three axes (LA, Laryngeal axis; PA, Pharyngeal axis; OA, Oral axis) for intubation

- Ventilate manually
- Confirm the correct placement of the ETT by:
  - Directly visualizing the passage of the tube through the vocal cords
  - Condensation of water vapors in the tube with respirations
  - Movement of the chest with respirations
  - Bilaterally auscultating the chest
  - Auscultation over the stomach to rule out the gurgling sound
  - End-tidal CO_2 monitoring
  - Improving oxygen saturation

JAYPEE BROTHERS

  - Clinical improvement of the patient
  - Chest X-ray anteroposterior (AP) view in a semierect or supine position keeping the patient's head in the neutral position and confirm that the tip of the ETT is 2 cm above the carina
- Secure tube (3 methods—Twill tape, adhesive tape and tube fastener devices that prevents the formation of lip ulcers and has better access to the oral cavity to optimize oral care) (Fig. 11).

Difficult Intubation

An intubation is called difficult, if normally trained anesthesiologists need more than three attempts or more than 10 minutes for a successful endotracheal intubation. Intubations in the ICU are more likely to be difficult than intubations in theater. In the ICU settings; it is often difficult to visualize the glottis due to space constraints, uncooperative patient and the accompanying comorbidities. Multiple attempts of endotracheal intubation, often required in ICU, may increase the risk of airway edema, trauma, hemorrhage and vomiting leading to difficulty in intubation.

Alternatives

Alternatives to conventional laryngoscopy and orotracheal intubation include and should be considering in case of difficult/failed intubation:

- Nasotracheal intubation
- Endotracheal intubation using the videolaryngoscope/bronchoscope
- Esophageal tracheal combitube (ETC)
- Laryngeal mask airway
- Tracheostomy
- Cricothyrotomy (for an emergency).



Fig. 11 Endotracheal tube fixation with commercial tube holder

Source: Fexicare

JAYPEE BROTHERS

POST-PROCEDURE CARE

Once the position of the ETT is confirmed, it should be reassessed periodically because the ETT can migrate over time as a consequence of coughing, suctioning and movement. The clinical examination to confirm the correct ETT placement like chest auscultation for breath sounds, symmetrical chest expansion and palpable tube cuff in the suprasternal notch may be inaccurate in the ICU settings. Hence, daily chest X-rays are done at many centers to verify tube position. However, studies suggest a more restrictive approach (e.g. chest radiographs only in response to a change in clinical condition) to decreases the number of chest radiographs without worsening clinical outcomes.

Routine change of ETT every 1–2 weeks, to decrease the incidence of complications (given here) is not recommended as the process itself may lead to silent aspirations and nosocomial pneumonia.

COMPLICATION/PROBLEM

Tracheal intubation procedure in ICU settings is more complex compared to that done in the operation theater (OT). In the OT, intubation is associated with a low rate of complication as it is done by a trained anesthesiologist, generally in a stable patient with good physiological reserve. Conversely, high incidence of failure and complications are associated with intubation in the ICU, where airway tools may not be readily available. In ICU settings, intubation is done often by a junior doctor with little or no training of intubation, as an emergency, in a critically ill patient with precarious hemodynamic and respiratory status. There is under-evaluation of the airways and suboptimal response to preoxygenation. In addition, many drugs used during intubation are associated with adverse hemodynamic effects.[6]

Following complications may occur during intubation in ICU:

- Injury to teeth, soft tissue (lips, pharyngeal tissue), arytenoid cartilages, larynx and related structures
- Nasal intubation may be associated with damage to turbinates, bleeding and nasopharyngeal mucosal perforation
- Airway edema, bleeding, tracheal and esophageal perforation, laryngospasm causing a complete airway obstruction
- Barotrauma due to absence or malfunction of pressure release valve, pneumothorax, subcutaneous emphysema
- Endotracheal tube obstruction by a foreign body, dry respiratory secretions or blood clots causing collapsed lung
- Severe hypoxia because of central respiratory dysfunction, deranged chest wall mechanics, or intrapulmonary ventilation/perfusion abnormalities that may induce hypoxic arrhythmias on intubation
- Endobronchchial intubation (ETT inserted too far)
- Esophageal intubation, if remain undiagnosed, will result in gastric distension and regurgitation on attempting ventilation (possibly leading to hypoxemia, hypercapnia and death), vomiting and aspiration
- Bradycardia, sympathetic stimulation resulting in hypertension and tachycardia [dangerous in a patient with intermittent hemodialysis (IHD)] cardiac arrhythmias

JAYPEE BROTHERS

- Cardiovascular collapse due to hypovolemia, vasodilatation, myocardial depression and suppression of sympathetic response by anesthetic drugs used for intubation, and due to the negative effects of positive pressure ventilation on venous return, prophylactic intravenous crystalloid administration may prevent, these adverse cardiovascular effects
- Endotracheal tube cuff damage that may result in inadequate seal and leak
- Microorganisms may colonize and multiply on the inner surface of the ETT and subsequently develop biofilms. These biofilms are resistant to antibiotic penetration may act as source of pulmonary infection and development of VAP.

To decrease complications related to endotracheal intubation in the ICU, Samir Jaber et al.[7] developed an intubation care bundle management system based on a review of the ICU airway literature.

Intubation Care Bundle Management[7]

Preintubation

- Presence of two operators
- Fluid loading (isotonic saline 500 mL or starch 250 mL) in absence of cardiogenic pulmonary edema
- Preparation of long-term sedation
- Preoxygenation for 3 minutes with noninvasive positive pressure ventilation (NIPPV) in case of acute respiratory failure [fraction of inspired oxygen (FiO_2) 100%, pressure support ventilation level between 5 and 15 cm H_2O to obtain an expiratory tidal volume between 6 and 8 mL/kg and positive end-expiratory pressure (PEEP) of 5 cm H_2O].

During Intubation

- *Rapid sequence induction:* Etomidate 0.2–0.3 mg/kg or ketamine 1.5–3 mg/kg combined with succinylcholine 1–1.5 mg/kg in absence of allergy, hyperkalemia, severe acidosis, acute or chronic neuromuscular disease, burn patient for more than 48 hours and medullar trauma.
- Sellick's maneuver (cricoid pressure of 20–44 N to occlude the esophagus, preventing regurgitation and subsequent aspiration of gastric contents during intubation).

Postintubation

- Immediate confirmation of tube placement by capnography
- Norepinephrine, if diastolic blood pressure remains below 35 mm Hg
- Initiate long-term sedation
- *Initial "protective ventilation":* Tidal volume 6–8 mL/kg of ideal body weight, PEEP 5 cm H_2O and respiratory rate between 10 and 20 cycles/minutes, FiO_2 100% for a plateau pressure less than 30 cm H_2O.

The implementation of an endotracheal intubation care bundle management in the ICU may reduce the incidence of life-threatening complications occurring within the first hour after intubation from 34–21%. Severe hypoxemia and

JAYPEE BROTHERS

cardiovascular collapse incidences, which were the main life-threatening complications after intubation, were reduced by half in the intervention group compared to the control group.[7]

REFERENCES

1. Szmuk P, Ezri T, Evron S, Roth Y, Katz J. A brief history of tracheostomy and tracheal intubation, from the Bronze Age to the Space Age. Intensive Care Med. 2008;34(2):222-8.
2. Burkle CM, Zepeda FA, Bacon DR, Rose SH. A historical perspective on use of the laryngoscope as a tool in anesthesiology. Anesthesiology. 2004:100(4):1003-6.
3. Jaber S, Amraoui J, Lefrant JY, Arich C, Cohendy R, Landreau L, et al. Clinical practice and risk factors for immediate complications of endotracheal intubation in the intensive care unit: a prospective, multiple-center study. Crit Care Med. 2006;34(9):2355-61.
4. Jabre P, Combes X, Lapostolle F, Dhaouadi M, Ricard-Hibon A, Vivien B, et al. Etomidate versus ketamine for rapid sequence intubation in acutely ill patients: A multicentre randomised controlled trial. Lancet. 2009;374:293-300.
5. De Jong A, Molinari N, Terzi N, Mongardon N, Arnal JM, Guitton C, et al. Early Identification of Patients at Risk for Difficult Intubation in the Intensive Care Unit: development and validation of the MACOCHA score in a multicenter cohort study. Am J of Respir Crit Care Med. 2013;187(8):832-9.
6. Divatia JV, Khan PU, Myatra SN. Tracheal intubation in the ICU: Life saving or life threatening? Indian J Anaesth. 2011;55(5):470-5.
7. Jaber S, Jung B, Corne P, Sebbane M, Muller L, Chanques G, et al. An intervention to decrease complications related to endotracheal intubation in the intensive care unit: a prospective, multiple-center study. Intensive Care Med. 2010;36(2):248-55.

JAYPEE BROTHERS

for detailed information on medicine books, visit our website **www.jaypeebrothers.com,** for deta

MANUAL OF ICU PROCEDURES

Salient Features

- It is a reference book for ICU procedures
- Contains 61 chapters including simple as well as more complex procedures, being done in critically and acutely ill patients
- Describes step-by-step procedures along with more than 700 illustrations
- The chapters are written by experts with their vast experience and knowledge from various specialties
- Presents as a ready resource in ICU and emergency room
- Useful for postgraduate students across all clinical specialties and faculties such as critical care physicians, emergency physicians, anesthetists, pulmonologists, pediatricians, general physicians and general surgeons.

Mohan Gurjar MD PDCC FICCM is an Associate Professor, Department of Critical Care Medicine, Sanjay Gandhi Postgraduate Institute of Medical Sciences (SGPGIMS), Lucknow, Uttar Pradesh, India. The SGPGIMS is a premier academic institute, having credit of first standalone department of critical care medicine across the country.



He authored more than 70 publications; and currently serving as an editorial board member and as a Reveiwer for many international and national peer-reviewed journals.

Available at all medical bookstores or buy online at www.jaypeebrothers.com

JAYPEE BROTHERS Medical Publishers (P) Ltd.
www.jaypeebrothers.com
Join us on facebook.com/JaypeeMedicalPublishers

Shelving Recommenation
MEDICINE

ISBN 978-93-5152-422-9