n cardiology books, visit our website www.jaypeebrothers.com, for detailed information on cardiology books

Clinical Pearls in Cardiology

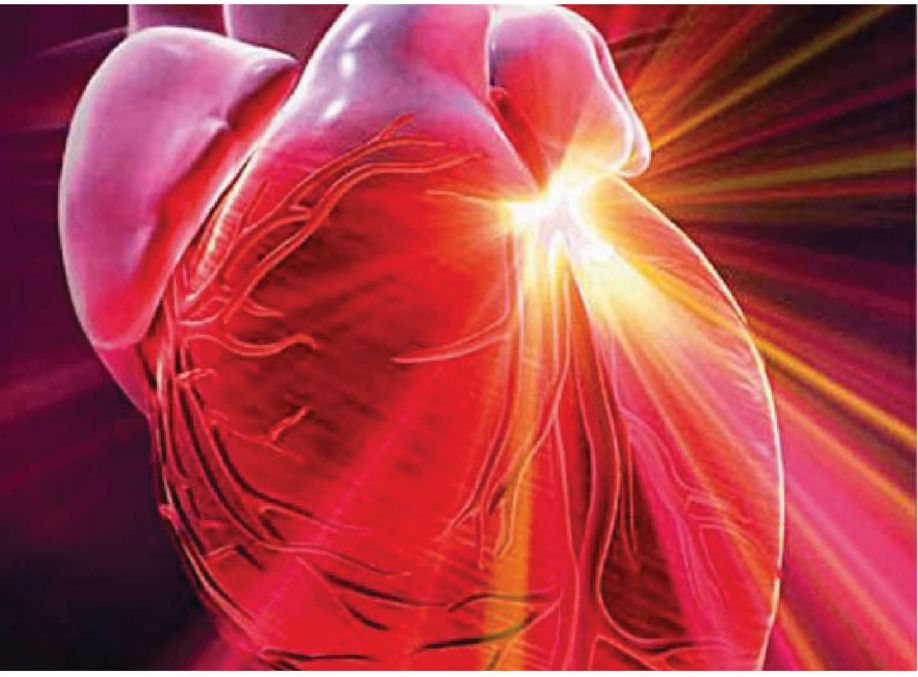

Hemanth IK
Shafeeq Mattummal

Foreword
Thirunavukkarasu Ganesan

JAYPEE

Contents

Chapter 1	History and General Examination	1
Chapter 2	Arterial Pulse and Blood Pressure	28
Chapter 3	Jugular Venous Pulse	60
Chapter 4	Inspection and Palpation of the Precordium	72
Chapter 5	Auscultation of the Precordium	81
Chapter 6	Valvular Heart Diseases	99
Chapter 7	Heart Disease and Fever	129
Chapter 8	Congenital Heart Disease	140
Chapter 9	Ischemic Heart Disease	153
Chapter 10	Radiology	178
Index		*189*

Chapter
4 Inspection and Palpation of the Precordium

1. What is meant by cardiac apical impulse?

The cardiac apical impulse is the lowermost and outermost part of the chest wall where a definite cardiac impulse can be felt by the palpating fingertips. The normal apical impulse is confined to one intercostal space (area of a 50 paisa coin) and it is confined to the first half of ventricular systole.

As intraventricular pressure rises during the phase of isovolumic contraction in early systole, the left ventricle rotates in a counter clockwise direction on its long axis, and its apical part gets lifted and makes contact with the left anterior chest wall. This movement produces the apical impulse. During mid and late systole, the left ventricle is diminishing in volume, and the apical impulse moves away from the chest wall. Thus, any outward precordial apical motion occurring in late systole is always abnormal.

2. How will you examine the cardiac apical impulse?

The apical impulse is ideally inspected with the patient in the supine or slightly propped up position. In difficult situations, the location of the apical impulse can be best observed with the patient sitting up, leaning forward and exhaling. Turning the patient into the left lateral decubitus position improves appreciation of the character of the apical impulse on palpation. However, it has to be remembered that this maneuver falsely

JAYPEE BROTHERS

displaces the apical impulse laterally, and so it should not be used to localize the apex (Fig. 1).

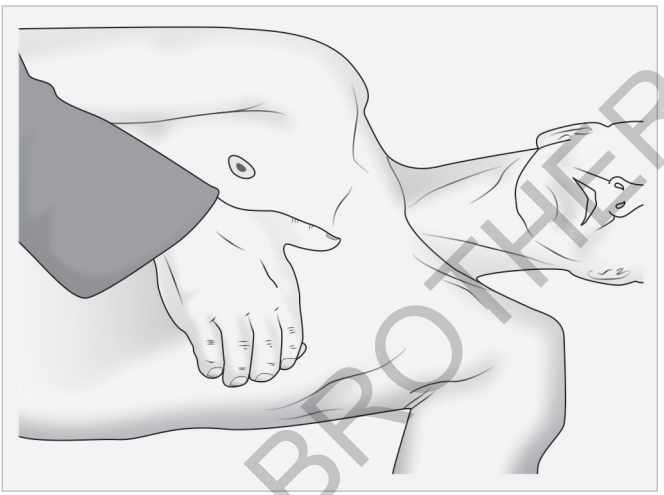

Fig. 1: Examining the character of the apical impulse in the left lateral position

3. What are the important types of apical impulses?

The character of the apical impulse is dependent on various factors like myocardial wall contractility, myocardial wall thickness, etc. The important types of apical impulses are illustrated in Table 1:

Table 1: Different types of cardiac apical impulses

Type	Important features
Hyper-kinetic (Volume loaded)	• Forceful impulse • Occupies more than one intercostal space • Lasts between more than 1/3rd to less than 2/3rd of systole • Seen in volume overload states like aortic or mitral regurgitation

Contd...

JAYPEE BROTHERS

Contd...

	• Also seen in hyperkinetic circulatory states like anemia, pregnancy
Heaving (Pressure loaded)	• Forceful impulse • Confined to one intercostal space • Lasts more than 2/3rd of systole • Seen in pressure overload states like aortic valve stenosis and hypertensive heart disease
Tapping	• Due to the palpable first heart sound in mitral stenosis
Double apex	• Due to secondary impulse (HOCM, left ventricular aneurysm, etc.)
Triple apex	• Seen in HOCM

4. What are thrills?

Thrills are defined as palpable vibrations which result from turbulence of blood flow. They are best felt with the distal palm or ball of the hand, when pressed gently against the precordium. Thrills usually accompany murmurs that are caused by very high pressure gradients.

5. What is carotid shudder?

Carotid shudder is a thrill or 'shivering' felt at the peak of the carotid pulse in the neck in patients with aortic stenosis, aortic regurgitation or both. It represents transmission of the murmur to the artery. It is a relatively specific, but rather insensitive sign of aortic valve disease.

6. What are the common causes of impalpable apical impulse?

In some cases, the cardiac apical impulse cannot be clinically located. Some important causes of nonpalpable apical impulse include the following;

- Overlying rib
- Structural deformities like barrel-shaped chest, gross kyphoscoliosis, etc.
- Obesity

JAYPEE BROTHERS

- Pleural or pericardial effusion
- Pneumothorax.

7. How do you clinically differentiate predominant right ventricular enlargement from left ventricular enlargement?

Cardiomegaly due to predominant left ventricular enlargement causes the apical impulse to be displaced both laterally and downwards. Predominant enlargement of the right ventricle occurs in conditions like chronic cor-pulmonale, mitral stenosis with pulmonary arterial hypertension, etc. In such conditions, the grossly enlarged right ventricle pushes the left ventricle postero-laterally. So the apical impulse is displaced laterally in those with predominant right ventricular enlargement.

Sometimes in those with predominant right ventricular enlargement, prominent right ventricular pulsations will be visible over the precordium. This may give the impression of a false apical impulse. So one should carefully look for the left ventricular impulse (*i.e. the true apical impulse*) which is usually displaced laterally, and located either in the anterior axillary or in the midaxillary line (Fig. 2).

8. Which are the conditions that can cause 'ballooning' motion of the apex?

The two important conditions that can cause 'ballooning' motion of the left ventricular apex are left ventricular aneurysm and stress cardiomyopathy. Left ventricular aneurysm is a sharply delineated area of scar tissue that bulges paradoxically during ventricular systole. They are seen in some patients who survive an acute myocardial infarction. Apical aneurysms are the most common type of left ventricular aneurysms and they produce a local ballooning or expansile wall motion. The persistence of

JAYPEE BROTHERS

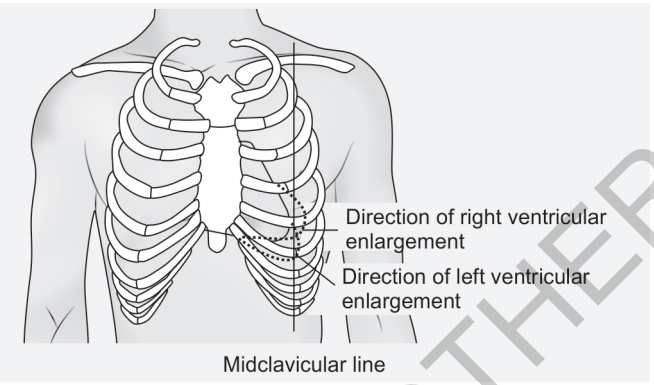

Fig. 2: Direction of enlargement in right and left ventricular dilatation

ST segment elevation for 4 weeks or more after an acute myocardial infarction suggests a ventricular aneurysm. When no previous ECG is available, the presence of a qS complex in the setting of ST segment elevation without T wave inversion, is highly suggestive of a left ventricular aneurysm. The important complications of left ventricular aneurysms are congestive heart failure, mural thrombus with arterial embolism and ventricular arrhythmias.

Stress (Takotsubo) cardiomyopathy, also called as the apical ballooning syndrome, is characterized by severe akinesia of the distal portion of the left ventricle, with ballooning of the apex. All the changes in this condition are reversible within one week.

9. What are the important features of hypertrophic cardiomyopathy?

This is a form of cardiomyopathy with autosomal dominant transmission which is characterized by inappropriate left ventricular hypertrophy. The

JAYPEE BROTHERS

hypertrophy may be generalized or confined largely to the interventricular septum. Septal hypertrophy may also cause dynamic left ventricular outflow tract obstruction. This occurs when the upper part of the septum meets a mobile part of the anterior mitral valve leaflet that is 'sucked anteriorly' during ventricular systole. The important symptoms of hypertrophic cardiomyopathy are the following:

- Angina on effort
- Dyspnea on effort
- Syncope on effort
- Sudden death (due to ventricular arrhythmias) during or just after vigorous physical activity. It is most common cause of sudden death in young athletes.

An implantable cardiac defibrillator should be considered in patients with risk factors for sudden death. Digoxin and vasodilators may increase outflow tract obstruction by decreasing the left ventricular cavity size and should be avoided in these patients. Outflow tract obstruction can be improved by partial surgical resection or by septal ablation. Septal ablation is done by injecting alcohol using a catheter into the first major septal perforator coronary artery and a myocardial infarction is produced in that region (*i.e. iatrogenic infarction*) that reduces the thickness of the septum.

10. How will you clinically differentiate left parasternal lift from left parasternal heave?

Left parasternal heave is an upward thrust felt over the precordium. It indicates gross hypertrophy of the right ventricle. Left parasternal heave is clinically assessed by placing the heel of the examiner's hand over the left parasternal region, and the patient is asked to hold his breath in end expiration. The duration of the heave can

JAYPEE BROTHERS

be assessed by simultaneous cardiac auscultation. Based on the duration, left parasternal heave is graded into three grades as follows:

Grading of left parasternal heave
Grade 1: Heave is confined to early systole
Grade 2: Heave extends throughout systole
Grade 3: Heave extends beyond systole

In severe mitral regurgitation without significant pulmonary arterial hypertension, the large regurgitant jet refluxing into the left atrium produces an outward recoil of the anterior cardiac structures. This will produce a brief palpable late systolic impulse beneath the lower part of the sternum. This movement is known as the left parasternal lift (Table 2).

Table 2: Difference between left parasternal heave and lift

Left parasternal lift	Left parasternal heave
Movement occurs in later part of systole	Movement begins in early systole
Brief impulse	Sustained impulse
Associated with murmur of mitral regurgitation	Murmur of tricuspid regurgitation may occur (secondary to pulmonary hypertension)

11. What are the clinical signs of pulmonary artery hypertension?

Pulmonary hypertension is defined as a mean pulmonary artery pressure greater than 25 mm Hg at rest, or greater than 30 mm Hg with exercise. Pulmonary artery hypertension may be primary or secondary to diseases of the lung or the heart. Pulmonary hypertension causes

JAYPEE BROTHERS

a substantial increase in workload of the right heart, often leading to right heart hypertrophy and failure. The clinical signs of pulmonary artery hypertension, in general, are the following:

- Cardiomegaly
- Large 'a' wave in jugular venous pulse
- Cyanosis is a very late sign
- Visible and palpable systolic pulsations in the pulmonary area due to the dilated pulmonary artery
- Compression by the dilated pulmonary artery can cause paralysis of the left recurrent laryngeal nerve. This results in hoarseness of voice. This condition is called as Ortner syndrome.
- Palpable tap of pulmonary valve closure (i.e. palpable P2) (Fig. 3)
- Left parasternal heave due to hypertrophy of the right ventricle
- Narrowly split second heart sound with a loud P2 component (*earliest sign*)
- Ejection click and flow murmur along the left sternal border due to the dilated pulmonary artery in early stages
- Right ventricular S4 may be heard
- High pitched early diastolic decrescendo murmur in the pulmonary area due to pulmonary regurgitation in late stages (Graham/Steell murmur)
- Clinical signs of the associated functional tricuspid regurgitation secondary to right ventricular dilatation like prominent epigastric and systolic hepatic pulsations, raised JVP with prominent 'v' and 'y' waves and holosystolic murmur along the lower left sternal border may be seen in late stages

JAYPEE BROTHERS

- Signs of right heart failure like peripheral edema, ascites and congestive hepatomegaly occur in late stages.

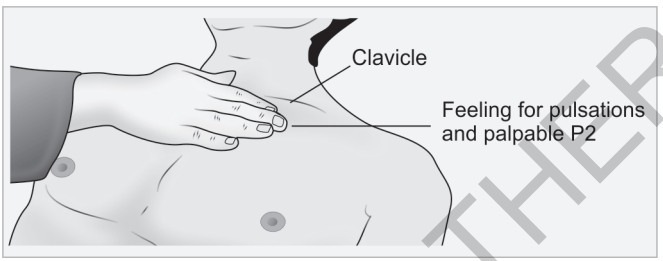

Fig. 3: Palpating the pulmonary area

JAYPEE BROTHERS

or detailed information on cardiology books, visit our website www.jaypeebrothers.com, for detailed

Clinical Pearls in Cardiology

Salient Features

- A pocket-sized quick reference guide
- Presents the essentials of cardiology in a simple and compact style
- Provides a concise collection of vital information on the signs and symptoms of heart diseases
- Includes more than 200 questions and answers on clinical aspects of cardiology and enhanced by 36 illustrations
- Divided into 10 chapters, covering history taking and general examination, pulse and blood pressure, the precordium, heart diseases and radiology
- Analyzes the common symptoms of heart diseases, with pathophysiological explanations and differential diagnoses of each symptom, i.e. chest pain, shortness of breath, palpitations, dizziness and leg swelling
- Serves as an ideal source material for undergraduate and postgraduate medical students.

Hemanth IK MBBS MD is Associate Professor, Department of Internal Medicine, KMCT Medical College, Kozhikode, Kerala, India. He graduated and postgraduated from Calicut Medical College, Kozhikode. His other notable publications are *20 Cases in Clinical Medicine* and *Clinical Pearls in Pulmonology.*



Shafeeq Mattummal MBBS MD DM is Assistant Professor and Interventional Cardiologist, Department of Cardiology, KMCT Medical College, Kozhikode, Kerala, India. He passed his MBBS from Calicut Medical College, Kozhikode and did his MD (General Medicine) and DM (Cardiology) from Seth GS Medical College and King Edward VII Memorial (KEM) Hospital, Mumbai, Maharashtra, India. He did his Fellowship in interventional cardiology from Inselspital University, Centre for Heart Diseases, Bern, Switzerland.



Available at all medical bookstores or buy online at www.jaypeebrothers.com

JAYPEE BROTHERS
Medical Publishers (P) Ltd.
www.jaypeebrothers.com

Join us on facebook.com/JaypeeMedicalPublishers

Shelving Recommendation
CARDIOLOGY

ISBN 978-93-5152-436-6