cs & gynecology books, visit our website **www.jaypeebrothers.com,** for detailed information on obstetrics & gynecology book

T Radha Bai Prabhu

A Practical Approach to Cervical Cancer Screening Techniques


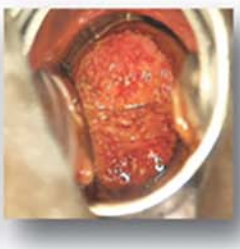


1. Introduction
2. Cervical Anatomy
3. Etiology and Risk Factors for Cervical Carcinoma
4. Human Papillomavirus and Cervical Carcinoma
5. Pathogenesis of Cervical Carcinoma
6. Progression and Regression of CIN Lesions
7. Histology of Cervical Intraepithelial Neoplasia
8. Screening Tests for Cervical Carcinoma
9. HPV DNA Testing
10. Cytology of Normal and Abnormal Cells of Cervix
11. Management of Abnormal Cytology Cell Results
12. Colposcopy
13. Interpretation of Colposcopy Findings
14. Visual Inspection Methods (VIA and VILI)
15. Cell Cycle Markers
16. Polarprobe
17. Laser-induced Fluorescence
18. Speculoscopy
19. Cervicography
20. Colposcopy Training Log Book

Chapter 2

Cervical Anatomy

JAYPEE BROTHERS

To understand the various screening approaches used in the detection of precancerous lesions of the cervix, it is important that one has a good knowledge about the anatomy of the cervix. Depending upon the age, parity and the hormonal status of the woman, the size and shape of the cervix varies. In nulliparous women, the cervix appears small and the external os is a small circular opening. In multiparous women, who have delivered by the vaginal route, the cervix is bulky and the external os is wide and gaping and appears as a transverse slit. Occasionally, there is marked eversion of the ectocervix due to torn cervix. In pregnancy, the cervix appears hypertrophied and patulous. Often there is marked ectopy of the cervix **(Figure 2-1)**.

In postmenopausal women, the cervix is atrophic and button-like or may be flushed with the vagina **(Figure 2-2)**. The above knowledge will help the clinician is choosing the appropriate technique for screening.

HISTOLOGY

The cervical tissue has a stromal layer over which epithelial cells are arranged. The stroma of the cervix is composed of vessels, lymphatics and nerve supply to the cervix. The epithelial cells of the cervix are squamous epithelium, which covers the ectocervix and the columnar epithelium, which lines the endocervical canal. The point at which the

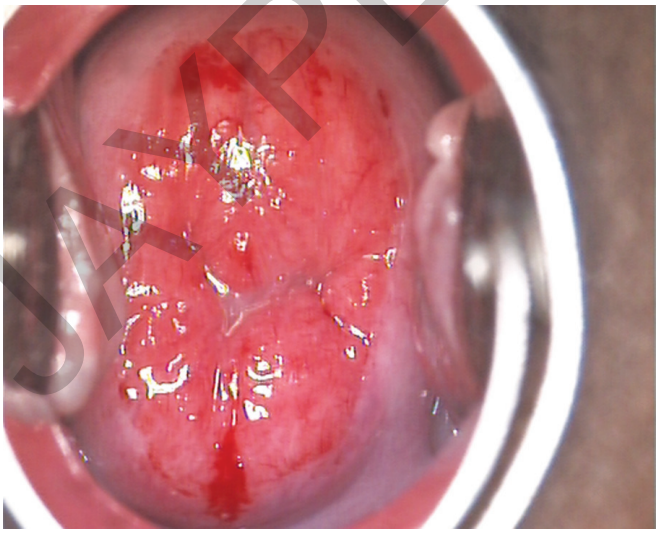

Figure 2-1: Ectopy of the cervix in pregnancy

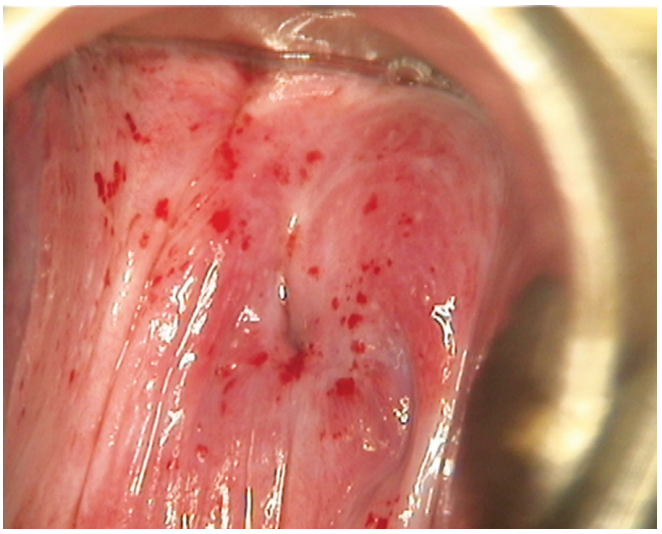

Figure 2-2: Postmenopausal cervix—atrophic, thin, flushed with the vault and brittle with petechial hemorrhages

squamous and columnar epithelium meet is called squamo-columnar junction (SCJ).

THE SQUAMOUS EPITHELIUM

The squamous epithelium of the ectocervix is multilayered, non-keratinizing and contains glycogen. The epithelial cell layer does not have blood vessels. Because of the multiple layer, it does not transmit the color from the underlying blood vessels. Therefore, on naked-eye inspection, the surface of the ectocervix appears opaque and pale pink. The original squamous epithelium of the vagina and ectocervix has four layers **(Figures 2-3A and B)**.

1. *The basal layer:* The basal layer is a single row of immature cells with a large nuclei and a small amount of cytoplasm. The basal cell layer is arranged on the basement membrane. The basal cells divide and differentiate into parabasal, intermediate and superficial cells. As the cells mature from basal epithelium to superficial layers, there is a gradual increase in cytoplasm and a reduction in nuclear size.
2. *The parabasal layer:* The parabasal layer includes two to four rows of immature cells that have normal mitotic figures.
3. *The intermediate layer* contains four to six rows of cells, polyhedral in shape with large amount of cytoplasm. The cells are separated by an intercellular space and the glycogen content is increased.
4. *The superficial layer* has five to eight rows of flattened cells with large amounts of cytoplasm containing glycogen. The nucleus is small, uniform and pyknotic.

These cells detach from the surface (exfoliation) and these cells form the basis for the Papanicolaou (Pap) testing.

In postmenopausal women, the cells do not mature beyond the parabasal layer; therefore, multiple layers of cells are not seen. As a result, the squamous epithelium becomes thin and atrophic. Therefore, it appears pale and brittle with sub-epithelial petechiae and it is easily prone to trauma **(Figure 2-4)**.

COLUMNAR EPITHELIUM

The endocervix of the cervix is lined by a single layer of columnar cells, which show dark staining round the nucleus at the base with mucus on the top. On naked-eye inspection, the columnar epithelium appears red, because the color of the underlying stromal vasculature is transmitted through a single layer of columnar epithelium. The columnar epithelium

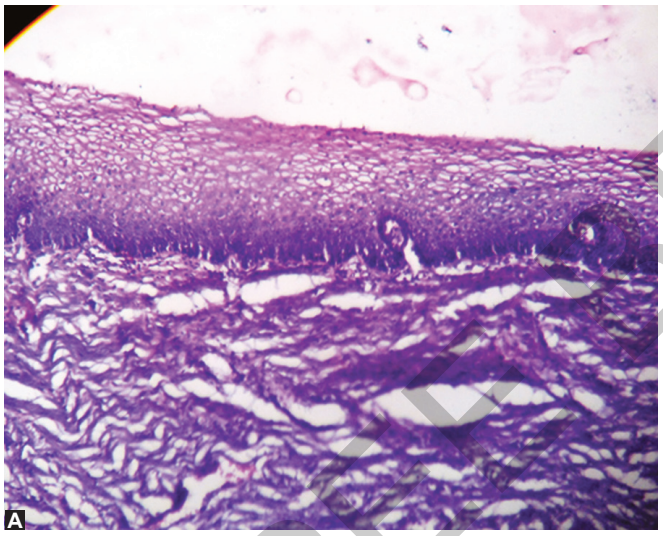

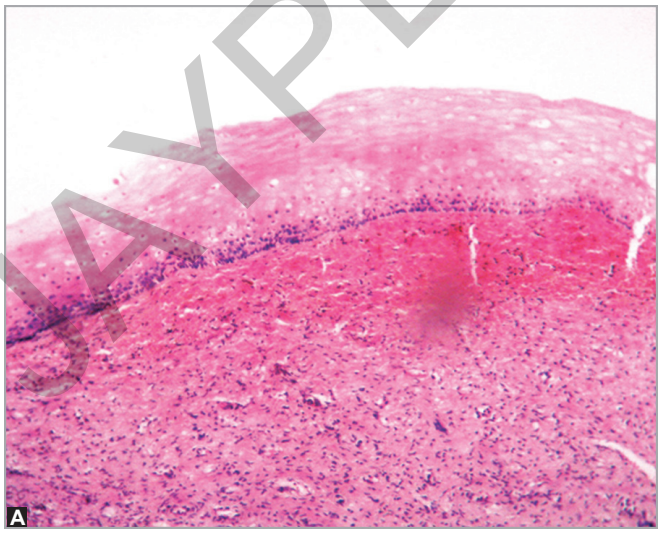

Figures 2-3A and B: Squamous epithelium of normal cervix



Figure 2-4: Postmenopausal cervix with petechial hemorrhages

JAYPEE BROTHERS

also buries into the stroma through the basement membrane producing endocervical ridges and crypts. These infoldings, when covered by squamous metaplasia, give an appearance of gland openings **(Figure 2-5)**. The mouth of these gland openings can get occluded, the mucus collecting within the glands forming what are called nabothian cysts **(Figure 2-6)**.

Occasionally, there may be localized proliferation of endocervical glands to produce what is called endocervical polyp **(Figures 2-7A and B)**.

SHEDDING OF CELLS IN VARIOUS AGE GROUPS[7]

Depending upon the age of the individual and endocrine status, the cytological picture also varies.

Different hormones have different effects on the cellular morphology, namely the degree of maturation, relationship of one cell to another (stickiness, singleness), their cellular contents, and their overall cellular shape (crinkling, flatness).

The exfoliated cells from the cervix include parabasal cells, intermediate and superficial cells. Two morphological features separate these three cell types.

Cytoplasm

- Parabasal cells have thick cytoplasm.
- Intermediate and superficial cell types have wafer-thin cytoplasm.

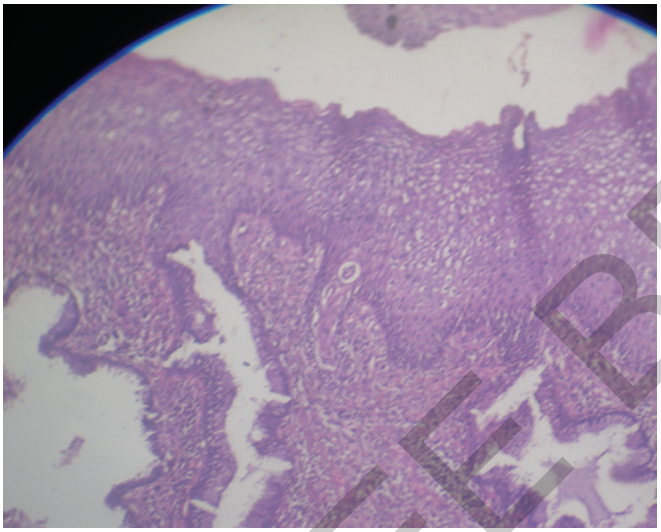

Figure 2-5: Squamous epithelium with endocervical glands

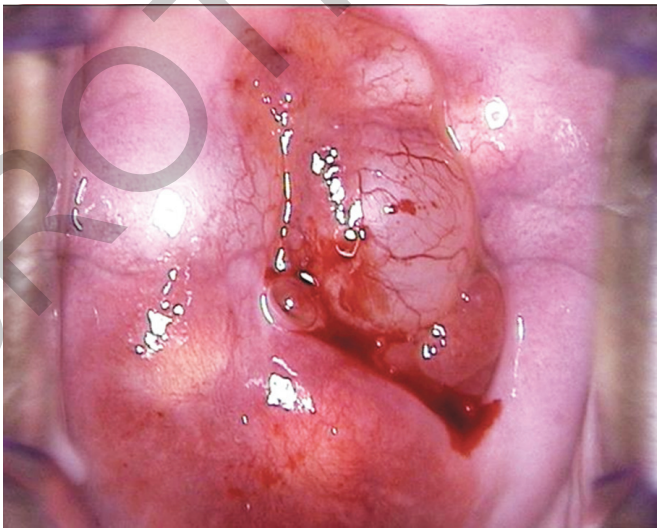

Figure 2-6: Nabothian cyst

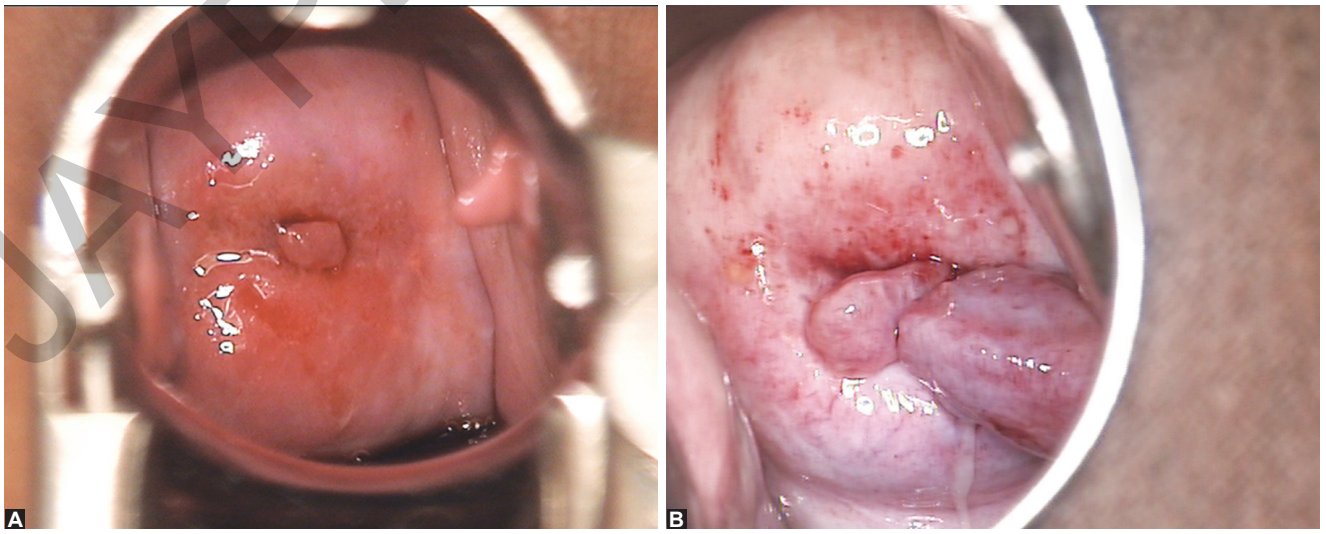

Figures 2-7A and B: Endocervical polyp

JAYPEE BROTHERS

Nuclear Pattern

- In intermediate cell type, the nucleus is metabolic (plump, vesicular, intact chromatin pattern).
- In superficial cells, the nucleus is pyknotic (small, chromatin pattern is lost, hyperchromatic).

EXPOSURE TO ESTROGEN

When exposed to estrogen, the epithelium thickens and proliferates with intermediate and superficial cells. When the exposure to estrogen is more, the percentage of superficial cells is increased. Cellular degeneration and inflammation are reduced or cleared and smear appears 'clean' with cells lying flat and distributed singly.

Exposure to Progestogens

When exposed to progestogens, the epithelium proliferates and matures to intermediate cell stage.

When the epithelium is primed with sufficient estrogen and in the presence of Doderlein's bacillis, cytolysis occurs. Edges of the intermediate cell cytoplasm crinkle or curl up and the cells appear to be sticky and clumped together in masses. The background is messy with mucus, neutrophils and cellular debris.

Childhood Period

In the childhood period, the epithelium is thin and the exfoliated cells are parabasal or intermediate cells (Appearance of superficial cells is abnormal).

Reproductive Age

- In the first half of the cycle, superficial cells predominate with single layer of clear cells. This is the ideal time to take Pap smear.
- In the second half of the cycle, the intermediate cells predominate; they are crowded and curl at the borders. Taking Pap smear during this time is best avoided.

Pregnancy

During pregnancy, there is exaggerated intermediate cell picture due to high levels of progesterone in the body.

Postpartum Period

In the postpartum period, the smears appear atrophic and almost all cells are parabasal.

Postmenopausal Period

In the postmenopausal period, two patterns of cells are seen:

- Intermediate cell atrophy with predominance of intermediate cells and is usually asymptomatic.
- Parabasal cell atrophy (Teleatrophy). At this stage, the tissues get inflamed and infected from organisms, which are usually nonpathogenic. Small amounts of oestrogen will quickly mature the epithelium and heal the infection.

In the postmenopausal period, the superficial cells should be less than 10%.

THE SQUAMOCOLUMNAR JUNCTION (SCJ)

The SCJ is a dynamic point that changes in response to puberty, pregnancy, menopause and hormonal stimulation. In the neonates, the SCJ is located on the ectocervix. At menarche, with the production of estrogen, there is accumulation of glycogen in the cells. Lactobacilli present in the vagina act on the glycogen to lower the pH, which stimulates the sub-columnar reserve cells to undergo metaplasia.[8] Metaplasia advances from the original SCJ inward, towards the external OS and over the columnar villi, eventually forming an active new SCJ. The area between the original SCJ and the new physiologically active SCJ is called the transformation zone (TZ) **(Figure 2-8)**.

The transformation zone is identified by the presence of gland openings and nabothian cysts.

Metaplastic Epithelium

The metaplastic epithelium found at the SCJ begins in the subcolumnar reserve cells. The reserve cells, under the

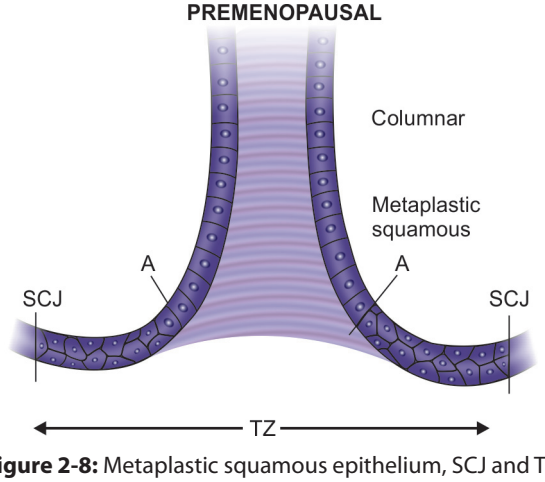

Figure 2-8: Metaplastic squamous epithelium, SCJ and TZ

JAYPEE BROTHERS

stimulation of low pH of vagina, proliferate and lift the columnar epithelium.

The metaplastic process begins at the tips of columnar villi and proceeds into the cervical clefts. However, the deeper clefts may not be completely replaced by the metaplastic epithelium. As a result, mucus-secreting columnar epithelium is trapped under the squamous epithelium. This results in gland openings and nabothian cysts. The immature metaplastic cells have large nuclei with small amount of cytoplasm without glycogen. As the metaplastic cells mature normally, they produce glycogen, eventually forming the four layers of squamous epithelium. Once the metaplastic epithelium matures and forms glycogen, it is called the healed TZ and is relatively resistant to oncogenic stimulation.

Gland openings and nabothian cysts mark the original SCJ and the outer edge of the original SCJ

- Metaplasia is most active during menarche and pregnancy
- In most cases CIN originates as a single focus in the TZ at the advancing SCJ
- Once CIN occurs, it progresses laterally to involve the entire TZ, but usually does not replace the original squamous epithelium
- Proximally, CIN involves the cervical clefts and tends to have most severe CIN lesions, therefore, should be destroyed completely
- The entire SCJ with early metaplastic cells is susceptible to oncogenic stimuli

BLOOD SUPPLY TO THE CERVIX

The arterial supply to the cervix is from the descending cervical branch of uterine artery. These vessels divide and subdivide as they near the external os of the cervix. Therefore, in procedures like cervical biopsy, the bleeding is minimal and can be controlled by packing. In large loop excision of the transformation zone (LLETZ), the depth of cone may be as long as 1.5–2 cm. In these procedures, the active bleeding can be safely coagulated. In cold knife cone biopsy, the descending cervical branch is ligated on either side to minimize blood loss.

NERVE SUPPLY

The nerve supply to the cervix is derived from the hypogastric plexus. There are very few sensory fibers in the ectocervix and is plenty in the endocervix. Therefore, any procedure on the ectocervix such as biopsy, cryotherapy are well tolerated without local anesthesia. Procedures like LLETZ would need paracervical block. The endocervix has an abundance of sympathetic and parasympathetic fibers. Therefore, any manipulation of cervix, such as uterine sounding or endocervical curettage can cause severe pain by stimulating these nerve endings.

JAYPEE BROTHERS

or detailed information on obstetrics & gynecology books, visit our website **www.jaypeebrothers.com,** for detailed informatio

A Practical Approach to Cervical Cancer Screening Techniques

Salient Features

The book explains the practical means of using the various screening techniques in the diagnosis of pre-invasive lesions of the cervix.

- The chapter on etiopathogenesis will help the readers in understanding the basis behind the various techniques used in screening.
- The procedure of Pap test and its interpretation and the precautions while taking the test have been described in detail.
- The chapter on colposcopy explains the tissue basis of colposcopy, which will help the clinicians in understanding and interpreting the colposcopic images with ease. The technique and the interpretation have been described in detail along with the illustrative images.
- The book also includes a chapter on visual inspection methods, which is best suited for screening in developing countries.



T Radha Bai Prabhu MD DGO MNAMS FRCOG FRCS PhD has 33 years of clinical experience in obstetrics and gynecology. She has retired as the Director of the Institute of Obstetrics and Gynecology, Chennai, Tamil Nadu, India, in 2011. Presently, she is working as Professor, Department of Obstetrics and Gynecology at Meenakshi Medical College and Research Institute, Kancheepuram, Tamil Nadu.

After getting her DGO, MD and MNAMS from Government Stanley Medical College, Chennai, she went to the UK for further training. She was awarded the membership of the Royal College of Obstetricians and Gynaecologists (MRCOG), in 1996, and was admitted as Member of the Royal College of Surgeons of Edinburgh (FRCS), in 1997. She was conferred Fellowship of the Royal College of Obstetricians and Gynaecologists (FRCOG) in the year 2009. She was subsequently awarded PhD for her work on "infertility and genital tuberculosis" by "The Tamil Nadu Dr MGR Medical University", in 2010.

She has been an undergraduate and postgraduate teacher since 1982 and examiner for various universities in Tamil Nadu, Kerala, Andhra Pradesh, Karnataka and Maharashtra. She has also been an inspector and examiner for the National Board of Examinations and Indira Gandhi National Open University (IGNOU).

She is the author of more than 80 publications in national and international journals. She has been involved in various national research projects including Indian Council of Medical Research (ICMR). She has delivered more than 150 guest lectures at the national and international conferences. She is actively involved in maternal death audit in Tamil Nadu. She has organized and conducted many workshops on labor and colposcopy. She conducts regular cervical cancer screening camps. She is an active member of Indian Society of Colposcopy and Cervical Pathology (ISCCP) and British Society of Colposcopy and Cervical Pathology (BSCCP). Her areas of special interests are high-risk pregnancy, preventive oncology and infertility.

Available at all medical bookstores or buy online at www.jaypeebrothers.com

JAYPEE BROTHERS
Medical Publishers (P) Ltd.
www.jaypeebrothers.com

Join us on facebook.com/JaypeeMedicalPublishers

Shelving Recommendation
OBSTETRICS & GYNECOLOGY

ISBN 978-93-5152-469-4