website www.jaypeebrothers.com, for detailed information on orthopedic books, visit our website www.jaypeebrothers.com

Recent Advances in SPINAL SURGERY



Alexander R Vaccaro
John D Koerner
Daniel H Kim

JAYPEE

Contents

1. **Spinal Cord Injury: Stem Cells and Pharmacologic Treatment** 1
   Abhijeet B Kadam, Sarah C Nyirjesy, Paul W Millhouse, Christopher Y Kong, Alexander R Vaccaro, Troy I Mounts
2. **Axial Back Pain: Diagnosis** 25
   John D Laughlin, Gaetano J Scuderi
3. **Axial Back Pain: Surgical Treatment** 37
   William A Muñoz, Saad B Chaudhary, Michael J Vives
4. **Molecular Basis of Disc Degeneration and Regeneration** 55
   Zachary R Schoepflin, Hyowon Choi, Zariel I Johnson, Irving M Shapiro, Makarand V Risbud
5. **Disc Arthroplasty: Cervical and Lumbar** 69
   Kasra Ahmadinia
6. **Surgical Site Infection (SSI) in Spine Surgery** 83
   Etienne Schonbach, Caleb Behrend
7. **Spine Imaging: Diagnostic and Intraoperative Techniques** 99
   Joseph H Liao, Amish Doshi, Amish Patel
8. **Cervical Spondylotic Myelopathy: Treatment Options** 117
   Daniel Choi, Michael J Vives, Saad B Chaudhary
9. **Anticoagulation, Venous Thromboembolism, and Prophylaxis in Spine Surgery** 133
   Andrew G Park, John D Koerner, Matthew McDonnell, Kristen Radcliff
10. **Adolescent Idiopathic Scoliosis: Techniques** 141
    Heidi Martin Hullinger, Rex AW Marco
11. **Perioperative Analgesia for Complex Spinal Surgery** 157
    Marc A Dany, Marc W Kauffman, Eugene R Viscusi
12. **What Role Should Spine Surgeons Play in Osteoporosis Treatment?** 183
    Joseph M Lane, Arianna L Gianakos
13. **Recent Advances in Measuring Outcomes in Spine Surgery** 197
    John D Koerner, Jeffrey A Rihn
14. **Sports-Related Injuries** 209
    Steven McAnany, Andrew C Hecht

15. Intraoperative Monitoring During Spine Surgery **223**

Eugene M Martin, Adam T Doan

16. Minimally Invasive Spine Surgery—New Techniques and Complications **241**

Sreeharsha V Nandyala, Alejandro Marquez-Lara, Benjamin C Mayo, Dustin H Massel, Kern Singh

17. Adult Spinal Deformity **255**

Colin MacElroy Vroome, Babak Khamsi, Michael Daubs

Index *271*

Chapter 3

William A Muñoz,
Saad B Chaudhary, Michael J Vives

Axial Back Pain: Surgical Treatment

INTRODUCTION

Low back pain is one of the leading causes of disability worldwide with a significant societal and economic impact. Axial back pain is an epidemic in the United States and developed nations, with a lifetime prevalence of 80% in the adult population.[1] The etiologies of back pain can be diverse with numerous anatomic sites potentially responsible for the pain. This makes an accurate diagnosis sometimes impossible and most often difficult. Conceivable sources of low back pain include degenerative disc disease (DDD), internal disc disruption, facet joint arthrosis, disc herniation, myofascial pain, and certain nonmusculoskeletal conditions including intra-abdominal pathology.

Axial back pain can be defined as midline low back pain with an absence of radicular complaints. Although a vast majority of patients with low back pain present with radiographic changes, images should be interpreted cautiously as many asymptomatic patients have similar X-ray and magnetic resonance imaging (MRI) findings. Low back pain for most patients is a self-limiting condition, and the cornerstone of initial treatment must be conservative management.

A variety of surgical options exist for the minority of patients who fail nonoperative interventions. Arthrodesis has been the primary surgical treatment for this patient population. The rationale behind spinal fusion is to stabilize or immobilize a painful spondylotic motion segment. Several techniques exist to accomplish this end result in the lumbar spine. Motion preserving and emerging technologies including total disc arthroplasty and nucleus replacement provide alternative surgical options for the axial back pain population.

EPIDEMIOLOGY AND NATURAL HISTORY

Low back pain is extremely common, with up to 84% of adults experiencing it during their lifetime.[2] It is also the leading cause of workplace absence and visits to primary care physicians behind the common cold.[3] The adverse economic impact of low back pain includes both direct medical costs and indirect costs associated with lost wages, disability payments, and opportunity costs. A patient who has been out of work for 6 months has a 50% chance of returning to work and this drops of drastically to 25% at 1 year and <5% at 2 years.[4] It is further estimated that between $33 and $55 billion is spent annually in direct medical costs for axial low back pain.[5,6]

Patients with low back pain can present with a spectrum of symptoms from stiffness to excruciating back pain with varied patterns of buttocks and lower extremity complaints. Moreover, it has been suggested that up to 85% of low back conditions cannot be clearly diagnosed with a history, physical examination, and diagnostic evaluation.[7] Several risk factors have been implicated in the development of lumbar DDD and axial back pain. These include smoking, heavy lifting, use of a jackhammer or similar vibratory machine tools, or the operation of motor vehicles.[8] Of note, disabling chronic low back pain is seen more commonly in patients who have a high level of "fear avoidance", disputed compensation claims, psychological distress, job dissatisfaction, and tort compensation involvement.[9-13]

Most cases of low back pain are self-limiting, with resolution of symptoms without treatment in about 20–60% of patients.[14] Although resolution of symptoms is the most common outcome, there is a high recurrence rate, with only 25% of patients seeking treatment for low back pain having full recovery at 1 year.[15] Surgical treatment may be offered to this patient population after failure of > 6 months of multimodality nonsurgical management.

CLINICAL PRESENTATION

Patients with discogenic back pain usually present with a constellation of symptoms that may be vague. Commonly, they describe a deep, aching low back pain that is mechanical in nature and may radiate to the sacroiliac region. Standing, bending, and axial loading often exacerbate symptoms, while rest and lying down may provide relief. Patients may have pain in both flexion and extension, with an associated decrease in the range of motion. Radicular complaints or neurogenic claudication generally is not present, unless there is an associated disc herniation or spinal stenosis.

Physical examination findings are often unremarkable and nonspecific. Reproduction of pain with palpation of the lumbar spine, paraspinal muscles, and sacroiliac joints may be seen. Range of motion in the lumbar spine may be decreased; with flexion resulting in increased pain for disc-based

pathologies and extension causing facet joint mediated pain. Straight leg raise and femoral stretch tests are usually negative.

History and physical examination should also include assessment of renal, vascular, and abdominal pathologies, which may masquerade low back pain. Specifically, be cognizant of renal calculi, aortic aneurysm, pancreatic pathology, and tumors. Questions regarding fevers, unexpected weight loss, night pain, night sweats, and gastrointestinal and urinary symptoms must be asked. Low back pain secondary to disc degeneration must be approached as a diagnosis of exclusion.

IMAGING STUDIES

Weight-bearing anteroposterior and lateral radiographs are initial, inexpensive imaging tests that should be obtained for patients with protracted complaints of low back pain. These images may show disc space narrowing, end-plate sclerosis, marginal osteophytes, foraminal narrowing, instability, facet degeneration, and vacuum phenomenon within the disc. Flexion and extension radiographs may be done if there is concern for spondylolisthesis. Radiographs should be scrutinized to rule out fractures, metastases, and other visceral findings that may mimic low back pain. Computed tomography (CT) scans can provide a significantly improved evaluation of the osseous spine and can be combined with myelography to evaluate for neurologic compression, but its invasiveness and radiation exposure make it a less desirable screening test in most cases.

Magnetic resonance imaging is the imaging study of choice for DDD as it is the most sensitive and accurate modality for diagnosing spinal pathology.[16] Magnetic resonance imaging provides a detailed view of the intervertebral disc, and a normal appearing disc on MRI is unlikely to be the pain generator. Internal disc disruption can be seen on MRI as a high-intensity zone in the annulus fibrosus.[17] However, the significance of these findings have been questioned and not clearly defined.[18]

Other MRI characteristics indicative of disc pathology include disc desiccation, loss of height, and end-plate changes. Modic et al.[19] delineated MRI-based end-plate changes and correlated them with histopathology findings in the degenerative process.[19] Type I changes are reflective of acute end-plate inflammation and are seen as decreased signal intensity on T1-weighted images with increased signal intensity on T2- weighted images. Type II changes correspond with fatty degeneration of the adjacent marrow and demonstrate increased signal intensity on T1-weighted images and slightly increased signal on T2-weighted images. Type III changes correspond to advanced degeneration with associated subchondral bone sclerosis and are manifested by decreased signal intensity on both T1-and T2-weighted images.

Although there is invaluable anatomic detail provided by MRI, the clinical significance of these findings remains elusive. Several authors have reported up to 80% of asymptomatic individuals with no history of low back pain as having disc abnormalities on MRI, which subsequently were not predictive for the development of low back pain at long-term follow-up.[20,21]

Provocative discography has traditionally been used to confirm the diagnosis of discogenic pain. A positive test produces concordant pain with saline injection of a suspected intervertebral disc combined with no pain at an adjoining control level. The limitations of discography include reliance on subjective pain response, patient's psychometric profile, and operator-dependent variability.

Controversy exists in the use of discography as a diagnostic tool. Studies have shown a positive test in 30–80% of asymptomatic patients, especially in patients with psychological distress, previous disc surgery, concurrent pain processes, or disputed compensation claims.[22,23] Moreover, a recent study suggests that discography results in accelerated disc degeneration, disc herniation, and end-plate changes compared with matched-controls at 10-year follow-up.[24] Based on the available literature, discography should not be used as a stand-alone diagnostic measure, but instead it should be utilized only as a confirmatory test in patients who have failed extensive non-operative treatment.

NONSURGICAL MANAGEMENT

The majority of individuals with acute low back pain have resolution of symptoms within 3 months, regardless of treatment. Consequently, conservative care remains the primary focus of treatment[1] First-line nonsurgical management includes nonsteroidal anti-inflammatory drugs, exercise programs, weight loss, and functional rehabilitation. Other nonsurgical modalities that have shown modest improvement include acupuncture, exercise therapy, and behavior therapy.[25] Transcutaneous electrical nerve stimulation and chiropractic treatment have not shown long-term benefits in the treatment of low back pain.[26,27] A multidisciplinary cognitive-behavioral approach has been advocated as the best approach for this patient population.

SURGICAL MANAGEMENT

Lumbar arthrodesis or total disc arthroplasty (TDA) are viable surgical options for patients with intractable discogenic low back pain after failure of extensive nonsurgical management. Other management schemes, currently being investigated, include nucleus replacement and intradiscal biologic therapies.

Surgical treatment can be fairly effective, but remains controversial in this patient population, due to inconsistent clinical results. Turner et al.

reviewed the fusion results over a 25-year period and found the average patient satisfaction rate ranged from 16% to 95%.[28] This discrepancy can likely be attributed to a poor understanding of the exact pathoanatomic cause for intractable pain in many patients with DDD, making it exceedingly difficult to identify individuals who would benefit most from surgical intervention. Response to surgery can be varied and is often affected by patient psychometrics, socioeconomic factors, compensation claims, and unrealistic expectations. Decisions regarding surgical management must be made not only with regard to the structural cause of pain, but must also take patient psychosocial and socioeconomic factors into consideration.

The Swedish Lumbar Spine Study Group has made significant contributions in delineating characteristic traits of patients with chronic low back pain. They reported that patients with low back pain and depression would likely benefit from nonoperative care. Conversely, patients with disc collapse and low level of neuroticism would have an improved outcome with surgery.[29,30] The same group has postulated that sufficient evidence exists in the literature supporting fusion as a more efficacious treatment option than nonsurgical care in the setting of chronic intractable back pain.[31] In a randomized controlled multicenter study comparing fusion with nonsurgical therapy, they reported the fusion group to be significantly better at 2 years with regard to reduced back pain (33% vs 7%). They also found the fusion group to have reduced Oswestry disability index (ODI), improved patient satisfaction, and a higher "net back to work rate" compared with the nonsurgical group.[31]

A recent systematic review by Phillips et al.[32] evaluated patient-reported clinical outcomes for over 3,000 patients who underwent fusion for chronic low back pain. They concluded that lumbar arthrodesis is a viable treatment option for reducing pain and improving function in patients with intractable symptoms of DDD despite prolonged nonsurgical care.

Lumbar Arthrodesis

Lumbar fusion has historically been the "gold standard" surgical treatment for DDD. Choices for spinal arthrodesis include posterolateral fusion (PLF), posterior-based interbody fusion, anterior or lateral interbody fusion, or a combined 360° fusion. Successful surgical treatment for DDD usually requires complete disc ablation and immobilization of the spinal motion segment. These objectives cannot be achieved adequately through a PLF alone. Biomechanical and clinical studies conducted by Zdeblick[33] and Weatherley et al.[34] respectively provide proof of this concept. Weatherley's study reported decrease in pain and increase in function in five patients who underwent anterior lumbar interbody fusion (ALIF) despite an existing solid PLF.[34]

Lumbar Interbody Fusion

Interbody techniques for lumbar fusion provide many potential benefits. The lumbar vertebral body provides a large vascular surface area and supports 80% of the compressive load across the spine. This creates an optimal fusion environment with interbody graft compression leading to a greater fusion potential.[35] In order to obtain adequate fusion, a nearly complete intervertebral discectomy must be performed with meticulous end-plate preparation, followed by implantation with autograft bone, allograft bone, or cage device packed with bone graft and/or bone graft supplements.[36] Various approaches to interbody fusion have been described. These include ALIF, lateral lumbar interbody fusion (LLIF), transforaminal lumbar interbody fusion (TLIF), and posterior lumbar interbody fusion (PLIF). In select cases, a combined 360° approach is utilized to achieve the highest fusion rate (Figs. 3.1A to C).

Anterior Lumbar Interbody Fusion

The anterior approach for lumbar arthrodesis was first described in the 1930s for the surgical management of spondylolisthesis,[37] and later recommended for the treatment of internal disc disruption.[38] Currently employed indications for this technique include DDD, lumbar spondylolisthesis, pseudarthrosis, and instability.[39]

Anterior lumbar interbody fusion is performed through either an intra-abdominal or a retroperitoneal approach. Symptomatic disc spaces are exposed, followed by an annulotomy and complete discectomy. The

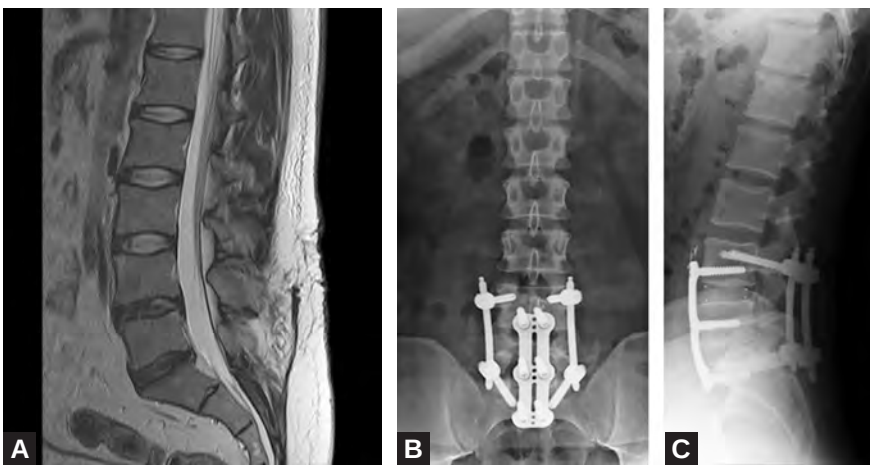

Figs. 3.1A to C: (A) Sagittal T-2 weighted magnetic resonance imaging demonstrating L4-5 and L5-S1 degenerative disc disease in a patient with previous discectomy and severe low back pain. (B and C) Anteroposterior and lateral radiographs of the same patient after undergoing an L4-5 and L5-S1 360° fusion.

intervertebral space is then reconstructed with autograft bone, allograft bone or a cage device packed with bone graft and/or osteobiologic material (Figs. 3.2A to E). Advantages of ALIF include direct access to the intervertebral space with the ability to restore disc height and lumbar lordosis without disrupting the posterior spinal muscles and ligamentous complex. The ALIF technique has been associated with significant patient satisfaction, with fusion rates as high as 89% and clinical success reported at 86%.[40] The reported fusion rate with the use of rhBMP-2 and tapered cage device has been even higher at 94.5%.[41] Complications associated with ALIF include intra-abdominal vascular and visceral injury, inability to directly decompress the neural elements, retrograde ejaculation, pseudarthrosis, and infection.[42,43]

Although the ALIF procedure is a minimally destructive procedure and well tolerated by patients, surgeons have attempted to further minimize the morbidity of this surgery by employing a laparoscopic-assisted or a mini-open technique. These less invasive approaches offer the advantage of a smaller incision and potentially reduced tissue injury. However, they are associated with a steep learning curve, longer preparation, and operative times, and at times higher complication rates when compared with the traditional anterior approach.[44] The mini-open retroperitoneal approach has emerged as the more commonly employed technique. The complication profile of this surgical method is significantly less than that of the laparoscopic group, without the associated morbidity of the traditional approach.[45]

Lateral Lumbar Interbody Fusion

Lateral lumbar interbody fusion is a minimally invasive lateral transpsoas approach to the lumbar spine that was first described in 2001.[46] This procedure has become increasingly popular and differs from other interbody fusion techniques in several ways. A lateral decubitus position is used to allow for retroperitoneal dissection, followed by splitting of the psoas muscle to gain access to the spine and disc via a lateral portal. Discectomy, end-plate preparation, and graft placement are performed using standard interbody fusion principles. Most LLIF procedures are performed for degenerative conditions, such as spondylolisthesis, DDD, degenerative scoliosis, and frequently supplemented with posterior fixation[47,48] (Figs. 3.3A to D). In addition to all the advantages afforded by a traditional ALIF, this technique purports a minimally invasive approach with less tissue dissection/destruction, decreased operative time, less blood loss, less postoperative pain, and shorter hospital stay when compared with open surgery.[49-51] Lateral lumbar interbody fusion does have a unique set of complications, most of which are related to its transpsoas approach. These include lumbar plexus injury, ipsilateral anterior thigh pain, and psoas muscle weakness.[48] However, the complications associated with other spinal fusion techniques including graft subsidence, vertebral body fracture, nonunion, and pseudarthrosis can also occur.[52]

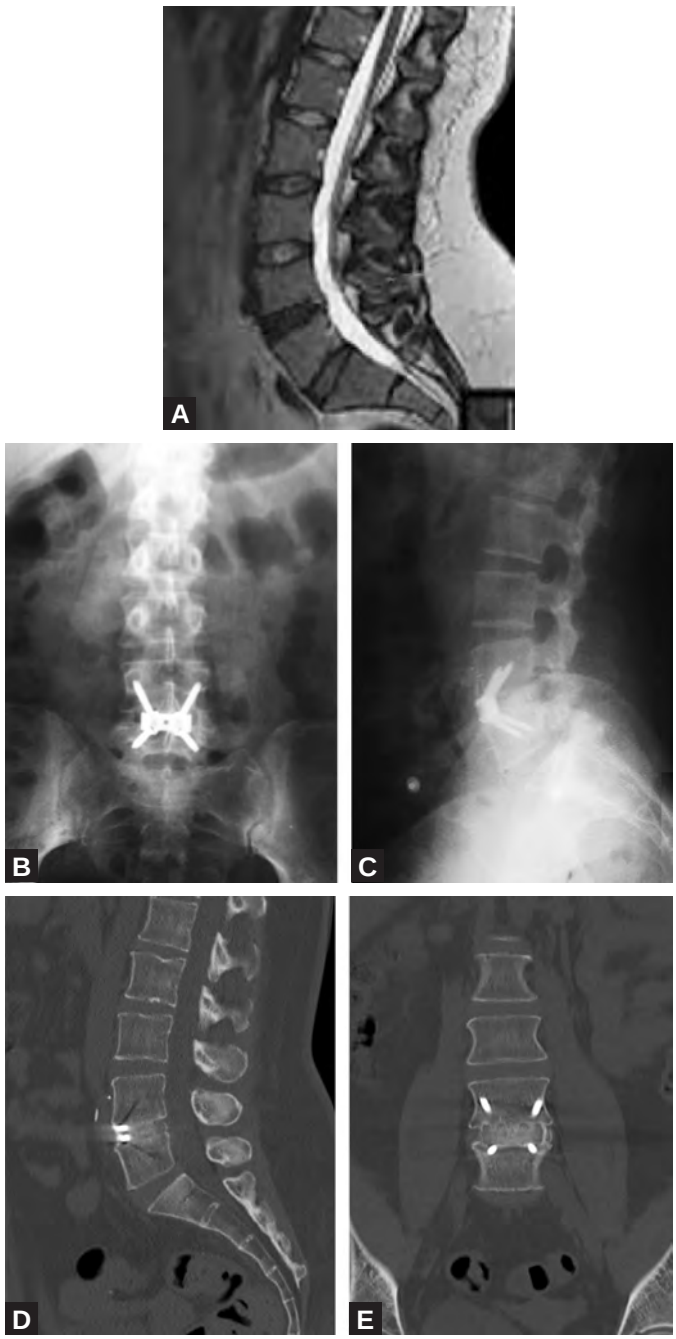

Figs. 3.2A to E: (A) Sagittal T-2 weighted magnetic resonance imaging demonstrating L4-L5 degenerative disc disease in a patient with chronic low back pain. (B and C) Anteroposterior and lateral radiographs reveal an anterior L4-L5 fusion using a stand-alone polyetheretherketone cage with anterior screw fixation. (D and E) Sagittal and coronal computed tomography scans, respectively, reveal a solid arthrodesis in the same patient.



Figs. 3.3A to D: (A and B) Lateral X-ray reveals a well-aligned lumbar spine without obvious signs of degeneration or instability. Sagittal magnetic resonance imaging demonstrates L4-L5 degenerative disc disease. (C and D) Anteroposterior and lateral radiographs demonstrate a lateral L4-L5 fusion using a polyetheretherketone cage packed with bone graft and percutaneous posterior pedicle screw fixation.

Several large studies have reported favorable outcomes of LLIF. Rodgers et al.[53] reported a fusion rate of 96.6% at 1 year, and a clinical satisfaction rate of 89.4%. Ozgur et al.[54] delineated a 91% fusion rate and a 71% clinical success rate based on ODI score improvement at 2-year follow-up. Marchi et al.[55]

found 70.1% significant reduction in visual analog scale (VAS) scores and significantly improved lumbar lordosis at a 2-year follow-up in patients with DDD treated with lateral interbody fusion. Alimi et al.[56] reported significant increase in foraminal and disc height at 12-month follow-up and 84% clinical improvement at 17-month follow-up in 90 patients treated with lateral interbody fusion for degenerative lumbar disorders, with a 4.4% complication rate.

Posterior Lumbar Interbody Fusion

Cloward[57] first described the PLIF in 1953 with almost complete removal of the disc with anterior column fusion all through a posterior approach. Unlike Cloward's initial description, in the modern era of spinal instrumentation, this technique involves pedicle screw fixation with a wide laminectomy and partial or complete facetectomy and discectomy followed by vertebral body end-plate decortication and interbody graft and cage implantation. The advantages of the PLIF procedure include avoidance of an intra-abdominal approach and its risks while retaining the ability of achieving anterior column/intervertebral fusion and restoration of disc height. This technique also permits direct neurologic decompression and PLF all through a single approach. However, PLIF is associated with increased risk of dural retraction with tears, nerve root or conus injury, increased epidural bleeding, and fibrosis.[58] Furthermore, the posterior approach results in muscle and ligamentous complex injury, which is postulated to be responsible for long-term muscle dysfunction, pain, and iatrogenic instability and injury to adjacent segments. Clinical outcomes have been reported as extremely favorable by Lee et al.[59] with a 94% fusion rate and a 96% success rate at relieving back pain. However, other authors have not been as reassuring with Brantigan et al.[60,61] showing only a 56% fusion rate and a 60% clinical success rate. Interestingly, Madan and Boeree[62] reported no difference in outcome for patients treated with ALIF or PLIF for discogenic back pain, while Vamvanij et al.[63] showed decreased fusion rates in PLIF when compared with combined ALIF and posterior facet fusion. It is important to note that superior fusion rates do not always correlate with improved clinical outcomes.

Transforaminal Lumbar Interbody Fusion

Transforaminal lumbar interbody fusion was introduced by Harms as a safer alternative to the PLIF technique in 1982.[64] This technique typically involves a unilateral facetectomy and laminotomy/hemi-laminectomy for disc space access. Once the annulus is isolated, a subtotal discectomy is performed with a standard end-plate preparation followed by bone graft and cage placement. The TLIF procedure is performed concomitantly with pedicle screw fixation

and posterior lumbar fusion of the contralateral lamina, facet and transverse process decortication, and autograft/allograft augmentation. This approach facilitates a three-column stabilization of the spine, and has become a popular procedure to obtain circumferential fusion.[65] The full laminectomy, bilateral partial facetectomy, and excessive dural retraction used in the PLIF technique are obviated. This decreases operative time, blood loss, and risk of dural tears and conus medullaris injury during the transforaminal fusion. Clinical and radiographic outcomes have been favorable using the TLIF technique in managing the degenerative lumbar population. A prospective study of 40 patients who underwent unilateral TLIF with pedicle screw fixation for degenerative lumbar disease reported an overall improvement in segmental lordosis, 90% fusion rate, and excellent or good clinical outcomes in 85% of patients.[66] Another report on 100 patients undergoing the TLIF techniques with 55 documented cases of DDD revealed an overall 93% fusion rate and an approximately 80% patient satisfaction rate.[67]

During the past several years, various modifications including use of tubular retractor systems and microscopic visualization have been incorporated in the TLIF procedure to deliver a less invasive technique (Figs. 3.4A to D). The purported advantages of MIS-TLIF include limited dissection with preservation of the multifidus muscle and midline ligamentous structures minimizing iatrogenic spinal instability.[68] Clinically, this technique has revealed short-term benefits of decreased blood loss, shorter length of hospital stay, and reduced postoperative narcotic use.[69,70] However, there is a steep learning curve associated with these procedures with significantly increased complication rates earlier on in one's experience.[71] Long-term outcomes data is still limited.

Total Disc Arthroplasty

Total disc arthroplasty is an alternative treatment option for patients with axial low back pain. Replacement of the degenerated disc with an anteriorly placed intervertebral prosthesis results in motion sparing surgery. Preservation of motion allows for decreased shear stresses at the adjacent levels and theoretically a decreased risk for adjacent segment disease. As arthroplasty obviates the need for a fusion, adverse events associated with ALIF surgery including pseudarthrosis and graft donor site morbidity can be avoided.[72]

Surgical indications for performing TDA in the lumbar spine remain narrow. Total disc arthroplasty has been approved in the United States for the treatment of isolated discogenic back pain without instability.[72] There are numerous contraindications for TDA, which include facet arthrosis, spondylolysis and spondylolisthesis, scoliosis, osteoporosis, radiculopathy due to lumbar disc herniation, stenosis, obesity, chronic steroid use, pregnancy and previous lumbar fusion, fracture, and infection.[72]

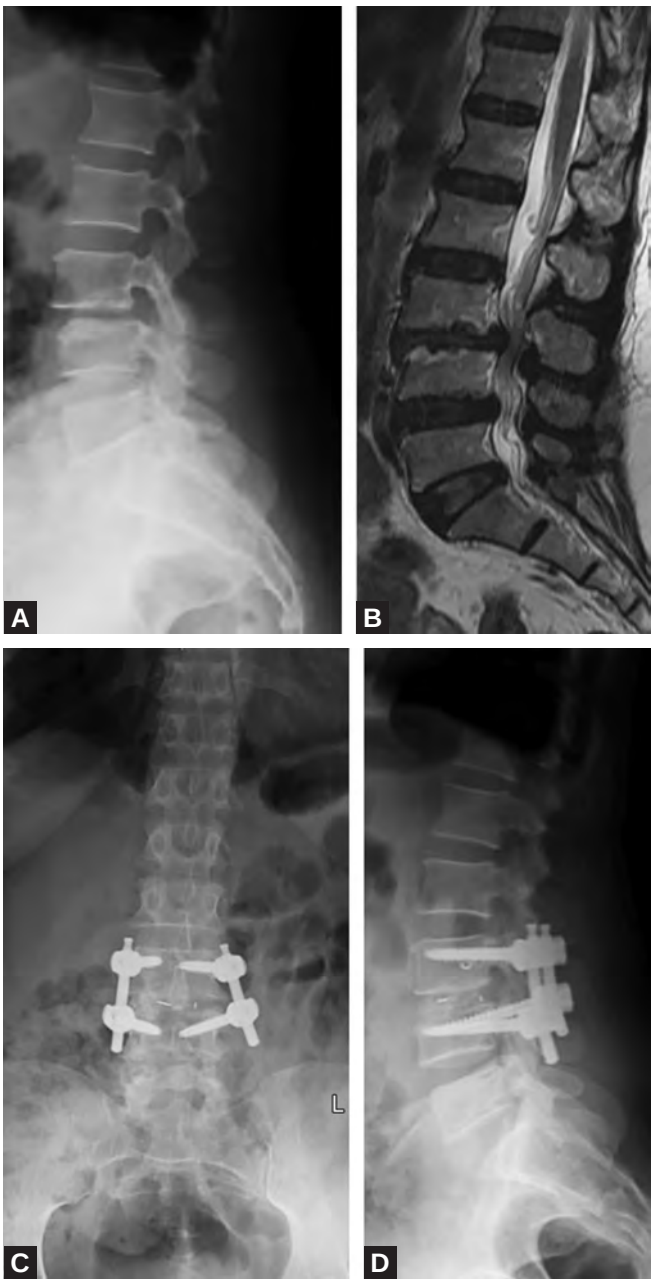

Figs. 3.4A to D: (A) Lateral radiograph shows an L3-L4 degenerative spondylolisthesis. (B) Sagittal T-2 weighted magnetic resonance imaging of the same patient demonstrates severe L3-L4 disc degeneration with Type II Modic changes and accompanying stenosis. (C and D) Anteroposterior and lateral radiographs demonstrate an L3-L4 minimally invasive laminectomy, facetectomy, and transforaminal lumbar interbody fusion using a polyetheretherketone cage packed with autograft bone and percutaneous posterior pedicle screw fixation.

detailed information on orthopedic books, visit our website www.jaypeebrothers.com, for detailed information on orthoped

Recent Advances in SPINAL SURGERY

Salient Features

- Covers the spectrum of spinal conditions and interventions from the molecular basis to advanced surgical interventions.
- Reviews novel pharmacologic and biologic neuroprotective and neuroregenerative strategies for spinal cord injuries.
- Considers variety of surgical options that exist for the minority of patients that fail non-operative interventions.
- Explores total disc replacements for both cervical and lumbar spines in order to maintain intervertebral motion and decrease the incidence of adjacent pathology.
- Discusses most frequently used outcome measures to evaluate spinal surgery and reviews newer tools to predict outcomes and collect data.



Alexander R Vaccaro MD PhD MBA graduated Summa Cum Laude from Boston College, Chestnut Hill, Massachusetts, USA in 1983 with a BS in Biology. He received his MD degree from Georgetown University School of Medicine, Washington DC, USA, where he was promoted with "Distinction". He earned membership in the Alpha Omega Alpha (AOA) Honor Society and graduated with Honors in 1987. He completed a year of Surgical Internship at Cedars-Sinai Medical Center in Los Angeles, California, USA and his Orthopedic Surgery Residency at Thomas Jefferson University in Philadelphia, Pennsylvania, USA, which he finished in 1992. Dr Vaccaro then completed a Spine Fellowship at the University of San Diego, California, USA. He earned PhD in 2007 in the field of Spinal Trauma and is currently pursuing MBA at the Fox School of Business at Temple University in Philadelphia, Pennsylvania, USA.

Dr Vaccaro is the Richard H Rothman Professor and Chairman of Orthopedic Surgery and Professor of Neurosurgery at the Sidney Kimmel Medical College at Thomas Jefferson University in Philadelphia, Pennsylvania, USA. He was the recipient of the Leon Wiltse award given for excellence in leadership and clinical research for spine care by the North American Spine Society (NASS) and is the past President of the American Spinal Injury Association and current President of the Association for Collaborative Spine Research.

He has over 610 peer-reviewed and 200 non-peer-reviewed publications. He has published in excess of 300 book chapters and is the editor of over 46 textbooks and co-editor of OKU-Spine I and editor of OKU-8. Dr Vaccaro is the Co-Director of the Regional Spinal Cord Injury Center of the Delaware Valley, Doylestown, Pennsylvania, USA and Co-Chief of Spine Surgery and the Spine Fellowship program at the Sidney Kimmel Medical College at Thomas Jefferson University, Philadelphia, Pennsylvania, USA, where he instructs current fellows and residents in the diagnosis and treatment of various spinal problems and disorders.



John D Koerner MD graduated from Wake Forest University, Winston-Salem, North Carolina, USA, with a BS in Business and Minor in International trade before completing a premedical post-baccalaureate at Rutgers University, New Brunswick, New Jersey, USA. He received his medical degree from the University of Medicine and Dentistry of New Jersey, Newark, New Jersey, USA, where he also completed his residency in Orthopedic Surgery. Dr Koerner completed a combined research and clinical Spine Fellowship at Thomas Jefferson University/Rothman Institute in Philadelphia, Pennsylvania, USA. He has authored numerous peer-reviewed publications and received the North American Spine Society award for Outstanding Paper for Basic Science in 2012. He also serves as a Deputy Editor for Journal of Spinal Disorders and Techniques.



Daniel H Kim MD FAANS FACS is a Neurosurgeon and Director of Reconstructive Spinal and Peripheral Nerve Surgery at the Memorial Hermann Mischer Neuroscience Institute, Houston, Texas, USA. He is also Professor and Nancy, Cliver and Pierce Runnells Distinguished Chair in Neuroscience, Vivian L Smith Department of Neurosurgery at UTHealth Medical School, Houston, Texas, USA. Additionally Dr Kim is Adjunct Professor in the Department of Bioengineering, Electrical Engineering and Computer Science at Rice University, Houston, Texas, USA. Dr Kim received a degree in chemical engineering from the University of Oklahoma, Norman, Oklahoma, USA, before earning his medical degree at Tulane University School of Medicine, New Orleans, Los Angeles, USA. He then completed his neurosurgery residency at Louisiana State University, Baton Rouge, Los Angeles, USA and fellowship in spine surgery at the University of Florida, Gainesville, Florida, USA.

Available at all medical bookstores or buy online at www.jaypeebrothers.com

JAYPEE BROTHERS Medical Publishers (P) Ltd.
www.jaypeebrothers.com

Join us on facebook.com/JaypeeMedicalPublishers

Shelving Recommendations
MEDICINE, CLINICAL SURGERY, ORTHOPEDICS, SPINE

ISBN 978-93-5152-491-5