website **www.jaypeebrothers.com,** for detailed information on orthopedic books, visit our website **www.jaypeebrothers.com**

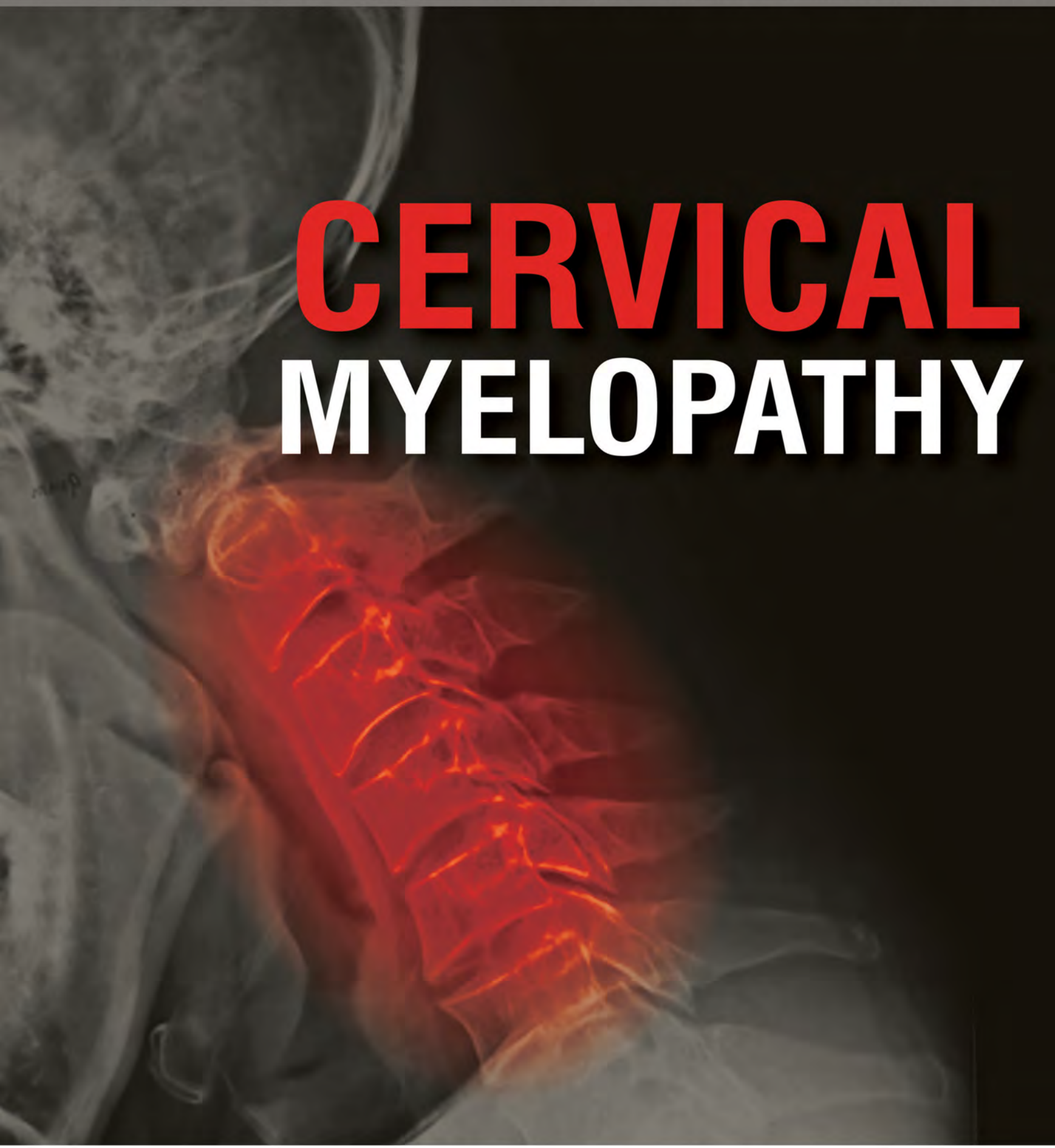

CERVICAL MYELOPATHY

Peter G Passias

JAYPEE

Contents

Section 1: Introduction

1. **Anatomy and Embryology of the Skull Base and Cervical Spine** 3
   Carolina G Benjamin, Donato Pacione
2. **Cervical Biomechanics and Clinical Instability** 15
   Shaobai Wang
3. **Cervical Alignment** 25
   Shaleen Vira, Matthew A Spiegel, Virginie Lafage, Frank Schwab
4. **Clinical Diagnosis of Cervical Myelopathy** 33
   Brett M Walker, Kristen Radcliff
5. **Electrodiagnostics** 43
   Athena Lolis, Anna Shor, Aleksandar Beric

Section 2: Outcomes

6. **Natural History of Cervical Spondylotic Myelopathy** 57
   Christopher D Witiw, Michael G Fehlings
7. **Influence of Conservative Management on Outcomes** 67
   Jerry Cheriyan, Elizabeth Tanzi, Peter G Passias, Thomas Cheriyan
8. **Influence of Surgical Intervention on Outcomes** 73
   Hisashi Yoshimoto

Section 3: Distinct Diagnostic Etiologies

9. **Cervical Amyotrophy** 87
   Venu M Nemani, Han Jo Kim
10. **Rheumatologic Disorders of the Cervical Spine** 93
    Afshin E Razi, Lana Nirenstein, Yong Kim
11. **Ossification of the Posterior Longitudinal Ligament** 103
    Nikhil A Sahasrabudhe, Russell G Strom, Michael L Smith
12. **Os Odontoideum** 109
    Peter G Passias, Cyrus M Jalai
13. **Atlantoaxial Dislocations** 117
    Shenglin Wang, Chao Wang
14. **Basilar Invagination** 133
    Andrew J Grossbach, Arnold H Menezes
15. **Congenital Anomalies of the Cervical Spine** 143
    Peter G Passias, Cyrus M Jalai, Nancy Worley

Section 4: Surgical Management

16. **Surgical Management of Cervical Spondylotic Myelopathy: Anterior Techniques** 149
Michael Gerling, Nancy Worley

17. **Cervical Laminectomy with or without Fusion** 157
Hiroyuki Yoshihara

18. **Cervical Laminoplasty: Techniques and Outcomes** 167
John A Buza III, Themistocles S Protopsaltis

19. **Instrumentation Techniques of the Occiput, Upper Cervical Spine, and Subaxial Spine** 177
Afshin E Razi, Yong Kim, Ahmed Saleh

20. **Neurological and Vascular Complications after Surgery for Cervical Myelopathy** 189
Hideki Sudo

Section 5: Cervical Myelopathy in the Setting of Cervical Deformities

21. **Cervical Myelopathy in the Setting of Cervical Deformities** 201
Shaleen Vira, Matthew A Spiegel, Virginie Lafage, Frank Schwab

Section 6: Cervical Myelopathy in the Setting of Spine Tumors

22. **Cervical Myelopathy in the Setting of Metastatic Tumors in the Spine** 213
Mohamad Bydon, Rafael De la Garza-Ramos Daniel M Sciubba, Ziya L Gokaslan

23. **Cervical Myelopathy in the Setting of Intramedullary Spinal Cord Tumors** 221
Akwasi Ofori Boah, Donato Pacione, Anthony K Frempong-Boadu

24. **Role of Total Disk Replacement for the Treatment of Cervical Myelopathy** 237
Emmanuel N Menga, Shaleen Vira, John A Bendo

Index *243*

Chapter 3

Cervical Alignment

Shaleen Vira, Matthew A Spiegel, Virginie Lafage, Frank Schwab

INTRODUCTION

The history of spinal deformity dates back to Hippocrates, the father of medicine, who described spinal curves in his book, "On Bones and Joints."[1] In the times of antiquity, understanding alignment of the spinal column was limited to gross qualitative descriptions based on cadavers and prone patient positioning. Since then, cervical alignment, as a discipline that informs the diagnosis and treatment of myelopathy, has grown to a robust subspecialty within cervical spine surgery.

More recently, a great revolution in spinal deformity examination occurred after Roentgen discovered radiographic imaging, X-rays.[2] Consequently, health care providers are now able to visualize spinal deformities first documented by Hippocrates in two dimensions, and without direct visualization through dissection. X-rays remain the primary modality used to evaluate cervical alignment in myelopathic patients.

SIGNIFICANCE OF SPINAL ALIGNMENT

Humans require an erect stance for locomotion. During hominid evolution, the pivotal landmark that afforded bipedalism was the acquisition of sagittal balance of the trunk on the lower limbs.[3] Specifically, an ideal compromise between mobility and stability was reached by the evolution towards the double S shape of the vertebral column.[4] *Homo sapiens* is the only species to have both a lumbar and cervical curvature. The pelvic vertebra, the keystone of equilibrium, participated in this evolution by progressive widening and retroversion; this enabled the acquisition of erect posture. The alignment of the spinal column allows humans to carry food, hunt, use tools, and participate in parenting.

The vertebral column serves to provide support and balance to the human body. Specifically, the spine is the primary means by which the body can maintain an upright posture and a horizontal gaze. Dubousset asserted that there exists a conus within which the whole body can maintain an upright posture. His conus ranges from the "cone of economy," representing minimal exertion, to the "cone of maximum work," which is the upper limit of energy expenditure.[5] Specifically, he visualized a conus of balance for the standing position, in which the feet are located within a zone called the "polygon of sustentation", and the body, under the influence of muscle function and ligamentous support, can move in a conical fashion without moving the feet.[5] He further expanded his concept of "conus of economy", where the body can stay balanced with minimal muscle action.[5]

The body adapts to changes in balance in order to regulate the center of gravity (COG) over as narrow a perimeter as possible.[6] This fundamental tendency towards equilibrium is what drives compensatory changes in the spine as it attempts to adapt to pathological processes that are global, regional, or focal. To maintain a center of mass over the feet, the body recruits truncal rotation or translation, thoracolumbar curvature, and pelvic and lower limb compensatory mechanisms. While the cervical spine may play less of a role in this capacity, it likely plays a greater role in maintaining horizontal gaze due to its proximity to the cranium. Furthermore, changes in cervical alignment, in turn, contribute towards the development of pathologic conditions that can eventually contribute to myelopathy.

RADIOGRAPHIC PARAMETERS

The cervical spine is the most mobile part of the spinal column. To fully evaluate the cervical spine, 3-ft X-rays are recommended. With this modality, most radiographic parameters for sagittal alignment can be measured.

Craniocervical Region

One of the first attempts to quantify alignment was in 1885 describing the Frankfurt horizontal line, defined as

JAYPEE BROTHERS

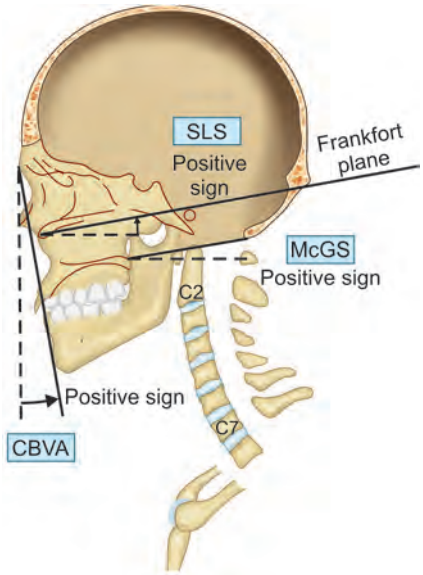

Fig. 3.1: Chin-brow vertical angle (CBVA), and CBVA surrogates: slope of line of sight and McGregor slope.

an extended line connecting the lower border of the orbit and the external auditory meatus.[7] Since then, a plethora of parameters to quantify alignment in the cervical and thoracolumbar spine have been developed.

The chin-brow vertical angle (CBVA) is a useful parameter for understanding a patient's ability to maintain horizontal gaze. Loss of the ability to maintain horizontal gaze has a significant negative impact on activities of daily living and quality of life (QOL).[8] Chin-brow vertical angle is defined as the angle subtended between a line drawn from the patient's chin to brow, and a vertical line (Fig. 3.1).[8]

A limitation of CBVA is that it is not readily measured on most standing lateral spine radiographs. Slope of line of sight (SLS) and McGregor slope (McGS) (Fig. 3.1) are two surrogate measures of horizontal gaze that are more readily available and have been found to be strongly correlated with CBVA.[9] Slope of line of sight, also known as the slope of Frankfort line, is subtended by the anteroinferior margin of orbit to the top of the external auditory meatus.[7] McGregor slope is a line subtended by the posterior margin of the hard palate and the most caudal part of the occiput.[10]

The maintenance of horizontal gaze is an important goal of craniocervical alignment. Normal CBVA values have not been specifically studied in asymptomatic volunteers, but in the postoperative settings patients appear to tolerate values of −10° to +10°.[11,12] Recently, the following CBVA range of values were found to be correlated with low disability: CBVA = [–4.7°; 17.7°]. Similarly, the following range of values for SLS and McGS has been elucidated: SLS = [–4.1°; 18.5°]; McGS = [–5.7°; 14.3°].[9]

Cervical Region

There are several methods to assess cervical lordosis (CL), each with its benefits and limitations. The Cobb angle method, most widely used, measures lordosis from either C1-C7 or C2-C7. The first line is drawn either parallel to the inferior endplate of C2, or extending from the anterior tubercle of C1 to the posterior margin of the spinous process. The second line is drawn parallel to the inferior endplate of C7. Orthogonal lines are then drawn from each of the two lines noted in the earlier text. The angle subtended between the crossings of the perpendicular lines is the cervical curvature angle.[13,14] Less commonly used, the Harrison posterior tangent method, involves drawing parallel lines to the posterior surfaces of cervical vertebral bodies, C2-C7, and summing segmental angles for the total angle.[13] Finally, the Jackson physiological stress lines method requires drawing parallel lines from posterior surfaces of C2 and C7 vertebral bodies, and measuring the angle between them.[14]

Every radiographic parameter has its benefits and limitations. The C2-C7 lordosis is easily measured, is widely accepted, and has reference values (5–20°). However, age-related degenerative changes affect what is considered a "normal" value. Furthermore, individual variation and morphotypes of the human body make it challenging to adapt to all patients. As Faline et al. described, only 29% of asymptomatic patients had lordotic alignment above 10°.[15] Indeed, distinguishing between normal variants and pathology remains a challenge. Finally, in comparison to other parameters, as Ames et al. summarized, it has been suggested that the Cobb, C1-C7 angle, overestimates CL, the Cobb C2-C7 underestimates CL, while the Harrison method provides the best estimate of lordosis.[13,14] Despite this finding, the Cobb method remains the clinical mainstay of CL measurements due to its ease of use, as well as its robust intra- and inter-rater reliability.

The C2-C7 sagittal vertical axis (cSVA) is defined as the offset from C2 plumbline (PL) to the posterosuperior corner of C7. It is a measure of regional alignment of the cervical spine and normative values have been established at 1.5 cm +/– 1 cm.[16] The benefits of this measure are that it correlates with health-related QoL and it is easy to measure. Approximately 4 cm of C2-C7 SVA corresponds to a Neck

JAYPEE BROTHERS

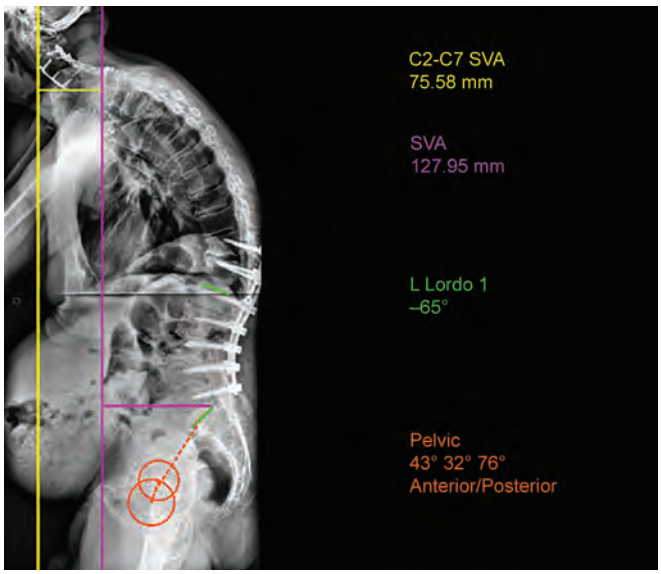

Fig. 3.2: Film emphasizing the sagittal vertical axis measurements.

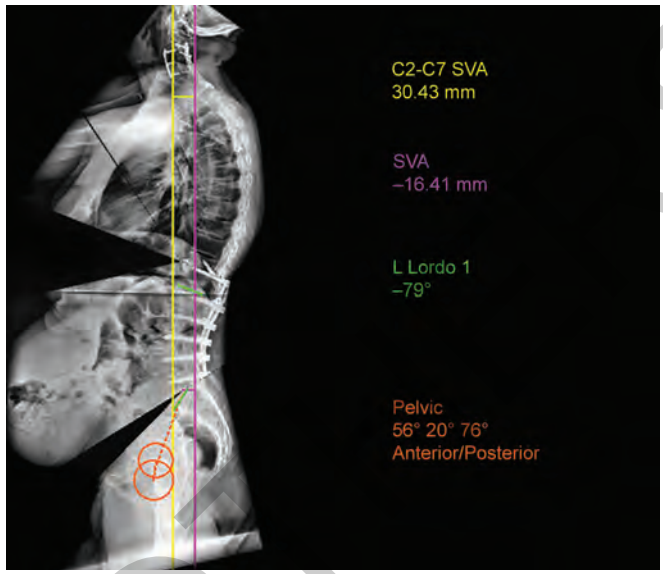

Fig. 3.3: Note the decreased cervical sagittal vertical axis as compared with Figure 3.2, secondary to compensatory changes.

Disability Index (NDI) of 25.[6] However, it requires calibrated images. Moreover, it can be affected by thoracolumbar deformity. For example, in Figure 3.2, C2-C7 PL is 7.5 cm. Is this a driver or consequence of deformity outside the cervical spine? The patient has global malalignment and pelvic retroversion and thoracolumbar kyphosis, due to proximal junctional kyphosis, may be the true driver of the cervical deformity. This illustration emphasizes the need to remove thoracolumbar compensatory mechanisms to evaluate the cervical spine. Figure 3.3 shows that when the compensatory mechanisms are accounted for, C2-C7 SVA is decreased. Indeed, there is a limit to the utility of any PL and one requires a global vision of the patient with a bottom to top analysis for truly understanding cervical alignment pathology.

Cervicothoracic Junction

In recent years, there has been a proliferation of novel parameters that have facilitated our understanding of cervical alignment, with their complex relations to QOL and surgical outcomes. For example, investigators have focused attention on the cervicothoracic junction as an important contributor to cervical alignment. The basis of this relationship goes back to the primary role of the spine: maintenance of horizontal gaze.

The shape and orientation of the thoracic inlet helps maintain a balanced upright posture.[17] Accordingly, Lee et al. introduced neck tilt (NT) and thoracic inlet angle (TIA), as radiographic parameters.[17] Neck tilt as they defined it is an angle between two lines, both originating from the upper end of the sternum, with one being a vertical line and the other connecting to the center of the T1 endplate. Thoracic inlet angle, as they defined it, is the angle between an orthogonal line through the center of the T1 endplate, and a line drawn from center of the T1 endplate to the upper end of the sternum. Subsequent to this, Lee et al. discovered the fundamental relation that TIA is equal to the T1 slope (T1S) (angle between the horizontal plane and T1 endplate), plus NT.[17] This is analogous to the established relationship of the lumbar spine, in which pelvic incidence (PI) equals the sacral slope, plus pelvic tilt.

The TIA is clinically relevant because it has been found to be significantly correlated with cranial offset and craniocervical alignment.[17] A small TIA creates a small T1S and a small CL angle, for which to maintain physiological neck tilting, and vice versa.[14] Lee et al. explained that the TIA and T1S may be used for evaluation of sagittal balance, prediction of physiological alignment, and guidance of deformity correction in the cervical spine.[17] The T1S determines the amount of subaxial lordosis required to maintain COG of the head in a balanced position, and varies depending on global spinal alignment, as measured by SVA and by the inherent upper thoracic kyphosis (TK). In patients with scoliosis, the T1S has been shown to correlate directly with SVA (as measured from

JAYPEE BROTHERS

Table 3.1: Correlations between T1 slope, C2-C7 sagittal vertical axis (SVA), C2-C7 lordosis, and T1 slope, C2-C7 lordosis.

Parameter	*Parameter*	*Pearson (r)*
C2-C7 SVA	C2-C7 lordosis	0.45
C2-C7 SVA	T1 slope	0.44
C2-C7 lordosis	T1 slope	0.38

Source: Ames CP, Blondel B, Scheer JK, et al. Cervical radiographical alignment: comprehensive assessment techniques and potential importance in cervical myelopathy. Spine (Phila Pa 1976). 2013;38:S149-60.

Table 3.3: Normal cervical lordosis values for men and women in different age groups in asymptomatic adults from literature.

Age	*Male (°)*	*Female (°)*
20–25	16 ± 16	15 ± 10
30–35	21 ± 14	16 ± 16
40–45	27 ± 14	23 ± 17
50–55	22 ± 15	25 ± 11
60–65	22 ± 13	25 ± 16

Source: Ames CP, Blondel B, Scheer JK, et al. Cervical radiographical alignment: comprehensive assessment techniques and potential importance in cervical myelopathy. Spine (Phila Pa 1976). 2013;38:S149-60. Values presented as the means ± SD.

a C2 odontoid PL), to provide a measure of overall sagittal alignment.[18] The significant correlations between T1S and C2-C7 lordosis, T1S and C2-C7 SVA, as well as C2-C7 SVA and the difference between T1S and C2-7 lordosis, are well illustrated in Table 3.1. Generally, C2-C7 lordosis should be proportional to T1S.[19,15]

Recently, an objective target of how much CL is required was developed as follows: T1S minus C2-C7 lordosis (TS-L) of 17° correlates with a C2-C7 SVA of 4 cm.[20] This can provide an objective target of how much lordosis is required based on T1S, thus underscoring the importance of cervicothoracic junctional radiographic parameters on understanding cervical alignment.

Normal Cervical Alignment

The cervical spine affords neck mobility, and there exists significant normal variation to the extent each level contributes to this versatility. Table 3.2 depicts the normal segmental cervical angles in asymptomatic adults.[16] In addition, there are slight gender- and age-related differences in CL (Table 3.3).[21] In asymptomatic normal volunteers, the mean total CL is approximately –40°.[16] The

Table 3.2: Normal segmental cervical angles in asymptomatic adults from literature.

Level	*Angle (°)*
C0-C1	2.1 ± 5.0
C1-C2	–32.2 ± 7.0
C2-C3	–1.9 ± 5.2
C3-C4	–1.5 ± 5.0
C4-C5	–0.6 ± 4.4
C5-C6	–1.1 ± 5.1
C6-C7	–4.5 ± 4.3
Subtotal (C2-C7)	–9.6
Total (C1-C7)	–41.8

Source: Ames CP, Blondel B, Scheer JK, et al. Cervical radiographical alignment: comprehensive assessment techniques and potential importance in cervical myelopathy. Spine (Phila Pa 1976). 2013;38:S149-60. Values presented as the means ± SD and the negative sign indicates lordosis in the segmental values.

C1-C2 articulation is responsible for the largest percentage, 75–80%, of cervical standing lordosis.[16,22] This can be explained by the idea that the COG of the head sits directly above the centers of the C1 and C2 vertebral bodies.[23] The lower cervical levels are responsible for the remaining lesser portion of lordosis. C4-C7 is only responsible for approximately 6°, or 15%, of lordosis.[16] The mean C2-C7 sagittal Cobb angles for those in their 20s and those older than 60 years are reported to be –8.98° (standard deviation = 10.98°) and –13.70° (standard deviation = 10.48°), respectively (Table 3.4).[24] Finally, with respect to the odontoid-C7 PL distance, average values range from 15 to 17 +/–11.2 mm (Table 3.5).[16]

Thoracic and Lumbar Regions

The simple concept that the cervical spine is connected to the thoracolumbar spine implies that the cervical spine cannot be studied in isolation. The long-established thoracic, lumbar, and pelvic parameters all play a role in determining cervical alignment.

For example, there is a known regional parameter chain of correlation, such that PI correlates with lumbar lordosis (LL), which correlates with TK, which finally correlates with CL (Figs. 3.4 and 3.5). Conversely, there is a lack of direct correlation found between PI and TK, making this chain of correlation, from pelvis to cervical spine, more complicated. The current view is that LL is proportional to PI and TK. Pelvic incidence is a fixed

JAYPEE BROTHERS

Table 3.4: Comparison of sagittal alignment and angle parameters between the younger and older groups.

	Young		*Old*	
	Mean	*SD*	*Mean*	*SD*
C2-C7 (mm)	+13.21	7.22	+13.68	9.86
S1-C2 (mm)	+11.81	30.49	+32.60	40.88
S1-C7 (mm)	+1.27	31.92	+20.54	41.63
T apex to C2 (mm)	+62.14	16.70	+78.25	31.40
T apex to C7 (mm)	+49.36	16.12	+66.87	26.97
L apex to C2 (mm)	–33.28	28.62	–12.33	40.75
L apex to C7 (mm)	–44.95	30.56	–23.92	41.41
C0-C2 (°)	–16.44	7.89	–14.44	8.79
C2-C7 (°)	–8.98	10.98	–13.70	10.48
T1-T12 (°)	+39.00	11.52	+33.37	17.94
L1-S1 (°)	–49.46	11.45	–45.59	19.63
T1 slope (°)	+23.76	7.06	+19.96	6.77

Source: Park MS, Moon S-H, Lee H-M, et al. The effect of age on cervical sagittal alignment: normative data on 100 asymptomatic subjects. Spine (Phila Pa 1976). 2013;38:E458-63.

Table 3.5: Normal cervical sagittal vertical axis (cSVA) values in asymptomatic adults from literature.

cSVA in Asymptomatic Adults (mm)	
Odontoid marker at C7	15.6 ± 11.2
Odontoid marker at sacrum	13.2 ± 29.5

Source: Ames CP, Blondel B, Scheer JK, et al. Cervical radiographical alignment: comprehensive assessment techniques and potential importance in cervical myelopathy. Spine (Phila Pa 1976). 2013;38:S149-60. Values presented as the means ± SD.

parameter and TK has little flexibility. Subjects with a small PI or a small TK are shown to have smaller LL than subjects with small PI and large TK. This demonstrates that TK is not a result of LL, but rather LL is a result of TK and PI. The increase in CL as TK increases is not large enough to maintain the head over the pelvis, but it does provide adequate maintenance of horizontal gaze.[25,26] Understanding thoracolumbar alignment is important because surgical correction of global balance at the thoracolumbar area can, in some cases, spontaneously improve cervical alignment.[27]

Sagittal Plane Translation

Sagittal plane translation of the cervical spine can be measured in different ways but the common theme among these methods is the concept of the already described above, the cervical SVA. Sagittal vertical axis in general measures a horizontal distance between a PL dropped from a defined point and another defined point, commonly the posterior superior corner of the sacrum. Again, in terms of cervical regional alignment, a cervical SVA can be defined as the distance between a PL dropped from the centroid of C2 (or odontoid) and the posterior superior aspect of C7. This is known as the C2-C7 SVA (Fig. 3.6).[14] Meanwhile, global sagittal alignment can be defined using either the C2 SVA or the C7 SVA. These parameters are used to measure the distance from the respective C2/C7 PLs to the posterior superior corner of the sacrum.[14] Another parameter used in global sagittal alignment analysis is the gravity line. The gravity line is similar to the C7 SVA, in that a PL is again dropped, but this time, from the head's COG.[28,29] The COG can be approximated on lateral radiographs using the anterior portion of the external auditory canal as an initial point for the PL (Fig. 3.7).[23]

RADIOGRAPHIC PARAMETERS AND MYELOPATHY ASSOCIATION

The true value of the cervical parameters discussed above lies in how they correlate with clinical measures of pain and disability. There has been a plethora of studies regarding this topic and they center on the theme of how sagittal malalignment leads to disability. However, depending on the patients studied and the methods used, there is some

JAYPEE BROTHERS

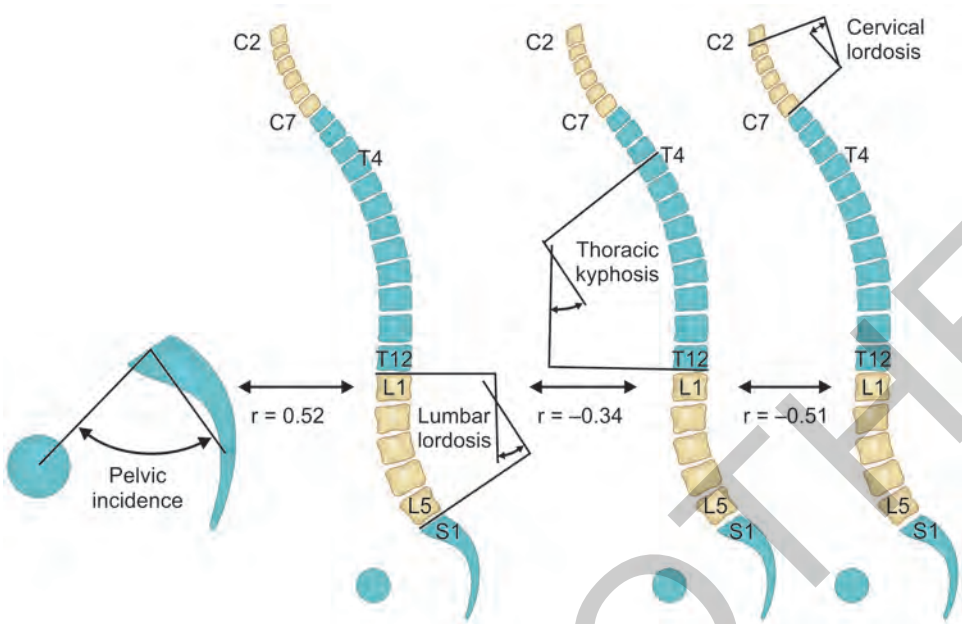

Fig. 3.4: Chain of correlation between pelvic incidence (PI) and regional sagittal parameters with the corresponding Pearson coefficient r values. A large PI requires a large lumbar lordosis (LL). An increase of LL is correlated with an increased TK, which is correlated with an increased cervical lordosis.

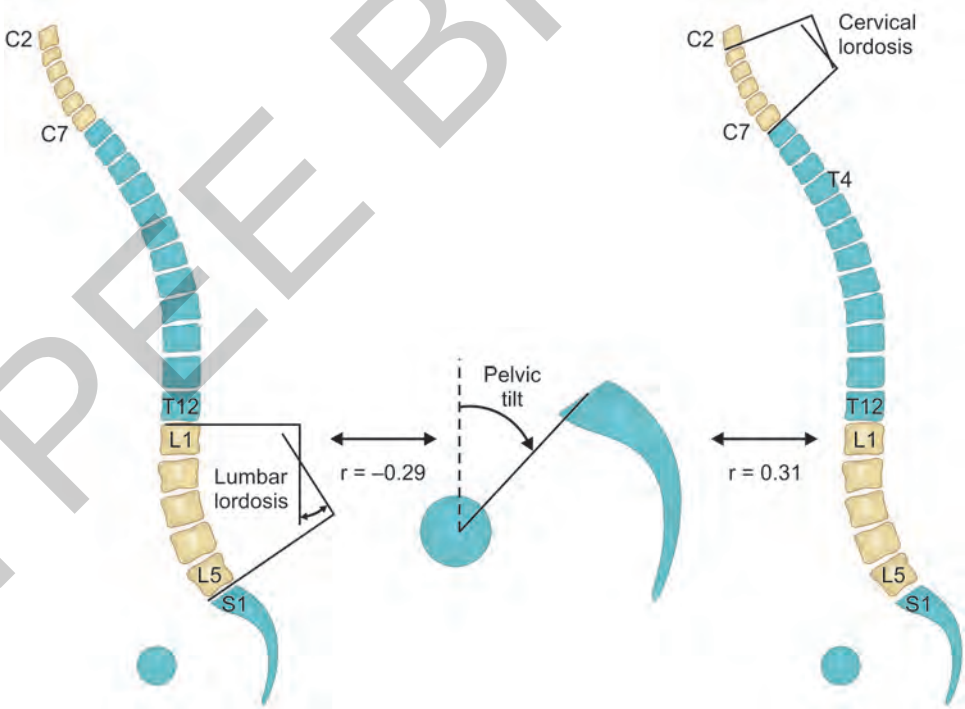

Fig. 3.5: Correlation between pelvic tilt and lumbar/cervical lordosis (CL). A loss of lumbar lordosis is correlated with a pelvic retroversion acting as compensatory mechanisms. Pelvic retroversion is also correlated with an increased CL.

JAYPEE BROTHERS

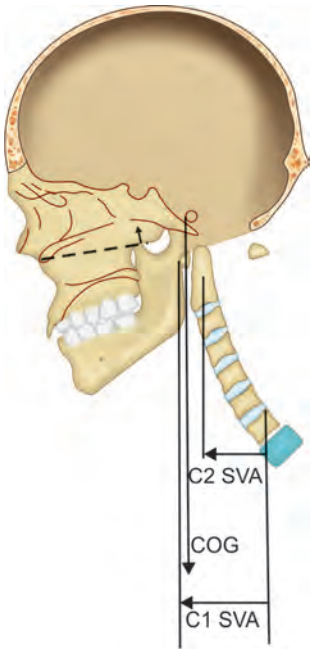

Fig. 3.6: Visual representation of the technique used to measure cervical sagittal vertical axis (SVA). C1 SVA is the distance between plumbline (PL) dropped from anterior tubercle of C1 and posterior superior corner of C7, C2 SVA is the distance between PL dropped from centroid of C2 and posterior superior corner of C7, and COG (center of gravity) is the distance between PL dropped from anterior margin of external auditory canal and posterior superior corner of C7.

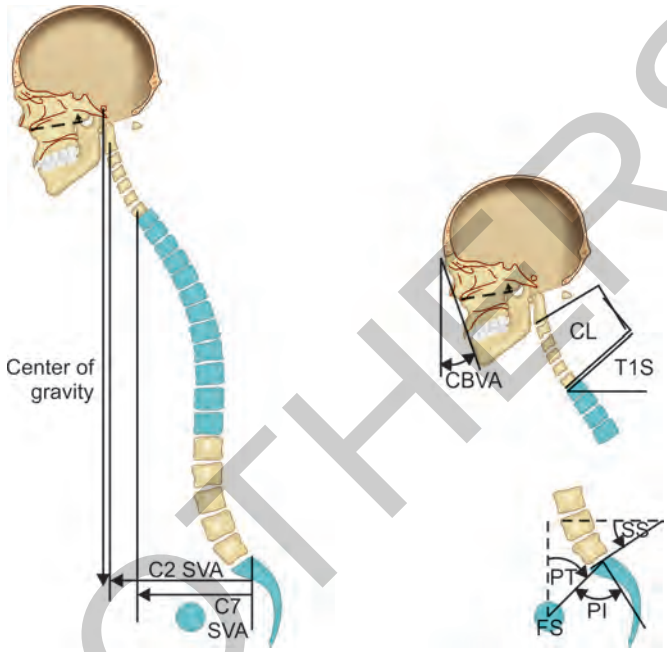

Fig. 3.7: The spine functions as a global unit so that cervical alignment parameters influence and are influenced by parameters in the lower regions. (CBVA: Chin-brow vertical axis; CL: Cervical lordosis; T1S: T1 slope; COG: Center of gravity; FS: Femoral shaft; PI: Pelvic incidence; PT: Pelvic tilt; SVA: Sagittal vertical axis).

controversy in the literature as to the exact role of how derangements in cervical alignment, as measured by cervical parameters, amount to disability. A full discussion of these issues is presented in Chapter 21.

CONCLUSION

This introductory chapter emphasizes the importance of understanding spondylotic myelopathy as a pathological process intimately dependent on cervical alignment. The reported normative data on cervical alignment and correlations between key parameters related to standing posture offer critical reference values as well as a foundation for the analysis and treatment of spinal malalignment conditions. Visualizing myelopathy from a "lens" of alignment considerations affords a richer awareness as to why there are large differences in outcomes among various treatments, and promotes acuity in critical evaluation of proposed surgical interventions developed for the future.

REFERENCES

1. Hippocrates. De Prisca Medicina.In: Littre PE (Ed.). Oeuvres Completes d'Hippocrate, Vol. 9. Amsterdam: AM Hakkert; 1982.
2. Keevil G. The Roentgen rays. Br Med J. 1896;1:433-4.
3. Tardieu C, Bonneau N, Hecquet JJ, et al. How is sagittal balance acquired during bipedal gait acquisition? Comparison of neonatal and adult pelves in three dimensions. Evolutionary implications. J Hum Evol. 2013;2013:209-22.
4. Schmitt D. Insights into the evolution of human bipedalism from experimental studies of humans and other primates. J Exp Biol. 2003;206:1437-48.
5. Dubousset J. Three-dimensional analysis of the scoliotic deformity. In: Weinstein SL (Ed.). The Pediatric Spine. New York: Raven Press; 1994, pp. 479-96.
6. Tang JA, Scheer JK, Smith JS, et al. The impact of standing regional cervical sagittal alignment on outcomes in posterior cervical fusion surgery. Neurosurgery. 2012;71:662-9; discussion 669.
7. Garson J. The Frankfort Craniometric Agreement, with Critical Remarks Thereon. J Anthropol Inst Gt Britain 1885.

JAYPEE BROTHERS

8. Suk K, Kim K, Lee S, et al. Significance of chin-brow vertical angle in correction of kyphotic deformity of ankylosing spondylitis patients. Spine (Phila Pa 1976). 2003;28:2001-5.
9. Lafage R, Challier V, Ferrero E, et al. Validation of correlation between CBVA, SLS and McGregor's Slope. Scoliosis Res. Soc. (SRS); Sept. 10-13, Anchorage, Alaska: 2014.
10. McGregor M. The significance of certain measurements of the skull in the diagnosis of basilar impression. Br J Radiol 1948;21(244):171-81.
11. Pigge RR, Scheerder FJ, Smit TH, et al. Effectiveness of preoperative planning in the restoration of balance and view in ankylosing spondylitis. Neurosurg Focus. 2008;24:E7.
12. Kim K-T, Suk K-S, Cho Y-J, et al. Clinical outcome results of pedicle subtraction osteotomy in ankylosing spondylitis with kyphotic deformity. Spine (Phila Pa 1976). 2002;27:612-8.
13. Harrison DE, Harrison DD, Cailliet R, et al. Cobb method or Harrison posterior tangent method: which to choose for lateral cervical radiographic analysis. Spine (Phila Pa 1976). 2000;25:2072-8.
14. Ames CP, Blondel B, Scheer JK, et al. Cervical radiographical alignment: comprehensive assessment techniques and potential importance in cervical myelopathy. Spine (Phila Pa 1976). 2013;38:S149-60.
15. Faline A, Szadkowski S, Berthonnaud E, et al. Morphological study of the lower cervical curvature: results of 230 asymptomatic subjects. EuroSpine, Brussels, Belgium: 2007.
16. Hardacker JW, Shuford RF, Capicotto PN, et al. Radiographic standing cervical segmental alignment in adult volunteers without neck symptoms. Spine (Phila Pa 1976). 1997;22:1472-80; discussion 1480.
17. Lee S, Kim K, Seo E, et al. The influence of thoracic inlet alignment on the craniocervical sagittal balance in asymptomatic adults. J Spinal Disord Tech. 2012;25:E41-7.
18. Knott PT, Mardjetko SM, Techy F. The use of the T1 sagittal angle in predicting overall sagittal balance of the spine. Spine J. 2010;10:994-8.
19. Marnay T. Equilibre du rachis et du bassin. Cah D'enseignement La SOFCOT Elsevier, Paris 1988.
20. Protopsaltis TS, Terran J, Bronsard N, et al. T1 slope minus cervical lordosis (TS-CL), the cervical answer to PI-LL, defines cervical sagittal deformity in patients undergoing thoracolumbar osteotomy. Cerv Spine Res Soc Annu Meet. December 5-7, 2013.
21. Gore DR, Sepic SB, Gardner GM. Roentgenographic findings of the cervical spine in asymptomatic people. Spine (Phila Pa 1976). n.d.;11:521-4.
22. Jackson RP, McManus AC. Radiographic analysis of sagittal plane alignment and balance in standing volunteers and patients with low back pain matched for age, sex, and size. A prospective controlled clinical study. Spine (Phila Pa 1976). 1994;19:1611-8.
23. Beier G, Schuck M, Schuller E, et al. Determination of physical data of the head. I. Center of gravity and moments of inertia of human heads. Munich: University of Munich;1979.
24. Park MS, Moon S-H, Lee H-M et al. The effect of age on cervical sagittal alignment: normative data on 100 asymptomatic subjects. Spine (Phila Pa 1976). 2013;38:E458-63.
25. Lafage V, Ferrero E, Lafage R, et al. Chain of compensation related to PI-LL mismatch: a complete standing axis investigation including lower extremities. Scoliosis Res Soc (SRS); Sept. 10-13, Anchorage, Alaska: 2014.
26. Lafage VC, Ferrero E, Lafage R, et al. Maintaining chin brow vertical angle (CBVA) and horizontal gaze in lumbar fatback deformity: full body analysis of the chain of compensation from the cervical spine to the feet 2014.
27. Smith JS, Shaffrey CI, Lafage V, et al. Spontaneous improvement of cervical alignment after correction of global sagittal balance following pedicle subtraction osteotomy. J Neurosurg Spine. 2012;17:300-7.
28. El Fegoun AB, Schwab FJ, Gamez L, et al. Center of gravity and radiographic posture analysis: a preliminary review of adult volunteers and adult patients affected by scoliosis. Spine (Phila Pa 1976). 2005;30:1535-40.
29. Gangnet N, Pomero V, Dumas R, et al. Variability of the spine and pelvis location with respect to the gravity line: a three-dimensional stereoradiographic study using a force platform. Surg Radiol Anat. 2003;25:424-33.

JAYPEE BROTHERS

for detailed information on orthopedic books, visit our website **www.jaypeebrothers.com,** for detailed information on ortho

CERVICAL MYELOPATHY

Salient Features

- Covers anatomy of the skull base and cervical spine, biomechanics and alignment, diagnosis, outcomes, distinct etiologies, and both nonsurgical and surgical management of cervical myelopathy
- Includes a section on cervical myelopathy in the setting of spine tumors
- Conditions discussed include cervical amyotrophy, rheumatologic disorders, ossification of the posterior longitudinal ligament, os odontoideum, atlantoaxial dislocations, basilar invagination, and congenital abnormalities of the cervical spine
- Surgical procedures covered include laminectomy, laminoplasty, and total disk replacement
- Over 250 photographs and illustrations.



Peter G Passias MD There have been remarkable advancements in our understanding of the underlying mechanisms, diagnosis and treatment of disorders of the cervical spine in recent history. Even more remarkable is how much still remains not fully understood, which has driven Dr Passias to enrich his clinical experience and knowledge with extensive research related to the treatment of cervical spinal disorders during and after his formal training, and now as an attending surgeon. A native of New York City, after obtaining a background education in mechanical engineering and biomedical sciences, Dr Passias completed his formal medical education and postgraduate work at Tufts University and affiliated institutions in Boston, Massachusetts, USA. Following completion of his required training, he decided to enhance his knowledge of spine-related disorders by pursuing further years of training and research at the Harvard Combined Spinal Program at the Massachusetts General Hospital and the Brigham and Women's Hospital, Boston, Massachusetts, USA. His final formal training was performed at the Hospital for Special Surgery, Cornell University, New York, New York, USA. Since that time, he has pursued academic medicine as an attending physician at Hospital for Joint Diseases, New York University Langone Medical Center, New York, New York, USA. Dr Passias has published many scientific findings in the field of spine surgery, with a focus on the surgical treatment of cervical disorders. He has given over 30 talks at scientific conferences and professional meetings, co-authored 7 book chapters and has published more than 40 peer-reviewed journal papers and numerous conference posters and/or conference abstracts. His research experience to date has taught him that in order to make more significant advancements, more research into the fundamental principles of cervical alignment and kinematics needs to be conducted. Equally important is the evaluation of the impact that patient factors and clinical decisions have on clinical outcomes.

Available at all medical bookstores
or buy online at www.jaypeebrothers.com

JAYPEE BROTHERS
Medical Publishers (P) Ltd.
www.jaypeebrothers.com

Join us on facebook.com/JaypeeMedicalPublishers

Shelving Recommendations
ORTHOPEDICS AND SPINE

ISBN 978-93-5152-492-2