MICHAEL W CHAPMAN
MICHELLE A JAMES

Volume 5

CHAPMAN'S

PREHENSIVE

MICHAEL W CHAPMAN
MICHELLE A JAMES

Volume 4

CHAPM

COMPRE

MICHAEL W CHAPMAN
MICHELLE A JAMES

Volume 3

CHAPMAN'S

COMPREHENSIVE

MICHAEL W CHAPMAN
MICHELLE A JAMES

Volume 2

CHAPM

COMPRI

ORTHOPA

SUR(

Section 4: Hanc
Disorders and M

Section 5: Shou
Disorders

Section 6: Musc
and Amputatio

4

MICHAEL W CHAPMAN
MICHELLE A JAMES

Volume 1

CHAPMAN'S

COMPREHENSIVE

ORTHOPAEDIC

SURGERY

Section 1: Principles of Musculoskeletal Surgery and Medicine —*Jonathan G Eastman*

Section 2: Fractures, Dislocations, Malunions and Nonunions
—*Philip R Wolinsky, Mark A Lee, Jonathan G Eastman, Eric Giza*

Section 3: Infectious, Metabolic, Neurological and Other Disorders —*Robert J Stellner*

4 TH EDITION

UCDAVIS SCHOOL OF MEDICINE | Get Full Access with added features at emedicin

UCDAVIS SCHOOL OF MEDICINE | Get Full Access with added features at emedicine360.com

JAYPEE

Contents

Volume 1

SECTION 1 ♦ PRINCIPLES OF MUSCULOSKELETAL SURGERY AND MEDICINE

Section Editor: Jonathan G Eastman

1. **Physical Examination of the Musculoskeletal System** 3
   Michael W Chapman
2. **Imaging of the Musculoskeletal System** 46
   Wonsuk Kim, Jasjeet Bindra, Robert D Boutin
3. **Laboratory Workup of Musculoskeletal Diseases** 67
   Prasanth Surampudi
4. **Thromboembolic Disease and Pulmonary Embolism** 92
   Richard White, John P Meehan
5. **Professionalism in Orthopedic Surgery** 102
   Jeanne L DelSignore, Michelle A James
6. **Surgical Approaches to the Upper Extremity** 106
   Michael W Chapman
7. **Surgical Approaches: Acetabulum and Pelvis** 145
   Bradley Deafenbaugh, Jonathan G Eastman
8. **Surgical Approaches to the Lower Extremity** 158
   Michael W Chapman
9. **Preoperative Planning and Perioperative Management** 195
   David J Hak, Mark E Hake
10. **Anesthesia and Pain Management** 227
    Timothy Tautz
11. **Soft-Tissue Management** 243
    David E Sahar, Thomas R Stevenson, Thomas P Whetzel
12. **Basic Instrumentation** 270
    Michael W Chapman
13. **Bone Grafting** 282
    Michael W Chapman

SECTION 2 ♦ FRACTURES, DISLOCATIONS, MALUNIONS AND NONUNIONS

Section Editors: **Philip R Wolinsky, Mark A Lee, Jonathan G Eastman, Eric Giza**

14. Closed Treatment of Fractures and Dislocations 305
Michael W Chapman, Motasem R Refaat

15. Principles of Internal Fixation 374
Joel C Williams, Michael W Chapman

16. Principles of External Fixation 411
Justin F Lucas, Michael W Chapman

17. Open Fractures 431
Robert J Steffner

18. Multiple System Injuries 453
Roman Pfeifer, Bilai M Barkatali, Hans-Christoph Pape

19. Compartment Syndrome 463
David A Forsh, Philip R Wolinsky

20. Scapula Fractures 479
Lee M Reichel, Jeffrey A Gilbertson, Lisa K Schroder, Peter A Cole

21. Clavicle Fractures 508
Michael McKee, Jesse Wolfstadt

22. Proximal Humerus Fractures and Fracture-Dislocations 523
Gillian Soles, John Gorczyca

23. Humeral Shaft Fractures 538
Amy S Wasterlain, Kenneth A Egol

24. Distal Humerus Fractures 553
Jason A Lowe, Emily Keener

25. Elbow Fractures and Dislocations 566
David Ring, Neal Chen, Hesham Abdelfattah

26. Radial and Ulnar Shaft Fractures 587
Prism Schneider, Edward J Harvey

27. Distal Radius Fractures 611
Frank A Liporace, Richard S Yoon

28. Pelvic Ring Fractures and Dislocations 628
Milton Lee Routt

29. Acetabular Fractures 640
Steven A Olson, Nicholas Laucis, Michael Morwood

30. Hip Dislocations and Femoral Head Fractures 678
Robert F Ostrum

31. Hip Fractures in the Elderly **689**
Stephen L Kates, Richard D Southgate

32. Femoral Neck Fractures in Young Adults **707**
Cory Collinge, Hassan Mir

33. Proximal Femur: Atypical Fractures **719**
Nirmal Tejwani, Carlos Uquillas

34. Femoral Shaft Fractures **727**
William Min, Philip R Wolinsky

35. Distal Femur Fractures **764**
Brett D Crist, Mark A Lee

36. Patella Fractures **779**
Dean G Lorich, Stephen J Warner

37. Tibial Plateau Fractures **794**
Saam Morshed

38. Tibial and Fibula Shaft Fractures **822**
Christopher Glenn Finkemeier, Rafael Neiman, Zachary Mallon

39. Ankle Fractures and Syndesmosis Injuries **855**
Brad Yoo

40. Ankle Fractures: Arthroscopic Management **874**
Adam M Wegner, Jonathan G Eastman, Eric Giza

41. Tibial Pilon Fractures **882**
Sean E Nork, Samir Mehta

42. Talus Fractures and Dislocations **905**
Stephen K Benirschke, Patricia Ann Kramer

43. Calcaneus Fractures **918**
Samuel B Adams, Adam Schiff, Travis Dekker

44. Midfoot Fractures and Dislocations **944**
Aaron M O'Brien, James J Sferra, Mark J Berkowitz

45. Forefoot Fractures and Dislocations  **981**
Aaron M O'Brien, James J Sferra, Mark J Berkowitz

46. Nonunions and Malunions: Principles **1014**
Louis B Jones, Matthew L Graves

47. Upper Extremity Nonunions and Malunions **1069**
Neal Chen, David Ring

48. Pelvic Nonunions and Malunions  **1090**
Ross Leighton

49. Proximal Femoral Nonunions and Malunions 1108
Dave L Helfet, Lindsay Hickerson, Geoffrey Wilkin, Craig Klinger

50. Femoral Shaft and Patellar Nonunions and Malunions 1131
Rodrigo Pesantez

51. Tibial Nonunions and Malunions 1149
David L Rothberg, Thomas F Higgins

52. Ilizarov Techniques 1172
David Lowenberg, Michael Githens

SECTION 3 ♦ INFECTIOUS, METABOLIC, NEUROLOGICAL AND OTHER DISORDERS

Section Editor: Robert J Steffner

53. Infection and Antimicrobial Therapy 1217
Haroon Hussain, Mohammed Hussain

54. Osteomyelitis 1243
Michael Sirkin, John S Hwang

55. Septic Arthritis 1259
Ugochi Okoroafor, Scott Kaar, David D Greenberg

56. Metabolic Bone Disease 1273
Arun Aneja, Rex C Haydon, Hue H Luu

57. Hemophilic Arthropathy and Other Synovial Disorders 1290
James V Luck Jr, Doris V Quon, Carol K Kasper, Mauricio Silva, Robert J Steffner

58. Heterotopic Ossification and Charcot Arthropathy 1319
David Manning, Kevin Hardt, Hasham Alvi

59. Osteonecrosis 1334
Diren Arsoy, Derek F Amanatullah

60. Lower Extremity in Stroke and Brain Injury 1352
Mary Ann Keenan, Keith Baldwin

Volume 2

SECTION 4 ♦ HAND, WRIST AND FOREARM DISORDERS AND MICROSURGERY

Section Editor: Michelle A James

61. Microvascular Surgery 1379
Laith Al-Shihabi, Christopher O Bayne

62. Vascular Disorders in the Upper Extremity **1390**
Peter Apel, John Li, Beth Paterson Smith, Andrew Koman

63. Replantation **1419**
Christopher J Dy, Ryan P Calfee

64. Free Tissue Transfer **1439**
Bridget Harrison, Samantha Piper, Scott Oishi

65. Vascularized Bone Flaps **1452**
Arthur Turko, Jesse Jupiter

66. Fingertip and Nailbed Injuries **1470**
Nicholas Pulos, David Bozentka

67. Finger and Thumb Dislocations and Ligament Injuries **1490**
Donald H Lee, Sid Baucom

68. Metacarpal and Phalangeal Fractures **1530**
Goo Hyun Baek, Min Bom Kim, Young Ho Lee

69. Carpal Dislocations **1547**
Anthony Parrino, John Elfar

70. Carpal Fractures **1571**
Dawn LaPorte, Thomas Kim

71. Distal Radioulnar Joint Injuries **1589**
Robert R Slater Jr

72. Gunshot Wounds, Crush, Injection and Frostbite Injuries of the Hand **1609**
Nicole Strauss Schroeder, Nicolas H Lee, Ryan C Stehr, Patrick Hettinger

73. Hand Amputations **1625**
Terry R Light

74. Tendon Repair Principles **1638**
M Claire Manske

75. Flexor Tendon Injuries **1649**
Nicholas Crosby, F Thomas Kaplan

76. Extensor Tendon Injuries **1674**
Robert H Ablove, Michael J Sayegh

77. Stenosing Tenosynovitis **1689**
Curtis M Henn, Daniel A Osei

78. Elbow Tendinopathy **1706**
Jeffrey Stepan, Keith Corpus, Aaron Daluiski

79. Nerve Repair and Transfer Principles **1715**
Peter C Rhee, Peter M Murray

80. Compression Neuropathies of the Upper Extremity **1732**
Carl M Harper, Charles S Day

81. Neuromas **1775**
David Brogan, Sanjeev Kakar

82. Principles of Restoration of Muscle Balance after Paralysis **1788**
Michelle A James, Anne Hollister, Paul W Brand

83. Radial Nerve Palsy **1798**
Kensuke Ochi, Yukio Horiuchi, Kazuki Sato

84. Median Nerve Palsy **1813**
Joseph Catapano, Gregory H Borschel

85. Ulnar Nerve Palsy **1824**
Michelle A James, Anne Hollister, Paul W Brand

86. Brachial Plexus Injuries **1835**
Pat Roman, Ryan Endress, Christopher O Bayne

87. Brachial Plexus Birth Injury **1854**
Andrea Bauer, Kathryn Peck

88. Thoracic Outlet Disorders **1870**
Misty D Humphries, Julie A Freischlag

89. Dupuytren's Contracture **1891**
John D Lubahn, Kirk G Cleland, Daniel Torres

90. Burns of the Hand **1901**
David Greenhalgh, Peter Kwan

91. Volkmann's Contracture **1918**
Deidre L Bielicka

92. Upper Extremity Dysfunction Following Stroke and Brain Injury **1929**
Mary Ann Keenan

93. Upper Extremity in Tetraplegia **1953**
Deidre L Bielicka, Lauren E Kwan, Michelle A James

94. Congenital Upper Limb Anomalies: Overview and Malformations **1970**
Ee Ming Chew, Michelle A James

95. Congenital Upper Limb Anomalies: Deformities and Dysplasias **2019**
Ee Ming Chew, Michelle A James

96. Arthroplasty in the Hand **2044**
Benjamin L Gray, John R Lien, Peter J Stern

97. Basilar Thumb Arthritis **2060**
Ryan J Kozlowski, Jennifer Moriatis Wolf

98. Arthrodesis of the Hand and Wrist **2071**
Christian Skjong, Nathan Morrell, Edward Akelman

99. Hand Infections **2084**
Courtney Quinn, Rick Tosti

100. Tumors of the Hand, Wrist and Forearm **2105**
Mark E Puhaindran, Soumen Das De

101. Arthroscopy of the Wrist **2123**
Michael Q Potter, Jeffrey Yao

SECTION 5 ♦ SHOULDER AND ELBOW DISORDERS

***Section Editor*: James Van den Bogaerde**

102. Shoulder Anatomy and Biomechanics **2149**
Tyler J Nathe

103. Glenohumeral Arthroplasty **2163**
Jia-Wei Kevin Ko, Surena Namdari, Gerald R Williams

104. Nonrepairable Rotator Cuff Disease **2186**
Andrew Green, Daniel Bronsnick, E Scott Paxton

105. Shoulder Arthroplasty for Proximal Humerus Fractures **2212**
Robert Tashjian

106. Failed Shoulder Arthroplasty **2226**
Aaron Chamberlain, Ken Yamaguchi, Jason Hsu

107. Shoulder Stiffness **2240**
Andre D Ivy, Guido Marra

108. Scapular Disorders **2252**
W Ben Kibler, Brent J Morris, Aaron Sciascia

109. Elbow Anatomy and Biomechanics **2268**
Robert M Titelman, Bernard F Morrey

110. Elbow Arthroplasty and Arthrodesis **2284**
Graham King, Laura Kember

111. Elbow Arthroplasty for Fractures **2326**
Jeffrey S Hughes, Geoff C Smith, Travis M Falconer

112. Failed Elbow Arthroplasty **2348**
Thomas W Wright, Jeffrey C King

113. Elbow Stiffness 2368
Brent V McCarty, Michael J O'Brien, Felix H Savoie III

SECTION 6 ♦ MUSCULOSKELETAL ONCOLOGY AND AMPUTATIONS

***Section Editor*: Robert J Steffner**

114. Limb Salvage Principles 2387
Steven Gitelis, Alan T Blank, Matthew W Colman, Douglas J McDonald, Cara A Cipriano, Yale Fillingham

115. Shoulder Tumors 2392
Martin Malawer, Steven Gitelis, Alan T Blank, Yale Fillingham

116. Hip and Pelvic Tumors 2414
Matthew W Colman, Steven Gitelis

117. Knee Tumors 2438
Cara A Cipriano, Douglas J McDonald, Alan T Blank, Yale Fillingham, Steven Gitelis, Matthew W Colman

118. Imaging Bone Tumors 2456
Robert D Boutin, Jasjeet Bindra

119. Imaging Soft Tissue Tumors 2472
Robert D Boutin, Jasjeet Bindra, Robert J Canter

120. Benign Bone Tumors 2491
Lukas M Nystrom, Tomas K Kuprys, Dariusz Borys, Albert J Song

121. Malignant Bone Tumors 2537
Andre Spiguel, Adam Lindsay, Chung Ming Chan

122. Benign Soft-Tissue Tumors 2562
Robert J Steffner, Terrance D Peabody

123. Malignant Soft Tissue Tumors 2604
Raffi S Avedian

124. Metastatic Tumors 2618
Rosanna Wustrack

125. Amputations of the Upper Extremity 2639
L Daniel Wurtz

126. Amputations of the Lower Extremity 2647
Nicholas M Bernthal, Erik M Dworsky, Jeffery J Eckardt

Volume 3

SECTION 7 ♦ SPORTS INJURIES AND ARTHROSCOPY

Section Editors: Richard A Marder, Eric Giza

127. The Role of the Physician in Sports Medicine 2671
Eric Heiden

128. Stress Fractures 2673
Mark E Batt, Jeffrey L Tanji, Richard A Marder

129. Adolescent Sports Injuries 2679
Brian Haus, Holly Leshikar

130. Shoulder Arthroscopy: Principles 2716
Thomas W Powers, Richard A Marder

131. Throwing Injuries of the Shoulder 2729
Diego C Villacis, Michael A Stone, David Lehoang, Seth Gamradt

132. Acromioclavicular and Sternoclavicular Joint Injuries 2751
Tyler J Nathe, Thomas W Powers

133. Shoulder Instabilities 2772
C Benjamin Ma, Alan L Zhang, Richard J Han

134. Rotator Cuff Disorders 2796
Robert U Hartzler, Stephen S Burkhart

135. Nonrotator Cuff Tendon Disorders of the Shoulder 2843
Richard A Marder

136 Elbow Tendon Disorders 2856
James Van den Bogaerde, John Ryan Taylor

137. Elbow Arthroscopy 2875
Laura A Timmerman

138. Elbow Instabilities 2890
Luke S Oh

139. Hip Arthroscopy 2911
Carlos Guanche, Chad Fortun

140. Hip Tendon Injuries 2945
James T Beckmann, Marc R Safran

141. Knee Anatomy and Biomechanics 2963
Robert J Johnson, Bruce D Beynnon

142. Arthroscopy of the Knee: Principles 2986
David B Coward

143. Osteoarthritis and Other Arthropathies 3004
Benjamin Packard, Matthew P Abdel, Mark P Figgie

144. Arthroscopic Meniscectomy and Repair 3017
Joshua Christensen, Matthew Prince, Bert Mandelbaum

145. Meniscal Transplantation 3029
Thomas R Carter, David Barba

146. Chondral Injuries and Biologics 3043
Cassandra A Lee

147. Knee Extensor Mechanism Injuries 3059
Kirk Lewis

148. Anterior Cruciate Ligament Injuries 3074
Bernard R Bach Jr, Jonathan C Riboh

149. Posterior Cruciate Ligament Injuries 3101
Alexander E Weber, Amit Nathani, Asheesh Bedi, Jon K Sekiya

150. Knee Dislocation and Multiple Ligament Injuries of the Knee 3114
Gregory C Fanelli

151. Patellofemoral Disorders 3130
Jennifer J Beck, Lyle J Micheli

152. Posterolateral Instability of the Knee 3142
Samuel G Moulton, Robert F LaPrade

153. Knee Surgery Complications 3157
John R Raskind, Travis G Maak

154. Lateral Ankle and Subtalar Instability 3164
Jorge I Acevedo, Alexander A Fokin, Peter Mangone

155. Ankle Syndesmosis Injuries 3188
Justin Hopkins, Christopher Kreulen, Eric Giza

156. Medial Ligament Instability of the Ankle 3200
George Lian

157. Lisfranc Joint Injuries 3222
Kenneth J Hunt, Eric Q Pang, Jeffrey E Krygier

158. Forefoot Ligament Injuries and Turf Toe 3242
Douglas E Lucas, Robert B Anderson, Kenneth J Hunt, Eric Q Pang, Jeffrey E Krygier

159. Achilles Tendon Rupture: Acute 3258
David R Pedowitz, Boleslaw Czachor

160. Achilles Tendon Injury: Chronic **3266**
Christopher E Gross, Selene G Parekh

161. Peroneal Tendon Injury: Acute **3276**
Eric P Bluman, Kaitlin Neary, Christopher P Miller, Eric Giza

162. Peroneal Tendon Injury: Chronic **3287**
Christopher P Miller, Eric P Bluman, Eric Giza

163. Sports Foot and Ankle Tendon Injuries: Other Tendons **3293**
Aoife MacMahon, Steve Greenfield, Scott J Ellis

164. Jones Fracture in the Foot **3326**
W Bret Smith

165. Ankle Arthroscopy: History, Basics and Soft Tissue Techniques **3336**
Arash A Dini, Richard D Ferkel

166. Ankle Arthroscopy: Soft Tissue and Bony Impingement **3352**
Arash A Dini, Deborah A Castaneda, Richard D Ferkel

167. Ankle Arthroscopy: Talus Osteochondral Disease **3363**
Christopher Kreulen, Martin Sullivan, Eric Giza

168. Subtalar Joint Arthroscopy **3383**
Rebecca A Cerrato, Ettore Vulcano

169. Hallux Metatarsophalangeal Joint Arthroscopy **3392**
Rebecca A Cerrato, Ettore Vulcano

170. Hindfoot Arthroscopy **3401**
Shana N Miskovsky

SECTION 8 ♦ FOOT AND ANKLE DISORDERS

***Section Editor*: Eric Giza**

171. Ankle Arthritis **3429**
Peter Stavrou, George A Konstantinidis

172. Ankle Arthritis: Joint Preservation Surgery **3441**
Doug Beaman, Paul Fortin

173. Ankle Arthrodesis **3460**
Peter Stavrou, George A Konstantinidis

174. Total Ankle Arthroplasty: Principles **3475**
Daniel Fuchs, Anand Vora

175. Total Ankle Arthroplasty: Outcomes and Complications **3489**
Dawson Muir

176. Subtalar Arthritis **3505**
Thomas C Dowd, Katherine Bedigrew

177. Hindfoot and Pantalar Arthrodesis **3521**
Glenn G Shi, Christopher E Gross, Selene G Parekh

178. Midfoot Arthritis **3533**
Veerabhadra "Babu" Reddy

179. Hallux Rigidus: Introduction and Nonoperative Care **3543**
Spenser Cassinelli, Thomas G Harris

180. Hallux Rigidus: Cheilectomy, Osteotomy and Arthroplasty **3550**
Tibor Warganich, Thomas G Harris

181. Hallux Rigidus: Arthrodesis **3569**
Andrew Battenberg , Thomas G Harris

182. Adult Acquired Flatfoot Deformity **3581**
Snow Daws, Aaron T Scott

183. Flexible Flatfoot Reconstruction **3598**
Aaron T Scott, Snow Daws

184. Triple Arthrodesis for Rigid Flatfoot Deformity **3619**
Aaron T Scott, Snow Daws

185. Hallux Valgus: Nonoperative Care **3629**
Thevendran Gowreeson, Foo Gen Lin

186. Hallux Valgus: Operative Treatment **3641**
Lyle Jackson, Christopher Kreulen, Eric Giza

187. Hammer Toes **3655**
Lowell Weil Jr, Michael F Bowen

188. Metatarsalgia and Plantar Plate Disorders **3663**
Lowell Weil Jr, Michael F Bowen

189. Inflammatory Conditions of the Ankle and Foot **3676**
Sonya Ahmed

190. Diabetic Foot: Principles of Management **3686**
William M Weiss, Midhat Patel, Harrison Scofield, Vinod K Panchbhavi

191. Diabetic Foot Infection **3702**
William M Weiss, Midhat Patel, Vinod K Panchbhavi

192. Charcot Neuroarthropathy **3717**
Vinod K Panchbhavi, William M Weiss

193. Dropfoot **3734**
Steven K Neufeld, Matthew S Baer

194. Tarsal Tunnel Syndrome 3751
Daniel Goldbloom, Kaihan Yao

195. Foot Nerve Entrapment and Morton's Neuroma 3761
Daniel Goldbloom, Stewart Morrison

196. Adult Cavus Foot Deformity in Neuromuscular Disorders 3779
Gregory A Lundeen, Brent Roster, Linda Dunaway

SECTION 9 ♦ HIP AND KNEE RECONSTRUCTION

Section Editor: Mauro Giordani

197. Design and Performance of Joint Replacements 3805
Peter S Walker, Mauro Giordani

198. Periacetabular Osteotomy 3862
Michael McGrath, Steven A Olson

199. Total Hip Arthroplasty 3877
Stephen M Petis, Thomas J Blumenfeld

200. Revision of Failed Hip Arthroplasty and Arthrodesis of the Hip 3919
Christopher M Melnic, P Maxwell Courtney, Michael T Talerico, Neil P Sheth, Wayne G Paprosky

201. Osteotomies about the Knee 3954
Augustine Saiz, Mauro Giordani

202. Total Knee Arthroplasty 3974
Gavin Pereira, John P Meehan, Mauro Giordani

203. Revision Total Knee Arthroplasty and Knee Arthrodesis 4002
Kelly G Vince

204. Periprosthetic Joint Infection 4058
Matthew W Tetreault, Michael D Hellman, Darren R Plummer, Craig J Della Valle

Volume 4

SECTION 10 ♦ SPINE DISORDERS

Section Editor: Munish C Gupta

205. Bone Grafts, Substitutes and Growth Factors in Spine Surgery 4085
Sohrab Virk, Safdar Khan

206. Spinal Orthoses **4096**
Ioannis Avramis

207. Radiologic Imaging of the Spine **4107**
Adam Greenspan, Javier Beltran, Eric Ledermann

208. Cervical Spine: Surgical Approaches **4128**
Joseph A Osorio, Darryl Lau, Christopher Ames

209. Thoracic and Lumbar Spine Approaches **4134**
Kamran Majid, Ravinder-Raj Bains

210. Spine Biomechanics: Finite Element Techniques **4145**
Mohammad S Asadollahi, Jie Zheng, M Fanarjian, Daniel C Cook
Boyle C Cheng, YH Yang, Vijay K Goel

211. Occiput and Cervical 1-2 Injuries and Instabilities **4161**
Rolando Roberto

212. Cervical 3-7 Fractures and Dislocations **4184**
Barrett I Woods, Gregory D Schroeder, Alexander R Vaccaro

213. Thoracolumbar Fractures: Evaluation and Initial Care **4204**
Christopher J Kleck, Christopher MJ Cain, Evalina L Burger, Vikas V Patel

214. Thoracolumbar Fractures: Operative Treatment **4223**
John R Dimar II, Leah Y Carreon

215. Sacral Fractures **4239**
Eric O Klineberg, Michael A Robbins, Daniel O'Connor, Jonathan G Eastman

216. Degenerative Disc Disease: Pathophysiology **4262**
Jeffrey C Lotz, Stefan Dudli, Aaron J Fields

217. Degenerative Disc Disease: Nonoperative Management **4275**
Matthew J Mermer, Jaspaul Gogia

218. Cervical Spine Degenerative Disease: Surgical Treatment **4283**
Han Jo Kim, Sravisht Lyer, K Daniel Riew

219. Lumbar Spine Degenerative Disease: Surgical Management **4301**
Robert Owen, William Hotchkiss, Jacob M Buchowski

220. Failed Surgery for Lumbar Degenerative Disease: Management **4319**
Srinivasu Kusuma, Jonathan Allen, Munish C Gupta

221. Pyogenic Infections of the Spine **4332**
Yashar Javidan, J Matthew Cage

222. Granulomatous Infections of the Spine **4356**
S Rajasekaran, Rishi Mugesh Kanna, Ajoy Prasad Shetty

223. Primary Tumors of the Spine **4381**
Ran Lador, Stefano Bandiera, Alessandro Gasbarrini, Riccardo Ghermandi, Stefano Boriani

224. Metastatic Tumors of the Spine 4407
Heidi Martin Hullinger, Rex AW Marco

225. Rheumatological Disorders of the Spine 4424
John D Attenello, Lance K Mitsunaga, Kyle A Mitsunaga

226. Ankylosing Spondylitis 4440
Yong Qiu, Bang-ping Qian

227. Scoliosis: Principles and Nonoperative Care 4478
Rolando Roberto

228. Congenital Scoliosis and Fused Ribs: Treatment with VEPTR 4487
Robert M Campbell

229. Idiopathic Scoliosis in Children 4501
Purnendu Gupta, Kim W Hammerberg

230. Congenital Spine Deformity 4522
Nicholas Pirnia, Paul Mead, Munish C Gupta

231. Pediatric Kyphosis Deformity 4542
Scott C Wagner, Ronald A Lehman, Jack K Mayfield, Lawrence G Lenke

232. Pediatric Spondylolisthesis 4551
Hubert Labelle, Jean-Marc Mac-Thiong, Stefan Parent

233. Spinal Deformity in Myelomeningocele 4570
Burt Yaszay, Salil V Upasani

234. Neuromuscular Spinal Deformity 4580
Kenneth Chin, Paul Sponseller

235. Adult Spinal Deformity 4593
Michael J O'Brien, Richard Hostin, Ioannis Avramis

236. Degenerative Scoliosis: Surgical Management 4607
Nicholas Miladore, Tyler Snoap, Joshua Ellwitz

237. Sagittal Plane Deformities of the Spine in Adults 4622
Daniel O'Connor, Michael A Robbins, Eric O Klineberg

238. Revision of Failed Spinal Deformity Surgery 4640
Munish C Gupta

SECTION 11 ♦ PEDIATRIC DISORDERS

***Section Editor*: Jon R Davids**

239. Growth and Development 4655
Jennette L Boakes

240. Genetics 4684
Nancy Hadley-Miller, Daniel R Possley

241. Musculoskeletal Examination of the Child **4698**
Deborah Eastwood

242. Gait and Assessment of Gait Disorders **4718**
Jon R Davids

243. Endocrine and Metabolic Disorders in Children **4730**
Robert Lark, Benjamin Alman

244. Syndromes and Dysplasias **4747**
Michael J Goldberg, Maryse Bouchard, Klane K White, Suzanne M Yandow

245. Fractures and Dislocations in Children **4777**
S Imraan Ahmed, James D Bomar, Eric W Edmonds

246. Musculoskeletal Infections in Children **4823**
Bettina M Gyr

247. Lower Extremity Disorders in Children **4838**
Christopher Iobst

248. Developmental Dysplasia of the Hip **4897**
Pablo Castañeda, Jon R Davids

249. Legg-Calvé-Perthes Disease **4927**
Benjamin Joseph, Vedant A Kulkarni

250. Slipped Capital Femoral Epiphysis **4944**
Holly Leshikar, Brian Haus

251. Hip Impingement in Children **4968**
Matthew J Boyle, Travis H Matheney

252. Knee Disorders in Children **4985**
Kevin Shea, John Polousky, Joseph L Yellin, Michelle Ho, Ted Ganley, Alex Styhl

253. Foot Disorders in Children **5011**
Nicholas A Beckmann, Thomas Dreher

254. Cerebral Palsy in Non-Ambulatory Children **5060**
Uri Givon, Daniel M Weigl

255. Cerebral Palsy in Ambulatory Children **5080**
Mauro César de Morais Filho, Francesco Camara Blumetti

256. Cerebral Palsy: Upper Extremity Management **5109**
Ann Van Heest

257. Myelodysplasia **5131**
Eva Pontén, Åsa Bartonek, Marie Eriksson

258. Poliomyelitis **5150**
David A Spiegel, Bibek Banskota, Hugh G Watts

259. Limb Deficiency in Children **5170**
David E Westberry, Jon R Davids, Ed Skewes, Linda Wack

SECTION 12 ♦ PHYSICAL MEDICINE AND REHABILITATION

Section Editor: Carol Vandenakker-Albanese

260. Physiatric History and Physical Examination 5209
Carol Vandenakker-Albanese, John A Dorsett

261. Electrodiagnosis: Nerve Conduction and Electromyography 5216
Douglas G Chang

262. Neurophysiologic Monitoring in Spine Surgery 5230
Gregory A Kinney, Robert N Holdefer, Vicente Martinez

263. Ultrasound for Musculoskeletal Conditions 5247
Melita N Moore, M Kenji Yamazaki, Jonathan T Finnoff

264. Impairment and Disability Rating 5287
Wendy Helkowski, Betty Y Liu, Brady Wahlberg

265. Biophysical Agents and Electrical Stimulation 5301
Aaron E Embry, Jennifer L Hunnicutt, Margaret McKinney, Chris M Gregory

266. Therapeutic Exercise 5313
Brandee Waite, Gretchen Casazza, Sean Sumner

267. Orthoses for the Upper Extremity 5333
Brian M Kelly, Edward S Claflin, Carole V Dodge

268. Orthoses for the Lower Extremity 5352
Edward S Claflin, Brian M Kelly

269. Prostheses for the Upper Extremity 5370
Alberto Esquenazi, Maria Flach, Daniela Garcia, Drew Lerman

270. Prostheses for the Lower Extremity 5388
Christopher D Reger, Phillip M Stevens, Christopher A Robinson, Mark E Huang

271. Wheelchairs, Seating Systems and Mobility Aids 5403
Wendy Pierce, Aaron Pierce, Anne Stratton

272. Injection Techniques for Joints and Soft Tissues 5425
Amy X Yin, Ryan Mattie, David J Kennedy, Michael Fredericson

273. Lumbar Spinal Injections 5448
Douglas G Chang, Vinko Zlomislic

274. Spasticity Management 5460
Andrew Skalsky, Sathya Vadivelu, Pritha Dalal

275. Integrative Medicine 5475
Peter Gerritz

276. Peripheral Neuropathy 5483
Anita SW Craig

277. Myopathic Disorders 5501
Craig M McDonald

278. Motor Neuron Disease 5536
Nanette C Joyce, Carol Vandenakker-Albanese

279. Concussion and Traumatic Brain Injury 5554
M Elizabeth Sandel

280. Spinal Cord Injury 5569
Sunil Sabharwal

281. Cerebral Palsy 5599
Loren Davidson, Joyce Oleszek, Aaron Powell

282. Spina Bifida: Rehabilitative Care 5616
Maya C Evans, Katherine Bentley, Adam Bartlett

283. Rehabilitation of Lower Extremity Amputation 5632
Mark E Huang, Rachna H Soriano, Mary E Caldwell

284. Burns: Rehabilitative Care 5647
Karen Kowalske

285. Arthritis: Physiatric Management 5654
Ryan Mattie, Amy X Yin, David J Kennedy

Volume 5

Contributors Titles and Institutions

Index 5677

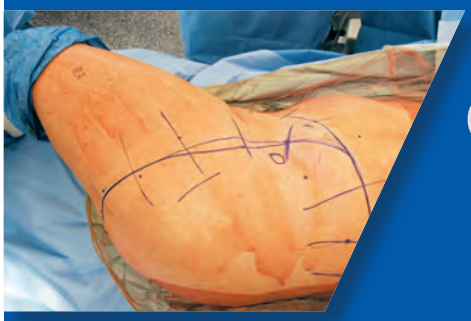

Chapter 126

Amputations of the Lower Extremity

Nicholas M Bernthal, Erik M Dworsky, Jeffery J Eckardt

- **Introduction**
- **Principles of Management**
  - Overall Philosophy
  - Flap Design
  - Bone Cuts
  - Nerve Cuts
  - Tourniquets
  - Drains
  - Sutures and Staples
  - Special Tools
- **Indications**
  - Peripheral Vascular Disease
  - Trauma
  - Malignancy
- **Preoperative Planning and Preparation**
  - Amputation Level Selection
  - Antibiotics

SURGICAL TECHNIQUES

Toe Disarticulation or Amputation
Ray Resection
Transmetatarsal Amputation
Lisfranc and Chopart Amputations
Boyd Amputation
Syme's Amputation
Below Knee Amputation
Knee Disarticulation
Above Knee Amputation
Hip Disarticulation
Hemipelvectomy (Hindquarter Amputation)

- *Level Selection*
- *Tourniquets*
- *Closure*
- *Short Stumps*

- **Postoperative Care and Rehabilitation**
  - Pain Management
  - Early Care
    - *Wound Healing and Stump Conditioning*
    - *Prosthesis Conditioning*
    - *Definitive Prosthesis*
- **Pitfalls and Complications**
  - Infection
  - Stump Breakdown
  - Neuromas and Phantom Limb Pain

Authors' Perspective

INTRODUCTION

Evidence of extremity amputation dates back to Neolithic times, with archaeologists uncovering transected skeletons alongside Stone Age tools. Hippocrates first described the surgical procedure and his principle of cutting out necrotic tissue remains true today. In the 16th century, German surgeon Fabricius Hildanus reported using a "hot knife" to remove limbs and control bleeding simultaneously. Soon after, Ambroise Paré introduced the vessel ligature (16th century) and Etienne Morel reported on using a tourniquet (17th century)[1] to control bleeding. The centuries to follow saw the introduction of aseptic technique, antibiotics to prevent infection, and general anesthesia to decrease the often fatal stress of surgery. With time, losing an extremity to preserve life became a viable option as mortality following amputation surgery decreased. More recently, advances in prosthetic design and materials science have produced monumental change in prostheses. Now amputees can reasonably expect to regain sufficient function to return to work and even participate in sports. Amputation surgery is no longer simply a removal of part of a limb; it is a reconstructive surgery aimed at a highly functional outcome.

Despite improvements in medical care, limb salvage surgical techniques, and trauma management, amputation remains a commonly performed procedure. In the United States alone, there are approximately 40,000 lower extremity amputations per year.[2] This is attributed to improved medical and surgical care, which has allowed vascular, trauma, and oncology patients to live longer. Consequently there are now more than two million amputees living in the United States. Projections suggest that this number will reach 3.6 million by 2050.[2]

The health system costs related to amputation are enormous. The projected lifetime healthcare costs of a lower extremity amputee are >$500,000.[3] This expense comprises hospitalizations, physical therapy, prosthetics, and additional surgeries such as higher-level amputations or revision amputations. Within the population of Medicare

JAYPEE BROTHERS

patients, most of whom represent amputees for vascular disease, 25% of amputees will have another amputation within 1 year and greater than one-third of these patients will die within 1 year of the index operation.[4] Forty to 60% of lower extremity amputations are due to diabetes mellitus (DM), with 85% of amputations in this population being preceded by foot ulceration.[5] Following new-onset diabetic foot ulceration, the 5-year mortality rate is predicted at 43–55%.[6] Sadly, diabetics are more likely than other amputees to experience progression to a higher-level amputation for any lower extremity amputation.[4] A study by Apelqvist et al. determined that 49–85% of lower extremity amputations from DM can be prevented by a regimen of comprehensive foot care.[5] The foundation of this regimen is regular care visits, patient education, and the provision of optimal footwear. Similarly, all amputees benefit from a comprehensive care team. This team often includes the primary care physician, surgeon, physiatrist, physical therapist, prosthetist, and social worker.[21] In the authors' experience, coordinating the patient visit such that all members of the team can be present is a cohesive and efficient means of care.[22-24]

Amputation can be stigmatized as a failure. Often an amputation follows an unsuccessful attempt at medical management, revascularization, or limb salvage. Nonetheless, emphasis should be placed on the idea that amputation can be a means to assuage suffering and regain independence. Prior to surgery, many future amputees suffer with a limited or nonfunctional limb that can be the source of great discomfort. Following amputation and the fitting of a prosthesis, many amputees enjoy improved mobility, once again becoming contributing members of society.

PRINCIPLES OF MANAGEMENT

Overall Philosophy

Amputation surgery can be divided into two parts: (1) the resection and (2) the reconstruction. Surgeons are often quite attentive to the resection, analyzing preoperative imaging and intraoperative findings to assess what tissue must be resected. Frequently, however, surgeons spend little time on the reconstruction, which can lead to wound complications, poor prosthesis fitting, and functional impairment. Remember that amputations are intended to be definitive procedures that allow patients to maximize recovery and function of the remaining limb.



Fig. 126-1: Beveling of the bone ends.

Flap Design

Bone length is often expendable, but a viable musculocutaneous flap for coverage of the end of the stump is essential. Design a larger flap than you believe is needed, reserving the option to remove the excess. More often than not, you will use every part of the oversized flap and be glad you did. Strive to have no tension on the wound at the time of closure.

Bone Cuts

Nearly all bone cuts should be beveled to allow for pain-free flap coverage. Beveling can be accomplished with a rasp or an oscillating saw used in a backhoe manner **(Fig. 126-1)**.

Nearly all bone cuts should be beveled to allow for pain-free flap coverage. Beveling can be accomplished with a rasp or an oscillating saw used in a backhoe manner **(Fig. 126-1)**. Keep in mind, however, that in very short stumps the working length is determined by the shorter end of the bevel, so avoid making the bevel too long.

Nerve Cuts

Dissect the nerve from distal to proximal, pull gentle traction to place the nerve under tension, and then transect the nerve with a sharp fresh scalpel blade. The nerve then retracts into the soft tissues in an area where the risk of impingement from the prosthesis is minimized. Ligate larger nerves, in particular the sciatic nerve, because their rich blood supply can result in substantial hemorrhage. Some surgeons advocate injecting the epineurium of larger nerves with local anesthetic before they are cut. There is little high-level evidence on the benefit of this technique, but anecdotal evidence suggests that patients have less postoperative pain. Alternatively, some surgeons place indwelling epineural catheters into large nerves prior to closure. This is the authors' preferred technique

JAYPEE BROTHERS

for proximal amputations such as hemipelvectomy and hip disarticulation, but not more distal ones such as an above knee amputation (AKA) and lower.

Tourniquets

Many surgeons advocate the use of tourniquets in amputation surgery. We feel, however, that tourniquets cannot be used for the most proximal amputations so why are they necessary for more distal ones? In our experience tourniquets are largely unnecessary and can even be counterproductive. You must be able to identify and control the major vessels and a tourniquet can hinder this effort. Moreover, a tourniquet can generate artificial tension in the limb that changes soft tissue dynamics and distorts the operative field, thereby artificially misaligning flaps. Lastly, releasing the tourniquet at the end of a procedure can result in a dramatic influx of blood into the stump, which in turn can prompt excessive use of electrocautery and devitalization of the flap. We do not use tourniquets in any amputation procedures, but recognize that many surgeons do. If a tourniquet is used, it is imperative that the tourniquet be sterile so that it can be deflated and removed prior to closure. Removing the tourniquet is key because even a deflated tourniquet can alter the soft tissue tension during closure.

Drains

Drains are useful to avoid the formation of excessively large hematomas or seromas. These fluid collections can hinder wound healing and provide an excellent medium for bacterial growth. While meticulous operative technique can minimize postoperative hematoma, postoperative seroma is common and can be a devastating complication. Seroma cavities often separate layers of tissue and create "boggy" stumps. We place drains in all amputations proximal to the forefoot and leave them in until drainage is <30 cc per day.

Sutures and Staples

Meticulous surgical technique with the skin closure is essential. Limit the number of deep dermal stitches to prevent necrosis of lengthy skin flaps. If flaps are of a sufficient length, no tension is necessary in the deep dermal layer and we use only several alignment sutures. Close the skin with interrupted nylon or staples as per your preference.

Special Tools

Amputations require very few special tools. All of the following procedures can be conducted with a scalpel, amputation knife, electrocautery, saw, rasp, drill, ligatures, and suture.

Proper use of the electrocautery is essential for transecting major muscles. Slow and even strokes with the tip of the device ensure optimal hemostasis. Moreover, the muscle remnants should have distinct ends for potential myodesis at closure.

INDICATIONS

Peripheral Vascular Disease

Vascular insufficiency is the most common indication for lower extremity amputation. Recalcitrant infection, unsuccessful revascularization, and chronic, nonhealing ulcers are indications for amputation. These amputations can occasionally be performed in conjunction with a higher-level revascularization procedure to avoid lower level amputations. This technique should be used with caution, however, as diabetes, peripheral neuropathy, and Charcot arthropathy often exist concurrently. Wound healing, pain relief, and postoperative function can be problematic.

Trauma

Following severe lower extremity trauma the treating surgeon must periodically make the difficult decision between limb salvage and amputation. This can be an emotionally charged decision and various scoring systems, such as the Mangled Extremity Severity Score (MESS), have been developed in an attempt to make the decision more objective. Moreover, multi-institutional trials such as the Lower Extremity Assessment Project (LEAP) have followed large groups of patients in an effort to optimize their care.[7] An interesting contribution of these studies has been the debunking of some long-held dogma about amputation. A prime example was the assertion that the loss of plantar foot sensation mandated subsequent amputation. To the contrary, the LEAP study concluded that plantar sensation at presentation was not indicative of final sensory status or functional scores after limb salvage.[7] These studies have also highlighted the potential difficulties associated with limb salvage, including prolonged medical care, associated costs, and possibility of an ill-functioning and painful limb with ensuing patient dissatisfaction. An unfortunate, but

JAYPEE BROTHERS

apropos adage is that failed limb salvage can leave patients "demoralized, divorced, destitute, and drug addicted."[8]

Malignancy

Amputation was the mainstay of oncologic extremity surgery until the latter part of the twentieth century. With the landmark studies of the late 1970s and early 1980s, surgical oncologists came to accept limb salvage surgery as an equivalent oncologic procedure when negative margins could be achieved.[9,10] Today, >95% of extremity sarcomas are treated with limb salvage, but amputation remains an important tool in the surgical oncologists' armamentarium. In general, amputation is now performed when negative margins cannot be achieved secondary to involvement of critical nerves or vessels or because resection would leave a nonfunctional extremity.

PREOPERATIVE PLANNING AND PREPARATION

Amputation Level Selection

The level of amputation is a critical decision. Gait analysis has shown higher walking speeds, less oxygen consumption, and better function with below knee amputation (BKA) than with through-knee or AKAs.[11,12] That being said, the adage that "longer is always better" is not always the case. Recent studies have shown limited functional benefit of mid- and hind-foot amputations over below-knee amputations.[13]

The level of amputation is a decision the surgeon must make understanding this functional hierarchy and then base the specific decision on: (1) identifying the level of injury, insult, or tumor and (2) identifying what viable structures are available for reconstruction **(Fig. 126-2).**

Within a given "level," where to cut is based on the often competing goals of preserving length and ensuring a tension-free soft tissue closure. Finally, it is essential to coordinate with prosthetists, orthotists, and physiatrists to understand functional goals and the relevance of stump length. For example, BKA stumps greater than 15 cm often impede prosthetic wear and cause dysfunction.

The ideal stump should be durable enough for end-bearing and remain pain free even with all day prosthesis wear. The stump should have appropriate length and shape for prosthesis fitting. Partial foot amputations benefit from maintaining full limb length and using tough plantar flaps. Below, above, or through-knee amputations benefit from

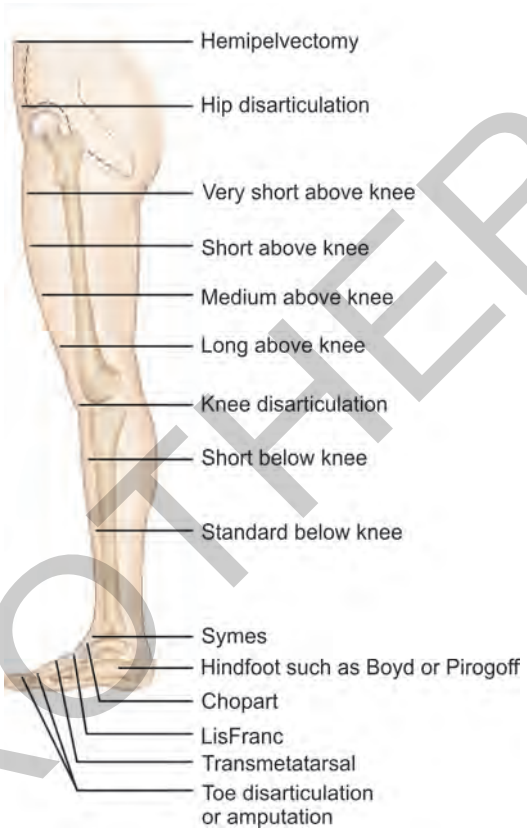

Fig. 126-2: Levels of lower extremity amputation.

myodeses that centralize the remaining bone in the muscle envelope. Disarticulations are generally thought to be better at weight bearing than transosseous amputations. Lastly, in children every attempt should be made to maintain the physes so as to maintain the growth of the extremity.

In patients with compromised blood supply to the limb, tools are available to assess viability of tissue. Transcutaneous oxygen partial pressure measurement ($TcPO_2$) is one such measure. The skin is heated to 44°C and a probe is placed to measure oxygenation. Studies differ in the specifics but a measurement above 20 mm Hg portends a significantly greater success rate than amputations undertaken at a level with a lower $TcPO_2$.[14,15]

Even with the above information, the decision on amputation level can be more nuanced. Further factors include age, comorbidities, ability to manage active medical issues, preoperative mobility, nutrition, and infection status to name a few. Every patient will be unique and surgical decisions must be individualized to achieve the best outcome.

JAYPEE BROTHERS

Antibiotics

All patients undergoing amputation surgery are treated with antibiotic prophylaxis consistent with Surgical Care Improvement Project (SCIP) guidelines.[16] In most patients, a first-generation cephalosporin administered 1 hour prior to incision and discontinued within 24 hours is appropriate.

SURGICAL TECHNIQUES

Toe Disarticulation or Amputation

Guiding principles: Preserve as much toe length as possible to prevent toe migration. This is particularly important with regard to the first digit as the first metatarsal bears approximately 50% of the weight during toe-off.

Procedure:

- Draw out a fish-mouth incision on the toe with approximately equal length dorsal and plantar full-thickness flaps.
- Proceed with the amputation from dorsal to plantar.
- Incise the skin and subcutaneous tissue.
- Cut the extensor tendon at the level of the skin incision and allow it to retract.
- Disarticulate the joint or transect the bone as required by the level of amputation.
- Bevel the edges of any bone cuts.
- Identify and transect the neurovascular bundles located medial and lateral to each digit. Gently pull the nerves distally and cut them back sharply to facilitate their retraction.
- Cut the flexor tendons at the level of the skin incision and let them retract.
- Consider tenodesis to cover the bony stump if sufficient tissue is present.
- Close the wound in a layered fashion with interrupted absorbable sutures in the subcutaneous fat and interrupted nonabsorbable sutures in the skin.

TIPS AND TRICKS

- ☑ Error toward a slightly larger plantar flap as this skin tends to be thicker and better for covering the distal stump.
- ☑ We prefer flaps in the following order of preference: plantar, side-to-side, then dorsal.
- ☑ Dog-ears on the flaps do not need to be removed as they will retract and remodel.

Ray Resection

Guiding principles: The most common indications for ray resection are a plantar ulcer resistant to conservative management and/or metatarsal osteomyelitis.[17]

Malawer described the foot as a tripod with the three legs being the first metatarsal head, the fifth metatarsal head, and the calcaneus.[4] Given their relative structural importance, removal of the first or fifth metatarsal is associated with more complications. First ray resection in the insensate foot can lead to a transfer lesion under the second metatarsal. In this scenario, a transmetatarsal amputation may have a better outcome. Moreover, the lesser metatarsals are not as well-suited to weight-bearing and first ray resection can result in transverse metatarsalgia.

If the pathology allows, cutting through the base of the metatarsal and leaving the tarsometatarsal (TMT) joint unperturbed often produces a stable, functional foot. However, if there is any question as to the viability of the flap, the oncologic margins of resection, or the quality of the bone, a ray disarticulation has a long track record of good function as well.

We also have some experience with nonconventional ray resections. When presented with patients who do not want to consider hindfoot amputation or BKA for sarcomas in the forefoot, we have performed several multiple ray resections to remove neighboring contaminated tarsal bones. While our experience is anecdotal, the functional outcomes have been good.

Procedure:

- Design a racket-type incision circumferentially around the afflicted toe with the handle along the dorsum of the involved metatarsal.
- The handle of the incision should extend beyond the location of the ulcer or lesion.
- Proceed with the amputation from dorsal to plantar.
- Expose the intermetatarsal space without damaging the periosteum.
- Identify and transect the digital nerves and ligate the digital arteries and veins. Take care to differentiate the neurovascular bundle of the affected metatarsal from that of the adjacent ray.
- Transect the metatarsal at the metadiaphyseal junction if circumstances allow.
- Now carry the dissection from proximal to distal using the distal bone as a handle to lever and tension the tissues.
- Dissect down to the plantar surface through the plantar fascia.
- Surrounding soft tissues may be sacrificed as necessary, including the intrinsics and lumbrical muscles.
- Following resection of a middle metatarsal, place a series of nonabsorbable sutures in the remaining intermetatarsal ligaments and metatarsophalangeal

JAYPEE BROTHERS

capsular tissues that will be used to approximate the intermetatarsal space. Pass all of the sutures before tying them down to facilitate easier suture placement. Then apply side-to-side pressure to close the gap and tie the sutures to maintain the closure. Tying the sutures with the hands oriented in the longitudinal axis is better than transversely to achieve a snug closure.
- If a tourniquet is used, deflate and remove it prior to closure so as to not artificially alter the resting soft tissue tension of the flaps.
- Close the wound in a layered fashion with interrupted absorbable suture in the subcutaneous tissue and nonabsorbable sutures in the skin.

TIPS AND TRICKS

- ☑ If the flexor and extensor tendons are not diseased, they can be used to tether the remaining metatarsals together; however, in our experience this is not necessary.
- ☑ Orthotics can be useful to redistribute the weight-bearing forces on the bottom of the foot following ray resection.

Transmetatarsal Amputation (Figs. 126-3 and 126-4)

Guiding principles: Global forefoot disease from tumor, trauma, or vascular insufficiency can lead to the need for a transmetatarsal amputation. Transmetatarsal amputations can be tolerated by the patient with little functional impact on the activities of daily living or cosmetic deficit when wearing a shoe.

Procedure:
- Draw out a fish-mouth type incision at the appropriate location on the midfoot with the dorsal flap slightly longer than the bony amputation and plantar flap long enough to cover the wound including the end of the stump.
- *Tip*: Good quality soft tissue coverage is significantly more important than maintaining maximal bone length.
- *Tip*: The plantar tissue is thicker and therefore better suited to cover the anterior aspect of wound over the end of the stump.
- Incise the skin and dissect from dorsal to plantar, lifting a full-thickness flap off the metatarsals.
- Transect the extensor tendons, ligate the dorsal veins, and cut back sharply the cutaneous nerves.
- Cut each metatarsal perpendicular to its axis with a small oscillating saw.
- Bevel the bone edges removing more plantar bone than dorsal.
- Bevel the first metatarsal more medially and the fifth metatarsal more laterally.
- Maintain the natural cascade of the metatarsals with the first projecting more distally and subsequent metatarsals becoming progressively shorter.
- *Tip*: The plantar flap is more difficult to separate from the metatarsals. Lever the cut end of the distal bone fragment in a dorsal direction. Then cut along the plantar aspect of the metatarsals maintaining as thick a flap as possible working from proximal to distal.
- Expose the flexor tendons and plantar neurovascular bundles. Divide the tendons and nerves and ligate and divide the vessels.
- Identify the common digital nerves in the plantar flap and cut them back sharply.
- If a tourniquet is used, deflate and remove it prior to closure so as to not artificially alter the resting soft tissue tension of the flaps.
- With interrupted sutures tack the plantar flap down to the periosteum on the dorsum of the remaining metatarsals.
- Place a drain under the metatarsals, exiting dorsally and laterally.
- Close the skin with interrupted nonabsorbable sutures.
- *Tip*: Consider performing an Achilles tendon lengthening (TAL) to avoid an equinus contracture.
- *Tip*: The fifth metatarsal is more parallel to the ground than the first metatarsal, so postoperative shoe inserts should provide medial support to evenly distribute weight.

Lisfranc and Chopart Amputations

Guiding principles: Lisfranc amputation is through the TMT joints. As such, it preserves the insertions of many tendons responsible for ankle dorsiflexion and plantarflexion. In contrast, Chopart amputation is through the talonavicular and calcaneocuboid joints, which sacrifices the ankle dorsiflexors.

Either amputation sacrifices the insertions of the tibialis anterior, toe extensors, and peroneal tendons. This primarily compromises dorsiflexion and predisposes to equinus positioning of the stump. Transfer of the tibialis anterior tendon to a remaining tarsal structure is advised.

Tip: Although ankle dorsiflexors can be transferred to the remaining bony structures, a TAL is often required to prevent equinus.

Risks:
- Lisfranc and Chopart amputations have a tendency to develop equinus, often making them less desirable options than a transmetatarsal or hindfoot amputation.
- Increased weight-bearing pressures over the plantar aspect of the end of the stump may lead to pain and/or ulceration.

JAYPEE BROTHERS

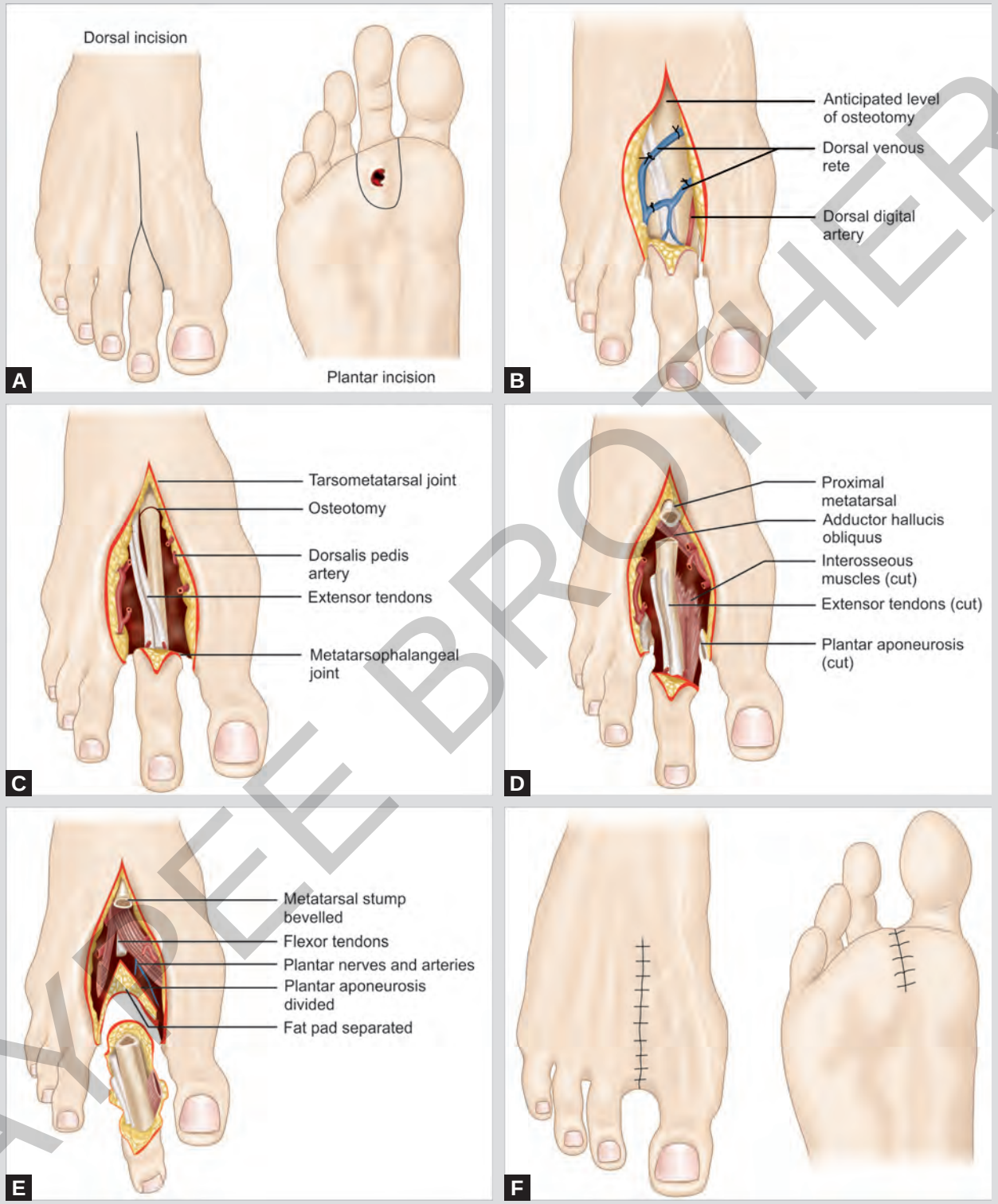

Figs. 126-3A to F: Amputation of the second ray of the foot (*see* text for details). (A) Skin incision. (B) Dorsal soft-tissue dissection to expose the metatarsal. (C) Osteotomy at the base of the metatarsal. (D) Release of other soft tissues. (E) The metatarsal and toe are now free. (F) Skin closure.
Source: Redrawn with permission from Bohne WHO. Atlas of Amputation Surgery. New York: Thieme Medical; 1987. pp. 40-2.

JAYPEE BROTHERS

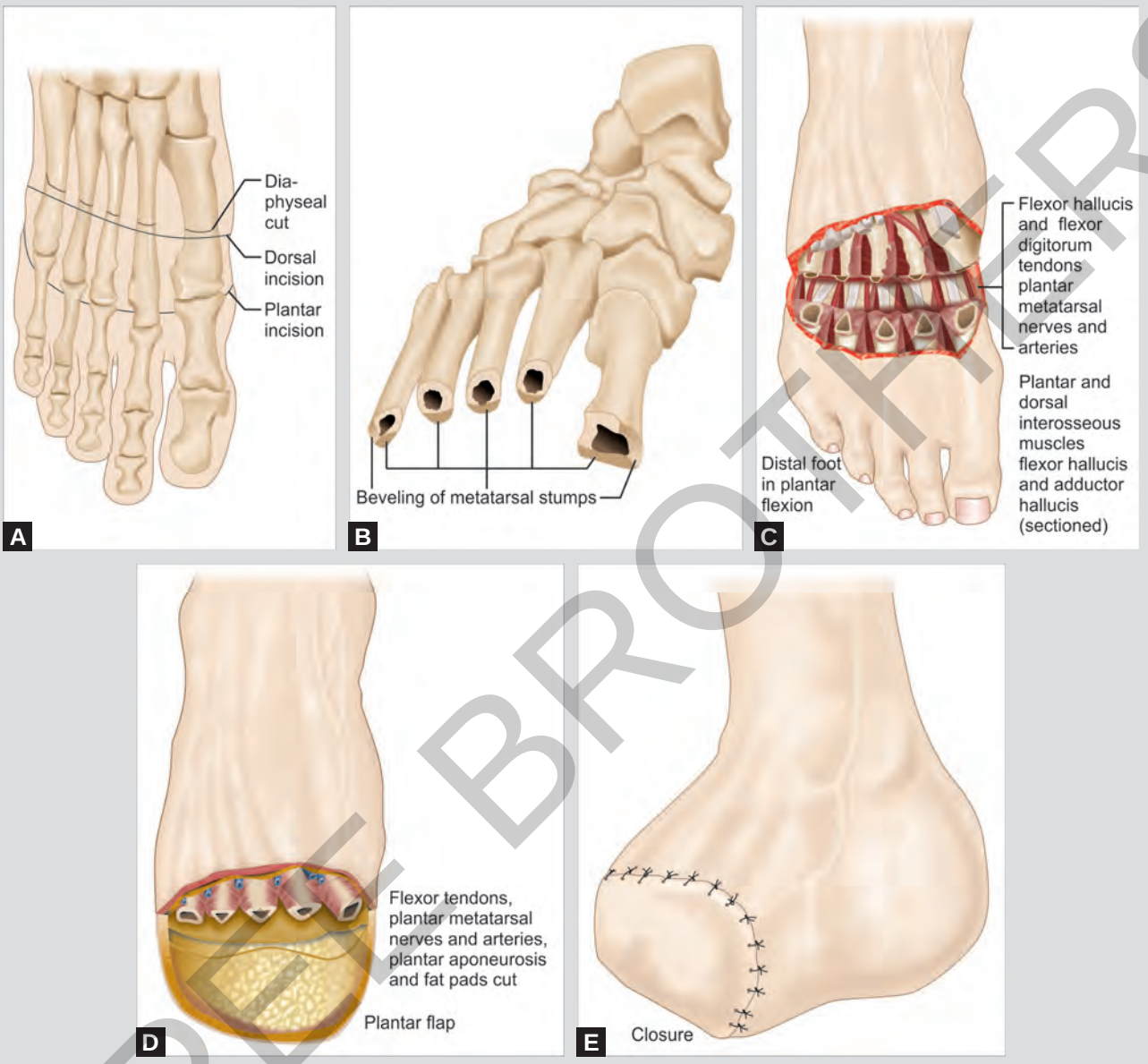

Figs. 126-4A to E: Transmetatarsal amputation (*see* text for details). (A) Dorsal and plantar skin incisions relative to level of transection of the metatarsals. (B) Transection of the metatarsals produces a cascade in which the fifth metatarsal remnant is slightly shorter than the first. Bevel the prominent plantar edges of the metatarsal remnants as well as the lateral aspect of the fifth and medial aspect of the first. (C) Plantarflex the forefoot after transection of the metatarsals to gain access to the plantar structures. (D) Completed amputation. (E) Skin closure.
Source: Redrawn with permission from Bohne WHO. Atlas of Amputation Surgery. New York: Thieme Medical; 1987. pp. 44-7.

Benefits:

- Lisfranc and Chopart amputations maintain limb length and are end weight-bearing.

Procedure:

- Design a fish-mouth type incision. Place the dorsal flap at the level of the disarticulation and make the plantar skin flap long enough to cover the distal end of the amputation.
- *Tip*: The plantar tissue is thicker and therefore better to cover the anterior aspect of wound.
- Incise the skin down to the deep fascia and identify the terminal cutaneous branches of the peroneal nerves and cut them back sharply.

JAYPEE BROTHERS

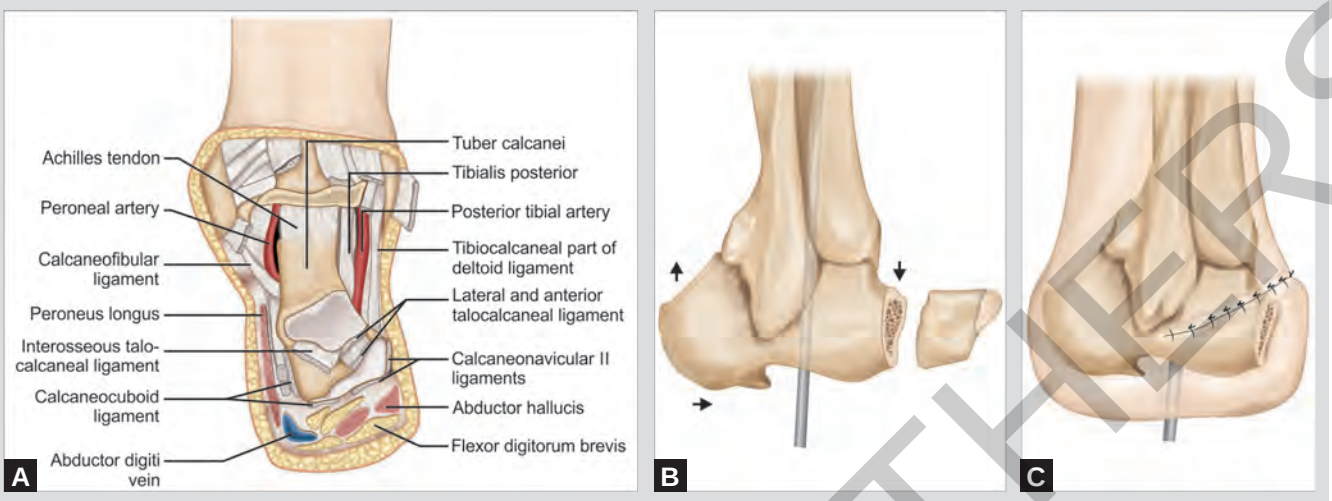

Figs. 126-5A to C: Boyd amputation (*see* text for details). (A) Anterior-dorsal skin incision and exposure with excision of the talus. (B) Excise the anterior process of the calcaneus and remove cartilage from the articular facets. Fit the calcaneus into the ankle mortise, shifting it anteriorly. Secure it with a Steinmann pin. (C) Completed amputation with skin closure.
Source: Redrawn with permission from Bohne WHO. Atlas of Amputation Surgery. New York: Thieme Medical; 1987. pp. 56-7.

- Plantarflex the forefoot to tension the joint capsules, ligaments, and tendons for incision.
- Transect the extensor tendons slightly long to allow their reinsertion onto the remaining tarsal bones.
- Ligate the dorsalis pedis artery.
- *Lisfranc amputation*: Incise the TMT joint capsules and ligaments.
- *Chopart amputation*: Incise the talonavicular and calcaneocuboid joint capsules and ligaments.
- Cut the flexor tendons while avoiding the medial and lateral plantar artery and nerves. Their integrity is essential for a vital and sensate stump.
- Maintain a full-thickness plantar flap in a manner similar to that described for a transmetatarsal amputation.
- Do not damage the cartilage of the remaining tarsal bones.
- *Tip*: Limiting cartilage damage decreases blood loss and maintains a barrier against bone infection.
- If a tourniquet is used, deflate and remove it prior to closure so as to not artificially alter the resting soft tissue tension of the flaps.
- *Tip*: Beware of devitalizing the plantar flap with excessive use of electrocautery.
- Place a drain into the wound that exits medially or laterally.
- Begin covering the distal stump by securing the deep fascia of the plantar flap to the periosteum with absorbable sutures.
- Close the skin with interrupted nonabsorbable sutures.

Boyd Amputation (Figs. 126-5 and 126-6)

Guiding principles: A Boyd amputation involves arthrodesis of the distal tibia to the calcaneus.

Boyd versus Syme's amputations: The Boyd amputation provides a broader weight-bearing surface; however, it is a more complex procedure and has a higher morbidity than a Syme's amputation.

Author's preference: We have moved away from Boyd and Syme's amputations in the adult population because of advances in modern below knee prostheses. Boyd and Syme's amputations are used more commonly in the pediatric population.

Procedure:

- Draw out a fish-mouth incision that crosses the ankle joint dorsally and the plantar surface at the distal end of the heel pad. The corners of the mouth are located 1 cm distal to both the medial and lateral malleoli.
- Make the plantar incision directly down to bone, taking care to achieve hemostasis.
- Then make the dorsal incision with the foot in maximal plantarflexion.
- Transect the dorsal cutaneous sensory nerves and the extensor tendons.
- *Tip*: Use the midfoot and forefoot as a lever to manipulate the hindfoot.
- Expose the tibiotalar joint by opening the anterior capsule.
- Release the deltoid ligament medially and the talofibular ligaments laterally.

JAYPEE BROTHERS

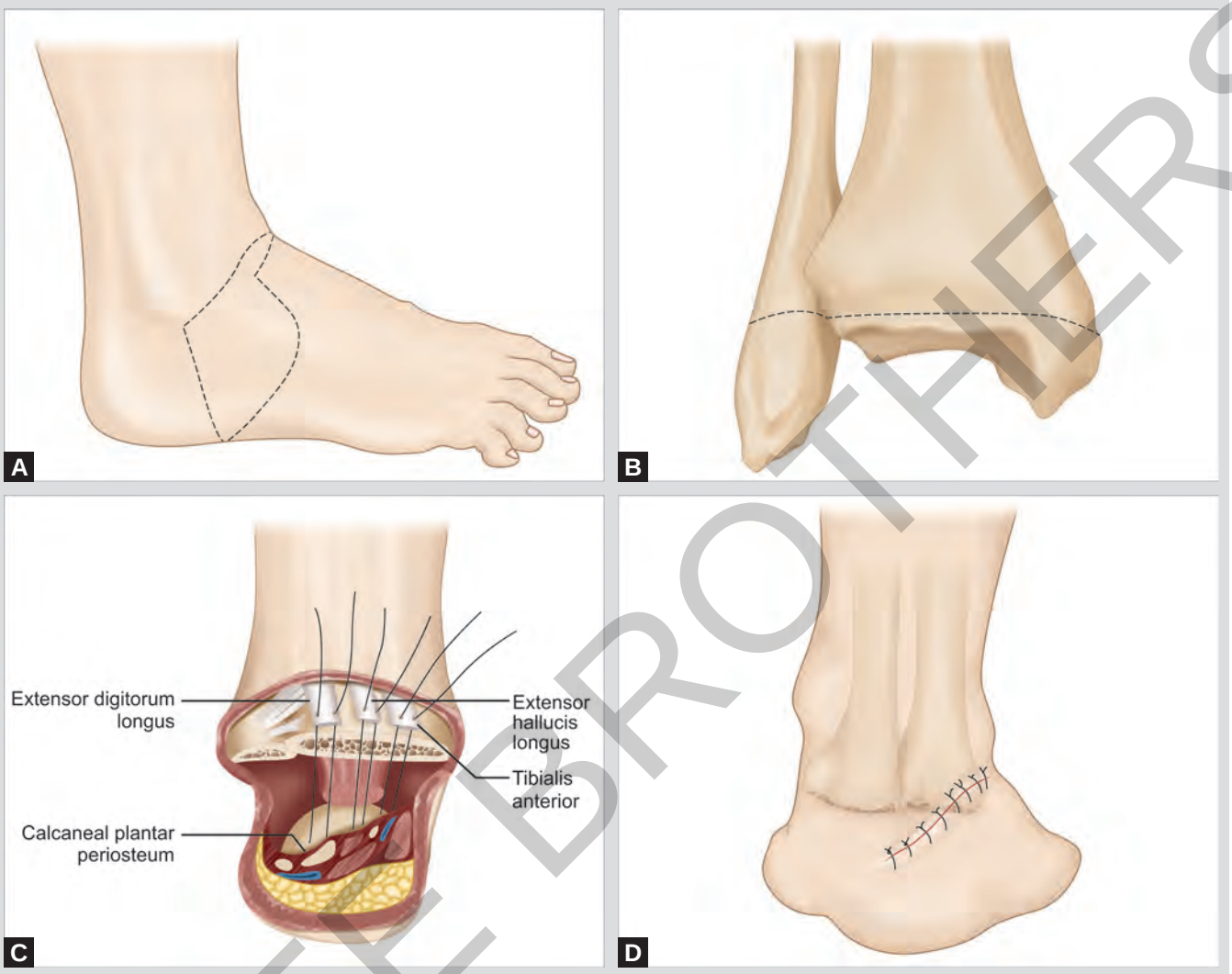

Figs. 126-6A to D: Syme's amputation. (A) Skin incisions. (B) Level of bone transection in adults. (C) Begin closure of the wound by attaching the extensor tendons to the calcaneal periosteum to help stabilize the heel pad. (D) Skin closure.
Source: Redrawn with permission from Bohne WHO. Atlas of Amputation Surgery. New York: Thieme Medical; 1987. pp. 58-62.

Surgical Technique

- *Tip*: Take great care to preserve the posterior tibial artery and vein when working posteromedially around the ankle capsule. The neurovascular bundle lies just medial to the flexor hallucis longus tendon.
- Use a bone hook inserted into the talar dome to sub-luxate the joint anteriorly.
- Now excise the talus, midfoot, and forefoot, leaving the calcaneus attached to the plantar flap.
- Use an oscillating saw to remove the anterior process of the calcaneus and decorticate the superior articular surface to fit into the ankle mortise.
- Decorticate the distal tibia down to cancellous bone.
- Use Kirschner wires, Steinmann pins, or partially threaded screws to fix the calcaneus to the tibia.
- Close the surgical wound in layers providing ample soft tissue coverage.
- Dress the wound and apply a splint. After the risk of swelling has subsided apply a short leg cast to immobilize the fusion site until bone healing occurs.
- *Tip*: In the pediatric population, a long leg cast flexed at 90° at the knee will prevent cast migration.
- The cast and wire/pin fixation can be removed, if necessary, once there is radiographic evidence of calcaneotibial union.

JAYPEE BROTHERS

Syme's Amputation

Guiding principles

Benefits

- The Syme's amputation stump is well-adapted to weight-bearing and walking directly on the stump without a prosthesis over short distances.
- Due to the end weight-bearing, patients can wear a prosthesis for longer periods of time as compared to a BKA.
- A Syme's amputation is used frequently in children, as it preserves the physes at the distal end of the tibia and fibula.

Risks

- Injury to the posterior tibial vessels as dissection is carried around the medial aspect of the calcaneus.
- Late migration of the heel pad due to inadequate fixation.

Procedure:

- Draw out a fish-mouth incision transversely across the anterior ankle from the medial to the lateral malleolus. Then continue the incision in a plantar direction around the anterior process of the calcaneus.
- *Tip*: Error on the side of creating too long a flap, which can later be trimmed. We must caution, however, that too long a posterior flap can be the source of compromised oncologic margins.
- Incise the skin taking care to preserve the tibial neurovascular bundle.
- Identify and transect the extensor tendons, cutaneous nerves, and dorsalis pedis artery and vein.
- Disarticulate the talus from the ankle mortise by transecting the medial and lateral collateral ligaments, again taking care to preserve the posterior tibial artery and nerve.
- Plantarflex the foot to better access the posterior ankle joint.
- Excise the calcaneus subperiosteally from the heel pad.
- *Tip*: Insert a bone hook in the posterior calcaneus and distract it anteriorly to aid the excision.
- Transect the plantar tendons taking care to preserve the neurovascular supply to the posterior heel pad.
- *Tip*: The standard amputation calls for removing the malleoli at the level of the ankle mortise. However, leave the malleoli intact in children and for first-stage amputations in diabetics.
- *Tip*: The heel pad is at risk for posterior translation off the end of the tibia. Options to minimize this risk include:
  - Decorticate the distal tibia to improve adherence of the flap.
  - Maintain the cartilage and suture the flap to the cartilage.
  - Temporarily fix the flap to the tibia with a pin.
  - Sew the anterior tibial tendon and extensor digitorum longus tendon to the anterior heel pad to discourage posterior migration.
  - Secure the Achilles tendon and posterior soft tissues to the anterior tibia with sutures placed through drill holes.
  - *Author's preference*: We prefer to maintain the cartilage on the end of the tibia to avoid excessive bleeding and minimize the risk of infection.
- Close the subcutaneous tissues in a layered fashion with absorbable sutures, incorporating a suction drain to avoid hematoma formation.
- Close the skin with interrupted nonabsorbable sutures.
- *Tip*: The postoperative wound will smooth itself and dog-ears will remodel without the need to be trimmed.
- *Author's preference*: Immediate weight bearing has been described in the pediatric population, but we prefer to apply a cast and keep the patient nonweight bearing for 4 weeks.

Below Knee Amputation (Figs. 126-7 to 126-10)

Guiding principles: Good soft tissue coverage is more important than preservation of limb length. Nonetheless, the minimum length associated with good function is 12 cm of tibial shaft as measured from the medial tibial plateau.

Author's preference: Based on anatomic limitations and the size of the patient, we aim to fashion a 12–15 cm stump.

Various skin flap designs exist. In our opinion, the long posterior flap is the most versatile. The subcutaneous position of the tibia anteriorly does not provide for ample anterior skin flaps and more tissue is easily acquired posteriorly. Moreover, this method locates the scar anteriorly as opposed to distally, on the weight-bearing portion of the stump.

Procedure:

- Draw out a fish-mouth incision on the anterior aspect of the leg approximately 1 cm distal to the level of the bone cut and a longer flap posteriorly.
- *Tip*: Error on the side of too long a flap, which can later be trimmed.
- Anteriorly cut perpendicular to the skin down to the deep fascia and periosteum of the tibia. Extend the incision medially and laterally approximately two-thirds the anteroposterior (AP) diameter of the leg.
- Develop the long posterior flap by redirecting the incision distally. Create a posterior flap that is at least

JAYPEE BROTHERS

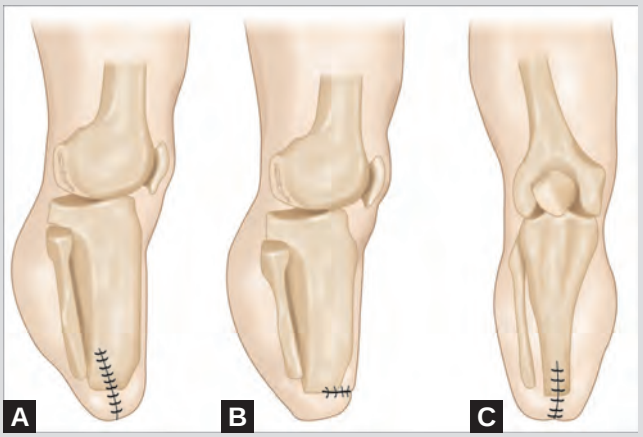

Figs. 126-7A to C: Suture line in various types of below-knee amputations. (A) In the nonischemic limb. (B) Amputation of the ischemic limb in the coronal plane. (C) Amputation of the ischemic limb in the sagittal plane.
Source: Redrawn with permission from Bohne WHO. Atlas of Amputation Surgery. New York: Thieme Medical; 1987. p. 69.

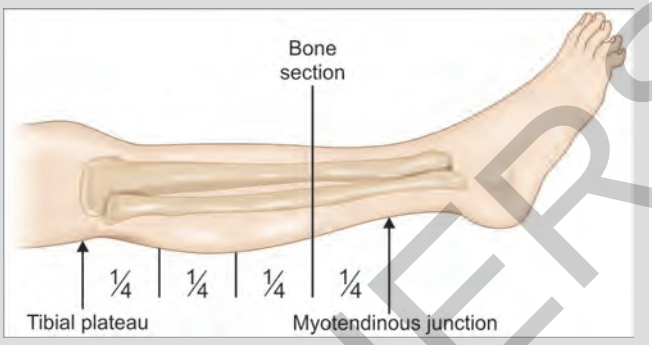

Fig. 126-8: Use a sterile marking pen to divide the leg into four equal quadrants from the tibial plateau to the myotendinous junction of the gastrocnemius and soleus muscles. In most cases, transect the bone at the distal portion of the third quarter.

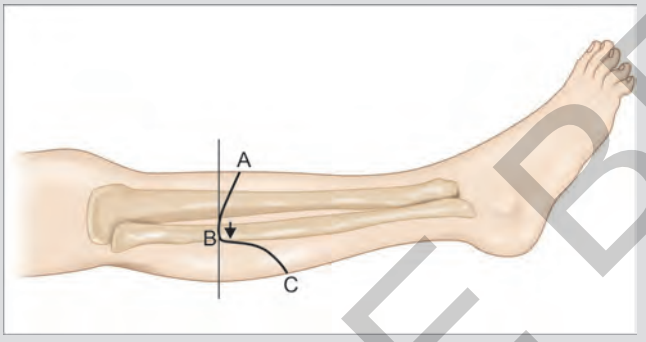

Fig. 126-9: Skin incision for a below-knee amputation as described by Mooney. A. Anterior flap, B. Apex, C. Posterior flap.

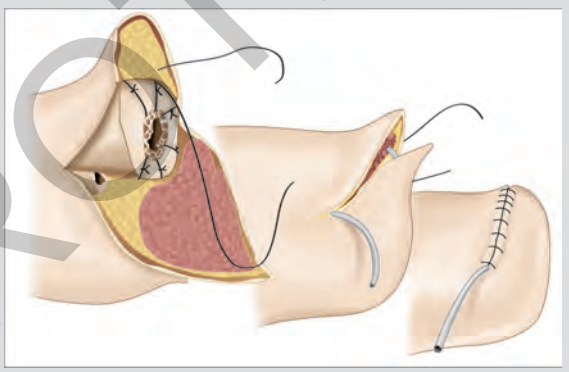

Fig. 126-10: Below-knee amputation. Myoplastic closure with approximation of the fascia of the posterior flap to the fascia of the anterior compartment and periosteum of the tibia, and subsequent closure of the subcutaneous tissues and skin over a drain placed at the level of the bone.
Source: Redrawn with permission from Bohne WHO. Atlas of Amputation Surgery. New York: Thieme Medical; 1987. p. 68.

equal in length to the AP diameter of the leg at the level that the bone will be cut.

- Lift a cuff of periosteum off the anterior tibia before beveling the bone. This preserved periosteum will be used later in the wound closure.
- Cut the tibia perpendicular to its axis with an oscillating saw.
- Bevel the tibia anteriorly approximately 30° to eliminate a sharp corner, as this area has less soft tissue coverage.
- Cut the fibula at least 1 cm proximal to the level of the tibial cut.
- Begin dividing the muscles and neurovascular bundles from anterior to posterior.
- *Tip*: The division of the muscles in the posterior flap is a taper where the muscles are full thickness next to the tibia and then taper gradually to the thickness of the fascia alone at the tip of the flap.
- Five nerves must be identified and cut to retract:
  - Saphenous
  - Superficial peroneal
  - Deep peroneal
  - Tibial
  - Sural
- Tension the nerves to approximately 2 cm beyond the muscle and then cut them back sharply.
- *Tip*: Be sure to identify and transect appropriately the sural nerve, which comes in close proximity to the distal stump and is a common source of painful neuroma. Similar attention should be paid to the saphenous nerve, which is located close to where the prosthesis puts maximal pressure on the stump.

JAYPEE BROTHERS

for detailed information on orthopaedic books, visit our website www.jaypeebrothers.com, for detailed information on orthopaedic books, visit our website www

CHAPMAN'S
COMPREHENSIVE
ORTHOPAEDIC SURGERY

Chapman's Comprehensive Orthopaedic Surgery, 4th Edition, is essentially a totally new text and provides extensive coverage of the work-up, surgical and medical treatment and rehabilitation of musculoskeletal disorders. The 12 section editors and 554 internationally recognized authors present in 12 subspecialty sections and 285 chapters comprehensive coverage with thousands of new tables, flowcharts, and full color 3D illustrations and photographs. Surgical techniques are bulleted and boxes on Tips and Tricks, Pitfalls and Complications and authors' perspective provide important "information at a glance". The digital edition has enhanced features and a video library is available.



Michael W Chapman MD FAOA FACS, Emeritus Professor of Orthopaedic Surgery in the School of Medicine (SOM) at the University of California Davis (UCD) located in Sacramento, California, USA, wrote many of the chapters for and edited the first edition of *Chapman's Comprehensive Orthopaedic Surgery*, published in 1988. Following undergraduate education at American River College and the University of California Davis, Sacramento, California, he attended medical school and served a residency in orthopaedic surgery at the University of California San Francisco (UCSF), San Francisco, California. He served three years in the United States Army, stationed in Europe, and then returned to the faculty at UCSF where he furthered his interest in orthopaedic trauma as the assistant chief of orthopaedics at San Francisco General Hospital, San Francisco, California, USA. He served as chair of the Department of Orthopaedic Surgery in the SOM at UCD from 1979 to 2000 and played a key role in the development of the UCD Medical Center, Level-1 Trauma Center. He was a co-founder and served as the second president of the Orthopaedic Trauma Association. He has held leadership roles in many major national orthopaedic societies and was president of the American Orthopaedic Association. His career as a traumatologist, operating on all aspects of the musculoskeletal system, and basic science interest in bone regeneration, provides an ideal background for editing this comprehensive text on musculoskeletal surgery and medicine, and rehabilitation.



Michelle A James MD FAOA is Chief of Orthopaedic Surgery at Shriners Hospitals for Children—Northern California, Sacramento, California, and Professor of Clinical Orthopaedic Surgery at University of California Davis, Sacramento, California and University of California San Francisco, San Francisco, California, USA.

Dr James is a pediatric orthopaedic hand surgeon, specializing in the treatment of congenital, neuromuscular and post-traumatic hand and arm problems. Her research focuses on children's hand function. She has authored over 100 scientific publications, and she served as Deputy Editor for The Journal of Hand Surgery. She currently serves as Deputy Editor for Hand, Upper Extremity, and Topics in Training for The Journal of Bone and Joint Surgery.

Available at all medical bookstores
or buy online at www.jaypeebrothers.com

JAYPEE BROTHERS
Medical Publishers (P) Ltd.
www.jaypeebrothers.com

Join us on facebook.com/JaypeeMedicalPublishers

Shelving Recommendation
ORTHOPAEDICS

ISBN 978-93-5152-497-7

9 789351 524977