surgery books, visit our website **www.jaypeebrothers.com,** for detailed information on surgery books

ATLAS OF ENDOCRINE SURGICAL TECHNIQUES



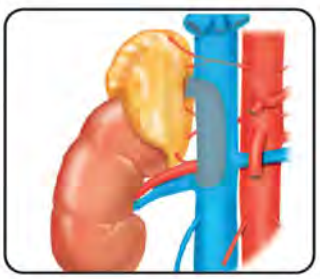




INCLUDES INTERACTIVE DVD-ROM

Editor
Sally E Carty

Foreword
Jon van Heerden

JAYPEE

Contents

Section 1: Thyroid Surgery 1

1. **Surgeon-Performed Ultrasound for Thyroid Nodules** 3
   Denise Carneiro-Pla, Carmen C Solorzano
2. **Thyroidectomy** 13
   Christopher R McHenry
3. **Thyroidectomy for Substernal Goiter** 25
   Kelly L McCoy, Ashok R Shaha
4. **Thyroidectomy for Locally Advanced Cancer** 33
   Henning Dralle, Andreas Machens, Nguyen Thanh Phuong
5. **Reoperative Thyroidectomy** 43
   Leigh Delbridge, Olov Norlén
6. **Central Node Dissection for Thyroid Cancer** 49
   Victoria Lai, Douglas B Evans, Tracy S Wang
7. **Lateral Neck Dissection for Thyroid Carcinoma** 59
   Shuddhadeb Ray, Jeffrey F Moley
8. **Robotic Total Thyroidectomy with a Gasless, Transaxillary Approach** 69
   Sohee Lee, Woong Youn Chung
9. **Laryngeal Function and Intraoperative Laryngeal Nerve Monitoring** 83
   Ashley K Cayo, Jan S Lewin, Nancy D Perrier
10. **Molecular Diagnostic Testing of Thyroid Nodules** 95
    Linwah Yip, Thomas J Fahey III

Section 2: Parathyroid Surgery 99

11. **Intraoperative Parathyroid Hormone Monitoring** 101
    Dawn M Elfenbein, Herbert Chen
12. **Bilateral Exploration for Hyperparathyroidism** 109
    Janice L Pasieka
13. **Minimally Invasive Parathyroid Surgery** 115
    Glenda G Callender, Robert Udelsman
14. **Minimally Invasive Video-Assisted Parathyroidectomy** 125
    Paolo Miccoli, Valeria Matteucci, Carlo Enrico Ambrosini
15. **Reoperative Parathyroid Surgery** 139
    Carolyn D Seib, Orlo H Clark
16. **Surgery for Secondary/Tertiary Hyperparathyroidism** 147
    Claudio Golfier, Jean-François Henry

17. **Parathyroid Autotransplantation and Cryopreservation** 155
Reza Rahbari, Allan Siperstein

18. **Surgery for MEN-1 Hyperparathyroidism** 159
Steven K Libutti, James A Lee

Section 3: Adrenal Surgery 167

19. **Laparoscopic Adrenalectomy** 169
Carolyn D Seib, Quan-Yang Duh

20. **Endoscopic Retroperitoneal Adrenalectomy** 177
Jennifer H Kuo, James A Lee

21. **Open Adrenalectomy** 185
Benzon M Dy, Geoffrey B Thompson

22. **Perioperative Management of Functional Adrenal Tumors** 191
Deva Boone, Richard A Prinz

23. **Adrenal Metastasectomy** 199
Samira M Sadowski, Electron Kebebew

24. **Paraganglioma Resection** 211
Ibrahim Nassour, Martha A Zeiger

Section 4: Surgery for Pancreatic and Carcinoid Tumors 219

25. **Resection of Duodenal Gastrinoma** 221
Gerard M Doherty

26. **Open Management of Pancreatic Neuroendocrine Tumor** 227
Clive S Grant

27. **Laparoscopic Management of Pancreatic Neuroendocrine Tumors** 239
Rohan A Joseph, William B Inabnet III

28. **Resection of Small Intestine Neuroendocrine Tumors** 249
Göran Åkerström, Peter Stålberg, Per Hellman

29. **Management of Neuroendocrine Tumor Metastatic to the Liver: Robotic-Assisted Right Hepatectomy and Laparoscopic Radiofrequency Ablation** 261
Patricio M Polanco, David L Bartlett

Index 273

Thyroidectomy for Locally Advanced Cancer

4

Henning Dralle, Andreas Machens, Nguyen Thanh Phuong

1 PREOPERATIVE

1.1 Indications

- Resectable locally advanced differentiated and medullary thyroid cancer
- Resectable local tumor recurrence
- *Contraindications:* Advanced undifferentiated thyroid cancer or malignant lymphoma

1.2 Evidence

- Prevention and treatment of aerodigestive tract invasion (ADTI)
- Significant improvement of locoregional recurrence rates and survival after microscopically complete compared to incomplete resection[1-3]

1.3 Materials Needed

- Magnifying glasses
- Retractors
- Vascular clamps
- Mini-saw for partial laryngeal resection
- Special instruments for replacement of the esophagus with a free jejunal graft
- Oscillating and automatic saw for median sternotomy (Figs. 4.1 to 4.3)



Fig. 4.1: Retractors (sharp, venous, lid, nerve).

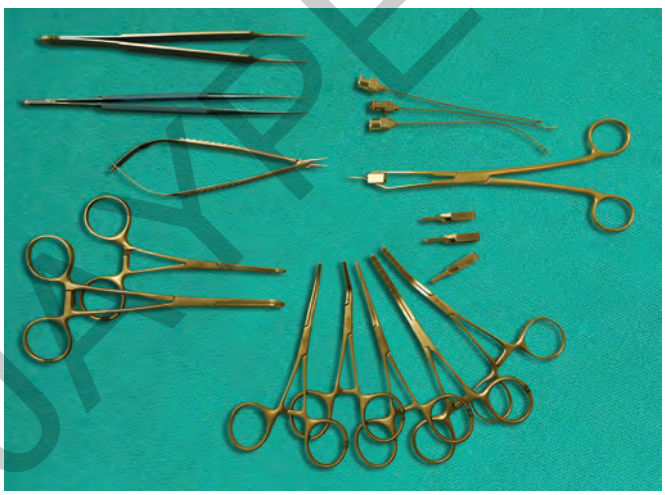

Fig. 4.2: Vascular instruments.



Fig. 4.3: Saws (mini-saw and saws for sternotomy).

JAYPEE BROTHERS

1.4 Preoperative Planning and Risk Assessment

Planning:

- Check vocal fold function.
- Check resectability by cross-sectional imaging (computed tomography, magnetic resonance imaging), and tracheoesophagoscopy in the case of transmural ADTI.
- Check operability by cardiopulmonary testing and systemic staging.
- Consider preoperative ultrasound-guided or open biopsy to exclude rapidly proliferating malignancies suitable for multimodal (neoadjuvant) treatment.

Risk assessment:

- *Disease-related risk:* Type and extent of thyroid malignancy (locoregional versus systemic)
- *Patient-related risk:* Age, physical shape, and mental condition
- *Low risk:* Differentiated thyroid cancer, young age, no cardiopulmonary comorbidity, intact vocal cord function, no ADTI
- *Intermediate risk:* Poorly differentiated or medullary thyroid cancer, intermediate age, history of myocardial infarction, unilateral vocal cord palsy, limited unilateral aerodigestive traction invasion
- *High risk:* Poorly differentiated or medullary thyroid cancer, advanced age, serious cardiopulmonary comorbidity, bilateral vocal cord palsy, or encasement of the recurrent laryngeal nerves, extensive uni- or bilateral tracheal invasion

1.5 Preoperative Checklist

- Laryngoscopic examination of vocal cord function
- Exclusion of coexistent pheochromocytoma in the case of hereditary medullary thyroid cancer

Before incision:

- Check patient's identity.
- Check vocal cord report.
- Check indication, type of surgery, and patient's positioning.
- Indicate the expected duration of surgery and anticipated blood loss.
- Indicate antibiotic prophylaxis.

At the end of surgery:

- Check that all materials have been removed from the operative field.
- Summarize the type and extent of surgery.
- Specify the need for postoperative monitoring and treatment.
- Verify that materials sent to surgical pathology or microbiology are correctly labeled.

1.6 Decision-Making Algorithm for ADTI

See Flowchart 4.1.

1.7 Pearls and Pitfalls

Pearls:

- When the posterior thyroid or the vascular sheath is involved:
  - Ensure that one recurrent laryngeal nerve/vagus nerve is preserved on at least one side.
  - Start on the uninvolved side using intraoperative nerve monitoring.
- When the aerodigestive tract is involved:
  - Refrain from prophylactic resections of uninvolved soft tissues, muscles, and nodes in the neck.
- When the tumor extends to the upper mediastinum:
  - Clarify the need for median sternotomy.
  - Perform sternotomy "as early as necessary and as late as possible".

Pitfalls:

- Avoid injuring both recurrent laryngeal/vagus nerves or both internal jugular veins.
- Avoid resecting a phrenic nerve in conjunction with a recurrent laryngeal/vagus nerve.
- Avoid resecting and reconstructing the aerodigestive tract and a carotid artery with the use of a vascular prosthesis during the same session.
- Prevent leakage after extramucosal esophageal resection by approximating the esophageal muscular layers around the defect with the use of interrupted or continuous sutures.
- Avoid fashioning a tracheostomy above the level of the tracheal anastomosis after tracheal resection.

1.8 Surgical Anatomy

See Figures 4.4 and 4.5.

1.9 Positioning

See Figures 4.6A and B.

1.10 Anesthesia

Because muscle relaxants interfere with the electromyography response signal during intraoperative nerve monitoring, the following procedural safeguards need to be taken:

- After induction of anesthesia neuromuscular blocking agents should be weaned off and avoided throughout the rest of the case.
- Apart from these restrictions, the anesthetist is free to choose any other medication during the operation.

JAYPEE BROTHERS

Flowchart 4.1: Decision-making algorithm for aerodigestive tract invasion.

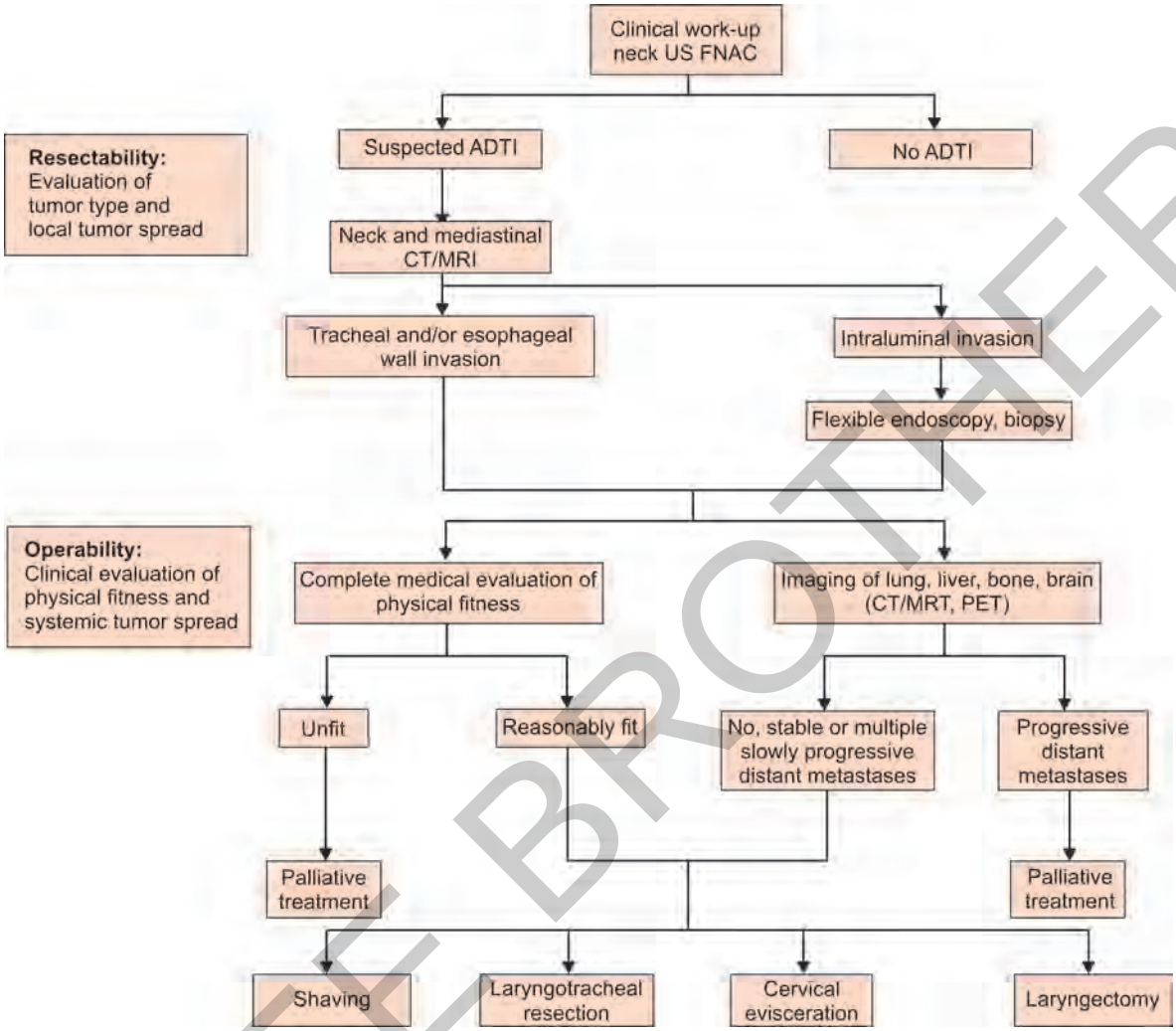

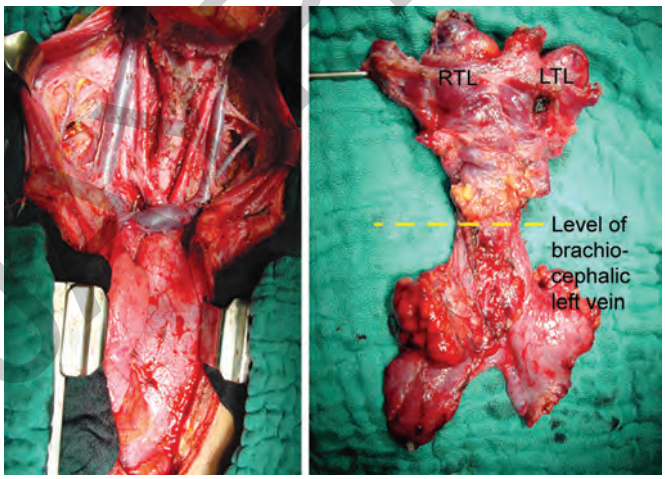

Fig. 4.4: Trans-sternal thyroidectomy with lymph node dissection of the central and lateral neck and upper mediastinum (left; surgical anatomy after removal of the contiguous surgical specimen (right), which encompasses the thyroid, the central neck and the mediastinal compartment together with the thymus.

JAYPEE BROTHERS

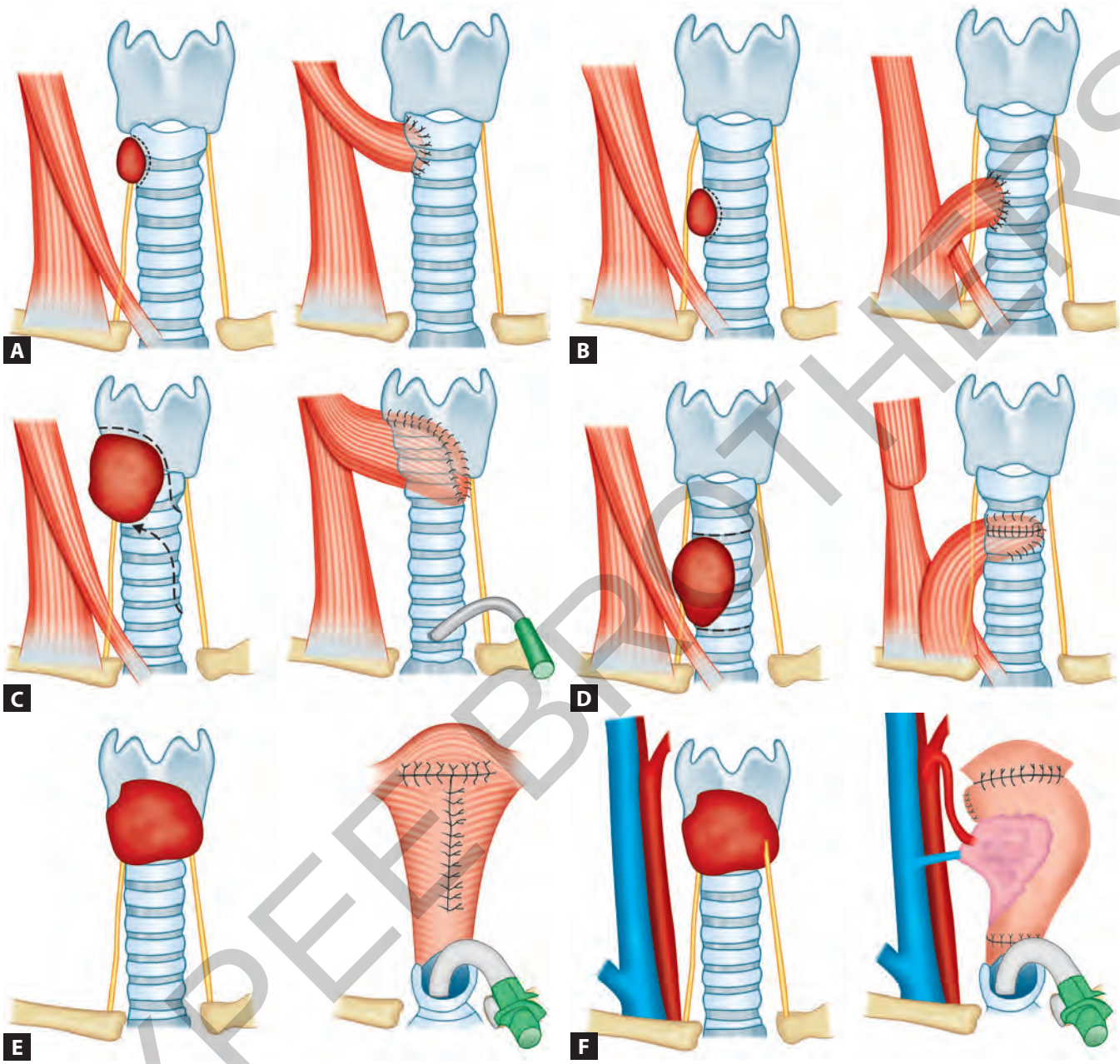

Figs. 4.5A to F: Classification of aerodigestive tract invasion in thyroid cancer. (A) Laryngocricoid, unilateral, ≤ 2 cm longitudinally, ≤ ¼ of circumference: window resection, SCM flap. (B) Trachea, unilateral, ≤ 2 cm longitudinally, ≤ ¼ of circumference: window resection, SCM flap. (C) Laryngocricoid, unilateral, > 2 cm longitudinally, > ¼ of circumference: oblique sleeve resection, primary anastomosis, SCM flap. (D) Trachea, uni- or bilateral, > 2 cm longitudinally, > ¼ of circumference: sleeve resection, primary anastomosis, SCM flap. (E) Laryngocricoid, bilateral: laryngectomy. (F) Laryngocricoid, bilateral plus hypopharynx/esophagus: cervical evisceration, tracheostomy, free jejunal graft. (SCM: Sternocleidomastoid muscle).

2 PERIOPERATIVE

2.1 Incision

Extended Kocher incision for thyroidectomy, central and lateral node dissection, or aerodigestive tract resection (Fig. 4.7).

2.2 Steps

Trachea Window Resection

See Figures 4.8 to 4.11.

Trachea Sleeve Resection

See Figures 4.12 to 4.16.

JAYPEE BROTHERS





Figs. 4.6A and B: (A) Patient is positioned supine with the left arm extended and (B) the right arm draped to the body.



Fig. 4.7: Neck incision third postoperative day after thyroidectomy, bilateral central and lateral node dissection due to medullary thyroid cancer.

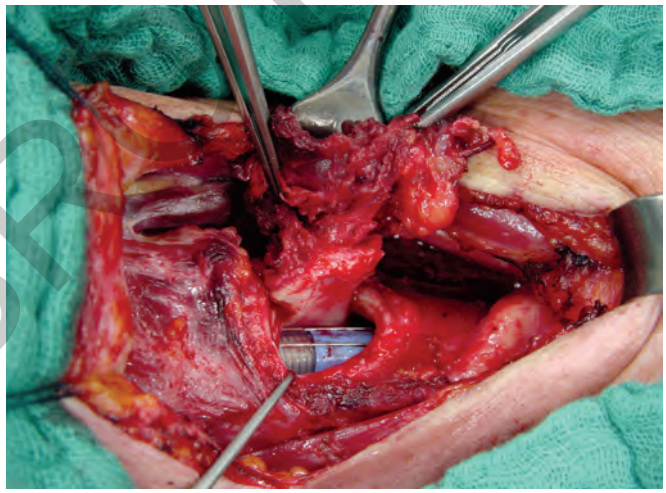

Fig. 4.8: Centripetal dissection of the tumor around the site of tracheal invasion: left window resection.

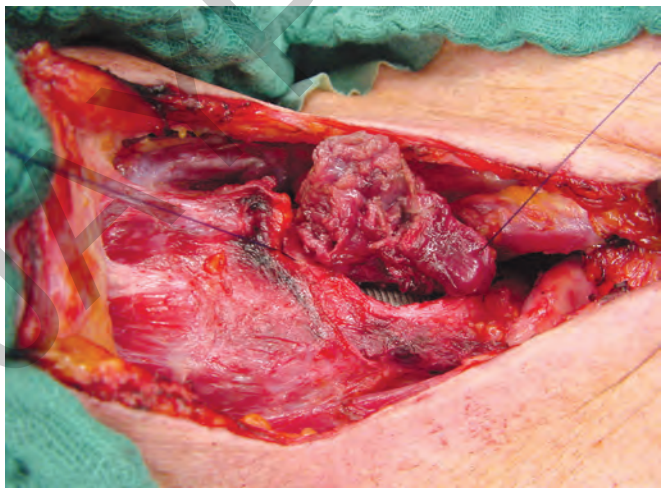

Fig. 4.9: After window resection ipsilateral sternocleidomastoid muscle flap is raised. Suturing of the flap onto the tracheal defect, with the fascia-covered aspect of the muscle facing the trachea.

JAYPEE BROTHERS

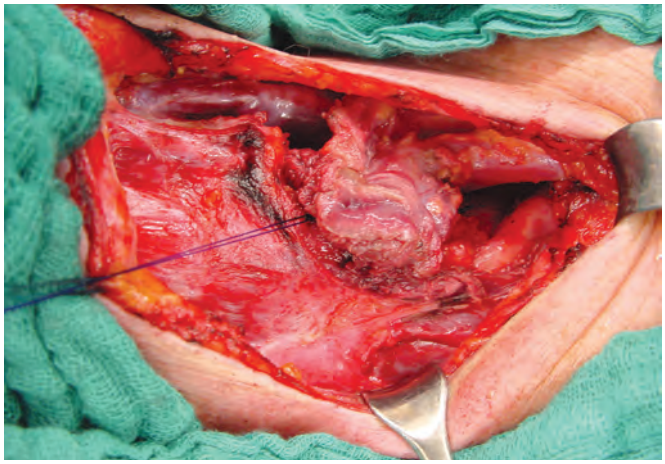

Fig. 4.10: Fashioning of the inner suture line of the trachea-sternocleidomastoid muscle anastomosis.

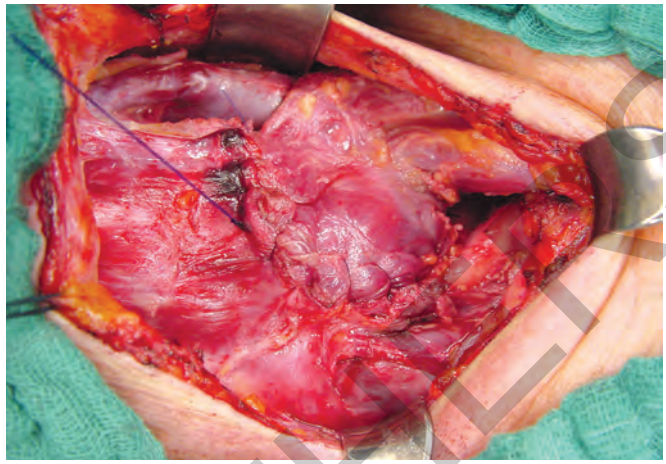

Fig. 4.11: Completion of the outer suture line of the trachea-sternocleidomastoid muscle anastomosis.

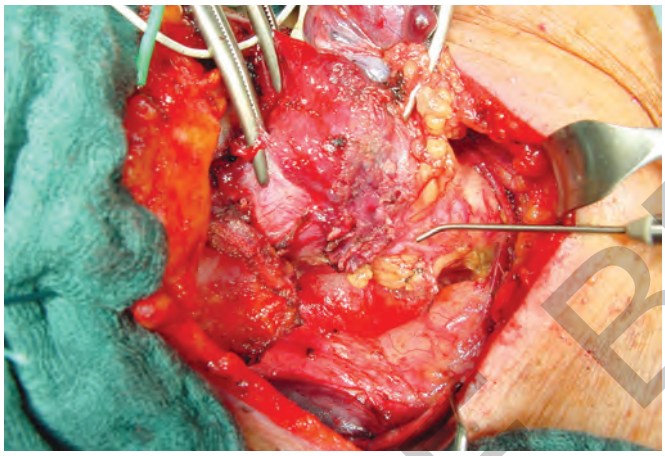

Fig. 4.12: Thyroid cancer invading the right anterior tracheal wall. Identification of the right recurrent laryngeal nerve with the use of nerve monitor.

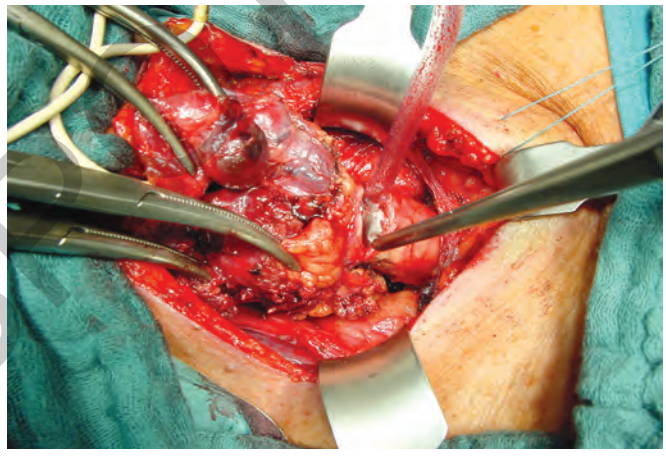

Fig. 4.13: Incision of the trachea below the level of invasion.

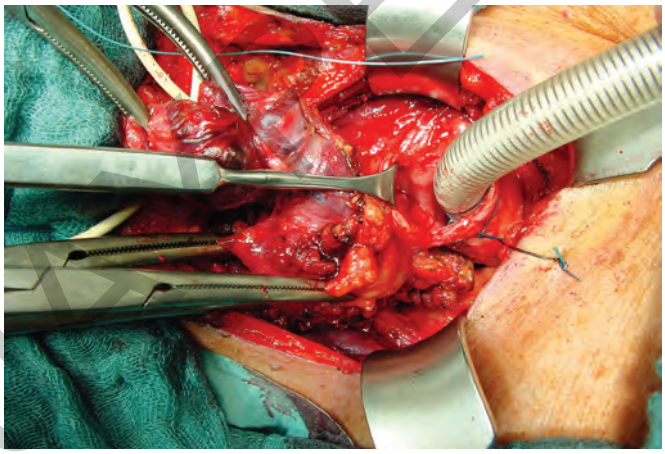

Fig. 4.14: Completion of the inferior trachea transection with change of the endotracheal tube, now placed through the line of transection.

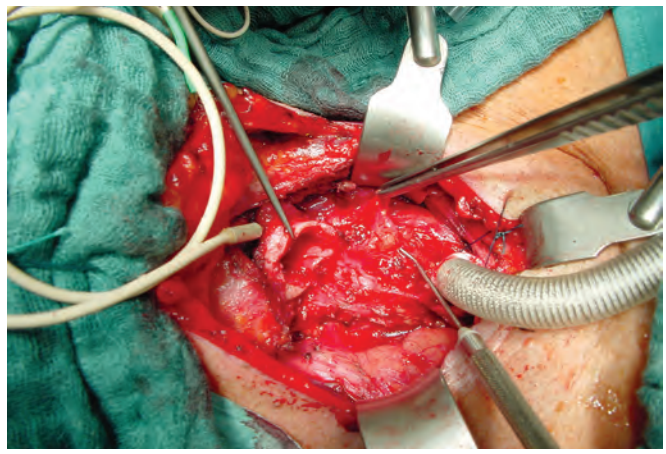

Fig. 4.15: Intraoperative monitoring of the left recurrent laryngeal nerve after trachea sleeve resection.

FREE BOOKLETS

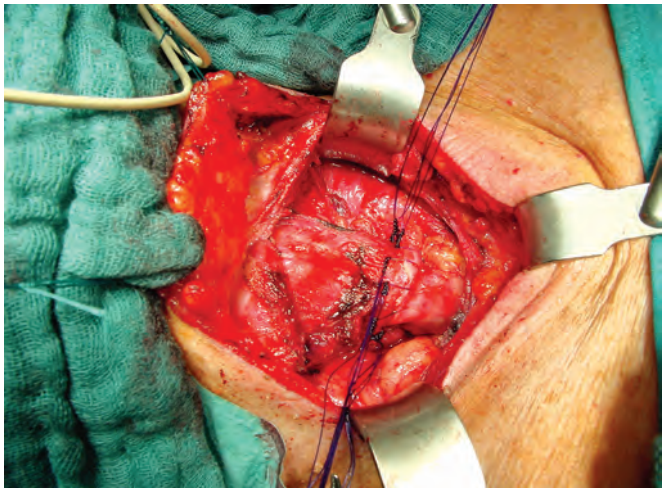

Fig. 4.16: Completion of the trachea anastomosis over an orotracheal tube using interrupted sutures.

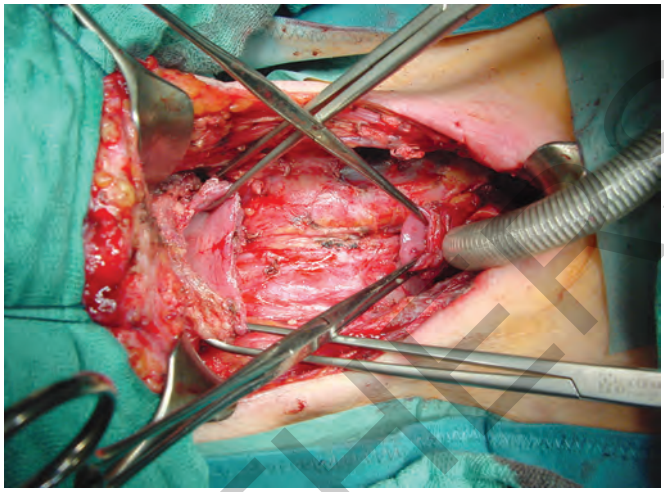

Fig. 4.17: Surgical anatomy after resection of the larynx, hypopharynx, and the cervical trachea with the endotracheal tube placed through the inferior trachea.

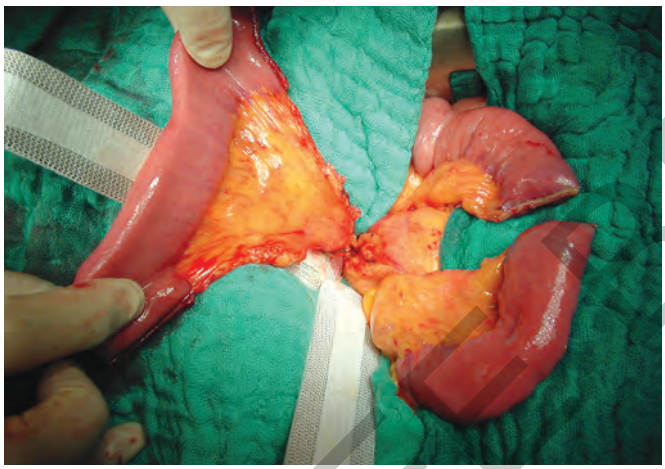

Fig. 4.18: Harvesting of a free jejunal graft: division of the mesentery and preparation of the feeding vessels.

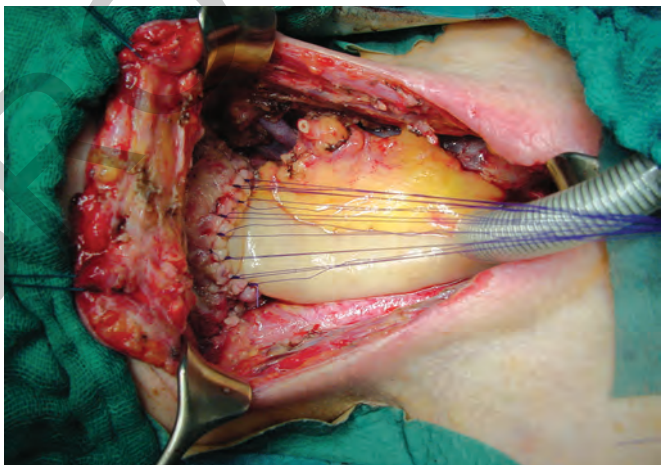

Fig. 4.19: Replacement of the cervical esophagus with a free jejunal graft (first step): Reconstruction of digestive continuity by fashioning the inferior anastomosis (end-to-end) first and the superior anastomosis (end-to-end or side-to-end) last.

Cervical Evisceration

Resection of the larynx, hypopharynx and proximal trachea, interposition of a free jejunal graft, and fashioning of a terminal tracheostomy (Figs. 4.17 to 4.22).

3 POSTOPERATIVE

3.1 Common Surgical Complications

- Recurrent laryngeal nerve palsy
- Hypoparathyroidism

3.2 Infrequent Surgical Complications

- Postoperative hemorrhage
- Wound infection
- Tracheal or esophageal leakage
- Graft ischemia
- Mortality

3.3 Outcome

- Locoregional recurrence arises in up to 50% after incomplete tumor resection, as opposed to 15% after complete tumor resection[1]
- 10-year disease-specific survival of 88%, 63%, and 11% after tracheal shaving, complete, and incomplete tumor resection, respectively[1]

JAYPEE BROTHERS

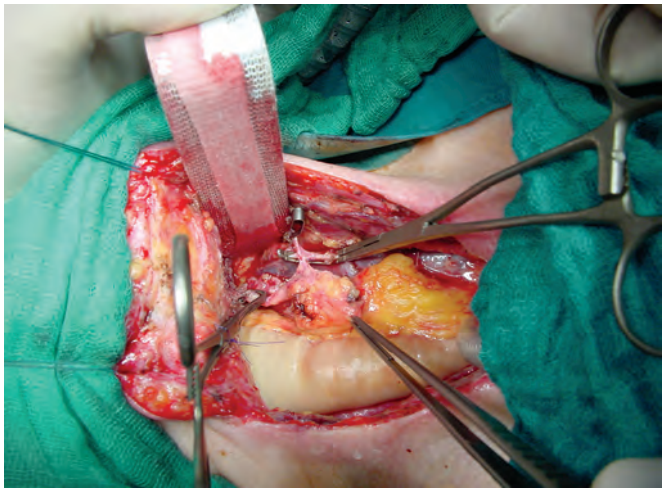

Fig. 4.20: Reconstruction of digestive continuity with a free jejunal graft (second step): The feeding mesenteric vein is connected to the internal jugular vein before the feeding mesenteric artery is hooked up to the external carotid artery.

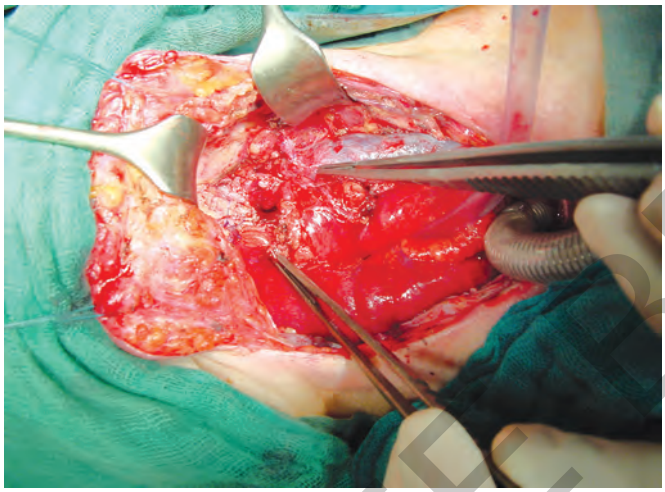

Fig. 4.21: Free jejunal graft after revascularization.



Fig. 4.22: Gastrografin swallow on postoperative day 7 showing free jejunal transport with no evidence of leakage.

3.4 Follow-Up

- Postoperative Gastrografin swallow after esophageal resection and reconstruction
- Endoscopy of the trachea and/or the interposed jejunal graft depending on the type of resection (trachea, cervical esophagus)
- Laryngoscopy after larynx-preserving procedures
- Measurement of serum calcium and intact parathyroid hormone levels; substitution of calcium and vitamin D as needed
- Adjustment of thyroxine substitution
- Inspection of the surgical site after 4 weeks
- Postoperative restaging 3 and/or 6 months after surgery depending on tumor type and extent of disease

3.5 Video Clip

Papillary thyroid cancer with trachea invasion, en bloc thyroidectomy, and trachea sleeve resection (4.1).

3.6 Email an Expert

Email Address: henning.dralle@uk-halle.de

REFERENCES

1. Brauckhoff M, Machens A, Nguyen Thanh P, et al. Impact of extent of resection for thyroid cancer invading the aerodigestive tract on surgical morbidity, local recurrence, and cancer-specific survival. Surgery. 2010;148:1257-66.

JAYPEE BROTHERS

2. Wada N, Nakayama H, Masudo Y, et al. Clinical outcome of different modes of resection in papillary thyroid carcinomas with laryngotracheal invasion. Langenbecks Arch Surg. 2006;391:545-9.
3. McCaffrey JC. Aerodigestive tract invasion by well-differentiated thyroid carcinoma: diagnosis, management, prognosis, and biology. Laryngoscope. 2006;116:1-11.

QUIZ

Question 1: Will laryngoscopy need to be performed routinely in patients with advanced thyroid cancer who have a normal voice?

a. No
b. Yes
c. Depending on the results of imaging
d. Depending on the planned extent of surgery

Question 2: Will preoperative endoscopy of the trachea and/or esophagus need be performed routinely in patients with advanced thyroid cancer?

a. No
b. Yes
c. Depending on the results of imaging
d. Depending on the planned extent of surgery

Question 3: Is postoperative radioiodine ablation a valuable adjunct to the surgical treatment of medullary thyroid cancer?

a. No
b. Yes
c. Only for patients with bilateral hereditary medullary thyroid carcinoma (MTC)
d. Only for patients with metastatic disease

Question 4: What is the preferred treatment for patients with malignant lymphoma that is locally invasive?

a. Extensive resection
b. Radiochemotherapy
c. Observation ("wait and *see*")
d. Immunotherapy

Question 5: What is the single most life-threatening surgical complication caused by infection of the neck wound after resection of advanced thyroid cancer?

a. Trachea leakage
b. Esophageal leakage
c. Hemorrhage from the carotid artery
d. Recurrent laryngeal nerve palsy

ANSWER:

1. b 2. c 3. a 4. b 5. c

JAYPEE BROTHERS

for detailed information on surgery books, visit our website **www.jaypeebrothers.com,** for detailed inf

ATLAS OF ENDOCRINE SURGICAL TECHNIQUES

The *Atlas of Endocrine Surgical Techniques* is a lushly illustrated surgical atlas that captures the entire field of endocrine surgery in 29 chapters written by expert faculty members from leading US, European, and Asian medical schools. The work is organized into four sections devoted to Thyroid Surgery, Parathyroid Surgery, Adrenal Surgery, and Surgery for Pancreatic and Carcinoid Tumors. Specific techniques are covered for endoscopic resection of all four major types of endocrine tumors. Novel topics include surgeon-performed ultrasound for thyroid nodules, robotic thyroidectomy, molecular testing of thyroid nodules, reoperative parathyroid surgery, parathyroid autotransplantation and cryopreservation, adrenal metastasectomy, resection of small intestinal neuroendocrine tumors, and hepatic metastasectomy for neuroendocrine tumors. Many chapters include videos that demonstrate surgical techniques and expertise.

Rather than containing dense passages of the text, each chapter features:

- Bulleted points that allow the reader to gather information at a glance
- Sections devoted to indications, evidence, preoperative assessment, surgical planning, instruments needed, surgical techniques, follow-up, and complications
- Illustrated surgical techniques with anatomical drawings and photographs
- Evidence for the surgical treatment options under discussion
- A wealth of practical details not found elsewhere, including the instruments used for surgical procedures, risk assessment, and complications
- Expert feedback by the authors in the *Pearls and Pitfalls* section
- A wealth of anatomic illustrations along with abundant intraoperative photographs and imaging studies.



Sally E Carty MD is Professor of Surgery at the University of Pittsburgh School of Medicine, and Chief of the Division of Endocrine Surgery, and Director of the Endocrine Surgery Fellowship Program at the University of Pittsburgh School of Medicine, Pittsburgh, Pennsylvania, USA. She is also Co-Director of the University of Pittsburgh Medical Center (UPMC)/University of Pittsburgh Cancer Institute (UPCI) Multidisciplinary Thyroid Center, and Past-President of the American Association of Endocrine Surgeons (AAES). As well as having an extensive clinical research program, Dr Carty has a busy academic endocrine surgery practice and is the Writing Group Chair developing the American Association of Endocrine Surgeons' Parathyroidectomy Guidelines.

Available at all medical bookstores
or buy online at www.jaypeebrothers.com

JAYPEE
JAYPEE BROTHERS
Medical Publishers (P) Ltd.
www.jaypeebrothers.com

Join us on facebook.com/JaypeeMedicalPublishers

Shelving Recommendations
ENDOCRINE SURGERY
GENERAL SURGERY

ISBN 978-93-5152-529-5
9 789351 525295