brothers.com, for detailed information on dermatology books, visit our website www.jaypeebrothers.com, for detailed information on dermatology books

JAYPEE

Color Atlas of Clinical Dermatology

Editor-in-Chief
Atif Hasnain Kazmi

Co-editors
Shahbaz Aman
Muhammad Nadeem



CONTENTS

1. INFECTIONS **1**

Bacterial Infections 2

- Folliculitis *3*
- Furunculosis *3*
- Ecthyma *5*
- Sycosis *5*
- Impetigo (Bullous and Nonbullous) *7*
- Cellulitis *7*
- Staphylococcal Scalded Skin Syndrome (SSSS) *9*
- Meningococcal Infections *9*

Viral Infections 10

- Herpes Simplex *11*
- Herpes Zoster (Shingles) *11*
- Warts (Verrucae) *13*
- Molluscum Contagiosum *15*

Fungal Infections 16

- Tinea Capitis *17*
- Tinea Corporis *21*
- Tinea Cruris *27*
- Tinea Manum *27*
- Tinea Pedis *27*
- Tinea Versicolor *31*
- Mycetoma *31*
- Chromoblastomycosis *31*

Candidal Infections 32

- Candidiasis *33*

Tuberculosis 34

- Cutaneous Tuberculosis *35*
- Lupus Vulgaris *35*
- Scrofuloderma *37*
- Tuberculous Gumma *39*
- Warty Tuberculosis (Tuberculosis Verrucosa Cutis) *41*
- Tuberculides *43*
- *Mycobacterium marinum* *43*

Sexually Transmitted Diseases 44

- Syphilis *45*
- Lymphogranuloma Venereum *49*

Leprosy 50

- Borderline Leprosy *51*
- Indeterminate Leprosy *51*
- Tuberculoid Leprosy *53*
- Lepromatous Leprosy *53*
- Complications *55*
- Prevention *55*
- Treatment *55*
- Treatment of Reactions *55*

Scabies 56

- Scabies *57*
- Pediculosis Capitis (Head Louse) *59*
- Papular Urticaria (Lichen Urticatus) *59*

Leishmaniasis 60

- Cutaneous Leishmaniasis *61*

2. BULLOUS DISORDERS **63**

- Pemphigus Vulgaris *65*
- Pemphigus Foliaceus *67*
- Bullous Pemphigoid *69*
- Linear Immunoglobulin A (IgA) Dermatosis *71*
- Shabbir's Syndrome *73*

3. DRUG REACTIONS **75**

- Erythema Multiforme *77*
- Toxic Epidermal Necrolysis *79*
- Fixed Drug Eruption *81*

4. CONNECTIVE TISSUE DISORDERS **83**

- Systemic Lupus Erythematosus (SLE) *85*
- Systemic Sclerosis *87*

- Linear Morphea *87*
- Dermatomyositis *87*

5. ICHTHYOSES 89
- Ichthyoses *91*
- Nonbullous Ichthyosiform Erythroderma *93*
- X-linked Recessive Ichthyosis *93*

6. KERATINIZATION DISORDERS 95
- Psoriasis *97*
- Onychogryphosis *99*
- Punctate Keratoderma *103*
- Pityriasis Rosea *103*
- Lichen Planus *105*

7. GENODERMATOSES 107
- Neurofibromatosis *109*
- Lipoid Proteinosis *109*
- Tuberous Sclerosis *111*
- Xeroderma Pigmentosum *113*

8. ECZEMAS 115
- Eczema *117*
- Contact Dermatitis *117*
- Patch Test *121*
- Atopic Dermatitis *123*
- Infective Eczema *123*
- Lichen Simplex *125*
- Stasis Eczema *125*

9. MISCELLANEOUS DISORDERS 127
- Purpura Fulminans *129*
- Urticaria (Hives) *129*
- Necrobiosis Lipoidica *129*
- Alopecia Areata (AA) *131*
- Basal Cell Carcinoma (BCC) *131*
- Calcinosis *133*
- Dermatitis Artefacta (DA) *133*
- Pyogenic Granuloma *133*
- Vitiligo *133*
- Pellagra *135*
- Cutis Verticis Gyrata *135*
- Granuloma Annulare *135*
- Infantile Hemangioma *137*
- Neonatal Acne *137*
- Porokeratosis of Mibelli *137*
- Port-wine Stain *139*
- Klippel-Trenaunay Syndrome (KTS) *139*
- Burn *139*
- Keratoacanthoma *141*
- Venous Ulcers *141*
- Lipodermatosclerosis *141*
- Keloid *143*
- Sebaceous Nevi *143*
- Xanthomas *143*
- Senile Comedones *145*
- Lentigines *145*
- Lichen Amyloidosis *145*
- Nodulocystic Acne *147*
- Epidermodysplasia Verruciformis (EDV) *147*
- Alkaptonuria *147*
- Exfoliative Dermatitis *147*

Index *149*

Chapter 3

DRUG REACTIONS

JAYPEE BROTHERS



Drug Reaction



Drug Reaction



Erythema Multiforme



Stevens-Johnson Syndrome

JAYPEE BROTHERS

Drug-induced cutaneous disorders frequently display a characteristic clinical morphology such as morbilliform exanthem, urticaria, hypersensitivity syndrome, pseudolymphoma, photosensitivity, pigmentary changes, acute generalized exanthematous pustulosis, lichenoid dermatitis, vasculitis, Stevens-Johnson syndrome, or fixed drug eruption (FDE).

ERYTHEMA MULTIFORME

Erythema multiforme (EM) is an acute, self-limited and sometimes recurring skin condition that is considered to be a type IV hypersensitivity reaction associated with certain infections, medications, and various other triggers. ***Erythema multiforme minor*** represents a localized eruption of the skin with minimal or no mucosal involvement. The papules evolve into pathognomonic target lesions or iris lesions that appear within a 72-hour period. More severe erosions of at least 2 mucosal surfaces are seen in ***erythema multiforme major*** and are characterized by hemorrhagic crusting of the lips (25%) and ulceration of the nonkeratinized mucosa. Occasionally, painful mucosal involvement may be extensive, with few or no skin lesions. Mucosal lesions usually heal without sequelae. The mucosal involvement in **Stevens-Johnson syndrome** is more severe and more extensive than that of erythema multiforme major. Generalized lymphadenopathy often accompanies erythema multiforme major. Erythema multiforme and Stevens-Johnson syndrome have different precipitating and clinical patterns and are generally recognized to be separate clinical entities. No specific laboratory tests are indicated to make the diagnosis of erythema multiforme (EM), which should be arrived at clinically. The most important treatment is usually symptomatic, including oral antihistamines, analgesics, local skin care, and soothing mouthwashes (e.g. oral rinsing with warm saline or a solution of diphenhydramine, xylocaine and kaopectate). Topical steroids may be considered. If a drug is suspected, it must be withdrawn as soon as possible. This includes all medications begun during the preceding 2 months. Infections should be appropriately treated after cultures. Prophylaxis for recurrence of herpes-associated erythema multiforme (HAEM) should be considered in patients with more than 5 attacks per year. Low-dose acyclovir (200 mg qid to 400 mg bid) can be effective for recurrence of HAEM, even in subclinical herpes simplex virus (HSV) infection. In children, 10 mg/kg/day may be considered.

JAYPEE BROTHERS



Stevens-Johnson Syndrome

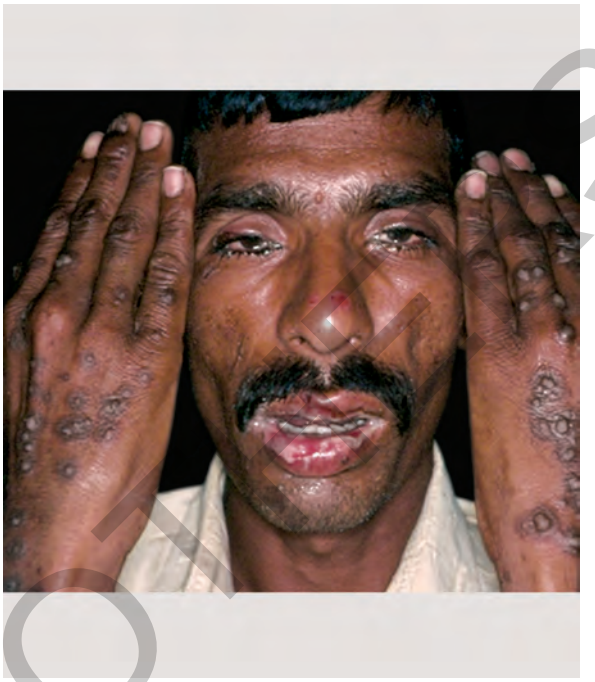

Stevens-Johnson Syndrome



Toxic Epidermal Necrolysis



Toxic Epidermal Necrolysis

JAYPEE BROTHERS

TOXIC EPIDERMAL NECROLYSIS

Toxic epidermal necrolysis (TEN), an acute disorder, is characterized by widespread erythematous macules and targetoid lesions; full-thickness epidermal necrosis, at least focally; and involvement of more than 30% of the cutaneous surface. Commonly, the mucous membranes are also involved. Nearly all cases of toxic epidermal necrolysis are induced by medications, and the mortality rate can approach 40%. Constitutional symptoms such as fever, cough, or sore throat, may appear 1–3 days prior to any cutaneous lesions. Patients may complain of a burning sensation in their eyes, photophobia, and a burning rash that begins symmetrically on the face and upper part of the torso. Delineation of a drug exposure timeline is essential, especially in the 1–3 weeks preceding the cutaneous eruption. The initial skin lesions of toxic epidermal necrolysis are poorly defined, erythematous macules with darker, purpuric centers. The lesions differ from classic target lesions of erythema multiforme by having only 2 zones of color: a central, dusky purpura or a central bulla, with a surrounding macular erythema. A classic target lesion has 3 zones of color: a central, dusky purpura or a central bulla; a surrounding pale, edematous zone; and an outer range of macular erythema.

Other findings in Stevens-Johnson syndrome/ toxic epidermal necrolysis include painful oral erosions causing severe crusting of the lips, increased salivation, and impaired alimentation. Lesions have been reported in the oropharynx, tracheobronchial tree, esophagus, gastrointestinal tract, genitalia, and anus. Involvement of the genitalia may lead to painful micturition. Intact expectorated cylindrical casts of bronchial epithelium have been reported; patients may develop a profuse, protein-rich diarrhea; internal involvement is not necessarily limited to patients with extensive cutaneous involvement; ocular lesions are especially problematic because they have a high risk of sequelae. Initially, the conjunctivae are erythematous and painful. The lids are often stuck together, with efforts to loosen them resulting in tearing of the epidermis. Pseudomembranous conjunctival erosions may form synechiae between the eyelids and the conjunctivae. Keratitis, corneal erosions, and a sicca-like syndrome may develop. Treatment of these dreaded conditions requires withdrawal of the offending drug, supportive therapy in a burn unit and pharmacologic therapy as outlined above for erythema multiforme major.

JAYPEE BROTHERS

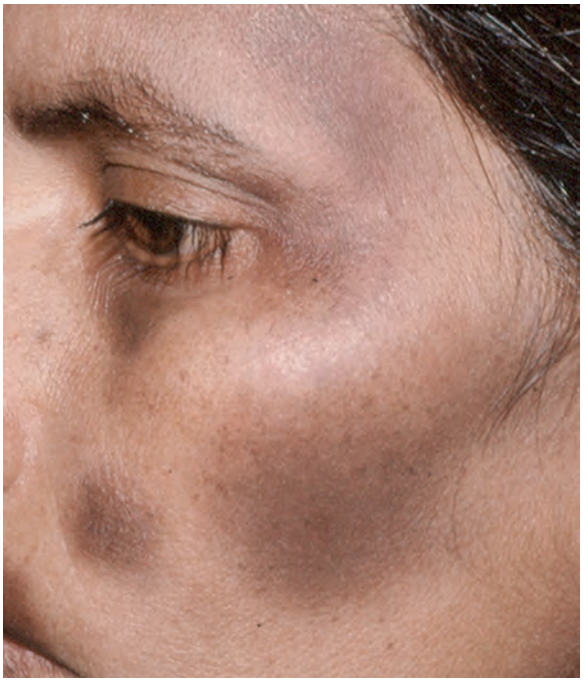

Fixed Drug Eruption



Fixed Drug Eruption



Fixed Drug Eruption

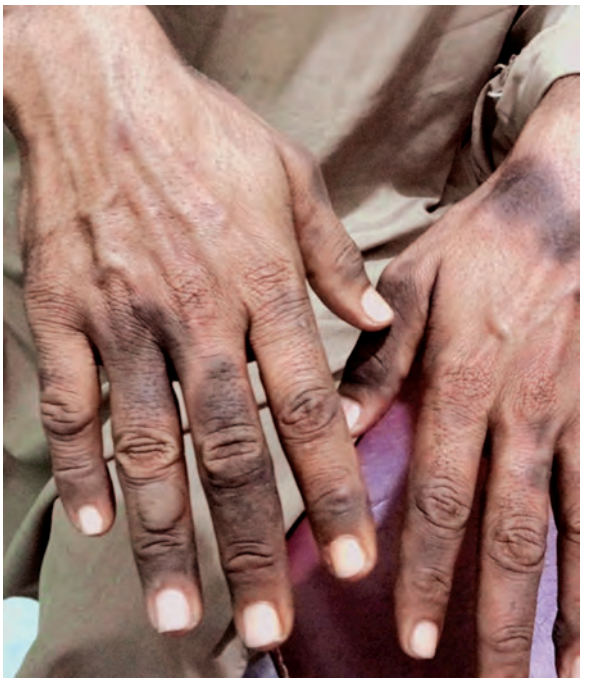

Fixed Drug Eruption

JAYPEE BROTHERS

FIXED DRUG ERUPTION

The term **Fixed Drug Eruption** describes the development of one or more annular or oval erythematous patches as a result of systemic exposure to a drug; these reactions normally resolve with hyperpigmentation and may recur at the same site with re-exposure to the drug.

Several variants of fixed drug eruption have been described, based on their clinical features and the distribution of the lesions. These include the pigmenting, generalized or multiple, linear, wandering, non-pigmenting, bullous, eczematous, urticarial, erythema dyschromicum perstans-like, vulvitis, oral, psoriasiform, cellulitis-like eruption. The initial eruption is often solitary and frequently located on the lip or genitalia. Rarely, the eruption may be intraoral.

Readministration of the medication poses the risk of increased pigmentation, size, and number of lesions. Individuals with darker pigmentation may develop post-inflammatory hypopigmented macules once the lesions have resolved. Diagnosis remains clinical as blood studies are not useful for the diagnosis of fixed drug eruption (FDE), although eosinophilia is common with drug eruptions. The main goal of treatment is to identify the causative agent and avoid it. **Treatment for fixed drug eruptions** otherwise is symptomatic. Systemic antihistamines and topical corticosteroids may be all that are required. In cases in which infection is suspected, antibiotics and proper wound care are advised. Desensitization to medications has been reported in the literature, but this should be avoided unless no substitutes exist.

JAYPEE BROTHERS

For detailed information on dermatology books, visit our website www.jaypeebrothers.com, for detailed information on dermatology books, visit our website

Color Atlas of Clinical Dermatology

This book aims to help the medical students and physicians in learning the subject of dermatology in a way he or she will encounter in daily practice. The book contains 260 colored photographs of various diseases. The color photographs illustrate the differences that lead to a diagnosis. A brief description has been given for an easy interpretation.



Atif Hasnain Kazmi MBBS (Pb) MCPS (Derm) MD (Pak) graduated from King Edward Medical College, Lahore, Pakistan, 1980. He did his MCPS (Dermatology) in 1982 and MD (Dermatology) in 1989. He has served in various medical institutions for the last many years and is currently working as Chairman/Head, Department of Dermatology; Dean, Faculty of Medicine and Allied, and Dean, Public Health, King Edward Medical University, Lahore, Pakistan. He is a well-recognized medical author in the country. There are 5 books to his credit on the subject of dermatology named—*MCQs in Dermatology, Derma Knowledge Series, Test Yourself, A Lecture Guide for Teachers and Students* and *Dermatology: Training and Evaluation.*



Shahbaz Aman MBBS (Pb) MCPS (Derm) FCPS (Derm) graduated from King Edward Medical College, Lahore, Pakistan, 1989. He did his MCPS (Dermatology) in 1993 and FCPS (Dermatology) in 1999. He has been serving in this institution for almost 22 years. He is currently working as Associate Professor, Department of Dermatology, King Edward Medical University, Lahore, Pakistan. He is a well-known medical writer and researcher in the country. He is author of 3 books on the subject of dermatology.



Muhammad Nadeem MBBS (Pb) FCPS (Derm) graduated from King Edward Medical College, Lahore, Pakistan, 1990. He did his FCPS (Dermatology) in 2000. He has served in this institution for almost 20 years. He is currently working as Assistant Professor, Department of Dermatology, King Edward Medical University, Lahore, Pakistan. He is a well-known medical writer and researcher in the country. He also holds 3 books to his credit written on the subject of dermatology.

Available at all medical bookstores or buy online at www.jaypeebrothers.com

JAYPEE BROTHERS
Medical Publishers (P) Ltd.
www.jaypeebrothers.com

Join us on facebook.com/JaypeeMedicalPublishers

Shelving Recommendation
DERMATOLOGY

ISBN 978-93-5152-627-8