dental books, visit our website **www.jaypeebrothers.com,** for detailed information on dental book

Sundeep S Bhagwath

MCQs on Oral Anatomy Oral Histology and Oral Physiology

MCQs

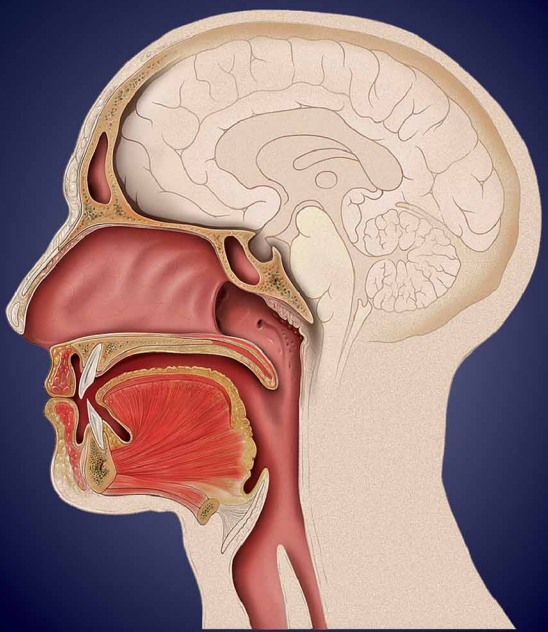

Foreword
NK Ahuja

Contents

Section I

Oral Anatomy 1–76

- Introduction to Oral Anatomy 3
- Deciduous Teeth 9
- Permanent Maxillary and Mandibular Incisors 15
- Permanent Maxillary and Mandibular Canines 21
- Permanent Maxillary and Mandibular Premolars 26
- Permanent Maxillary Molars 37
- Permanent Mandibular Molars 47
- TMJ, Muscles of Mastication and Movements of Mandible 54
- Occlusion 62
- Maxilla and Mandible 70

Section II

Oral Histology 77–162

- Development of Orofacial Complex and Development of Teeth 79
- Enamel 91
- Dentin-Pulp Complex 99
- Cementum 109
- Periodontal Ligaments 115
- Alveolar Bone 123
- Oral Mucous Membrane 129
- Salivary Glands 136
- Physiology of Eruption and Shedding of Teeth 142
- Maxillary and Paranasal Sinuses 150
- Histochemistry of Oral Tissues 154
- Processing of Soft and Hard Tissues 158

Section III

Oral Physiology 163–188

- Mastication 165
- Deglutition 170

- Mineralization in Hard Tissues 174
- Calcium and Phosphorous Metabolism 178
- Physiology of Taste and Speech 182
- Physiology of Pain 186

Section I

Oral Anatomy

1. Introduction to Oral Anatomy
2. Deciduous Teeth
3. Permanent Maxillary and Mandibular Incisors
4. Permanent Maxillary and Mandibular Canines
5. Permanent Maxillary and Mandibular Premolars
6. Permanent Maxillary Molars
7. Permanent Mandibular Molars
8. TMJ, Muscles of Mastication and Movements of Mandible
9. Occlusion
10. Maxilla and Mandible

Introduction to Oral Anatomy

Questions

1. **Which of the following class of permanent teeth is a non-succedaneous tooth?**
   a. Premolars
   b. Incisors
   c. Molars
   d. Canines

2. **The main bulk of a tooth is composed of:**
   a. Dentin
   b. Enamel
   c. Cementum
   d. Pulp

3. **Which amongst the following tissues of a tooth is purely ectodermal in origin?**
   a. Dentin
   b. Cementum
   c. Enamel
   d. Pulp

4. **Which amongst the following is not a correct designation for a surface of a tooth?**
   a. Distal
   b. Medial
   c. Mesial
   d. Buccal

5. **Mesial surface of which of the following teeth contact the mesial surface of their adjoining teeth?**
   a. Maxillary lateral incisor
   b. Mandibular lateral incisor
   c. Mandibular central incisor
   d. Maxillary canine

6. **Cusp of Carabelli is an example of a:**
   a. Cusp
   b. Tubercle
   c. Cingulum
   d. Lobe

7. **Transverse ridge is formed by the union of:**
   a. Marginal ridges
   b. Oblique ridges
   c. Buccal ridges
   d. Triangular ridges

8. **Oblique ridge is formed by the union of:**
   a. Triangular ridge of distobuccal cusp and distal ridge of mesiopalatal cusp

b. Triangular ridge of distopalatal cusp and distal ridge of mesiopalatal cusp
c. Triangular ridge of mesiobuccal cusp and distal ridge of mesiopalatal cusp
d. Triangular ridge of distobuccal cusp and triangular ridge of distopalatal cusp

9. Which amongst the following permanent teeth is the last to appear in the oral cavity?

a. Maxillary 2nd premolar
b. Maxillary canine
c. Mandibular 2nd molar
d. Maxillary 2nd molar

10. Which amongst the following class of permanent teeth is the first to calcify?

a. 1st molars
b. Central incisors
c. Lateral incisors
d. Canines

11. Which amongst the following statements is *true* regarding deciduous dentition?

a. They erupt usually in an anteroposterior sequence
b. They do not play any role in maintenance of space in the dental arches
c. Maxillary central incisor is usually the first deciduous tooth to erupt
d. Deciduous dentition phase lasts from $2^1/_2 - 6$ years of age

12. Which amongst the following represents correctly the deciduous mandibular left first molar in FDI notation?

a. 35
b. 75
c. L
d. 85

13. Which amongst the following morphological landmarks is not present on an incisor tooth?

a. Incisal ridge
b. Marginal ridge
c. Triangular ridge
d. Lingual fossa

14. Which amongst the following morphological landmarks is not present on a premolar tooth?

a. Transverse ridge
b. Oblique ridge
c. Triangular ridge
d. Marginal ridge

15. Which amongst the following morphological landmarks is present on a molar tooth?

a. Canine fossa
b. Lingual fossa
c. Cingulum
d. Central fossa

16. Deciduous teeth begin to calcify by about _____ months of fetal life.

a. 6
b. 5
c. 3
d. 4

17. The space within a tooth, containing the pulp tissue is called:

a. Pulp chamber
b. Pulp canal
c. Pulp core
d. Pulp cavity

18. The surfaces of teeth facing their adjoining teeth in the same dental arch are termed _____ surfaces.

a. Approximal
b. Proximal
c. Incisal
d. Occlusal

19. The four teeth that have their mesial surfaces contacting each other are:

a. Maxillary and mandibular incisors
b. Maxillary incisors and mandibular canines
c. Maxillary incisors and both maxillary and mandibular canines
d. Maxillary central incisors and mandibular lateral incisors

20. Which amongst the followings anatomical landmarks is not an elevated structure?

a. Cusp
b. Sulcus
c. Cingulum
d. Ridge

21. A _____ is an irregular depression or a concavity.

a. Fossa
b. Pit
c. Sulcus
d. Groove

22. All anterior teeth develop from _____ lobes.

a. 2
b. 4
c. 3
d. 5

23. The outlines of facial and lingual surfaces of all teeth may be visualized as:

a. Rhomboidal
b. Rectangular
c. Square
d. Trapezoidal

24. The fundamental form of which of the following teeth is described as rhomboidal?

a. Maxillary molars—Proximal aspects
b. Mandibular molars—Buccal and lingual aspects
c. Mandibular molars—Proximal aspects
d. Mandibular premolars—Buccal and lingual aspects

25. The primary function of teeth amongst the following is:

a. Prepare the food for swallowing
b. Maintaining the vertical dimension of face
c. Maintaining the facial esthetics
d. Allowing proper movements of mandible

Answers

1.c. Succedaneous teeth are those that erupt following the exfoliation of their deciduous predecessors like permanent premolars which erupt after the deciduous molars have shed. However permanent molars have no deciduous predecessors, hence the name non-succedaneous.

2.a. Enamel and cementum are thin mineralized tissues covering the crown and root respectively. Dentin is the tissue that forms the bulk of a tooth and also supports it internally.

3.c. Dentin, pulp, cementum, periodontal ligaments and alveolar bone are connective tissue structures derived from neuroectoderm (ectomesenchyme) by migration of neural crest cells into the head and neck region. Enamel however is derived from the ectoderm as the dental organ from which it originates is an ectodermal structure.

4.b. Buccal and mesial are the name given to tooth surfaces facing the cheek and the imaginary midline respectively while distal surface faces away from the midline. Medial surface is a medical term used to denote body surfaces that face the imaginary midline.

5.c. Maxillary and mandibular central incisors are the only

teeth whose mesial surfaces are in contact with each other.

6.b. Cusp, lobe and cingulum all contain enamel, dentin as well as pulp, while a tubercle is only an extra deposition of enamel. Cusp of Carabelli is one of its examples.

7.d. The word transverse pertains to structures lying across. In case of transverse ridge it is formed by union of the two triangular ridges lying across the central groove.

8.a. Oblique ridge is formed by union of triangular ridge of distobuccal cusp and distal cusp ridge of mesiopalatal cusp. It is a characteristic feature of maxillary molars. Occasionally it is crossed by a developmental groove partially or completely.

9.d. The maxillary 2nd molar erupts in the oral cavity by the age of 12–13 years. Other teeth erupt earlier.

10.a. The maxillary and mandibular first molars calcify at birth, whereas all other teeth calcify later.

11.a. Unlike the permanent dentition where the eruption sequence is highly variable, the deciduous teeth usually erupt in an anteroposterior sequence.

12.b. In the FDI notation, the first numerical figure stands for the side of the arch and the second numerical figure stands for the tooth number on one side of the arch. In deciduous dentition, the dental arches are numbered as 5, 6, 7 and 8 with 5 number given for right upper arch. Thus 75 stands for the deciduous left mandibular second molar.

13.c. Triangular ridges are seen on the occlusal aspect of posterior teeth where they form the prominence of the cusp.

14.b. Oblique ridges are seen only on the occlusal surfaces of maxillary permanent molars.

15.d. Canine fossa, lingual fossa and cingulum are morphological landmarks on all anterior teeth.

16.d. The deciduous teeth usually begin to calcify by around 4 months of intrauterine life and the first deciduous teeth erupt by 6 months of age.

17.d. Pulp cavity is the term designated to the space which houses the pulp tissue inside a tooth. Pulp chamber is the term used for space for pulp in the crown portion, while pulp canal is used for space inside the radicular portion of tooth. Pulp core is histological term used to denote the central part of pulp tissue.

18.b. Proximal surfaces are those surfaces of teeth that face each other. Proximal surfaces are two—Mesial and distal.

19.a. The deciduous and permanent maxillary and mandibular incisors are the only teeth in the dentition whose mesial surfaces are in contact with each other.

20.b. Sulcus is a valley-like structure between the ridges and cusps.

21.a. Examples of fossae are lingual fossa, triangular fossa, central fossa, etc.

22.b. All anterior teeth and most of the posterior develop from four developmental lobes namely, three buccal and one lingual lobe while the maxillary and mandibular first molars develop from five lobes, namely three buccal and two lingual.

23.d. In a trapezoid form, two surfaces are parallel while two are not. Thus in case of facial and lingual surfaces, the incisal/occlusal surfaces are considered as parallel surfaces while the two proximal surfaces are considered not parallel to each other.

24.c. When viewed from the proximal aspect, the mandibular posterior teeth show a pronounced lingual inclination and when so visualized, all the four lines, i.e. the buccal and lingual outlines and the occlusal and cervical outlines are all parallel giving the tooth a rhomboidal outline.

25.a. All other functions mentioned are important but considered auxiliary. Teeth in lower forms of life are primarily meant for prehension, while in higher forms of life are meant primarily for preparing the food for swallowing.

Deciduous Teeth

Questions

1. **The deciduous tooth that most closely resembles permanent premolars is:**
   a. Maxillary 1st molar
   b. Maxillary 2nd molar
   c. Mandibular 2nd molar
   d. Mandibular 1st molar

2. **The crown of deciduous _____ does not resemble any other tooth of permanent dentition.**
   a. Maxillary 1st molar
   b. Maxillary 2nd molar
   c. Mandibular 2nd molar
   d. Mandibular 1st molar

3. **The thickness of dentin between pulp chamber and enamel of deciduous teeth is the least in:**
   a. Maxillary 2nd molar
   b. Mandibular 2nd molar
   c. Maxillary 1st molar
   d. Mandibular 1st molar

4. **Each tooth of deciduous dentition occludes with two deciduous teeth of the opposing arch with the exception of:**
   a. Mandibular 2nd molar
   b. Maxillary 1st molar
   c. Maxillary 2nd molar
   d. Mandibular 1st molar

5. **The roots of deciduous dentition are completed by the age of _____ years.**
   a. 2
   b. $2^1/_2$
   c. $1^1/_2$
   d. 3

6. **The first permanent molar erupts distal to:**
   a. Premolars
   b. Deciduous 2nd molar
   c. Deciduous canines
   d. Deciduous 1st molars

7. The crown form of which deciduous tooth is unlike that of any of the permanent teeth?

a. Mandibular 2nd molar
b. Mandibular 1st molar
c. Maxillary 1st molar
d. Maxillary 2nd molar

8. As compared to permanent teeth, the deciduous teeth have more prominent _____ ridges.

a. Cervical
b. Incisal
c. Buccal cervical
d. Lingual

9. The deciduous maxillary central incisor erupts by the age of _____ months.

a. 12 –14
b. 6 – 8
c. 4 – 6
d. 8 – 9

10. Which one of the following statements regarding deciduous dentition is *false*?

a. Roots of deciduous teeth flare more than that of permanent teeth
b. Roots of deciduous teeth are more slender than that of permanent teeth
c. Cervical ridges of deciduous teeth are prominent than that of permanent teeth
d. Enamel of deciduous teeth is relatively thicker than that of permanent teeth

11. Viewing from the incisal surface, the shape of the deciduous maxillary canine is essentially _____ shaped.

a. Pentagon
b. Trapezoid
c. Diamond
d. Square

12. The deciduous mandibular lateral incisor is larger than deciduous mandibular central incisor in all dimensions except:

a. Labiolingual
b. Mesiodistal
c. Cervical
d. Incisocervical

13. The incisal ridge of deciduous mandibular lateral incisor slopes:

a. Mesially
b. Distally
c. Labially
d. Lingually

14. The incisal ridge of deciduous mandibular lateral incisor slopes distally so that it's distal contact area:

a. Contacts the distal contact area of mandibular canine
b. Contacts the mesial contact area of mandibular canine
c. Contacts the lingual fossa of maxillary canine
d. Contacts the mesial marginal ridge of maxillary canine

15. Which of the following ridges is not present on the lingual surface of deciduous maxillary canines?

a. Distal marginal
b. Mesial marginal
c. Cervical
d. Incisal

16. Which one of the following statements regarding the maxillary canine is incorrect?

a. It erupts by the age of 16–22 months
b. Its mesial and distal contact areas are at different levels
c. Its root inclines distally
d. Viewed from incisal aspect, crown appears diamond shaped

17. The widest measurement of the crown of deciduous maxillary first molar is at:

a. Mesial and distal contact areas
b. Incisocervically
c. Labiolingually
d. Cervical third region

18. Which of the following structures is not seen on the buccal surface of deciduous maxillary first molar?

a. Buccal developmental groove
b. Buccal cervical ridge
c. Mesiobuccal cusp
d. Distopalatal cusp

19. Which of the following statements regarding the roots of deciduous molars is incorrect?

a. They are longer and slender than that of permanent molars
b. They are spread more widely than permanent molars
c. Their root trunks are longer than that of permanent molars
d. There is no root trunk located on deciduous molars

20. Which cusp is the largest cusp on the deciduous maxillary 1st molar?

a. Mesiobuccal
b. Distobuccal
c. Mesiopalatal
d. Distopalatal

21. Which of the roots of deciduous maxillary 1st molars has the largest size?

a. All roots are of equal size
b. Mesiobuccal
c. Palatal
d. Distobuccal

22. The crown outline of deciduous maxillary 2nd molar when viewed occlusally resembles a:

a. Rhombus
b. Pentagon
c. Hexagon
d. Trapezium

23. Which of the following structures is not present on the occlusal surface of deciduous maxillary 2nd molar?

a. Central groove
b. Buccal pit
c. Mesial triangular fossa
d. Central fossa

24. The occlusal aspect of the deciduous mandibular 2nd molar resembles a:

a. Square
b. Pentagon
c. Rhombus
d. Rectangle

25. The triangular ridges of each of the cusps of deciduous mandibular second molar culminate in a:

a. Central developmental groove
b. Central pit
c. Central developmental fossa
d. Mesial triangular fossa

Answers

1.a. This is so primarily because of the fact that the deciduous maxillary molars show pronounced labiolingual tapering when viewed from the occlusal aspect.

2.d. Normally all molars have four cusps with well-defined grooves separating them on the occlusal surface. However, in case of deciduous mandibular 1st molars, the two buccal cusps are not very well-demarcated, thus giving the crown an atypical appearance.

3.b. This is due to the fact this tooth has very large pulp chamber with very thin enamel and dentin walls.

4.c. The mandibular teeth in both deciduous and permanent dentition are always located more mesially compared to their maxillary counterparts. Thus, the deciduous maxillary 2nd molars can occlude only with the deciduous mandibular 2nd molar.

5.d. In most teeth deciduous or permanent, root development lags behind the development of crown by around $1–1^{1}/_{2}$ years. The last decidous tooth erupts by around 2 years of age and the root is completed by 3 years.

6.b. All the permanent molars are also called non-succedaneous teeth which means that this class of teeth have no deciduous predecessors. They develop from the posterior extension of the dental lamina and erupt distal to the deciduous molars.

7.b. The deciduous mandibular 1st molar has a unique shape and does not resemble any other tooth, deciduous or permanent. It has two large buccal cusps which cannot be differentiated clearly and two smaller but well-delineated lingual cusps.

8.c. The buccal cervical ridges are sometimes so prominent that they are referred to as buccal cingulum.

9.d. Deciduous teeth usually but not always erupt in an anteroposterior sequence and the maxillary central incisor erupts by 8–9 months of age.

10.d. Enamel in deciduous teeth is thinner, more opaque and whiter, thus imparting a white hue to the crowns of deciduous teeth compared to the permanent teeth.

11.c. The deciduous canine when viewed from the incisal aspect appears diamond-shaped because of the prominent buccal ridge and the prominent cingulum and a wide mesiodistal width of the crown.

12.a. The deciduous mandibular lateral incisor is smaller in labiolingual dimension compared to mandibular central incisor.

for detailed information on dental books, visit our website **www.jaypeebrothers.com,** for detailed

MCQs on

Oral Anatomy, Oral Histology and Oral Physiology

This book purports to orient the undergraduate students towards attempting the multiple choice questions (MCQs) that are increasingly becoming a part of both—regular examinations and entrance examinations—for various postgraduate courses in dentistry. Different levels of questions have been framed on the subjects of Oral Anatomy, Oral Histology, and Oral Physiology so that students of all types of academic capabilities can be benefited from this book. Care has been taken by the author to frame the questions in clear and lucid language so that there is no ambiguity in understanding the questions. Explanatory answers have been provided so that the students can easily review the entire chapter easily.



Sundeep S Bhagwath BDS MDS is presently working as a Professor in the Department of Oral Pathology, and Head of the Department of Basic Sciences, College of Dentistry, University of Ha'il, Kingdom of Saudi Arabia. He is involved in teaching the subjects of Oral Pathology, Oral Anatomy and Oral Histology for the past 13 years. He has been appointed as examiner of undergraduate as well as postgraduate examinations in different universities.

He has already published the book *Oral Anatomy, Oral Histology, Embryology, Physiology and Occlusion*. Besides, he has published papers in several national and international journals.

Available at all medical bookstores
or buy online at www.jaypeebrothers.com

JAYPEE BROTHERS
Medical Publishers (P) Ltd.
www.jaypeebrothers.com

Join us on facebook.com/JaypeeMedicalPublishers

ISBN 978-93-5152-630-8

9 789351 526308