rthopedic books, visit our website www.jaypeebrothers.com, for detailed information on orthopedic book

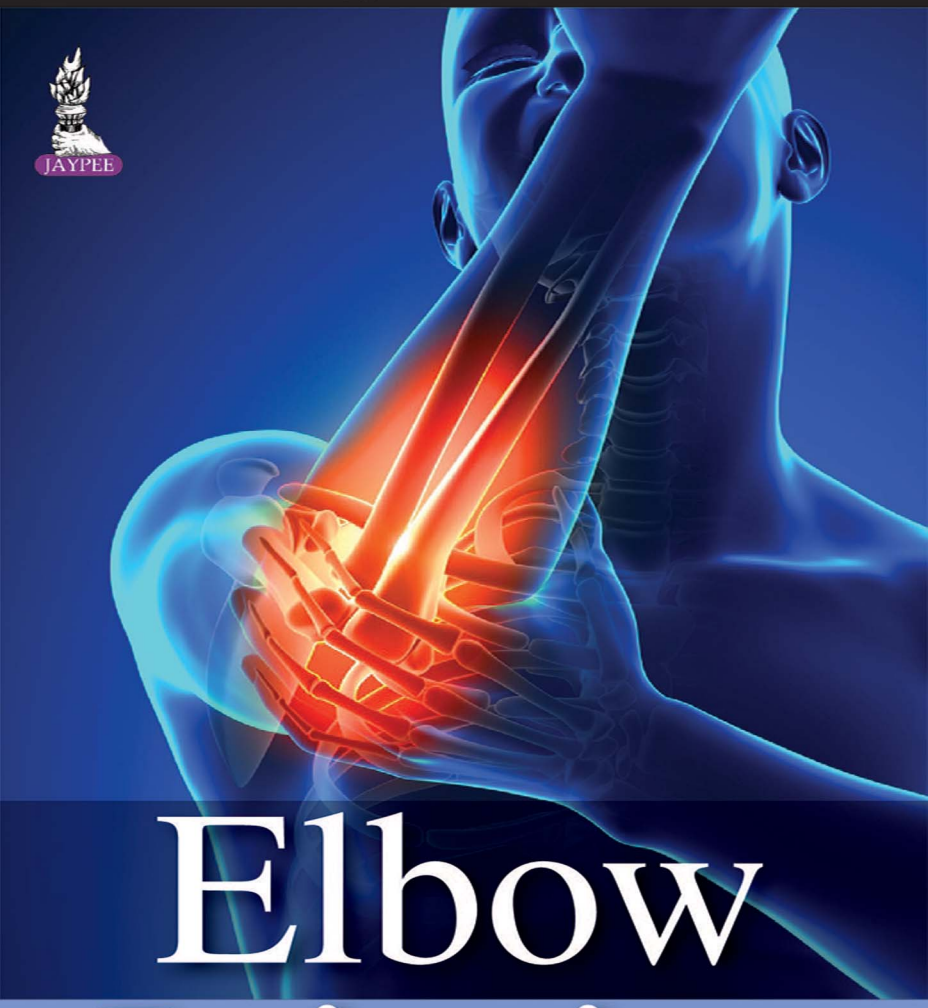

Elbow Injuries

Sudhir Babhulkar

Contents

1. Introduction, Anatomy and Biomechanics 1
Anatomy of Elbow 2
Functional Anatomy 3
Elbow Biomechanics 10

2. Arthroscopy and Soft Tissue Involvement around Elbow 18
Injuries around Elbow Including Athletic Injury of Elbow 19

3. Tennis Elbow—Lateral Epicondylitis 20

4. Medial Epicondylitis—Golfer's Elbow 25

5. Pronator Teres Syndrome (Anterior Elbow Pain) 27
Treatment 30

6. Anterior Interosseous Syndrome 31
Differential Diagnosis 34

7. Posteromedial Elbow Impingement 36
Clinical Findings 36
Diagnostic Tests: X-ray 36
Treatment 37
Differential Diagnosis 37

8. Valgus Extension Overload Syndrome 38

9. Triceps Tendon Rupture 40

10. Biceps Tendon Rupture 44
Biceps Tendon Tear at the Shoulder (Long Head of Biceps) 44
Biceps Tendon Tear at the Elbow—Distal Biceps Rupture 46

11. Fractures of Distal Humerus in Adults 54
Surgical Anatomy of Distal Humerus 55
Radiographic Evaluation 58
Classification 58
Conservative or Surgical Treatment 60
Role of Primary Total Elbow Replacement 80

12. Fractures of Capitellum and Trochlea 96
Anatomy 97
Fracture Classification 98
Clinical Examination 101
Radiology 103
Natural History 104

Treatment 104
Postoperative Management 113
Complications 114

13. Fractures of Olecranon 117
Clinical Features 118
Anatomy 119
Classification 120
Treatment 122
Postoperative Rehabilitation 140
Complications 140

14. Coronoid Fractures 147
Anatomy 147
Classification 149
Mechanism of Injury 151
Treatment 154
Postoperative Care 161
Discussion 162

15. Radial Head Fractures 173
Anatomy 173
Biomechanics of Radial Head 176
Classification 179
Role of Coronoid Process 182
Treatment 182
Open Reduction and Internal Fixation of Radial Head 184
Radial Head Arthroplasty 191
Postoperative Care 194

16. Ipsilateral Fracture of Humerus with Forearm Fractures in Adults (Floating Elbow in Adults) 200
Discussion 201

17. Elbow Dislocation and Instability 207
Components that Contribute to Stability of the Elbow 207
Acute Elbow Dislocation 210
Complex Elbow Dislocation 220
Complications of Elbow Dislocation 225
Open Reduction and Arthrolysis 232
Elbow Instability 238
Rehabilitation 260

18. Bony Injuries around Elbow in Children 264

19. Supracondylar Fractures of the Humerus in Children 266
Physical Examination 266
Radiographic Anatomy 268
Classification 273
Transphyseal Fractures of the Distal Humerus 278

Percutaneous Pinning 280
Pink Pulseless Hand 285

20. Fractures of the Lateral Humeral Condyle 291
Mechanism of Injury 291
Clinical Presentation 292
Imaging (Radiography) 294
Classification 296
Management 300
Growth Disturbance 311
Tardy Ulnar Nerve Palsy 314
Pearls 314
Pitfalls 314

21. Medial Condyle Fracture of Humerus 317
Classification 318
Anatomy 321
Mechanism of Injury 322
Pathophysiology 324
Presentation and Diagnosis 325
Management 326

22. Medial Epicondylar Apophysis Fracture in Children 329
Anatomy 329
Mechanism of Injury 331
Classification 331
Diagnosis 335
Imaging 336
Management 338
Surgical Technique 340
Complications 340

23. Distal Humeral Physeal Injuries in Children 345
Carrying Angle 345
Ossification of Distal Humerus 345
Pearls: Pediatric Distal Humeral Injuries 346

24. Fractures Involving Entire Distal Humeral Physis 347
Classification 347
Treatment 347
T - Condylar Fracture 348
Pearls: Pediatric Distal Humeral Injuries 349

25. Malunited Supracondylar Fracture of Humerus (Cubitus Varus and Valgus Deformity) 350
Prevention 351
Criteria for Closed Reduction 351
Treatment of Cubitus Varus Deformity 351
Complications 355

26. Nonunion Lateral Humeral Condyle Fracture **357**

27. Olecranon Fractures in Children **360**

28. Fractures of Radial Head-Neck in Children **361**
Radiographic Evaluation 361
Classification 361
Management 364
Percutaneous Reduction 364
Intramedullary Pin Reduction 366
Open Reduction 367
Complications 368

29. Ipsilateral Fracture of Distal Humerus with Forearm Fractures in Children (Floating Elbow in Children) **370**
Discussion 372

30. Panner's Disease and Osteochondritis Dissecans of the Capitellum **376**
Panner's Disease 376
Osteochondritis Dissecans 379

Index *387*

Chapter 4

Medial Epicondylitis—Golfer's Elbow

Golfer's elbow—medial epicondylitis is less common than tennis elbow. It is a type of tendonitis affecting common flexor-flexor pronator muscle group.[1,2] It is often seen in athletes. Patient has pain on the medial aspect of elbow, over the common origin of flexors of forearm. There is localized tenderness over the medial epicondyle, slightly distal and anteriorly. The grip may be weak and patient has pain on resisted pronation and wrist flexion.

All of the flexors of the fingers and the pronators of the forearm insert at the medial epicondyle of the ulna to include: Pronator teres, flexor carpi radialis, flexor carpi ulnaris, flexor digitorum superficialis, and palmaris longus, making this the most common elbow injury for athletes, whose sport is very grip intensive. The pain is normally caused due to stress on the tendon as a result of the large amount of grip exerted by the digits and torsion of the wrist, which is caused by the use and action of the cluster of muscles on the condyle of the ulna.

Golfer's elbow, also known as medial epicondylitis is characterized by pain and tenderness on the medial epicondyle of elbow. Sometimes the pain extends along the medial aspect of forearm. Patient might complain of stiffness or weakness in the wrist and hand. Overusing the muscles in the forearm that allow you to grip, rotate your arm, and flex your wrist usually causes golfer's elbow. Repetitive flexing, gripping, or swinging can cause pulls or tiny tears in the tendons. Usually, pain appears gradually and gets worse after flexing the wrist and repetitive movements of wrist and hand. Physical examination will reveal only the tenderness over medial epicondyle and origin of common flexors of forearm.[3,4] Patient has almost full range of movements and X-ray will be normal which rules out other causes of pain at the medial aspect of elbow. Rarely MRI may be performed.

The treatment should begin early so as to return to usual activities. Rest to the elbow and avoiding repetitive activities on hold until the pain is abolished. If you return to activity too soon, the condition is likely to worsen.

JAYPEE BROTHERS

Apply ice packs to your elbow for 15 to 20 minutes at a time, three to four times a day for several days. To protect your skin, wrap the ice packs in a thin towel. Massage the medial aspect of elbow with ice for 5 minutes at a time, two to three times a day.

NSAIDs and analgesics should be given for 2–3 weeks. Stretch and strengthen the affected area. Reduce the load on your elbow. Wrap your elbow with an elastic bandage or use a forearm strap. In addition remember to maintain a rigid wrist position during all lifting activities.

If NSAIDs do not work, one may recommend a cortisone injection to reduce pain and swelling. These injections are usually given 2–3 times with weekly interval, which may provide only short-term pain relief.

Gradually return to your usual activities. When patient is no longer in pain, practice the arm motions of your sport or activity. Review the sport activities and make adjustments if needed.

Surgery is seldom necessary. But if your signs and symptoms do not respond to conservative treatment in 6 to 12 months, surgery may be an option.

REFERENCES

1. Wilson JJ, Best TM. Common overuse tendon problems: A review and recommendations for treatment. Am Fam Physician. 2005;72(5):811-8.
2. Matthews, P. Acute Classification in tennis and golfer's elbow. Rheumatology. 1980;9(3):151-3.
3. Chen J, Wang A, Xu J, Zheng M. In chronic lateral epicondylitis, apoptosis and autophagic cell death occur in the extensor carpi radialis brevis tendon. J Shoulder Elbow Surg. 2010;19(3):355-62.
4. Gibbs, SJ, Kenneth SD. Medial Epicondylitis. Medicine. 2009.

JAYPEE BROTHERS

for detailed information on orthopedic books, visit our website www.jaypeebrothers.com, for detailed info

Elbow Injuries

Salient Features

- Describes in detail all injuries of elbow, which include bony, joint and soft tissue injuries in adults and children.
- Explains all injuries of distal humerus and proximal radius and ulna in adults and children with different methods of management.
- Enumerates all minor details of elbow injuries out of personal experience of the author of over 4 decades.
- Contains multiple pictorial demonstrations.
- Serves as a guide on elbow injuries to the practicing orthopedic surgeons.



Sudhir Babhulkar is the Director, Sushrut Hospital, Research Centre & Post Graduate Institute of Orthopedics, Nagpur, Maharashtra, India; and Professor Emeritus, Department of Orthopedics, Indira Gandhi Medical College and Mayo General Hospital, Nagpur.

He is the first qualified orthopedic surgeon to start an orthopedic and accident clinic in Nagpur, in the year 1970. His surgical skills and dedication to his profession have earned him a nationwide reputation. His keen interest in academics has brought him an international reputation. He has been a postgraduate teacher since 1979, a postgraduate examiner in many universities in India, and a Diplomate of National Board, New Delhi, India.

He has over 150 publications in national and international journals and over 500 research papers to his credit. He has held many prestigious posts including President of Indian Orthopedic Association; President of Trauma Society of India; Chairman, Bone and Joint Decade, India. He has also been awarded PhD and DSc in Orthopedics for his outstanding work in Sickle Cell Disease.

Available at all medical bookstores
or buy online at www.jaypeebrothers.com

JAYPEE BROTHERS
Medical Publishers (P) Ltd.
www.jaypeebrothers.com

Join us on facebook.com/JaypeeMedicalPublishers

Shelving Recommendation
ORTHOPEDICS

ISBN 978-93-5152-635-3
9 789351 526353