our website www.jaypeebrothers.com, for detailed information on cardiology books, visit our website www.jaypeebrothers.com

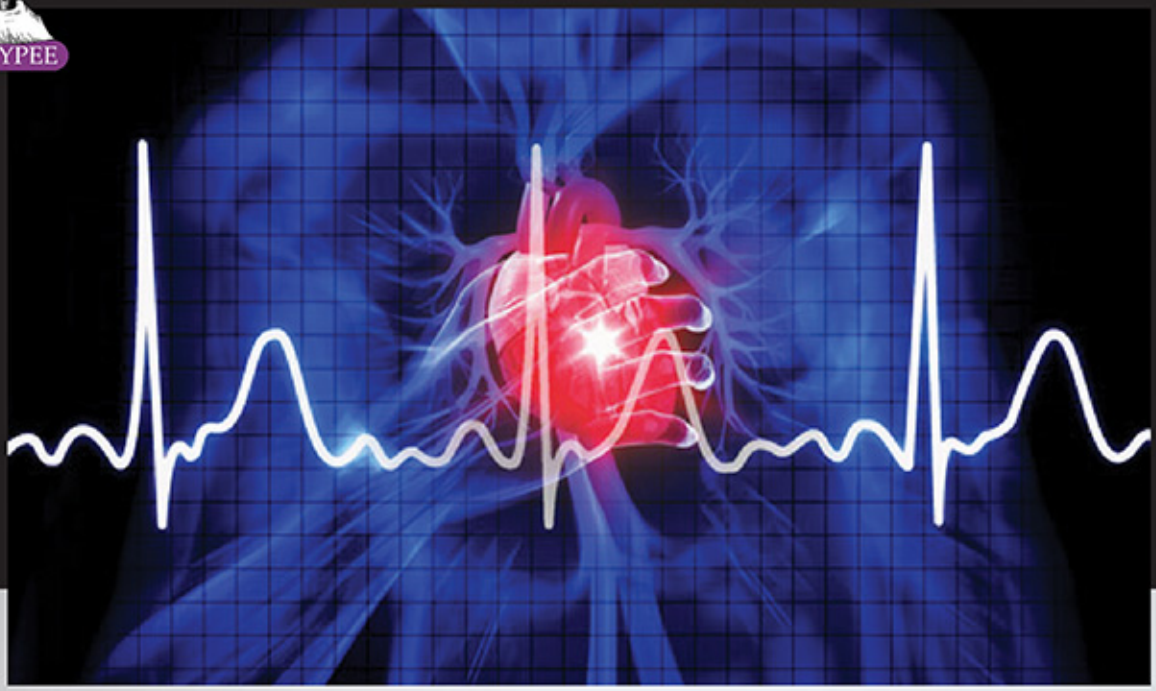

CLINICAL METHODS IN CARDIOLOGY

RS Sharma

CONTENTS

1. History Taking **1**

- Subclinical Disease; Asymptomatic Patients *1*
- Dyspnea *4*
- Chest Pain *7*
- Palpitations *10*
- Dizziness and Syncope *10*
- Other Symptoms of Heart Disease *11*
- Functional and Therapeutic Classification of Heart Disease *13*

2. Physical Examination **15**

- Approach to the Physical Examination *15*
- Examination of Organs and Regions Other than the Heart *21*
- Inspection *34*
- Integration of Cardiac Physical Findings *49*
- Renal Artery Stenosis *67*
- Cardiac Failure *67*
- Clinical Findings *69*

3. Congenital Heart Disease **77**

- Surgically Modified Disease *77*
- Classification of Congenital Heart Disease *77*
- Atrial Septal Defect *78*
- Pulmonary Stenosis *81*
- Ventricular Septal Defect *85*
- Patent Ductus Arteriosus *87*
- Eisenmenger's Syndrome *88*
- Coarctation of the Aorta *90*
- Clinical Findings *91*
- Differential Diagnosis *91*

4. Valvular Heart Disease **93**

- Classification of Valvular Disease *93*
- Mitral Valve Disease *94*
- Mitral Stenosis *95*
- Mixed Mitral Stenosis and Incompetence *100*
- Mitral Incompetence *102*
- Aortic Valve Disease *104*
- Multiple Valve Involvement *117*
- Modified Valvular Heart Disease Secondary to Surgery/Balloon Mitral Valvotomy *119*
- Patients with Artificial Valves *120*

5. Infective Endocarditis **122**
- Changing Characteristics of Endocarditis *122*

6. Myocardial Disease **129**
- Rheumatic Fever *130*
- Chronic Cardiomyopathies: Congestive Idiopathic or Primary Cardiomyopathy *133*
- Hypertrophic Obstructive Cardiomyopathy *134*
- Restrictive Cardiomyopathy *136*

7. Pericarditis **137**
- Differential Diagnosis *137*
- Complications *137*
- Cardiac Tamponade *137*
- Pericardial Constriction *139*

8. Pulmonary Heart Diseases **141**
- Right Heart Failure Secondary to Chronic Lung Disease *143*
- Differentiation of Heart Disease and Lung Disease *145*

9. Some Other Clinically Important Cardiovascular Conditions **147**
- Cardiac Tumors *147*
- Abnormal Position of the Heart *150*
- Heart Disease in Pregnancy *151*

10. Thyrotoxic Heart Disease and Some Other Heart Diseases of Clinical Importance **156**
- Myxedema and Myxedema Heart *157*

11. Cardiac Arrhythmias **160**
- Atrial Fibrillation and Atrial Flutter *163*

12. Frequently Asked Questions (FAQs) in Bedside Clinical Examination and Viva Voce **167**
- History Taking *167*
- Physical Examination *168*

Index *173*

Chapter 4

Valvular Heart Disease

JAYPEE BROTHERS

Both undergraduate and postgraduate students invariably get cases of valvular heart disease (Rheumatic mostly but sometimes nonrheumatic also) Valvular heart disease presents some of the most important diagnostic problems in adult cardiology. Because of the vast range in types of lesions, valvular involvement, causes, and associated conditions, certain broad generalizations about valvular heart disease are inevitable.

CLASSIFICATION OF VALVULAR DISEASE

Valvular disease can be classified according to the following factors :

A. **Lesions:** Valvular disease can be divided into three categories on the basis of the type of lesion: stenosis, incompetence, and mixed stenosis and incompetence (regurgitation, insufficiency).
B. **Valvular Involvement:** Lesions involving the mitral and aortic valves are more common than tricuspid and pulmonary valve lesions in adult valvular disease.
C. **Causes:** Rheumatic endocarditis is the most important cause of valvular heart disease; degenerative disorders and congenital disease are other prominent causes.

Associated lesions such as past or present myocardial damage due to rheumatic carditis, or degenerative changes due to hypertension, atherosclerosis. Cardiomyopathy or abnormal wear and tear secondary to the valvular lesion will affect the classification.

Variation in clinical features: Because the course of chronic valvular disease often lasts for 20–30 years, it is much easier to gain experience based on several patients seen at different stages of the disease that it is to follow a single patient progressively through the different stages. Although it is relatively easy to see that disease has progressed in a given patient, the nature, timing, and rate of progress are difficult to determine. The natural progress of disease is also modified by treatment, and it is in valvular heart disease that the iatrogenic modification of cardiac disease is seen most clearly.

Acute Valvular Lesions: The clinical picture in patients with acute valvular lesions is different from that seen in classic chronic lesions associated with rheumatic fever. Pure valvular incompetence rather than stenosis is an example of the classic acute lesion. It has become increasingly important to distinguish the clinical features of an acute lesion, which develops over a period of minutes, days, or weeks-from the more readily recognized effects of chronic valvular lesions. Acute lesions are relatively rate (10%), and their importance depends on their severity. If the patient survives, the onset of an acute lesion, compensatory responses to increased cardiac load occur, leading to hypertrophy or dilatation of the appropriate chambers. Such a lesion

becomes chronic in about 1 year. In acute severe valvular lesions, the heart tolerates the extra load poorly. In acute aortic and mitral incompetence, pulmonary congestion and edema tend to so dominate the clinical picture that separate clinical features must be distinguished. The lungs carry the brunt of the disease, and some of the cardiac manifestations associated with chronic valvular lesions may not appear for several weeks.

MITRAL VALVE DISEASE

Mitral valve disease is the commonest from of valvular heart disease and accounts for more than half of cases with significant valvular lesions. Rheumatic heart disease is the commonest cause of mitral valve disease in particular and all valve disease in general. Acute clinical manifestations of rheumatic fever are detected in only about half of patients who subsequently develop mitral valve disease. The presence or absence of a history or rheumatic fever makes no difference in the course of the disease or in its clinical, hemodynamic, or pathologic finding. In patients who have no history of rheumatic fever, it is generally assumed that a subclinical attack without over signs of cardiac or joints involvement was responsible for the valvular lesion.

Classification of Mitral Valve Disease

Mitral valve disease has been classified somewhat arbitrarily into three types: mitral stenosis, mixed mitral stenosis and incompetence, and mitral incompetence.

It is difficult to distinguish between the different lesions in some cases, and in some patients, the disease can on occasion shift from one category to another. The classification depends primarily on the physical finding rather than the history, although the history and course of the disease vary in the different lesions.

In mitral stenosis, the predominant lesion is obstruction to the diastolic flow of blood through the mitral valve. The hallmark of the lesion is the presence of a presystolic (atrial systolic) murmur indicating that mitral flow is still continuing when atrial contraction occurs and that the patient is still in sinus rhythm. Atrial fibrillation commonly accompanies mitral valve disease and occurs in all types of lesions. In mitral stenosis, however, it is seldom present when the patient first presents with symptoms. Predominant obstruction to mitral valve flow during diastole is such a potent cause of symptoms that patients with this lesion develop dyspnea early is adult life in all but the mildest cases.

In *mixed mitral stenosis and incompetence*, there is both obstruction to forward flow and leakage of blood from the left ventricle into the left atrium during systole. Mitral stenosis and incompetence have traditionally been thought to be mutually exclusive lesions that cannot coexist except in a mild form. The rationale for this category of mixed stenosis and incompetence may alter the natural history of mitral valve disease. In relieving mitral stenosis, the surgeon non-infrequently renders the valve incompetent. Long-term follow-up of patients who have had mitral valvotomy shows that the operation is usually only palliative and that symptoms recur. Although some patients show evidence of restenosis, the majority present a clinical picture of mixed stenosis and incompetence, often with a fixed, calcified valve that neither opens nor shuts completely. The hallmark of the lesion is the absence of a presystolic murmur, which indicates that the obstruction is not severe enough to hinder forward flow at the end of diastole. It also implies that the patient is in atrial fibrillation. Patients with mixed mitral stenosis and incompetence characteristically develop symptoms for the first time when their cardiac rhythm changes sinus to atrial fibrillation. This usually takes place at about age 40. This course also occurs in some patients who have not had a previous mitral valvotomy.

Mitral incompetence differs from other kind of mitral valve disease in that it has several forms and has a variety of causes. It is here

JAYPEE BROTHERS

divided into the following categories: (1) acute mitral incompetence and (2) chronic mitral incompetence (hemodynamically insignificant and significant). The hallmark of mitral incompetence is the presence of a systolic murmur without any significant diastolic murmur to indicate the presence of obstruction to the diastolic forward flow across the valve. In acute lesions the onset is abrupt and caused by acute disruption of the mitral valve due to rupture or stretching of the chordae tendineae, weakening of the papillary muscles, or perforation of a valve cusp. In hemodynamically insignificant chromic lesions, the characteristic feature is a late systolic murmur with or without a midsystolic ejection click. The murmur is associated with a specific clinical picture (click-murmur syndrome) and a course that may lead in time to either a significant chronic lesion or an acute exacerbation. In chromic hemodynamically significant chronic lesions the characteristic feature is a late systolic murmur with or without a midystolic ejection click. The murmur is associated with a specific clinical picture (click-murmur syndrome) and a course that may lead in time to either a significant chronic lesion or an acute exacerbation. In chronic hemodynamically significant mitral incompetence there is a pansystolic murmur with a third heart sound and no diastolic murmur. The lesion is well tolerated, and even the onset of atrial fibrillation does not cause serious symptoms. Left ventricular stroke volume is increased in mitral incompetence, and the way the ventricle responds to the extra "flow" work determines the course of the disease.

Cause of Mitral Valve Disease

Rheumatic heart disease is, in effect, the sole cause of all mitral valve disease except mitral incompetence. Even in cases of mitral incompetence, however, rheumatic fever probably accounts for half of chronic lesions. Rheumatic heart disease is much more common in women than in men; the female: male ratio of 9:1 in mitral stenosis falls to 3:1 in mixed mitral stenosis and incompetence and 1:1 in mitral stenosis or mixed stenosis and incompetence are congenital heart disease and hypertrophic cardiomyopathy. Congenital heart disease is rare, being encountered in less than 1% of adult cases, and it is debatable whether hypertrophic cardiomyopathy should be considered as a form of mitral disease or as part of the differential diagnosis.

MITRAL STENOSIS

In mitral stenosis, rheumatic endocarditis scars the mitral valve and commonly causes fusion of the commissures and matting of the chordae tendineae, which interfere with the opening of the valve. The left atrium bears the brunt of the load, and the extent to which it dilates depends on its internal pressure and the state of the atrial myocardium. With time, calcification of the mitral valve renders it less mobile. In some patients with tight mitral stenosis, pulmonary vascular resistance rises because the pulmonary arteriolar venous pressure by vasoconstriction. The reasons for this response are not clear. The increase in resistance appears to be related to the rise in pulmonary venous pressure and does not occur when the rise is small. At first, the changes are functional and reversible by drugs such as acetylcholine and tolazoline. Later, however, anatomic changes appear, with medial hypertrophy and intimal thickening of pulmonary arterioles occurring first at the base of the lungs, where venous pressure is higher because of the effects of gravity, and later throughout the lungs. Severe pulmonary vascular lesions with markedly raised pulmonary vascular resistance (> 7.5 mm Hg/L/min) are virtually limited to patients with severe mitral stenosis, whereas lesser increases in pulmonary vascular resistance are seen in other forms of mitral disease. When pulmonary vascular resistance rises, the course of mitral stenosis is strikingly altered; the brunt of the load is transferred from the left ventricle, and right ventricular failure eventually occurs if the stenosis is not relieved.

JAYPEE BROTHERS

Passive pulmonary hypertension: The pulmonary arterial pressure must rise to maintain pulmonary blood flow in any patient whose left artrial pressure rises. Thus, when left atrial pressure rises to 25–30 mm Hg in mitral stenosis, the pulmonary arterial mean pressure inevitably increases to a mean level of 30–40 mm Hg. This "passive" pulmonary hypertension results in redistribution of the blood flow to the lungs, with more perfusion of the apexes. The load is not severe enough to cause right heart failure and pulmonary congestion with orthopnea and paroxysmal dyspnea dominates the clinical picture. Before mitral valvotomy was available, some patients died of acute pulmonary edema. The right ventricle continued to pump blood into the congested lung, the leakage of fluid into the alveoli flooded the lungs, and produced a fatal disturbance of gas exchange.

Onset of Atrial Fibrillation

In patients without pulmonary hypertension, atrial fibrillation usually develops with the passage of time. Even if pulmonary hypertension is present, 30% of patients develop atrial fibrillation early in the course of the disease. Atrial fibrillation is most closely correlated with age, but it also depends on left atrial pressure and the severity of involvement of the left atrium in the rheumatic process.

Clinical Findings

Symptoms

1. **Dyspnea:** The commonest presenting symptom (80%) in patients with mitral stenosis is shortness of breath on exertion. In women with severe lesions, this is usually noticed in early adult life (age 20–30 years), while the patient is still in sinus rhythm, perhaps during pregnancy. The dyspnea is due to pulmonary congestion that results from a rise in left atrial pressure associated with an increase in heart rate and a decrease in left atrial emptying time. The increased stiffness of the lungs increases the work of breathing, and the fall in cardiac output, which results from mitral value obstruction leads to an increase in heart rate the further aggravates the congestion. Any factor that increases the, heart rate is likely to aggravate dyspnea in mitral stenosis; anxiety, anemia, exposure to high altitude, pregnancy, thyrotoxicosis, and atrial fibrillation in a patient, with significant mitral stenosis virtually always provokes dyspnea. In milder cases, there may have been no dyspnea prior to the onset of arrhythmia, but in most instances the onset of atrial fibrillation exacerbates dyspnea rather than provoking it for the first time. Conversely, when a patient believed to have significant mitral stenosis develops atrial fibrillation without experiencing dyspnea, the diagnosis is in doubt and the lesion is at most mild.
2. **Paroxysmal nocturnal dyspnea**: The dyspnea in patients with mitral stenosis may be severe enough to progress to episodes of acute pulmonary edema, especially in the presence of some additional stress. Increased heart rate due to anxiety, atrial arrhythmia, fever due to intercurrent infection, excessive salt intake, or unaccustomed exertion should be sought. An acute episode of dyspnea often occurs at night, and the patient wakes from sleep with a choking sensation accompanied by cough. Relief is obtained by sitting or standing up. One episode of paroxysmal nocturnal dyspnea may cause the patient to sleep on several pillows indefinitely, and the association between recumbency and dyspnea is readily apparent to the patient. However, orthopnea is not necessarily present just because the patient uses several pillows. It is important to count the pulse and respirations and observe how well a change in posture is tolerated when the patient lies flat. Orthopnea should be treated as a sign rather than a symptom.
3. **Hemoptysis**: Hemoptysis is the second most common presenting symptom in mitral

JAYPEE BROTHERS

stenosis. There may be frank pulmonary hemorrhage from rupture of a pulmonary vein; frothy pink, blood-tinged sputum in pulmonary edema; or hemoptysis resulting from pulmonary infarction. Hemoptysis is seen in patients with raised pulmonary vascular resistance and in those with pulmonary congestion.

4. **Systemic embolism**: Presenting symptoms due to systemic embolism are infrequent in patients with mitral stenosis. Embolism is more common after atrial fibrillation has occurred and tends to occur later in the disease.
5. **Palpitations**: Palpitations are rarely the chief presenting complaint. Any arrhythmia is likely to provoke dyspnea, and the patient will usually complain of dyspnea rather than palpitations.
6. **Symptoms in patients with raised pulmonary vascular resistance**: Fatigue, coldness of the extremities, abdominal discomfort, and swelling of the abdomen and ankles are symptoms of right heart involvement. They suggest the presence of severe pulmonary hypertension and raised pulmonary vascular resistance with a low cardiac output and are thus indicative of severe mitral stenosis. Symptoms of right heart involvement can also occur in patients with associated organic involvement of the tricuspid valve. Chest pain that is indistinguishable from angina pectoris is occasionally noted in the presence of raised pulmonary vascular resistance or pulmonary embolism.
7. **Episodic symptoms**: Confusion in diagnosis sometimes occurs when the patient's symptoms are episodic. In this case, arrhythmia should be suspected, and the physician should try to see the patient during an attack in order to record an ECG.

Signs

The physical signs in patients with mitral stenosis vary with the severity of the valvular lesion and also with the amount of increase in pulmonary vascular resistance. The classic signs of mitral stenosis develop early in the natural course of the condition and can usually be noted before symptoms develop. However, the patient may have to engage in exercise in order to elicit the signs. In classic mitral stenosis, the pulse is normal or small in amplitude, and the blood pressure and systemic venous pressure are normal.

1. **Loud first heart sound**: The heart is not enlarged, and on palpation, there is an obvious localized tapping cardiac impulse. This represents the vibrations from the loud first heart sound that result from closure of the mitral valve (closing snap). There may also be a diastolic thrill with presystolic accentuation felt at the apex and a palpable opening snap felt at the base of the heart.
2. **Opening snap**: On auscultation, the first sound is loud, and the second sound is followed by a loud opening snap that is high-pitched and widely transmitted but heard best to the left of the sternum, near the base of the heart.
3. **Diastolic murmur with presystolic accentuation**: The characteristic finding in predominant mitral stenosis is a long, loud, rumbling mitral diastolic murmur with presystolic accentuation due to atrial systole. The murmur is often best heard in a localized area about 2.5 cm in diameter located at the apex of the heart. The patient should lie on the left side after exercise, and the physician should use the bell of the stethoscope and little pressure on the chest. The murmur may be absent in mid-diastole in mild cases but still show presystolic accentuation.
4. **S_2-OS interval**: The time elapsing between the aortic valve closure sound and the opening snap is roughly related to left atrial pressure. If left atrial pressure is high, the valve will open early because left atrial pressure soon comes to exceed left ventricular pressure. Conversely, if left atrial pressure is low, a longer time will elapse before left atrial

JAYPEE BROTHERS

pressure exceeds left ventricular pressure and filling starts. Thus, an early opening snap (0.05–0.07 sec after A2) suggests more severe stenosis than a later (0.10–0.12 sec after A2) opening snap. The presence of loud opening and closing snaps indicates that the mitral valve is flexible and suggests that mitral valvotomy rather than valve replacement will be appropriate treatment.

There is not infrequently a mitral systolic murmur in pure mitral stenosis. A long, rumbling diastolic murmur with presystolic accentuation during atrial contraction is the definitive auscultatory sign of mitral stenosis, and the presence of a presystolic (atrial systolic) murmur excludes a diagnosis of significant mitral incompetence. Thus, even though mild, hemodynamically insignificant mitral incompetence may cause a systolic murmur, this should not be construed as evidence of significant mitral incompetence when a patient has none of the other signs of mitral incompetence but some of the signs of mitral stenosis. The murmur may be due to tricuspid incompetence.

5. **Signs in the presence of atrial fibrillation**: When the patient develops atrial fibrillation, the presystolic murmur disappear. The heart rate becomes irregular, and after the heart rate has been slowed by digitalis therapy, it becomes important to listen for the length of the diastolic murmur during the longest diastolic pauses. In patients with predominant mitral stenosis, the murmur should persist until the end of diastole even in cardiac cycles lasting 1 sec. A shorter murmur suggests either mixed mitral stenosis and incompetence or raised pulmonary vascular resistance. It is the length of the diastolic murmur and not the fact that it lasts until the next first heart sound that is important in the determination of the severity of mitral stenosis.
6. **Pulmonary signs**: Rales at the bases of the lungs are commonly found in mitral stenosis, but their absence does not exclude the possibility of pulmonary congestion or even edema. The patient is often orthopneic because the lungs become more congested when the patient is in a supine position, the respiratory rate increase as the lungs become stiffer, and the patient becomes breathless. It is more reliable to have the patient lie flat and look for evidence of orthopnea than to ask shortness of breath occurs on recumbency.
7. **Signs in the presence of pulmonary hypertension**: When pulmonary vascular resistance is markedly raised (> 7.5 mm Hg/L/min), the physical signs of mitral stenosis tend to be different. The patient usually has a low cardiac output and is often thin, with peripheral cyanosis, cool extremities, and a pulse of small volume. Dilated veins on the cheeks combined with peripheral cyanosis give rise to a "mitral facies" that is also seen in other patients with a chronically low cardiac output. Systemic venous pressure is likely to be raised, with a prominent a wave visible in the jugular pulse if sinus rhythm is present. The heart may be enlarged, with a right ventricular substernal impulse. The auscultatory signs of mitral stenosis tend to be less florid than those in patients with low pulmonary vascular resistance because the cardiac output is lower. Less often, there is a diastolic thrill, but pulmonary valve closure is usually palpable. In about one-third of cases, either reduction in the cardiac output or valvular calcification modifies the classic physical signs, making the diagnosis difficult. Calcification of the valve may eliminate the opening snap but should not affect the murmur. Low output may eliminate the murmur but should not affect the snap. Calcification of the mitral valve does not always affect the physical signs and more than half of patients with valvular calcification have an opening snap. There is often a pulmonary systolic ejection click and a short pulmonary systolic murmur in addition to a loud pulmonary valve closure sound.

JAYPEE BROTHERS

a. **Pulmonary incompetence**: Pulmonary incompetence secondary to pulmonary hypertension may cause an immediate diastolic murmur at the base of the heart (Graham Steel murmur). In practice, associated hemodynamically insignificant aortic incompetence is a much more common cause of such a basal murmur.
b. **Tricuspid incompetence**: Pansystolic murmurs are common in patients with pulmonary hypertension and are usually due to secondary tricuspid incompetence, as shown by increased systemic venous pressure, a prominent a wave in the neck, and increased intensity of the murmur during inspiration. When right ventricular failure occurs, the right side of the heart may become so large that it occupies the whole front of the chest.

8. **Signs in the presence of low output:** In severely ill patients, the mitral diastolic murmur may vary in intensity because of changes in cardiac output or heart rate. The face that one observer has heard the murmur and another has not, should not be discounted, and repeated examinations may be helpful. A mitral diastolic murmur that is ordinarily inaudible may be heard by listening in the axilla, with the patient lying on the left side.
9. **Assessment of severity from physical signs**: Assessment of the severity of mitral stenosis based on physical signs is not of sufficient accuracy to be clinically valid. Patients with varying degrees of stenosis can all show fully developed classic physical signs. The timing of the opening snap confirmed by phonocardiography may be a guide to the severity of the disease, but this measurement must be assessed in relation to the rest of the clinical picture. The degree of pulmonary congestion shown on the chest X-ray and the findings at cardiac catheterization provide a more reliable index of severity.

Differential Diagnosis

Left atrial myxoma is the most important disorder in the differential diagnosis of mitral stenosis with or without raised pulmonary vascular resistance. The radiologic picture closely resembles that of mitral stenosis, and left atrial appendage enlargement is seen. Episodic symptoms, variable heart murmurs, fever, systemic embolism, a raised sedimentation rate, and hyperglobulinemia suggest the possibility of myxoma. The lesion is 100 times less common than mitral stenosis and 100 times more common than the rare congenital lesion cor triatriatum, in which the left atrium is divided into an upper and a lower chamber by an incomplete transverse septum. Cor triatriatum may also simulate stenosis. Echocardiography and angiocardiography with injection of dye into the left ventricle or pulmonary artery are helpful in diagnosis.

In patients with raised pulmonary vascular resistance, pulmonary hypertension due to any other cause such as Eisenmenger's syndrome, idiopathic or thromboembolic pulmonary hypertension, or atrial septal defect with acquired pulmonary hypertension must be ruled out. Because mitral stenosis with pulmonary hypertension can be cured by surgery and patients with pulmonary hypertension due to other causes do not withstand exploratory thoracotomy well, it is essential to make the correct diagnosis.

A. **Atrial Fibrillation**: Atrial fibrillation occurs so frequently in the course of mitral stenosis that it hardly qualifies as a complication. The importance of both the effect of atrial fibrillation on the natural history of the lesion and its time of onset cannot be stressed too strongly. The circumstances precipitating atrial fibrillation and its clinical effects provide important diagnostic and prognostic information about the lesion. It is important to determine whether the onset of atrial fibrillation aggravated existing symptoms or heralded their appearance. If the onset of atrial fibrillation escapes notice in a patient

JAYPEE BROTHERS

with mitral stenosis, either the lesion is extremely mild or increased pulmonary vascular resistance is present. In the latter situation, the patient has presumably been so disabled that the additional stress of the arrhythmia goes unnoticed. The earlier atrial fibrillation occurs, the worse the prognosis because of the implication that rheumatic carditis must have damaged the atrial muscle. Conversely, if atrial fibrillation has not developed by age 50 in a patient with mitral stenosis, the stenosis is almost invariably mild. It is therefore imperative to determine the circumstance surrounding the onset of atrial fibrillation and to assess the patient's tolerance of the arrhythmia.

B. **Bronchitis:** The congested lungs of patients with mitral disease are prone to bronchitis. This is seen more frequently in patients with mitral stenosis because pulmonary congestion is generally more severe than in other type of mitral valve disease.

C. **Pulmonary Infarction**: Pulmonary embolism and pulmonary infarction are common, especially in mitral stenosis with raised pulmonary vascular resistance. The lungs with their double arterial blood supply normally are not subject to infarction unless they are congested, and mitral stenosis is one of the commonest conditions in which pulmonary embolism is followed by pulmonary infarction. It is not always possible to determine the origin of the thrombus, and although emboli from the veins of the pelvis and legs are common, the possibility of thrombosis in situ should not be ruled out.

MIXED MITRAL STENOSIS AND INCOMPETENCE

In some cases, the rheumatic involvement of the mitral valve leads to dilatation and stretching of the valve tissue and subsequent scarring and retraction in addition to narrowing. In this case, stenosis is present in addition to significant leakage through the valve. After severe mitral stenosis has been treated surgically, the stenosis is less severe, but the valve is still abnormal. With time, degenerative changes, fibrosis and calcification stiffen and immobilize the valve and produce a mixture of stenosis and incompetence. The cardinal features of this lesion include obstruction and leakage at the mitral valve, left atrial enlargement, and left ventricular enlargement (not hypertrophy). Variable features, which may alter these findings, are the severity of obstruction, the amount of regurgitation, and the severity of rheumatic myocardial damage.

Patients with mixed mitral stenosis and incompetence run a more constant clinical course than might be expected in view of the numerous possible combinations of severity of the components. The blood that leaks back across the mitral valve during systole must flow forward during diastole, augmenting the normal forward stroke volume. Mitral incompetence thus increases mitral diastolic blood flow. The extra blood flow resulting from systolic mitral incompetence raises left atrial pressure and makes any mitral stenosis appear more severe. For these reasons, the clinical severity of mixed mitral stenosis and incompetence depends on the sum of the incompetence and the stenosis and tends to remain constant. If there is more stenosis than incompetence, there is a smaller amount of systolic back flow and a smaller diastolic forward flow across the valve. If there is more incompetence than stenosis, there is a larger systolic backflow and a larger diastolic forward flow. Thus, the symptoms in patients with mixed mitral lesions tend to vary less than might be expected. In contrast, the physical signs—which depend mainly on the volume of blood passing through the mitral valve during both systole and diastole—tend to depend on the severity of incompetence, and there is wide variation in the lengths and intensities of the systolic and diastolic mitral murmurs and in the degree of left ventricular volume overload.

JAYPEE BROTHERS

Clinical Findings

Symptoms

1. **Dyspnea:** Dyspnea is the commonest presenting symptom in patients with mixed mitral stenosis and incompetence. It seldom occurs while the patients are in sinus rhythm. The patient often presents with an acute episode of dyspnea associated with the development of atrial fibrillation. This onset commonly heralds the approach of other symptoms, and the patient, who may have been living a relatively normal life, becomes acutely ill with severe dyspnea and perhaps pulmonary edema. Atrial fibrillation is sometimes triggered by an intercurrent infection such as influenza, pneumonia and a systemic or pulmonary embolism may occur simultaneously. This clinical picture is so common that it is important to consider the possibility of mitral stenosis and incompetence in any patient who suddenly becomes short of breath, especially if the heart rate is rapid and atrial fibrillation is present. The physical signs can be difficult to interpret in the acute stage when the heart rate is rapid. Episodic dyspnea may be present when there is paroxysmal atrial arrhythmia. In such circumstances, it is important to see the patient during an attack.
2. **Palpitations**: Palpitations are common in patients with mixed mitral stenosis and incompetence. Palpitations are generally due to atrial arrhythmia; if the heart rate is rapid, dyspnea is likely to occur.
3. **Systemic embolism:** The first symptom of mixed mitral stenosis and incompetence may be due to acute systemic embolism. Sudden pain and coldness in the leg, sudden paralysis, acute loin pain due to renal infarction, flank pain due to infarction of the spleen, and infarction of the bowel due to mesenteric artery emboli sometimes occur. Embolism usually occurs in patients with atrial fibrillation, particularly when the rhythm changes, but it may happen when the patient is in sinus rhythm.
4. **Pressure from a large left atrium:** Symptoms due to pressure from a greatly enlarged left atrium on surrounding structures are occasionally seen. Thus, cough, hoarseness, and recurrent lung infection involving the left lower lobe may occur.

Signs

The signs in patients with mixed mitral, stenosis and incompetence. When incompetence is the predominant lesion, the left ventricular systolic ejection rate is more rapid than normal, and the peripheral pulse resembles a miniature "water-hammer" pulse. In patients with mixed mitral stenosis and incompetence, it is not always easy to assess the relative importance of the stenosis, the incompetence, or the overall severity of the lesion. It is possible that the patients with this lesion have resulted from either valvotomy or calcification and fixation of the deformed valve as well as degenerative, age-related changes and increased wear and tear.

The systemic venous pressure is not often raised unless there is associated tricuspid valve disease. Because pulmonary hypertension is seldom severe, the pulse is usually normal and the rhythm irregular in patients with atrial fibrillation. The heart is usually enlarged, with a hyperdynamic left ventricular impulse. The first sound may be loud and there may be an opening snap, especially if the patient has had a previous valvotomy for mitral stenosis. A third heart sound may also be heard, sometimes replacing the snap rather than accompanying it. Depending on the volume of mitral diastolic blood flow, there is a pansystolic mitral murmur transmitted to the axilla and a diastolic mitral murmur of variable length. In patients with moderate mitral incompetence, the murmur may last until the end of diastole at rapid heart rates (more than 100/min.). The murmur is never accentuated during atrial systole because even if the patient is in sinus rhythm, the mitral stenosis

JAYPEE BROTHERS

is not sufficient to limit atrial emptying, and the force of contraction of the distended left atrium is reduced. In patients with atrial fibrillation, the length of the mitral diastolic murmur depends on the R-R interval of the preceding beat. A long diastolic pause allows time for equilibration between left atrial and left ventricular pressure. With long pauses, the murmur disappears towards the end of diastole. It is thus important to ascertain the length of the diastolic murmur during the longest pauses. In mixed mitral stenosis and incompetence, the murmur is less than full length at a normal heart rate of 70/min.

Pulmonary congestion in mixed mitral valve disease is less marked than in mitral stenosis. Although pulmonary edema may occur at the onset of atrial fibrillation, control of the heart rate by digitalis usually leads to rapid improvement, and the symptom seldom recurs. Similarly, an increase in pulmonary vascular resistance seldom occurs and is not often severe in mixed mitral valve disease, presumably, because left atrial pressure is lower than in pure stenosis. The most important factors to consider in mixed mitral valve disease are heart rate and heart rhythm. The whole clinical picture is greatly dependent on these factors and the efforts of changes in heart rate and rhythm. The whole clinical picture is greatly dependent on these factors, and the effects of changes in heart rate on the patient's condition offer the best means of assessing the severity of the lesion.

Differential Diagnosis

A. Atrial Septal Defect: Atrial septal defect with normal pulmonary vascular resistance and hypertrophic obstructive cardiomyopathy enter into the differential diagnosis of patients with mixed mitral stenosis and incompetence. In atrial septal defect, atrial fibrillation, cardiac enlargement, and systolic and diastolic murmurs occur, and in the middle-aged patient, an erroneous history of rheumatic fever in childhood is sometimes present. With these findings, the incorrect diagnosis of rheumatic heart disease is easily made. Radiologic examination is most useful because in atrial septal defect the chest X-ray shows a large pulmonary artery, a small aorta, a big heart, a big right atrium, and a left atrium that is usually unimpressive. The ECG almost invariably shows incomplete or complete right bundle block with an rsR' pattern in lead V1. This finding should always raise the suspicion that an atrial defect exists. Cardiac catheterization is ordinarily required to establish the diagnosis with certainty. The two lesions—mitral valve disease and atrial septal defect—may rarely coexist in Lutembacher's syndrome. In this condition, raised venous pressure, hepatomegaly, and peripheral edema are common, and the presence of right heart failure in a patient with mixed mitral stenosis and incompetence should always suggest an associated atrial septal defect.

B. Hypertrophic Cardiomyopathy: Patients with hypertrophic cardiomyopathy (who tend to be confused with those with mixed mitral valve disease) have lesions of the left ventricular inflow tract, with or without outflow obstruction. This lesion is rare, but when it is present mitral systolic and diastolic murmurs and mitral incompetence are seen. Significant left ventricular hypertrophy is always seen on the ECG. Echocardiography shows narrowing of the left ventricular outflow tract and systolic anterior motion of the aortic cusp of the mitral valve. Left ventricular catheterization and angiography are needed to confirm the diagnosis.

MITRAL INCOMPETENCE

Mitral incompetence differs from other forms of mitral valve disease in that it occurs as both an acute and a chronic lesion. The chronic lesions are further subdivided into hemodynamically insignificant and significant lesion. The hemodynamically insignificant form is present in those patients with the "click-murmur" syndrome described by Barlow, sometimes

JAYPEE BROTHERS

referred to as the floppy valve syndrome or mitral valve prolapse, but these terms are unsatisfactory because prolapse and "floppy valves" may cause acute mitral incompetence and imply a pathologic process that cannot be determined at the bedside.

Clinical Findings of Mitral Valve Prolapse (MVP)

1. **Symptoms**: Most patients are entirely symptom-free, and the condition is found accidentally on routine physical examination. In some cases, atypical chest pain is present, and palpitations, fatigue, and dyspnea unrelated to exertion also occur. Exercise tolerance is usually normal. Symptoms are more likely in patients who know they have the lesion. A family history of the lesion is occasionally found, and there may be a familial history of sudden death.
2. **Signs**: The only abnormalities are usually auscultatory in nature. The characteristic sign is a late systolic murmur. It is often preceded by one or more midsystolic clicks. The murmur increases in intensity up to the second heart sound, making it difficult to time and often leading to an incorrect diagnosis of diastolic murmur. It may become pansystolic with exercise or when the patient stands up. It often has a honking quality and may on occasion be loud enough to be heard without a stethoscope. It is not uncommonly the only abnormal finding and its timing is its most consistent feature. In some cases, a click is heard without a murmur. In such patients, mitral valve prolapse without mitral incompetence is thought to be present.

Differential Diagnosis Mitral Valve Prolapse

The physical signs of click-murmur syndrome are sufficiently specific to make the diagnosis of hemodynamically insignificant mitral incompetence reasonably certain. The underlying pathology and the causes are more difficult to determine, however, and the significance of the lesion is always open to question. The presence of associated coronary artery disease may have to be ruled out by angiography in some cases.

Clinical Findings of Mitral Incompetence

Symptoms

1. **Acute lesions:** Dyspnea is the principal presenting symptom in patients with acute mitral incompetence. The onset may be acute, (e.g. when a cusp perforates or tears), or subacute (e.g. when the mitral valve gradually shrinks and retracts after treatment of endocarditis). Dyspnea may progress to acute pulmonary edema with acute circulatory collapse, shock, and frothy pink, blood-tinged sputum. The patient may be ill at the time of onset, with a high fever and septicemia. Episodic attacks of dyspnea may occur and are associated with minor increases in cardiac output in response to the exertion of meals, washing, bowel movements, or even the excitement of visitors. Left atrial pressure is markedly dependent on the peripheral resistance in this lesion, and any increase in arterial pressure may provoke an attack of dyspnea.
2. **Chronic lesions:** In hemodynamically significant lesions, dyspnea is the principal presenting symptom. It is not usually as severe as in mitral stenosis, and the effects of an increase in heart rate are less prominent. The onset of atrial fibrillation is generally well tolerated and does not provoke the acute symptoms seen in patients who have mitral stenosis. Palpitations are more common than in other forms of mitral disease; atrial fibrillation is the commonest cause. Patients do not usually present with symptoms due to systemic embolism, but such symptoms can occur, especially in the presence of endocarditis.

JAYPEE BROTHERS

Signs

The first heart sound is usually buried in the pansystolic murmur, but there is never an opening snap. The presence of an opening snap indicates that significant rheumatic mitral stenosis is present. There is almost invariably a loud third heart sound associated with the rapid phase of left ventricular filling. It is a dull, low-pitched, thudding sound occurring about 0.10–0.18 second after the second sound. Some observers may consider it long enough to be called a diastolic murmur. Differences of opinion may arise about whether any degree of mitral stenosis is present. The characteristic murmur is a loud, high pitched, pansystolic apical murmur transmitted to the axilla. It is louder on expiration and decreases when systemic vascular resistance decreases acutely, as occurs with amyl nitrate inhalation.

Signs of right heart failure and raised pulmonary vascular resistance are rare except in patients with severe acute mitral incompetence resulting from acute disruption of the valve. The presence of right sided failure with increased venous pressure in a patient with mitral incompetence should suggest the possibility of associated organic tricuspid valve disease.

Differential Diagnosis of Mitral Incompetence

Mitral incompetence must be distinguished from hypertrophic cardiomyopathy. There is a long pansystolic murmur in both conditions, and although the murmur in mitral incompetence is usually higher pitched, has a timing that is not of the ejection type, and is transmitted to the axilla rather than centrally, the two lesions can be confused on diagnosis. Both show a third heart sound and a prominent left ventricle.

Ventricular septal defect is another condition that can be confused with mitral incompetence. Again, the auscultatory findings are similar, with an overactive left ventricle, a pansystolic murmur, and third heart sound. Chest X-ray may be helpful if the ventricular septal defect is large enough to cause increased lung markings resulting from increased pulmonary blood flow, but even these markings can be confused with those due to pulmonary congestion. Endocardial cushion defects with an associated ostium primum atrial defect and mitral incompetence are also difficult to differentiate from pure mitral incompetence and cardiac catheterization is almost invariably needed to confirm the diagnosis. In the case of acute lesions, especially in patients who have suffered a recent myocardial infarction, the distinction between acquired ventricular septal defect due to rupture of the ventricular septum and acute mitral incompetence due to papillary muscle involvement can be extremely difficult. Here, too, as in all significant lesions, cardiac catheterization and angiography are necessary to confirm the diagnosis before surgery.

AORTIC VALVE DISEASE

It is tolerated rather well for a long time as compared to mitral disease. Aortic valve disease is the next most common form of valvular heart disease after mitral disease and accounts for about 35% of patients with significant valvular lesions. Classification is difficult because of the varied causes, hemodynamic severity, acuteness or chronicity, anatomic site and nature of the lesion.

Classification

Aortic valve disease has been classified in this text into three main categories; (1) hemodynamically insignificant aortic valve disease, (2) hemodynamically significant predominant aortic incompetence, and (3) hemodynamically significant predominant aortic incompetence.

In hemodynamically insignificant aortic value disease, it is impossible to determine whether stenosis or incompetence is predominant because the lesion is so mild. There is no evidence of cardiac enlargement or hypertrophy and no limitation of exercise tolerance. It is

JAYPEE BROTHERS

for detailed information on cardiology books, visit our website www.jaypeebrothers.com, for detailed information on cardiology

CLINICAL METHODS IN CARDIOLOGY

Salient Features

- An 'exhaustive but not exhausting' compilation of proper history taking, clinical methods, physical signs and their intelligent correlation to come to an intelligent diagnosis before investigation reports are seen
- Besides an overview of history, signs and symptoms in cardiology, an individual 'disease-wise approach' which definitely provides more in-depth knowledge rather than just a superficial brushing up
- Making full use of his great experience of 30 years post-DM Cardiology teaching in a Government Medical College, Jabalpur, Madhya Pradesh, India, Dr RS Sharma has collection of a large number of questions commonly asked in the UG and PG examinations. He has devoted a separate chapter for these important and at times vital questions and their correct answers. This is to be used as 'mental gym' as Dr Sharma suggests.



RS Sharma MD Medicine DM Cardiology (AIIMS, New Delhi) FICP from prestigious All India Institute of Medical Sciences has been associated with Clinical and Investigative Cardiology Teaching since 1984 in Government Medical College, Jabalpur, Madhya Pradesh, India. Presently, he is Senior Consultant and In-Charge, Department of Cardiology, Government Medical College, Jabalpur. He is actively interested in academics besides cardiology practice. He has a large number of national publications and conference presentations. Besides an original article in the 'Lancet (UK)' describing an original grading of intensity of heart sounds and murmurs. He is active member of API, CSI. He is a dedicated, well-respected teacher and impressive orator. He also has great interest in cardiac, peripheral color Doppler, coronary and peripheral angiography, and angioplasty. He also runs the NGO 'Hridya Mitra' for increasing heart well-being awareness. He is 'Editor-in-Chief' of regular magazine of the same name 'Hridya Mitra'. He also writes for public at large in various forms of media. He recently invented 'Suicide-proof ceiling fan' which was widely acclaimed.

Available at all medical bookstores
or buy online at www.jaypeebrothers.com

JAYPEE BROTHERS
Medical Publishers (P) Ltd.
www.jaypeebrothers.com

Join us on facebook.com/JaypeeMedicalPublishers

Shelving Recommendation
CARDIOLOGY

ISBN 978-93-5152-665-0

9 789351 526650