others.com, for detailed information on cardiology books, visit our website www.jaypeebrothers.com, for detailed information on cardiology books

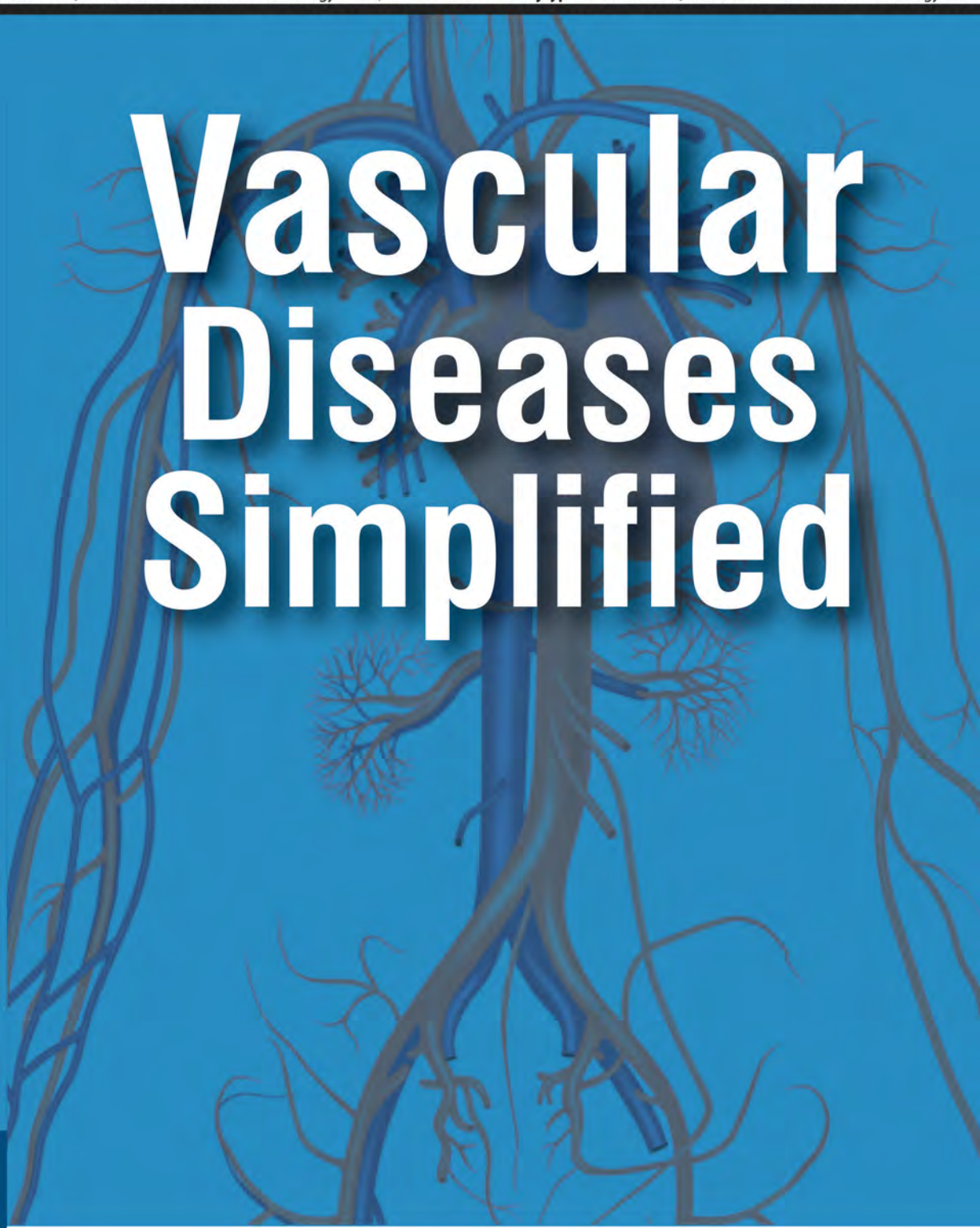

Vascular Diseases Simplified

Editor
Sumit Kapadia

JAYPEE

Contents

1. **Acute Limb Ischemia** 1
   Sumit Kapadia
2. **Chronic Lower Limb Ischemia** 11
   Sumit Kapadia
   - Presenting Symptoms and Signs of Lower Limb Ischemia *12*
   - Investigations for Lower Limb Ischemia *17*
   - Treatment of Lower Limb Ischemia *23*
3. **Varicose Veins** 43
   Sumit Kapadia
   - Causes of Varicose Veins *43*
   - Investigations *50*
   - Treatment of Varicose Veins *53*
4. **Leg Ulcers** 70
   Sumit Kapadia
   - Classic Features of Different Leg Ulcers *70*
   - Management of Venous Ulcers *73*
5. **Vascular Malformations** 82
   Sumit Kapadia
   - Clinical Features *84*
   - Diagnosis *88*
   - Treatment of Low-flow Vascular Malformations *92*
   - Treatment of High-flow Arteriovenous Malformations *100*
6. **Thoracic Outlet Syndrome** 104
   Tarun Grover
   - Classification and Incidence *104*
   - Anatomy *104*
   - Etiology *104*
   - Cervical Rib *105*
7. **Hemodialysis Access Procedures** 118
   Vishnu M
   - Hemodialysis *118*
   - Arteriovenous Graft *126*
   - Complications of Dialysis Access Procedures *128*

8. Diabetic Foot **136**
Vishnu M
- Facts *136*
- Clinical Assessment of the Diabetic Foot *140*
- Diagnostic Investigations *146*
- Classification of Foot Ulcers *149*
- Preventive Care of Diabetic Foot *150*
- Diabetic Foot Management *150*

9. Vascular Injuries **158**
Sumit Kapadia
- Clinical Features of Extremity Injuries *158*
- Investigations for Extremity Vascular Trauma *161*
- Treatment of Extremity Vascular Injuries *163*
- Treatment of Pseudoaneurysms and AV Fistulae *167*

10. Deep Vein Thrombosis **178**
Sumit Kapadia
Pathophysiology of Venous Thrombosis *178*

11. Carotid Artery Disease **191**
Sumit Kapadia
- Presentation *191*
- Natural History of Carotid Artery Atherosclerotic Disease *191*
- Diagnostic Tests for Carotid Disease *192*
- Treatment *196*

12. Portal and Mesenteric Vascular Disorders **206**
Sumit Kapadia
Portal Hypertension: A Vascular Surgeon's Perspective ***206***
- Complications of Portal Hypertension *206*
- Clinical Presentation *206*
- Investigations in Patients with Portal Hypertension *207*
- Treatment of Portal Hypertension *208*

Acute Mesenteric Ischemia ***213***
- Clinical Features *213*
- Diagnosis *214*
- Chronic Mesenteric Ischemia *216*

Index *223*

CHAPTER 3

Varicose Veins

Sumit Kapadia

INTRODUCTION

The term varix is derived from the word varus, meaning bent. Varicose vein refers to dilated, tortuous veins associated with incompetent valves and reverse flow.

Varicose veins are a common clinical problem, one of the most frequently encountered vascular disorders. The worldwide incidence of varicose veins is believed to be in 10–15% of men and 20–25% of women. The diagnosis and treatment of varicose veins has evolved over many years.

Varicose veins are not just a cosmetic problem, as they can lead to numerous complications due to venous insufficiency and subsequent venous hypertension.

CAUSES OF VARICOSE VEINS

- Primary
- Secondary
  - Post-thrombotic
  - AV fistula
  - Klippel-Trenaunay syndrome.

The most common cause is primary or idiopathic varicose veins, which is possibly due to vein wall weakness, primary valvular incompetence or both. A familial history may or may not be evident. It is more frequent in women, especially after pregnancy. Junctional reflux, sapheno-femoral or sapheno-popliteal is responsible for majority of varicose veins. Few patients have primary reflux from leg perforators alone.

Of the secondary causes, varicosity in a patient with previous thrombosis is common. Due to thrombosis and subsequent recanalization, there is valvular damage, resulting in deep venous reflux which leads to perforator reflux and varicose veins. The patients with post-thrombotic varicosities are more likely to have edema, skin changes and ulceration than those with primary varicose veins.

A congenital arterio-venous malformation or acquired arterio-venous fistula can also lead to varicose veins in atypical locations. A palpable thrill or auscultatory bruit is noted in these patients.

Klippel-Trenaunay syndrome is a congenital vascular malformation with a triad of cutaneous hemangiomas, congenital lateral leg varicosities and limb hypertrophy due to persistent embryonic lateral vein.

JAYPEE BROTHERS

Symptoms

The severity of signs and symptoms does not necessarily correlate with the size or extent of visible varicose veins.

Pain in leg especially associated with prolonged standing may range from a mild dull ache to tiredness to muscle fatigue and cramps. However, the fact that it is brought on by standing and is relieved from leg elevation differentiates it from other causes of leg pain.

Some patients may seek advice because of asymptomatic unsightly veins alone.

Few patients consult their doctors only after the onset of complications (*see* Box 3.1).

Signs

Reticular veins are small sub-dermal nonpalpable veins of 1–3 mm (Fig. 3.1).

Box 3.1

Complications of varicose veins

- Eczema
- Ulcers
- Bleeding
- Thrombophlebitis
- Deep vein thrombosis
- Champagne leg deformity
- Marjolin's ulcer



Fig. 3.1 Reticular veins

JAYPEE BROTHERS



Fig. 3.2 Varicose veins in GSV territory



Fig. 3.3 Large varicose veins in GSV territory

Varicose veins are palpable subcutaneous veins of more than 3 mm diameter. They are common in the great saphenous vein territory (thigh, medial aspect of leg or along the anterior leg) (Figs 3.2 and 3.3).

Patients with short saphenous varicose veins have visible veins in posterior aspect of leg or popliteal fossa (Fig. 3.4).

JAYPEE BROTHERS



Fig. 3.4 Varicose veins in SSV territory



Fig. 3.5 Giacomini vein in posterior thigh

Occasionally, Giacomini vein is noted in posterior thigh, extending from short saphenous vein and connecting to the long saphenous vein in medial part of thigh (Fig. 3.5). This is also termed as the intersaphenous vein.

Venous hypertension due to varicose veins can often lead to a variety of skin changes and problems which are listed in Box 3.2.

Common skin changes include brown pigmentation due to hemosiderin deposition or eczema (Fig. 3.6). In patients with lipodermatosclerosis, the skin of lower leg is brown, thick, indurated or hard, with possible scars of previous ulcers or active ulceration (Figs 3.7 and 3.8).

JAYPEE BROTHERS

Box 3.2

Signs of venous hypertension

- Skin pigmentation
- Eczema
- Ankle flare
- Lipodermatosclerosis
- Healed ulcers
- Active ulcers



Fig. 3.6 Skin pigmentation in lower leg



Fig. 3.7 Lipodermatosclerosis right leg.

Venous ulcers are most frequently found on medial aspect of lower leg or ankle (Fig. 3.9). The ulcers can range from small to large ones and take a long time to heal. However, in short saphenous territory varicose veins ulcer may be noted on the lateral aspect of ankle (Fig. 3.10). These venous ulcers are usually not very painful and in spite of granulation do not heal. Some patients have large ulcers for many years and can develop a champagne leg deformity due to the hypertrophied calf muscle and thin leg.

Few patients may present with bleeding from a small varix. The bleed is usually a spurt due to the high venous pressure and may occur spontaneously

JAYPEE BROTHERS



Fig. 3.8 Lipodermatosclerosis with healed ulcer



Fig. 3.9 Large ulcer over medial aspect of leg



Fig. 3.10 Varicosities in short saphenous region, leading to ulcer in lateral aspect of ankle

JAYPEE BROTHERS

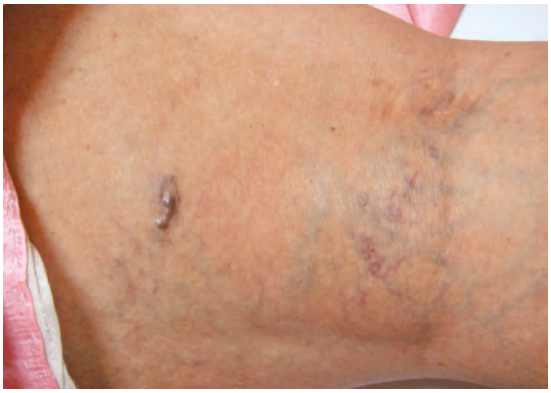

Fig. 3.11 Thin walled varicosity, prone to rupture



Fig. 3.12 Bleeding varix which has been ligated.

or after minor trauma or scratch. Thin walled small varices (Fig. 3.11) are more prone to rupture rather than large thick walled varicosities. Limb elevation and direct pressure or suture ligation of varix is required to stop the bleed (Fig. 3.12).

Acute onset of pain, redness and swelling along the saphenous vein is suggestive of thrombophlebitis, which is a rare occurrence in patients with varicose veins (Fig. 3.13). Rarely, patients may not have severe pain but present with indurated, noncompressible thrombosed varicosities (Fig. 3.14).

The CEAP classification system of venous insufficiency

Clinical signs	(A) for asymptomatic and (S) for symptomatic
Etiologic classification	Congenital, primary, or secondary
Anatomic Distribution	Superficial, deep, perforating, or combination
Pathophysiologic dysfunction	Reflux or obstruction, alone or in combination.

JAYPEE BROTHERS



Fig. 3.13 Thrombophlebitis of long saphenous vein in leg



Fig. 3.14 Thrombosed varicosities without significant redness or inflammation

Clinical Classification of Chronic Venous Disease

Class 0 No visible or palpable evidence of venous disease.
Class 1 Telangiectasias or small reticular veins (1–4 mm diameter).
Class 2 Varicose veins > 4 mm in diameter.
Class 3 Varicose veins with edema
Class 4 Skin changes (pigmentation, lipodermatosclerosis)
Class 5 Skin changes with healed venous ulceration.
Class 6 Skin changes with active ulceration.

INVESTIGATIONS

A good clinical examination is a good guide to identify sapheno-femoral reflux, sapheno-popliteal reflux and presence of perforators.

Color Doppler

Color Doppler is a good noninvasive imaging tool with high sensitivity and specificity and has replaced venography as the first line investigation for patients with varicose veins.

JAYPEE BROTHERS

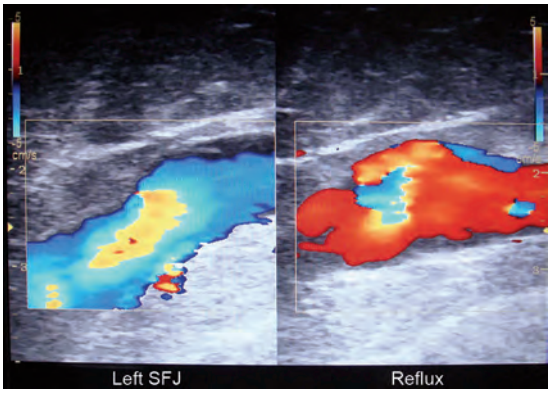

Fig. 3.15 The saphenofemoral junction shows blue color (on the left) and on Valsalva manoeuvre, the Doppler shows color change to red suggestive of reverse flow or reflux (on the right)

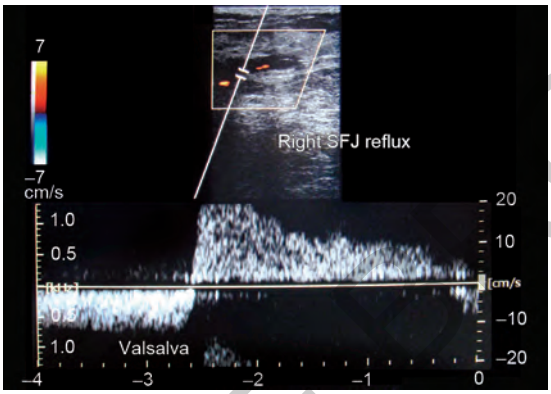

Fig. 3.16 Spectral doppler shows reflux more than 2 seconds at the sapheno-femoral junction

Triplex or color Doppler utilizes B-mode ultrasound with color flow and spectral flow. The sapheno-femoral junction can be identified. Reversal of color flow at the junction on Valsalva maneuver is suggestive of reflux or incompetence (Fig. 3.15). On spectral Doppler, the duration of reflux is noted. It is significant if lasting for more than 1 second (Fig. 3.16).

Large varicosities as well as large perforators are noted along the course of the long and short saphenous veins (Fig. 3.17).

Patent and compressible deep veins are confirmed on duplex to rule out previous deep vein thrombosis (Fig. 3.18).

The other major advantage of color Doppler is marking of incompetent sapheno-popliteal junction (which is highly variable) as well as incompetent perforators prior to surgery.

Plethysmography

The role of physiologic testing with plethysmography is to identify patients with deep vein reflux and high chances of recurrence after surgical interventions. Ambulatory venous pressure (AVP) at ankle and venous refilling time (VRT)

JAYPEE BROTHERS

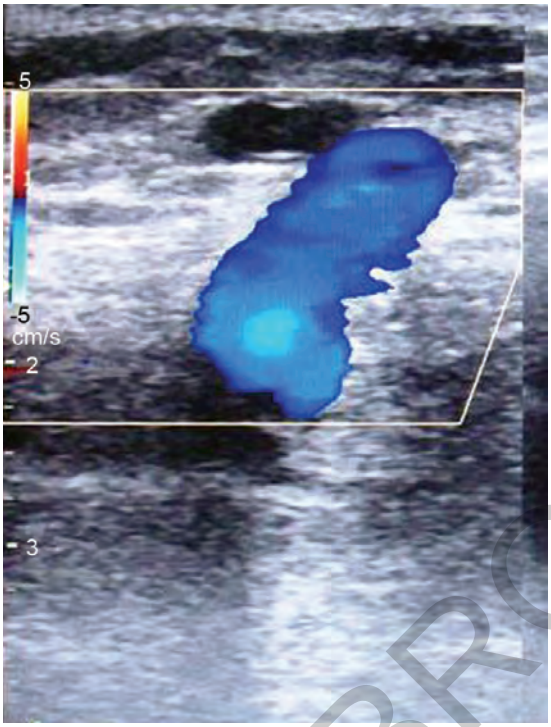

Fig. 3.17 Large vein perforator seen on color doppler

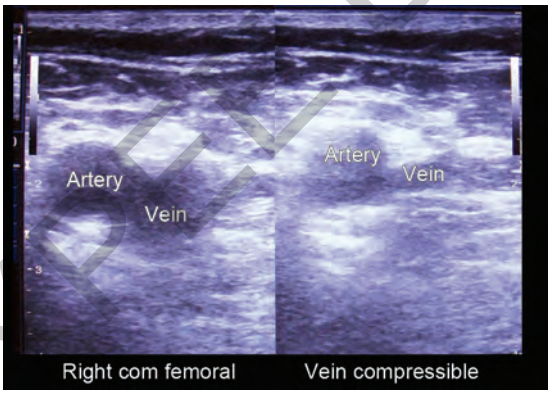

Fig. 3.18 Patent and compressible femoral vein rules out deep vein thrombosis

are useful to identify severity of venous reflux as well as role of venous outflow obstruction or calf muscle pump failure.

Venography

Being an invasive investigation, descending venography is used very selectively to detect the source of reflux in recurrent varicose veins or for evaluation of deep venous reflux.

JAYPEE BROTHERS

TREATMENT OF VARICOSE VEINS

Principles of Treatment

- Ensure that varicose veins are responsible for symptoms
- Identify the sites of venous reflux
- Rule out post-thrombotic changes in deep veins.

The five modes of treatment include

- Medicines
- Compression therapy
- Injection sclerotherapy/Foam sclerotherapy
- Surgery
- Endovenous procedures—LASER/Radiofrequency ablation

Medical Management

Medicines alone have no definite role in treatment of varicose veins. Drugs including Flavonoids, calcium dobesilate or oxerutins are useful in improving symptoms or edema especially when used along with compression therapy. Patients are also advised to keep their legs elevated at night to reduce the edema.

Compression Therapy

Graduated compression stockings with class 2 compression (18–25 mm Hg pressure at ankle) are recommended for conservative management of varicose veins (Fig. 3.19). They should be worn throughout the day and removed at night.



Fig. 3.19 Graduated compression stockings

JAYPEE BROTHERS

Elastocrepe bandages are not useful as they do not provide uniform compression as well as tend to get loose.

The use of compression therapy improves symptoms, reduces edema and helps in ulcer healing, but the vein size or associated reflux do not reduce after compression.

Foam Sclerotherapy

Detergent based sclerosants (1% Polidocanol or 1–3% sodium tetradecyl sulfate) are chemicals that produce endothelial destruction and vein sclerosis when injected directly into veins. These can be injected in to small isolated varicosities after the vein has been punctured and emptied by leg elevation (Fig. 3.20). The major limitation in their use is that the volume should not exceed 1 mL per injection.

In recent years, these liquid sclerosants are converted in to foam when mixed with air and passed across two syringes across a two-way. Thus by this technique, 1 mL of sclerosant is transformed to 4–5 mL of foam (Fig. 3.21). The other advantage of foam sclerosant is that foam displaces blood and thus empties the vein well.



Fig. 3.20 Scalp vein being inserted into varicose vein for sclerotherapy



Fig. 3.21 Foam sclerotherapy made by two 5 mL syringes

JAYPEE BROTHERS

Ultrasound-guided vein puncture and foam sclerotherapy is helpful as a day-care procedure for isolated varicose veins and perforators (Fig. 3.22). Some vascular specialists use this method for the long and short saphenous vein segments also. This can be performed under local anesthesia with Doppler guidance. Figures 3.23 and 3.24 show ultrasound/Doppler pictures of foam



Fig. 3.22 Ultrasound guided perforator puncture. 5 mL syringe filled with foam vein being attached

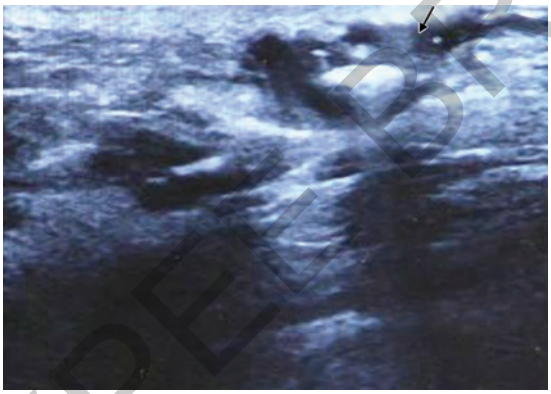

Fig. 3.23 White cloudy appearance of foam within the varicose vein seen on ultrasound

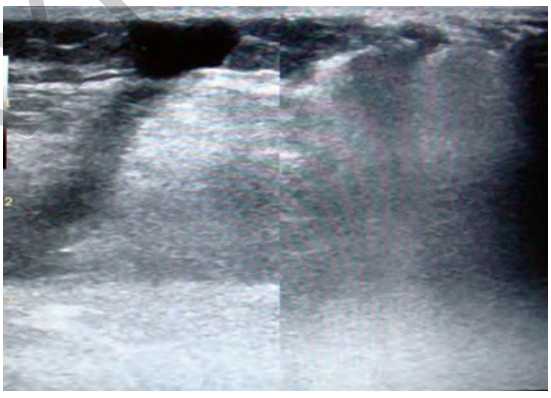

Fig. 3.24 Doppler foam sclerotherapy. The left image shows perforator and varicose vein. The right image shows postsclero image

JAYPEE BROTHERS

for detailed information on cardiology books, visit our website **www.jaypeebrothers.com,** for detailed information on cardiology books, visit our w

Vascular Diseases Simplified

The incidence and detection of peripheral vascular diseases has been steadily escalating over the past two decades, owing to increased training centers, better awareness and availability of various diagnostic and therapeutic modalities throughout the country.

However, existing textbooks on vascular diseases, which have been authored by foreign authors, may appear to be more exhaustive and hence suitable only for vascular surgeons in training or in practice.

The book meets the requirement for a more concise handbook which can be handy and beneficial to medical students, surgical trainees and practicing clinicians or surgeons who wish to be familiar with principles of vascular diseases.

The highlights of the book include practical guidelines in diagnosis and treatment of vascular diseases, crisp discussion of treatment steps and a large number of self-explanatory photographs. Most vital tips are included in boxes and tables to enable the reader a rapid understanding.



Sumit Kapadia completed his MBBS with gold medal and his MS (General Surgery) (2001) from Baroda Medical College, Vadodara, Gujarat, India. His concise notes in subjects of medicine and surgery were widely circulated amongst medical students in Vadodara and other cities of Gujarat for more than 15 years. He also has the credit of clearing DNB (General Surgery) and MRCS examinations.

He accomplished DNB Fellowship in Vascular and Endovascular Surgery (2005) from Sir Ganga Ram Hospital, New Delhi, India.

He is a Consultant Vascular and Endovascular Surgeon, Venus Hospital, Vadodara, for past 9 years. He has published 23 papers in national and international journals, and has been the recipient of two awards for best paper presentation in national and international conferences. He has keen interest in the field of endovascular interventions including peripheral angioplasty, angioembolization and treatment of vascular malformations.

This book is a dream come true to Dr Sumit, who has always enjoyed teaching as a hobby apart from his profession. Further queries can be addressed to Dr Sumit Kapadia at *drsumit_k@rediffmail.com* and on website *www.venusvascular.in.*

Available at all medical bookstores
or buy online at www.jaypeebrothers.com

JAYPEE BROTHERS
Medical Publishers (P) Ltd.
www.jaypeebrothers.com

Join us on facebook.com/JaypeeMedicalPublishers

Shelving Recommendation
CARDIOLOGY

ISBN 978-93-5152-671-1

9 789351 526711