oks, visit our website www.jaypeebrothers.com, for detailed information on surgery boo

JAYPEE

Clinical Surgery

Mahmoud Sakr

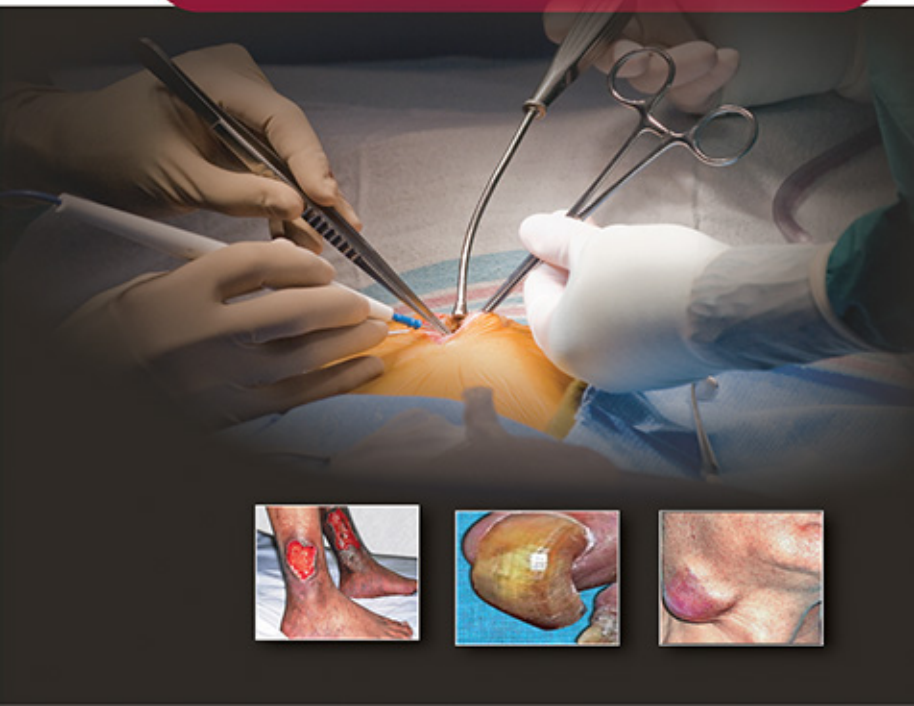

Contents

Chapter 1: Surgical Case Sheet 1
- Introduction to Surgical Case Sheet 1
- History Taking 2
- Special Present History (Pain, Bleeding, Swelling, and Ulcer) 10
- Clinical Examination and Diagnosis 16

Chapter 2: Clinical Problems 24
- Swelling 24
- Ulcer 32
- Sinus–fistula 43
- Lymphadenopathy 49

Chapter 3: Skin and Subcutaneous Tissues 59
- Cyst of the Skin and Subcutaneous Tissues 59
- Solid Swellings of the Skin 65
- Solid Swellings of "Subcutaneous" Tissues 76

Chapter 4: Head and Neck 81
- Swellings of the Scalp 81
- The Face 88
- Oral Cavity 96
- Jaws 115
- Salivary Glands 123
- Cervical Lymph Nodes 139
- Midline Neck Swellings 148
- Lateral Neck Swellings 155
- Thyroid Gland (Goiter) 169

Chapter 5: Chest Wall and Breast 189
- Chest Wall Swellings 189
- Swellings of the Axilla 192
- Breast 196

Chapter 6: Dysphagia 220
- Definition and Types 220
- Functional Grades of Dysphagia 220
- Causes of Dysphagia 220
- Dysphagia: Clinical Approach 222

Chapter 7: Anterior Abdominal Wall and Umbilicus 231
- Anterior Abdominal Wall 231
- Diseases of the Umbilicus 242

Chapter 8: Abdomen 246
- Abdominal Examination 246
- Hepatomegaly 257
- Splenomegaly 260
- Schistosomal Hepatic Fibrosis 263
- Jaundice 270
- Abdominal Mass 281
- Abdominal Distention 309

Chapter 9: Hernia 312
- Examination of Groin Hernia 312
- Differential Diagnosis of a Groin Lump 322
- Other Rare Hernia 325

Chapter 10: Anorectal Surgery 329
- Anorectal Examination 329
- Rectal Bleeding 334
- Perianal Pain 338
- Anal Lumps 341

Chapter 11: Vascular Surgery 346
- Arterial Disease 346
- Venous Disease 364
- Lymphatic Disease 385
- Leg Ulcers 390
- Swollen Limb 403

Chapter 12: Urosurgery 408
- Urological Case Sheet 408
- Renal Swelling 424
- Diseases of the Ureter 432
- Diseases of Urinary Bladder 433
- Diseases of the Prostate 437
- Hematuria 442
- Urine Retention 448
- Scrotal Swellings 452
- Hydrocele 463
- Varicocele 466
- Testicular Tumors 470
- Maldescended Testis 475

Chapter 13: Neurosurgery 482
- Neurosurgical Sheet 482
- Congenital Anomalies 494
- Spinal Abnormalities 497
- Back Pain 514
- Peripheral Nerve Injuries 518
- Intracranial Space-occupying Lesion 534

Chapter 14: Orthopedic Surgery 549
- Diseases of Muscles, Tendons, and Fasciae 549
- Diseases of Bones 554
- Diseases of Joints 581
- Diseases of the Upper Limb 596
- Diseases of the Lower Limb 606
- Diseases Peculiar to Hands 628
- Diseases Peculiar to Feet 650

Bibliography 665
Index 667

Chapter

4 Head and Neck

SWELLINGS OF THE SCALP

I. Congenital
   1. Inclusion (sequestration dermoid) dermoid cyst
   2. Meningocele/encephalocele
   3. Cirsoid aneurysm

II. Acquired
   A. Traumatic
      Cephalohematoma:
      1. Subcutaneous
      2. Subgaleal or subaponeurotic
      3. Subperiosteal
   B. Inflammatory
      1. Infected granuloma
      2. Osteomyelitis
      3. Cock's peculiar tumor
      4. Suppuration (abscess)
      5. Cellulitis and erysipelas
   C. Sebaceous cyst
      - Single
      - Multiple
      - Cock's peculiar tumor
   D. Neoplastic

Benign tumors	Malignant tumors	
	Primary tumors	Secondary tumors
1. Papilloma.	1. squamous cell carcinoma (SCC)	1. Thyroid
2. Hemangioma	2. Basal cell carcinoma (BCC)	2. Breast
3. Lymphangioma	3. Malignant melanoma	3. Bronchogenic
4. Cirsoid aneurysm	4. Multiple myeloma	4. Kidneys
5. Neurofibroma	5. Fibrosarcoma	5. Suprarenal glands
6. Lipoma		6. Prostate
7. Osteoma/ chondroma		

   E. Pott's puffy tumor.

JAYPEE BROTHERS

Congenital Masses

Inclusion Dermoid Cyst (Sequestration Dermoid)

- Duration: It may be noticed at birth, but usually first seen a few years later when it begins to fill up.
- Symptoms: Parental distress at the cosmetic disfigurement and concern about diagnosis.
- Sites (position): Midline of scalp. Very rarely, it may have an intracranial extension through a defect in the underlying bone forming a dumbbell-shaped swelling known as hourglass dermoid.
- Clinical examination: The cyst is usually single. It is small (1–2 cm) and ovoid or spherical, with a smooth surface and well-defined borders. Consistency is cystic or soft. The cyst may fluctuate, but will not transilluminate (opaque). It is not pulsatile, compressible or reducible. The skin overlying is normal unless it is inflamed. They lie in the subcutaneous tissue and unlike sebaceous cysts, are not attached to the overlying skin.
- Investigations: Plain X-ray of the skull may show the defect in the bone.

Differences between a dermoid cyst and a sebaceous cyst

Criteria	Dermoid cyst	Sebaceous cyst
Age	Childhood and adolescence	Middle and old age
Site	At lines of embryonal fusion	Anywhere especially in scalp and face
Punctum	–ve	+ve
Pinching skin	+ve (subcutaneous location)	–ve (intradermal)
Consistency	Cystic or soft	Cystic or doughy (indented)
Multiplicity	Usually single	Commonly multiple
Extension	± intracranial	–ve

Meningocele/Encephalocele

- It is a protrusion of the meninges through a defect in the skull (**Figure 4.1**) (or spinal canal). It contains cerebrospinal fluid (CSF).
- The commonest site is the occipital region. The other three sites are all extremely rare, through the root of the nose, the pterion and the mastoid region.
- Meningocele is translucent, but encephalocele is not. It is tense, rounded, fluctuant, not adherent to the skin and yields an impulse on straining (crying).



Fig. 4.1: Encephalocele

JAYPEE BROTHERS

Cirsoid Aneurysm



Fig. 4.2: Cirsoid aneurysm

- It is a painful, pulsating swelling, which is formed of arterial malformation (hamartoma)
- The commonest site is the side of the scalp (superficial temporal artery)
- It is elongated, tender, not attached to the skin or the skull (**Figure 4.2**).
- It empties easily on pressure and refills very rapidly on releasing the pressure.
- A thrill may be felt and a bruit may be heard.
- The skull may show a bone defect.
- An angiogram is essential as it may show an intracranial extension, i.e. the feeding artery may be an intracerebral vessel.

Acquired Masses

Traumatic

Cephalohematoma

- It usually occurs in neonates after traumatic labor and in infants after direct trauma.
- Absence of signs of inflammation excludes abscess and lack of in size with crying excludes meningocele
- It may be subcutaneous, subgaleal (subaponeurotic) or subperiosteal
  1. Subcutaneous hematoma: It is always small and limited because the SC of the scalp is dense and fibrous and does not allow effusion of much blood.
  2. Subaponeurotic hematoma: It is always diffuse because the aponeurosis of the occipitofrontalis muscle (galea aponeurotica) is loosely attached to the underlying periosteum by a very loose areolar layer. The hematoma will be limited by the attachment of the aponeurosis to the superior nuchal line behind and to the superior temporal lines on either side. However, anteriorly, the hematoma can extend into the two upper eyelids causing black eyes.
  3. Subperiosteal hematoma: It spreads under the periosteum taking the shape of the bones underneath because it is limited by the attachment of the periosteum at the suture lines. It is usually accompanied by a fissure fracture of the bone and may act as a 'safety valve hematoma' preventing brain compression. The hematoma is soft and fluctuant. If left for a few days, the edges become raised and hard simulating a depressed fracture, but the lip is above the level of the rest of the skull. In addition,

JAYPEE BROTHERS

the edges of a fracture are sharp, while those of a hematoma are firm and smooth. A plain X-ray is diagnostic.

Differences between subperiosteal hematoma and depressed fracture

Subperiosteal hematoma	Depressed fracture
1. Center of hematoma lies on same level of skull	1. The center lies below the level of the skull
2. Edge of the hematoma is firm and smooth	2. Edge of the fracture is hard, sharp and ragged
3. X-ray is diagnostic	3. X-ray is diagnostic

Inflammatory

1. **Infected granuloma:** Repeated injury of the scalp by a sharp comb, or scratching by a nail causes abrasions, which result in infection and a reaction in the skin with granulation tissue and fibrous tissue formation so that it becomes more subjected to trauma, ending in a small swelling, which is soft, strawberry colored, and covered by clots and dirty crusts. It is not malignant (sure diagnosis is by biopsy). Painting it with a silver nitrate solution causes it to shrink and disappear.
2. **Osteomyelitis of skull bones:** It is common in the mastoid region, reaching it from the middle ear due to otitis media. It is also common in skull bones close to sinuses where infection occurs, and at any site of trauma (e.g. fracture, which causes bone infection).
3. **Cock's peculiar tumor:** It is not actually a tumor, but a big sebaceous cyst in the scalp, which has been traumatized by a sharp comb causing injury and infection, thus forming "an ulcer on top of the sebaceous cyst". Repeated injury and infection causes elevation and the overlying skin ulcerates simulating a malignant ulcer (epithelioma). The edges are raised and not everted, and there is dry sebaceous material, necrotic tissue and pus. In addition, hair is attached to it.
4. **Suppuration (abscess):**
   - Subcutaneous abscess: Small and tense because of the dense fibrous tissue septae in the SC layer of the scalp.
   - Subaponeurotic (subgaleal) abscess: It may extend from the forehead to the occiput. It may also extend to the intracranial contents via the emissary veins.
   - Subperiosteal (subepicranial) abscess: Due to infection of cranial bone.
5. **Cellulitis and erysipelas:** These commonly affect the scalp.

Sebaceous Cyst

- It is an acquired retention cyst caused by obstruction of the duct of a sebaceous gland by dried sebum, or inflammatory scarring

JAYPEE BROTHERS



Fig. 4.3: Sebaceous cyst of the scalp



Fig. 4.4: Multiple cylindromas

- It is the commonest swelling in the scalp (**Figure 4.3**)
- It is usually multiple
- It has no intracranial connection, unlike some cases of dermoid cysts
- It is well localized and should be excised as it is liable to complications such as an abscess infection formation
- For clinical details refer back.

Neoplastic

1. Soft tissue swellings
   a. Lipoma: It may be subcutaneous, subaponeurotic or subperiosteal.
   b. Neurofibroma: It presents as a firm nodule along one of the scalp nerves. It may occur in the skin and SC tissues and has a soft knotty feeling. Overlying skin may be redundant (i.e. plexiform neuroma or pachydermatocele).

Differences between lipoma of the scalp and neurofibroma

Lipoma of the scalp	Neurofibroma
• Flat deep surface and a spherical superficial one	• Fusiform with the long axis along the nerve
• It causes dimpling of the skin	• Not attached to the skin and does not dimple it
• It moves in all directions	• It moves from side-to-side only
• It is soft or pseudocystic in consistency	• It is firm or soft in consistency

   c. Hemangioma: It is bluish and compressible.
   d. Turban tumor: An irregular mass that covers the whole scalp, looking like a 'turban' and caused by:
      i. Multiple cylindromas (the commonest cause): Present as firm pink nodules in the scalp (**Figure 4.4**).
      ii. Nodular multiple basal cell carcinoma (BCC): Firm, retain the pearly white appearance and covering of fine blood vessels.
      iii. Multiple hidradenoma: Multiple sweat gland tumors form soft boggy scalp swellings. Although soft, they are not fluctuant and cannot be compressed or indented.

JAYPEE BROTHERS



Fig. 4.5: Frontal bone osteoma

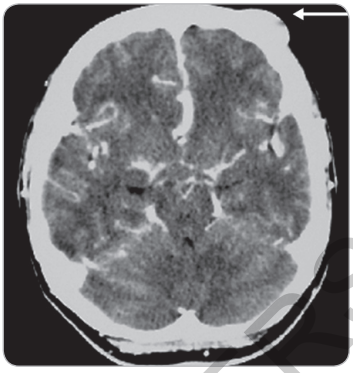

Fig. 4.6: Computed tomography of the same patient

iv. Plexiform neurofibroma (rarest): Usually associated with other neurofibroma and cafe-au-lait patches.

2. Bony swellings: Bony lesions of the skull are characterized by having no mobility whatsoever and the surrounding or underlying bone may be eroded or thickened.
   a. Ivory osteoma:
      - It is an osteoma of the cortical bone that forms the outer table of the skull (**Figure 4.5**).
      - It appears during adolescence and young adult life as a well-defined, hard swelling, but causes no symptoms.
      - It is more or less stationary in course; its onset is not related to trauma (excludes encysted hematoma), and is not accompanied by constitutional manifestations (rules out a chronic abscess).
      - Computed tomography (CT) of skull settles the diagnosis (**Figure 4.6**).
   b. Multiple myeloma:
      - Plain X-ray is diagnostic as it shows multiple or diffuse punched-out radiolucent bone defects without reaction around, i.e. osteolytic lesions scattered throughout the skull (**Figure 4.7**).
      - Other stigmata of multiple myeloma are present and confirm the diagnosis.

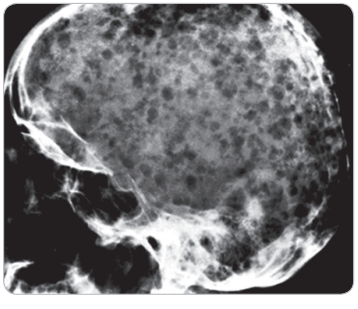

Fig. 4.7: Multiple myeloma

   c. Secondaries:
      - They are the most common tumors of the skull. Primary

JAYPEE BROTHERS

tumors that give bone metastases (blood-borne and start in the diploe) are those of the thyroid, breast, bronchi, kidneys, adrenal glands, and the prostate.

- The swellings are painful, tender, with ill-defined edges and hard consistency (or soft depending on vascularity). Some extremely vascular metastases show pulsations.
- PXR shows multiple osteolytic or osteoblastic (sclerotic) lesions (**Figure 4.8**).

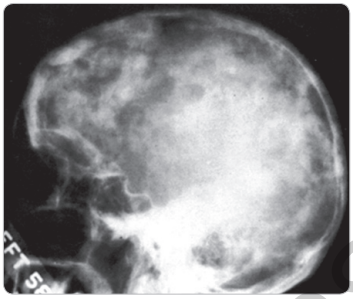

Fig. 4.8: Osteoblastic secondaries from carcinoma of the breast

Pott's Puffy Tumor

- It is not really, a tumor. It is simply 'edema' of the overlying skin and SC tissue, over an area of osteomyelitis of the skull, or in front of an intracranial lesion such as a chronic intracranial abscess in a "silent" area, so that it presents only on the outside of the skull.
- In the frontal region, it is due to imperfectly treated acute frontal sinusitis. About 10 days after the onset, considerable pyrexia with severe pain and tenderness over the sinus strongly suggests osteomyelitis.

The Following Signs are Helpful Diagnostic Guides

- The most common swelling in the scalp is sebaceous cyst. It is often multiple.
- Although an inclusion dermoid cyst is congenital, yet it usually appears during childhood and adolescence.
- The movement of the swelling over the underlying bone rules out a bony swelling.
- Transillumination is observed in meningocele.
- Hemangioma is compressible and bluish in color.
- Metastases are the most common tumor in the skull.
- A useful diagnostic approach is to determine whether the swelling is: Cystic ? Pulsating ? Solid ?

Cystic swellings
1. Sebaceous cyst
2. Inclusion dermoid cyst
3. Cephalohematoma
4. Hemangioma

Contd...

JAYPEE BROTHERS

Contd...

5. Lymphangioma
6. Abscess
Pulsating swellings
1. Cirsoid aneurysm
2. Sarcoma of the skull
3. Encephalocele
Solid swellings
A. Soft tissue swellings: 1. Lipoma 2. Turban tumor
B. Bony swellings: 1. Ivory osteoma 2. Multiple myeloma 3. Secondaries

Ulcers of the Scalp

1. Traumatic.
2. Inflammatory (osteomyelitic).
3. Ulcerated sebaceous cyst (cock's peculiar tumor).
4. Neoplastic (malignant):
   a. Epithelioma squamous cell carcinoma (SCC).
   b. Rodent ulcer (BCC).
   c. Malignant melanoma.
   d. Marjolin ulcer (squamous cell carcinoma on top of a benign ulcer).

THE FACE

Swellings of the Face

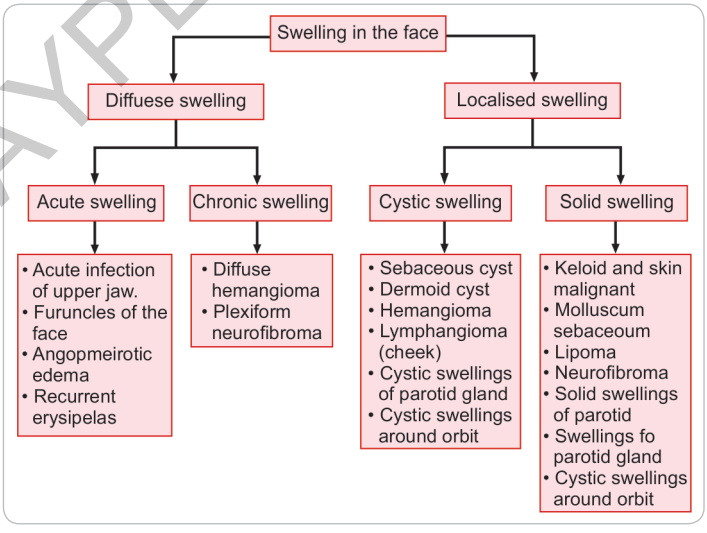

JAYPEE BROTHERS

Diffuse Swelling



Fig. 4.9: Angioneurotic edema

Acute diffuse swelling

1. **Acute infection of the upper jaws:** It is the commonest as a result of apical infection or after tooth extraction. Pain is marked, temperature is high, the swelling is diffuse and edema may close the eyes.
2. **Multiple face furuncles (furunculosis)** may lead to diffuse edema of the face.
3. **Angioneurotic edema** is allergic in nature **(Figure 4.9).**
4. **Recurrent erysipelas:** It causes repeated attacks of swelling of the face mainly the upper lip. The rosy red color, absence of lymph nodes, raised margins with peripheral vesicles and desquamation help in diagnosis.

Chronic diffuse swelling

1. Diffuse hemangioma
2. Plexiform neurofibroma.

Localized Swelling

Cystic swellings

1. Sebaceous cyst:
   - It is very common in the face of young adults with acne vulgaris, usually multiple
   - It is like a sebaceous any-where else and is liable to inflammation (**Figure 4.10**).
2. Dermoid cyst:
   - It occurs at the lines of fusion of the five parts constituting the face
   - The outer canthus is the most common site
   - Other sites are rare and include the inner canthus, at the fusion of the mandibular and maxillary processes and in the midline of the chin.
3. Hemangioma:
   - It is either capillary or cavernous, in the skin and subcutaneous tissue, or mixed
   - Early onset, bluish coloration (**Figure 4.11**)



Fig. 4.10: Inflamed sebaceous cyst in the right cheek

JAYPEE BROTHERS

and compressibility are characteristic.

4. Lymphangioma:
   - Uncommon
   - It causes thickening of the tissues of the cheek
   - It is translucent and does not empty on pressure.
5. Cystic swellings of the parotid gland (look later).
6. Cystic swellings around the orbit:
   a. **External angular (sequestration) dermoid cyst:** The outer end of the eyebrow characteristically extends over the swelling, which distinguishes it from a swelling of the lacrimal gland. The skin is mobile over the swelling, which is partly mobile. There is evident indentation of bones beneath the swelling. It is not compressible and its size does not ↑ on straining.
   b. **Inner angular dermoid cyst:** It is less common than the external angular dermoid. It lies over the root of the nose, in a more or less central position.
   c. **Swellings of lacrimal glands:** The lacrimal gland may be the seat of a tumor (similar to salivary gland tumors) or Mikulicz disease. Its position is more medial to the site of the external angular dermoid.
   d. **Swellings of the lacrimal sac:**
      - *Dacryocystitis* (lacrimal sac inflammation) causes swelling below and medial to the inner canthus.
      - *Mucocele of the lacrimal sac* is the result of blockage of the nasolacrimal duct. It results in a cystic swelling between the root of the nose and the inner canthus, accompanied by lacrimation. There is usually a history of recurrent inflammation.
   e. **Mucocele of frontal sinus:** It results from frontonasal duct blockage and lies just above and medial to the inner canthus. If it enlarges more, it displaces the globe.



Fig. 4.11: Capillary hemangioma

Solid swellings

1. **Keloid:** The lesion is elevated above the skin surface and is devoid of hair. It is unsightly, tender and usually itchy, firm, pinkish in color in its early states, but later on it becomes pale. It may give claw-like processes and the margin is ill-defined. It usually occurs at sites of previous scars, abscesses, or tuberculosis sinuses, and is particularly more common in Negroes, tuberculous patients, and pregnant women.

JAYPEE BROTHERS

2. **Malignant skin tumors:** Look Later.
3. **Lipoma:** It is SC and is similar to lipoma elsewhere. It is usually attached to the overlying skin by strands causing dimpling of the skin. It is freely mobile, soft, with lobulated surface and slippery edges.
4. **Neurofibroma:** Common in the supraorbital region and the face. It may be a firm nodule, fusiform in shape, along the course of a nerve, or it may occur in the form of a plexiform neuroma involving the skin and subcutaneous tissue. The skin may be redundant, overhanging and pigmented. Other neurofibroma and *cafe au lait* patches may be present (Neurofibromatosis)
5. **Swellings of the parotid gland** (look later).
6. **Swellings of the preauricular lymph nodes** (look later).
7. **Swellings of the jaw** (look later).

Ulcers of the Face

Classification

Ulcerative Infective Lesions		Ulcerating Tumors
Non-specific	**Specific**	
1. Chronic non-specific ulcer	1. Tuberculosis (TB)	1. Rodent ulcer (BCC)
2. Infected sebaceous cyst	2. Syphilis	2. Epithelioma (SCC)
3. Molluscum sebaceum	3. Leishmaniasis	3. Malignant melanoma
	4. Leprosy	4. Metastatic mass ulceration
	5. Actinomycosis	5. Infiltrating deeply-seated tumor, which invades the skin and ulcerates
	6. Anthrax	

Ulcerating infective lesions

Non-specific ulcers

1. **Chronic non-specific ulcer:**
   - Exuberant Type [Hypertrophic granulation tissue (GT)]: Warty-like lesion, soft, granulating tumor, bleeds easily
   - Flat Type: Painful, irregular margin, floor covered with granulation tissue (GT), firm base, purulent or serous discharge. Persistence of the cause maintains its chronicity.
2. **Infected sebaceous cyst:**
   - Long history, irregular edge, floor covered with purulent exudate, painful and firm base, hair follicle or punctum may be seen.
   - Infected sebaceous-like material comes out on squeezing.
3. **Molluscum sebaceum:**
   - Warty lesion that forms a superficial ulcer with umbilicated center, hard in consistency, long history, does not spread, lymph nodes are not enlarged.

JAYPEE BROTHERS

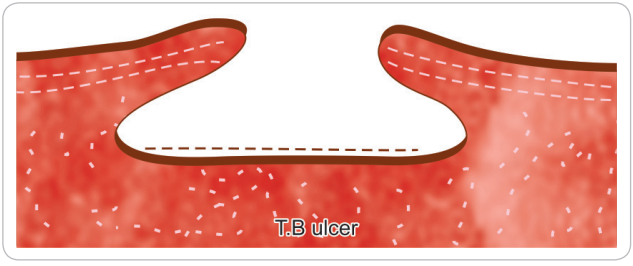

Fig. 4.12: Tuberculosis ulcer with undermined edges

- It may heal spontaneously (usually disappears within 2 months leaving behind a fibrous scar) and should be differentiated from squamous cell carcinoma.

Specific ulcers

1. **Tuberculous ulcers:**
   - These ulcers are painful.
   - **Site:** TB ulcer is common in the neck due to break down of lymph nodes, in the maxillary region due to TB of underlying bone, and in the skin of the face due to lupus vulgaris.
   - **Outline:** Irregular.
   - **Edge:** Undermined (**Figure 4.12**) and bluish, with characteristic apple-jelly nodules (in lupus vulgaris) around it.
   - **Floor:** Pale, soft, covered with unhealthy granulation tissue.
   - **Discharge:** This serous or watery.
   - Scarring may be present.
2. **Syphilitic ulcer:**

Chancre (primary syphilis)	Gumma (painless) (tertiary syphilis)
• *Site*: It occurs on the lips, nose, or eyelids • Surrounded by marked edema • Associated with enlarged lymph nodes • Swab examination shows spirochetes	• *Site*: Common in frontal region • *Margin*: Circular or serpiginous • *Edge*: Punched out (steep sides) **(Figure 4.13)**. • *Floor*: Wash leather • *Skin Around*: shows pigmentation and scar • Fixed to bone and plain X-ray shows bone sclerosis • Other stigmata of syphilis are present • WR reaction is positive

3. **Leishmaniasis (oriental sore):**
   - A slowly progressive, painless, ulcer that may occur anywhere in the face (exposed to mosquito bites)
   - May be raised above the surface and have a cauliflower-like appearance

JAYPEE BROTHERS

for detailed information on surgery books, visit our website www.jaypeebrothers.com, fo

Clinical Surgery

This book comprises 13 chapters that consider the clinical approach and diagnosis of different subjects related to clinical surgery; namely, introduction to surgical case sheet, approach to certain clinical problems, skin and subcutaneous tissue, head and neck, chest wall and breast, dysphagia, anterior abdominal wall and umbilicus, abdomen, hernia, anorectal surgery, vascular surgery, urosurgery, neurosurgery, and orthopedic surgery.

How to reach diagnosis using history taking, physical examination, and appropriate investigations, with the possible differential diagnosis in mind is clearly presented and illustrated in this book. Bibliography is also provided for further reading.



Mahmoud Sakr MSc PhD FAGE graduated in 1981 and completed his Masters and Doctorate Degree (PhD) in Surgery at the Faculty of Medicine, Alexandria University, Egypt. He had his fellowship in Surgery and Organ Transplantation at the University of Pittsburgh School of Medicine, Pennsylvania, USA. He is a fellow of the International College of Surgeons (ICS) and American College of Surgeons (ACS) and is currently the Chief, Department of Head & Neck and Endocrine Surgery at the Faculty of Medicine, Alexandria University, Egypt. He has published more than 12 surgical books as well as 90 articles in esteemed journals and has been serving as an editorial board member of repute.

Available at all medical bookstores or buy online at www.jaypeebrothers.com



JAYPEE BROTHERS
Medical Publishers (P) Ltd.
www.jaypeebrothers.com

Join us on facebook.com/JaypeeMedicalPublishers

Shelving Recommendation
SURGERY

