on obstetrics & gynecology books, visit our website **www.jaypeebrothers.com,** for detailed information on obstetric

JAYPEE

Manual on Cervical Cytology and Colposcopy

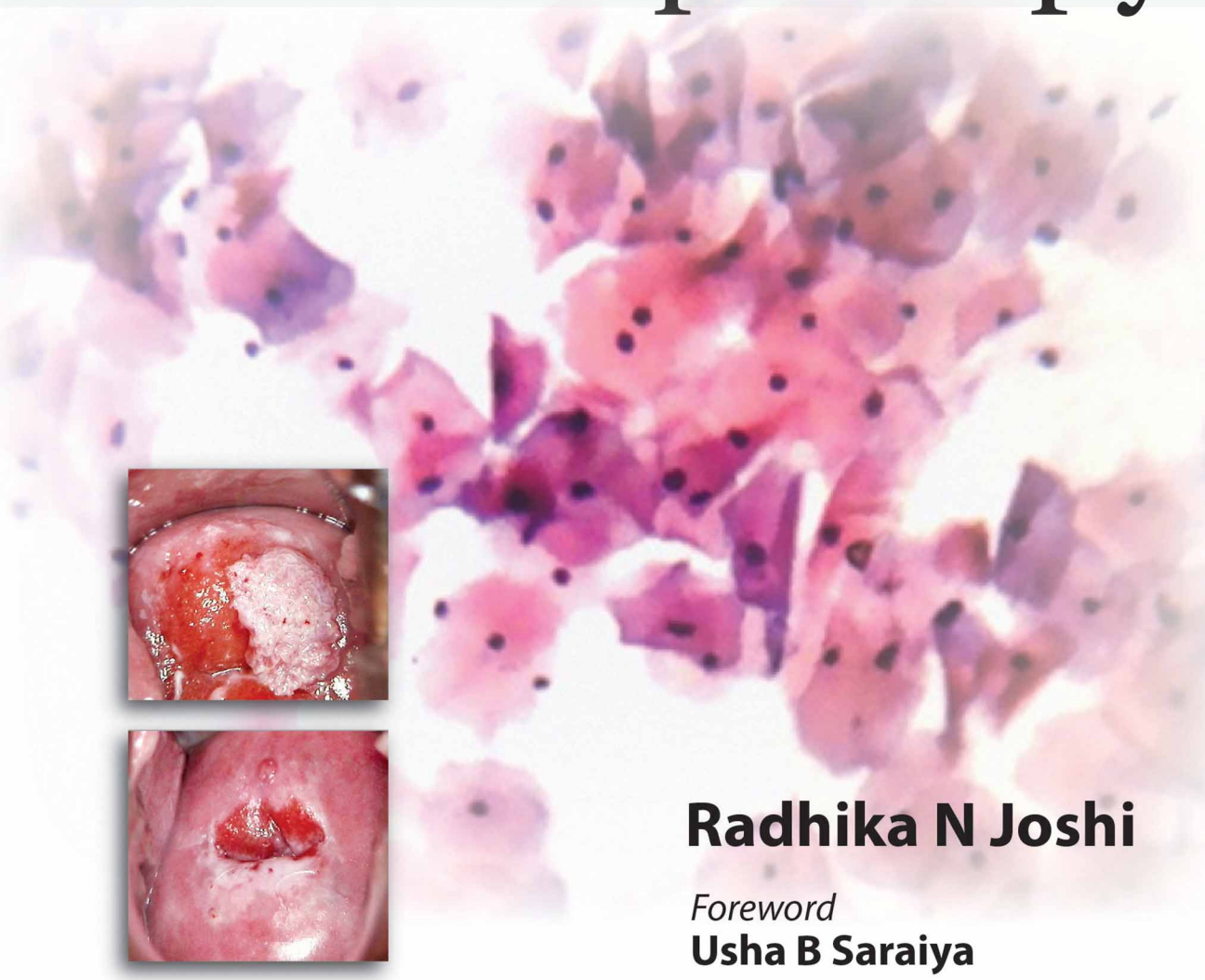

Radhika N Joshi

Foreword
Usha B Saraiya

Contents

Chapter 1: Cervical Cytology 1

- **History 1**
  - *Indian History 1*
- **Pap Smear 1**
- **Papanicolaou's Staining Technique 5**
  - *Preparation of Stains 5*
- **Interpretation of Smears 7**
  - *Cytological Description of Different Cells 7*
  - *Infections and Infestations 8*
  - *Atypical Squamous Cells of Undetermined Significance 8*
  - *Low Grade Squamous Intraepithelial Lesion 9*
  - *High Grade Squamous Intraepithelial Lesion 9*
  - *Microinvasive and Invasive Carcinoma 9*
  - *Glandular Cells 9*
  - *ASCUS 14*
- **Reporting of the Smear 15**
  - *Papanicolaou's Classification 15*
  - *WHO Classification 15*
  - *CIN Classification of Richart 15*
  - *The Bethesda System (TBS) 2001 15*
  - *Classification of Smears 17*
- **Liquid Base Cytology 17**
- **Visual Inspection 18**
  - *Diagnosis by Visual Inspection 18*
  - *VIA (Visual Inspection with Acetic Acid) Usefulness 18*
  - *VIA Advantages 18*
  - *New Technologies 19*
  - *Visual Inspection with Acetic Acid (VIA): Negative 20*
  - *Visual Inspection with Acetic Acid (VIA): Positive 22*
  - *Visual Inspection with Lugol's Iodine (VILI) 24*
- **Management of smears 25**
  - *Epithelial Cell Abnormalities 25*
- **Record Sheet 27**
  - *Gynecological Cytology 27*

Chapter 2: Colposcopy 28

- **History and Introduction to Colposcopy 28**
- **Indication for Colposcopy 28**
  - *Routine Colposcopy 29*
- **The Colposcopic Examination 29**
  - *Colposcopy Patients Information 30*
  - *Instruments 30*
  - *Steps in the Colposcopic Examination 32*
  - *Observation of Cervix 33*
  - *Colposcopy Record Form 33*
- **Colposcopic Findings 44**
  - *Copplesons Grading 44*
  - *Colposcopic Findings Ratified by International Federation of Cervical Pathology and Colposcopy 2003 44*
  - *Normal Colposcopic Finding 45*
  - *Abnormal Colposcopic Findings 45*
- **Transformation Zone 46**
  - *Atypical Transformation Zone (ATZ) 47*
  - *The New Transformation Zone (NTZ) Classification (IFCPC) 49*
  - *Reid's Colposcopic Index (RCI) 49*
  - *Newer Scoring System: The Swede Score 50*
- **Angiogenesis 50**
- **Vaginal Coloposcopy 51**
  - *Technique 51*
  - *Findings 51*
- **Colposcopy of Vulva 52**
- **Management of CIN 53**
  - *Management of Benign Lesion 53*
  - *Biopsy of Cervix 54*
  - *Prophylactic Management (CIN) 54*
  - *Management of Early CIN – LSIL 54*
  - *Tissue Distruction (Ablation) 55*
  - *Surgical Removal (Excision) 55*
  - *Cryotherapy 55*
  - *Light Amplification by Stimulated Emission of Radiation (LASER) 60*
  - *Electrocoagulation 60*
  - *Cone Biopsy 61*
  - *LLETZ 61*
- **Human Papilloma Virus (HPV), DNA Detection 67**
  - *HPV Cervical Cancer 67*
  - *HPV Testing 67*
  - *Method 68*
- **Recommendations 69**
  - *WHO Recommendations 69*

- **Setting up Practice in Cervical Cytology and Colposcopy 70**
  - *Organization of Clinic 70*
  - *Organization of Laboratory 71*
  - *Starting Work 71*
- **Cancer Detection Camps 71**
- **Breast 72**
  - *Prevention of Carcinoma of Breast: Self Examination, Fine Needle Aspiration Cytology (FNAC), Mammography 72*
  - *FNAC of Breast 73*
  - *Utility of FNAC 74*
- **FOGSI Recommendation for Vaccinations against HPV 74**
  - *Preamble 74*
  - *General 74*
  - *Cervical Cancer Screening 74*
  - *Vaccination Target Group 74*
  - *Dosage Schedule 75*
  - *Counseling before Vaccine 75*
  - *Vaccinating Sexually Active Women 75*
  - *Special Situations 75*
  - *Pregnancy and Lactating Women 75*
  - *Immunosuppressed Patients 76*
  - *Contraindications and Precautions 76*
- **Preparations of Chemicals 76**
  - *Preparation 76*
  - *Label 76*
  - *Lugol's Iodine Solution 76*
  - *Monsel's Paste 77*
- **International Federation for Cervical Pathology and Colposcopy (IFCPC) 77**
  - *2011 IFCPC Nomenclature 77*
- **Organization of Colposcopic Services 78**

Chapter 3: Case Studies 79

Index 103

CHAPTER 3

Case Studies

CASE NO. 1

A 25-year-old multiparous lady was referred to our clinic for irregular bleeding per vaginam. She had history of two full term normal deliveries and two medical terminations of pregnancy. Dilatation and curettage was done 3 years back.

Her colposcopy shows acetowhite lesions which does not take Lugol's iodine stain. HPV was not detected.

Pap smear report was low grade squamous intraepithelial lesion (LSIL).

Loop electrosurgical excision procedure (LEEP) was done under local anesthesia.

Colposcopy

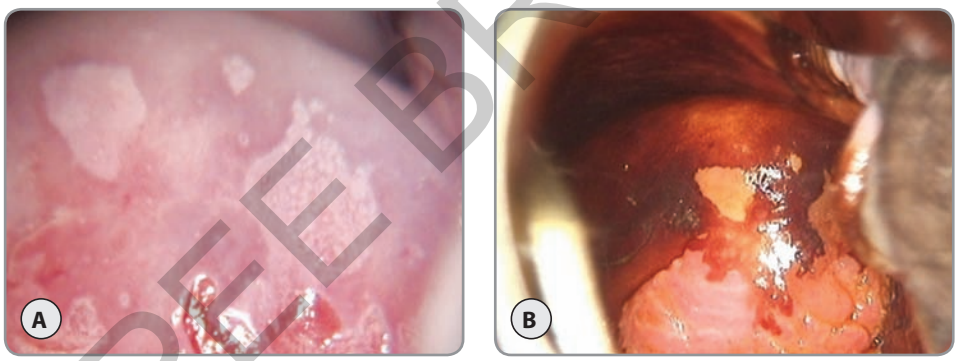

Figs 3.1A and B: Anterior lip

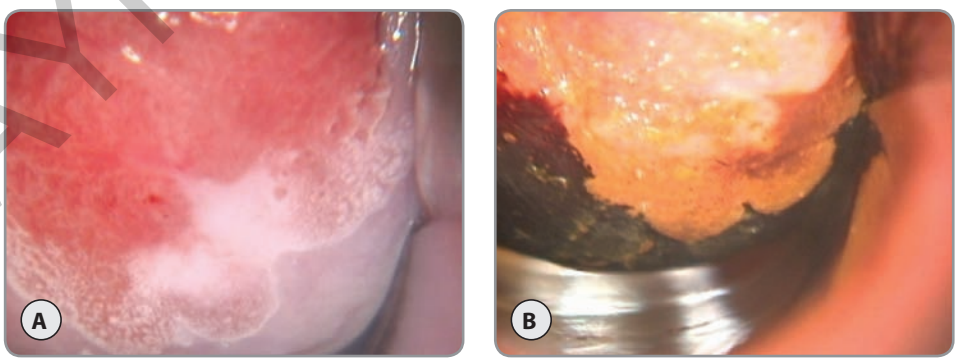

Figs 3.2A and B: Posterior lip

Histopathology: Chronic nonspecific cervicitis, CIN I changes.

JAYPEE BROTHERS

CASE NO. 2

A 33-year-old lady with irregular bleeding. She has one lower segment cesarean section and she is interested in conceiving again. Colposcopy reveals raised ectopy with acetowhite area on posterior lip.

Pap smear was negative for intraepithelial lesion or malignancy (NILM).

Biopsy from the posterior lip acetowhite area was taken without disturbing the OS with loop electrode.

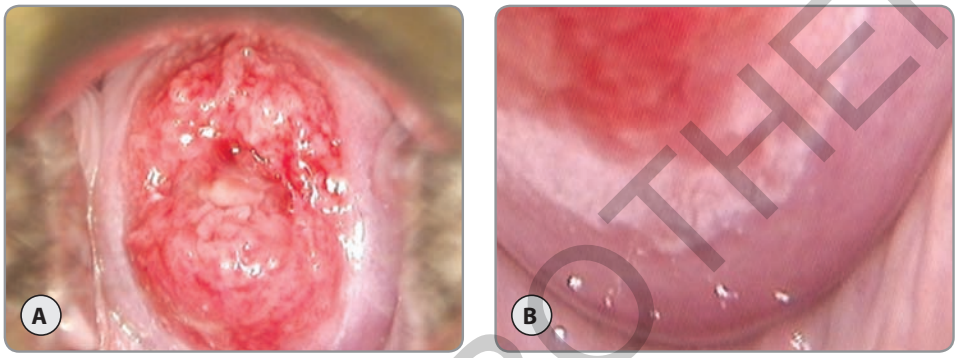

Figs 3.3A and B: Posterior lip—acetowhite area

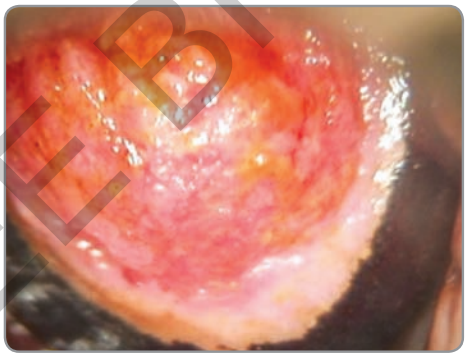

Fig. 3.4: Posterior lip—Lugol's iodine

Histopathology: Chronic nonspecific endocervicitis.

JAYPEE BROTHERS

CASE NO. 3

A 43-year-old multiparous lady was complaining of post coital bleeding and menorrhagia. Cervix shows big ectopy with metaplasia and small multiple polyps in endocervix. Endocervix bleeding on touch.

Pap smear was unsatisfactory because of blood.

LEEP procedure was done under local anesthesia.

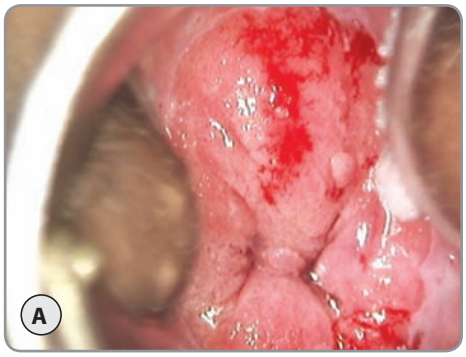

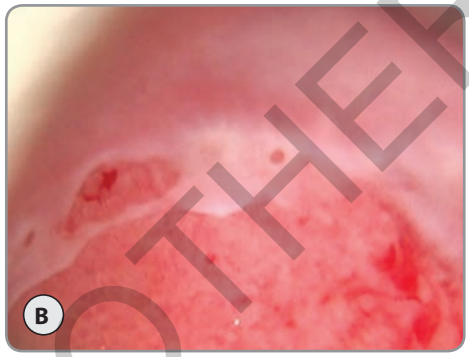

Figs 3.5A and B: Anterior lip

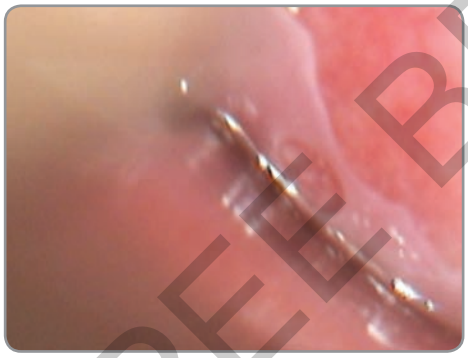

Fig. 3.6: Lower right quadrant

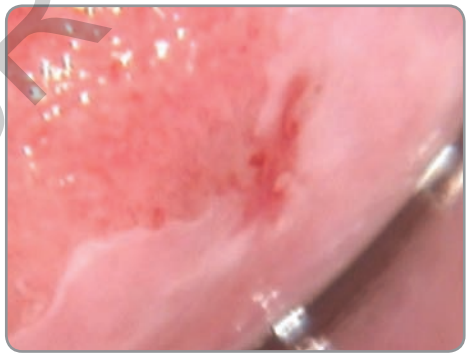

Fig. 3.7: Left lower quadrant

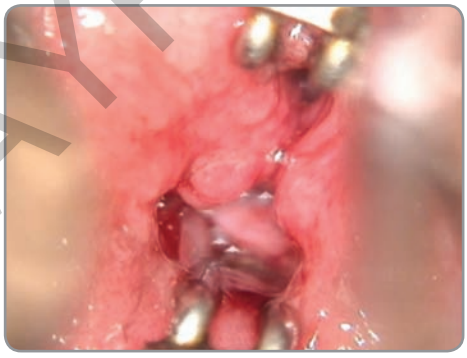

Fig. 3.8: Endocervical polyp

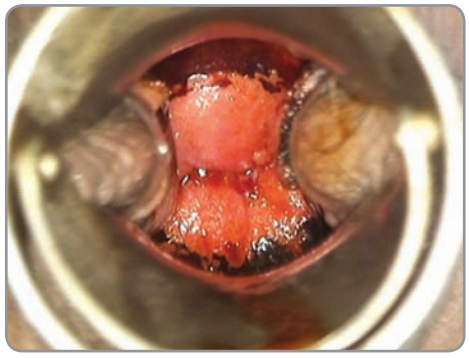

Fig. 3.9: Lugol's iodine

Histopathology: Chronic nonspecific papillary endocervicitis with CIN II changes.

JAYPEE BROTHERS

CASE NO. 4

An 36-year-old lady came in outpatient department with abdominal pain and post coital bleeding. She had thick acetowhite area on posterior lip.

Pap smear report was ASCUS (atypical squamous cells of undetermined significance).

Large loop excision of transformation zone (LLETZ) procedure was done.

Colposcopy

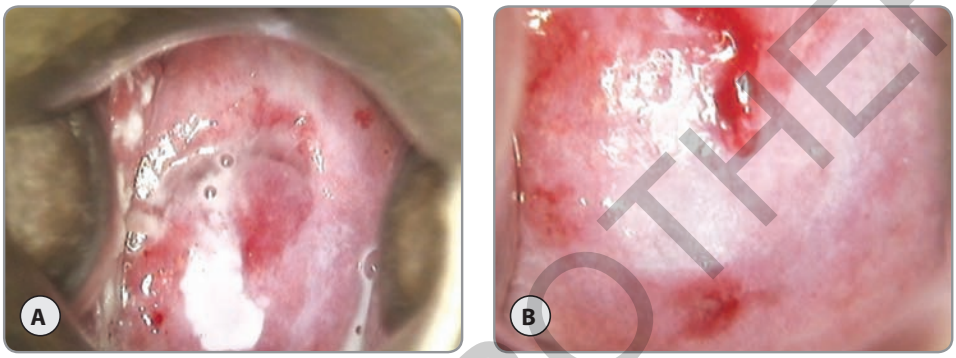

Figs 3.10A and B: Posterior lip acetowhite patch

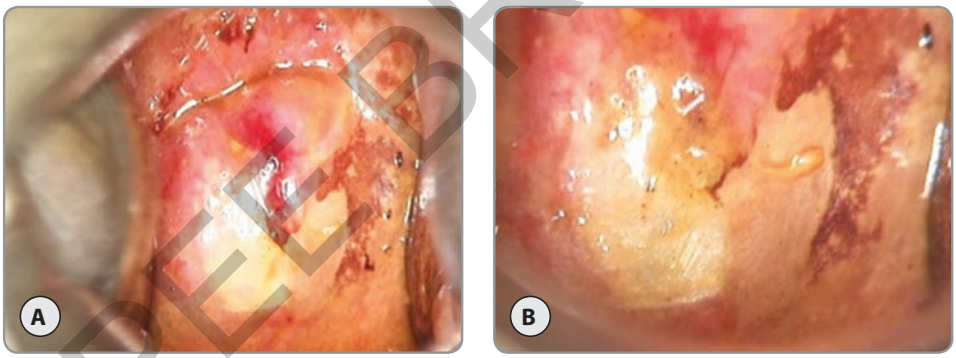

Figs 3.11A and B: Unstained posterior lip

Histopathology: LLETZ showed CIN II changes.

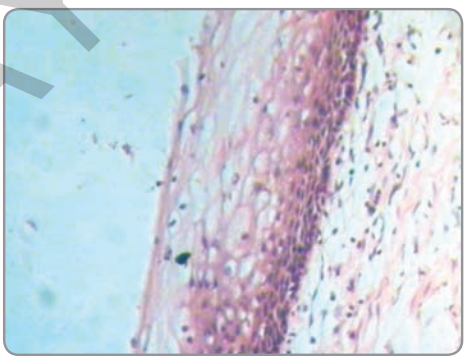

Fig. 3.12: CIN II

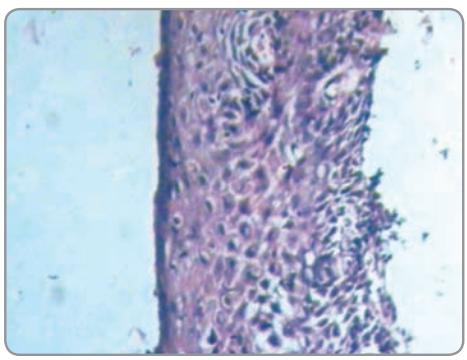

Fig. 3.13: Basal cell hyperplasia

JAYPEE BROTHERS

CASE NO. 5

A 32-year-old lady with menorrhagia and premenstrual spotting.

Colposcopy shows ectopy which bleeds on touch and acetowhite area on posterior lip.

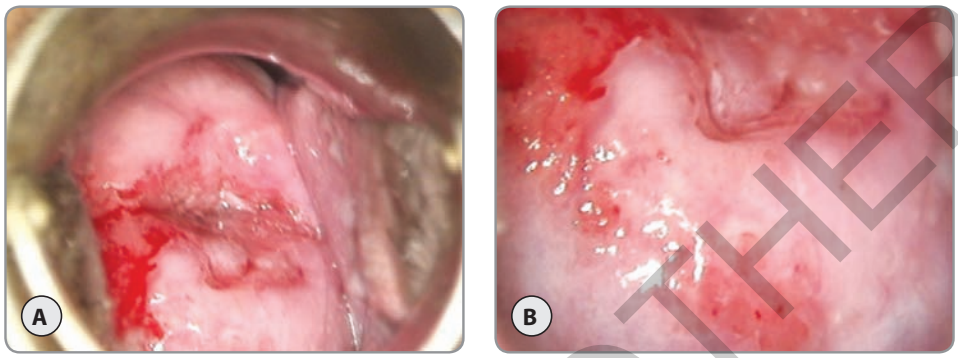

Figs 3.14A and B: Posterior lip

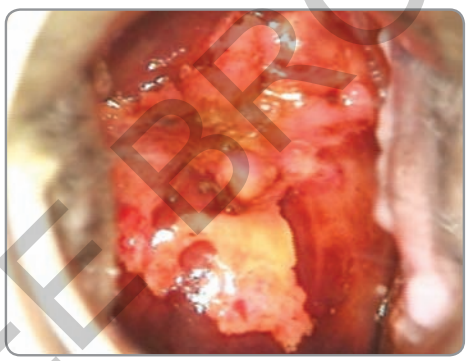

Fig. 3.15: Lugol's iodine

Histopathology: Showed CIN II.

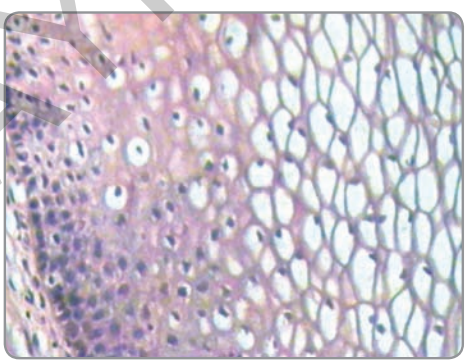

Fig. 3.16: Koilocytosis

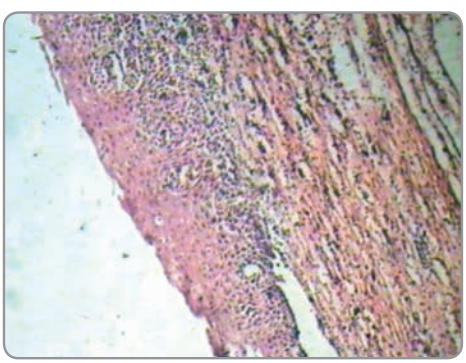

Fig. 3.17: CIN II

JAYPEE BROTHERS

CASE NO. 6

A 30-year-old patient comes with complains of irregular bleeding per vagina and post coital bleeding. She was married at the age of 15 year and has 3 children (risk factors here are early age of marriage and early child bearing).

The cervical tissue bled at the slightest touch and that is why patient was referred for colposcopy. Colposcopy shows many bleeding areas, acetowhite and gray areas.

Biopsy was taken with diathermy loops.

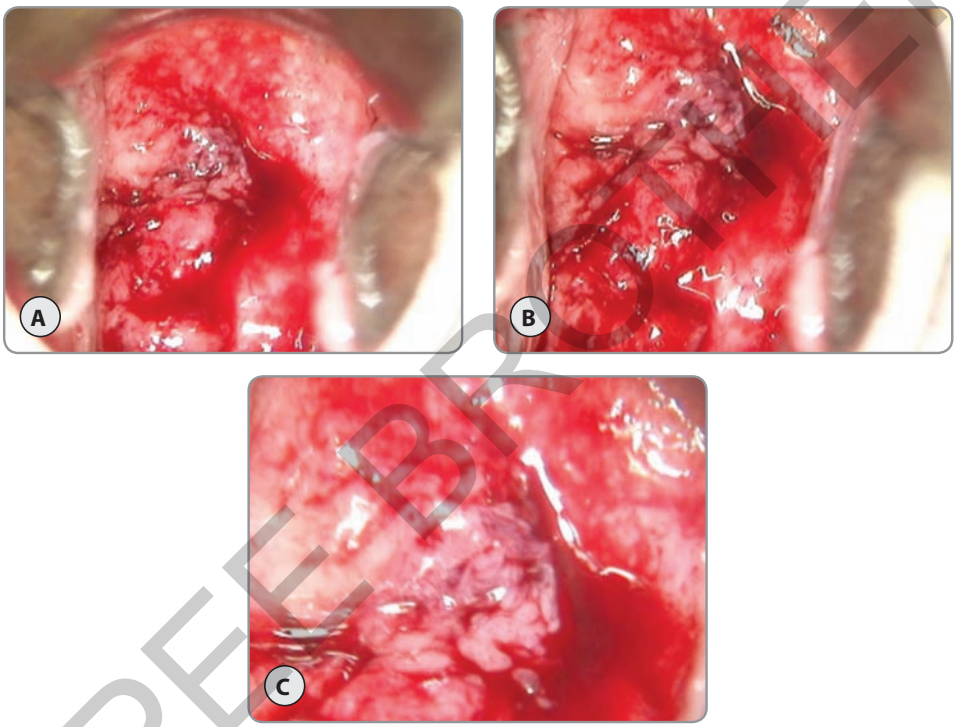

Figs 3.18A to C: Biopsy from irregular cervix

Histopathology: Showed adenocarcinoma.

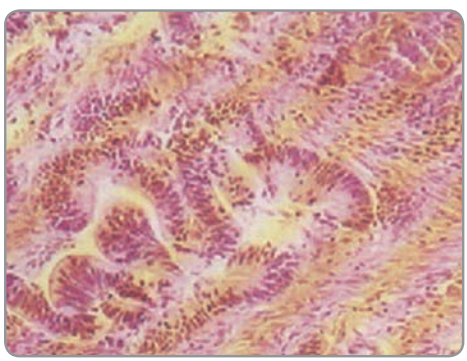

Fig. 3.19: Histopathology adenocarcinoma

JAYPEE BROTHERS

CASE NO. 7

A post menopausal lady was referred for change on Pap smear and irregular bleeding .Colposcopy showed irregular vessels, ectopy, acetowhite posterior lip and small polyp in endocervical region.

Pap smear report showed ASCUS changes.

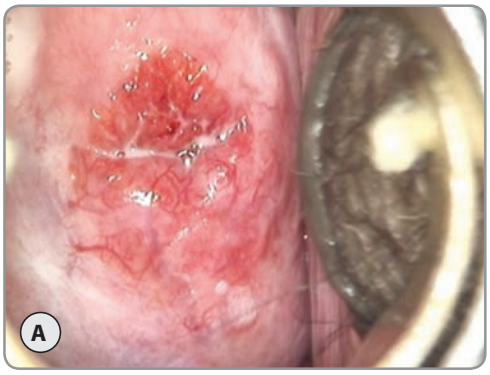

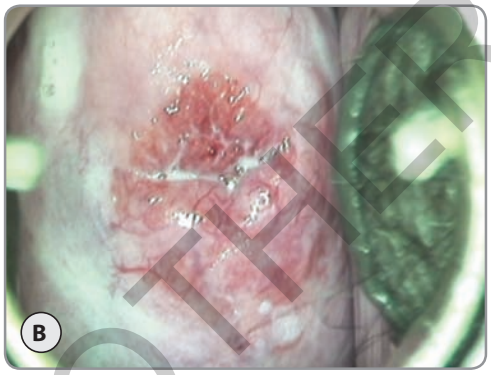

Figs 3.20A and B: Ectopy with vessels



Fig. 3.21: Vessels on posterior lip



Fig. 3.22: Polyp

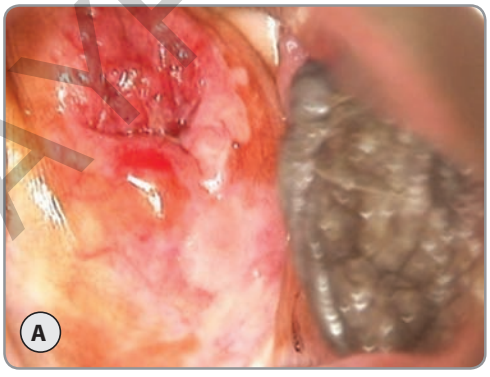

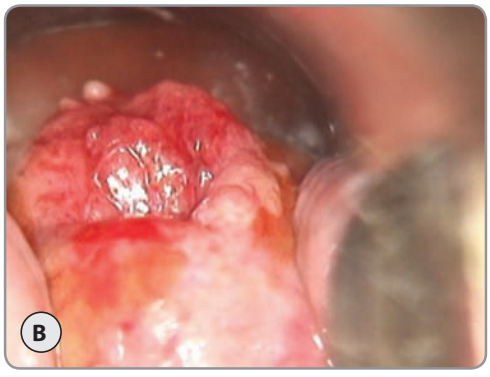

Figs 3.23A and B: Endocervical polyp

Histopathology: Chronic nonspecific cervicitis with ASCUS changes.

JAYPEE BROTHERS

CASE NO. 8

A 36-year-old lady with complaint of leukorrhea and spotting comes for check up. Her Pap smear is negative for intraepithelial lesion or malignancy. Her colposcopy shows acetowhite and iodine non-staining area on both lips.



Fig. 3.24: Acetowhite area on anterior lip

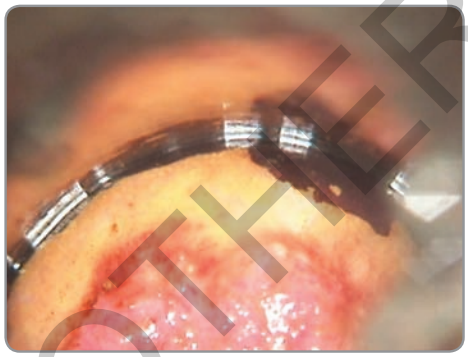

Fig. 3.25: Unstained anterior lip

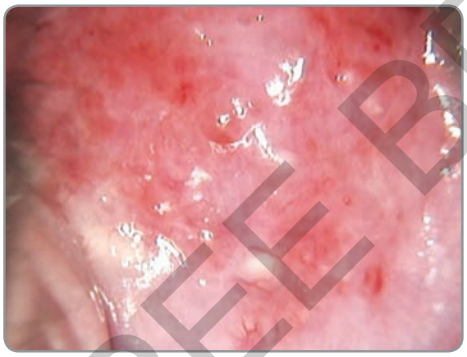

Fig. 3.26: Posterior lip

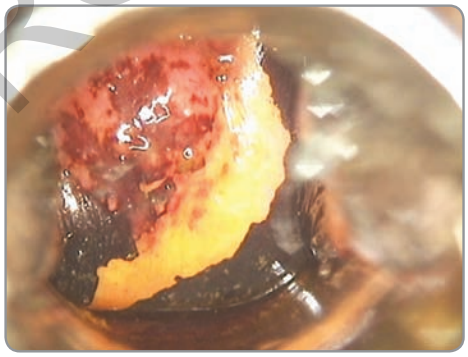

Fig. 3.27: Unstained posterior lip

Histopathology: Chronic nonspecific cervicitis with CIN II changes.

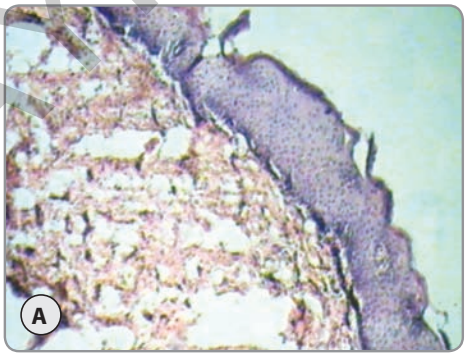

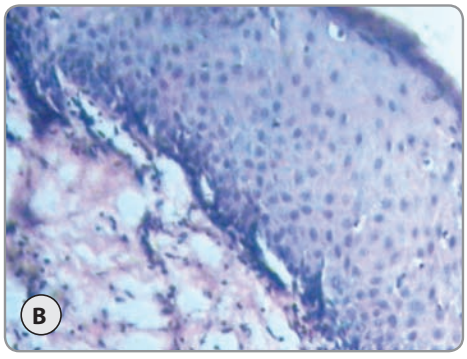

Figs 3.28A and B: CIN II

JAYPEE BROTHERS

CASE NO. 9

A 32-year-old para II IUCD user is referred to colposcopy clinic for bleeding per vaginam. Colposcopy showed ectopy with gland openings, squamous metaplasia and acetowhite area.

Pap smear is reported LSIL.

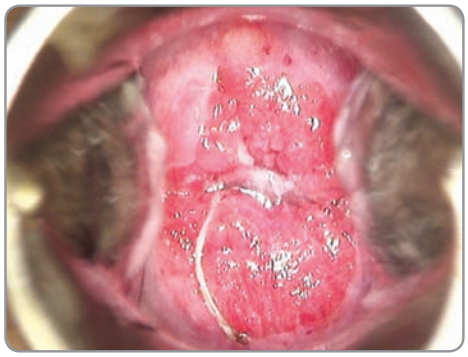

Fig. 3.29: Ectopy



Fig. 3.30: Gland opening

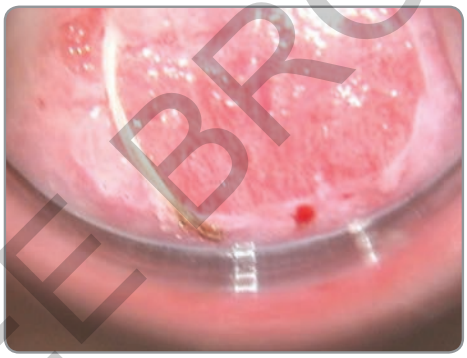

Fig. 3.31: Posterior lip

Histopathology: Chronic nonspecific cervicitis with CIN I changes.

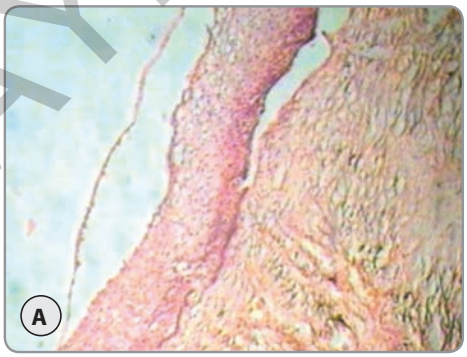

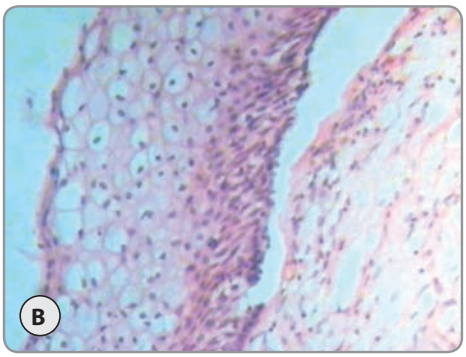

Figs 3.32A and B: Koliocytosis

JAYPEE BROTHERS

CASE NO. 10

A patient was referred for colposcopy by a gynecologist because she had *LSIL (low grade squamous intraepithelial lesion) on routine Pap smear.* She was premenopausal. Colposcopy showed ectopy which bled on touch, many gland opening and vessels. Biopsy shows chronic nonspecific cervicitis with CIN II changes. **Cryocauterization was done afterwards to treat the lesion completely.**



Fig. 3.33: Ectopy

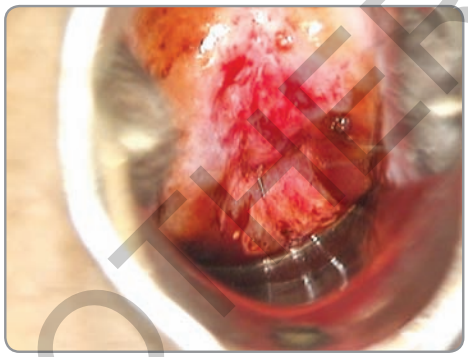

Fig. 3.34: Unstained areas

Histopathology: Chronic nonspecific cervicitis with CIN II changes.

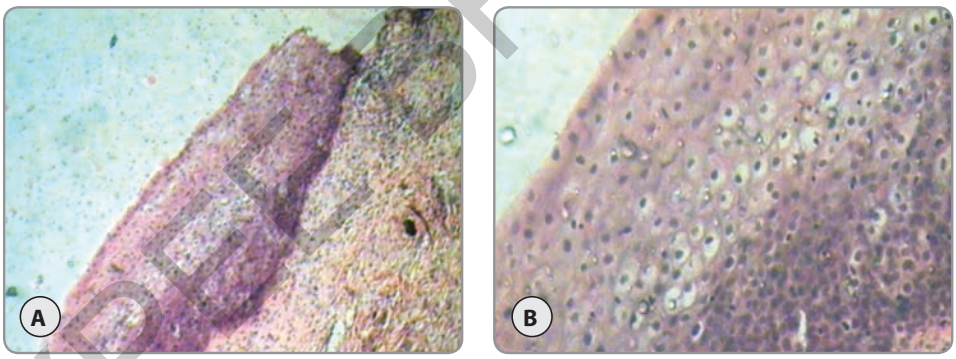

Figs 3.35A and B: Koilocytosis and basal cell hyperplasia

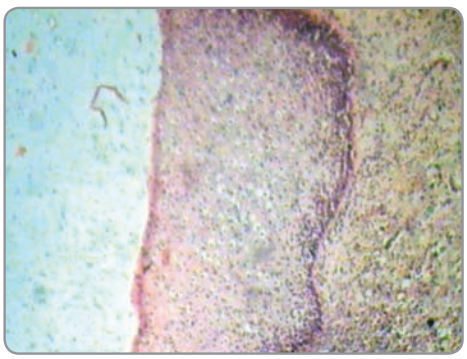

Fig. 3.36: Histopathology

JAYPEE BROTHERS

CASE NO. 11

A 57-year-old menopausal lady with spotting was referred to colposcopy clinic by a gynecologist. Her colposcopy showed acetowhite areas on both lips.

Pap smear showed HSIL (high grade squamous intraepithelial lesions).

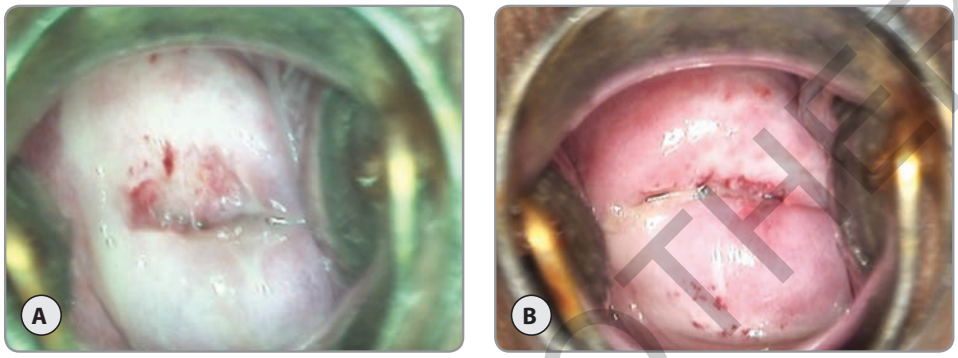

Figs 3.37A and B: Green filter

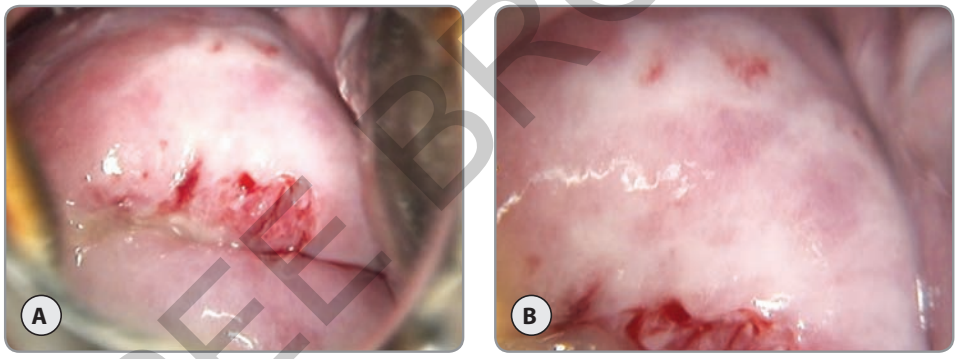

Figs 3.38A and B: Acetowhite area



Fig. 3.39: Posterior lip

Histopathology Report: Chronic nonspecific cervicitis (with CIN II changes).

JAYPEE BROTHERS

CASE NO. 12

A 25-year-old lady comes with complaints of post coital bleeding . She is married of the age at 15 year and has 2 children and 2 abortions. She had ectopy, metaplasia and acetowhite area on posterior lip she was very keen on definitive treatment.

Pap smear showed ASCUS change.

Since she had significant post coital bleeding, LLETZ was done and report showed koilocytotic changes.

Colposcopy

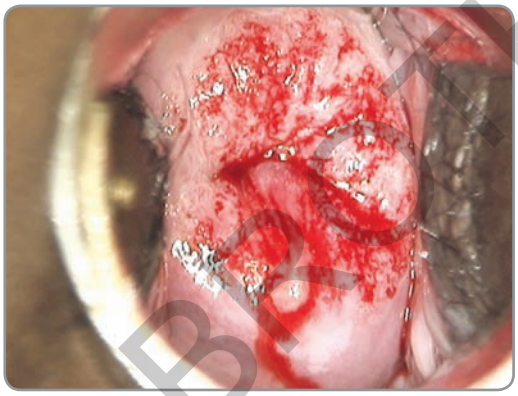

Fig. 3.40: Ectopy

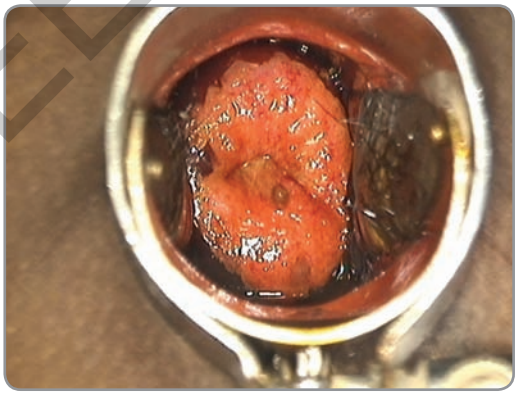

Fig. 3.41: Unstained ectopy

Histopathology: Chronic nonspecific cervicitis with koilocytosis.

JAYPEE BROTHERS

r detailed information on obstetrics & gynecology books, visit our website **www.jaypeebrothers.com,** for detailed in

Manual on Cervical Cytology and Colposcopy

Manual on Cervical Cytology and Colposcopy covers the syllabus prescribed by FOGSI for this course. It is a useful guide by the side of the patient. Visual inspection section is covered completely because colposcopy is not available at many clinics. What a gynecologist needs to know about Papanicolaou cytology is discussed. Practical colposcopy is covered completely with many colpophotographs. HPV sampling technique is described. There are many case studies included in the book. A clinician doing cloposcopy will be helped by this book and will not face any practical problem.

Radhika N Joshi is the first colposcopist in Kolhapur, Maharashtra, India. Her aim is to view as many cervices as possible and establish colposcopy centers in India to help prevent cervical cancer. She is an avid traveler who is ready to travel to any corner of the country to train gynecologists and nursing staff in colposcopy and early detection methods.



Available at all medical bookstores or buy online at www.jaypeebrothers.com

JAYPEE BROTHERS
Medical Publishers (P) Ltd.
www.jaypeebrothers.com

Join us on facebook.com/JaypeeMedicalPublishers

Shelving Recommendation
OBSTETRICS & GYNECOLOGY

ISBN 978-93-5152-764-0