Surgical Techniques in Otolaryngology—Head & Neck Surgery

HEAD & NECK SURGERY

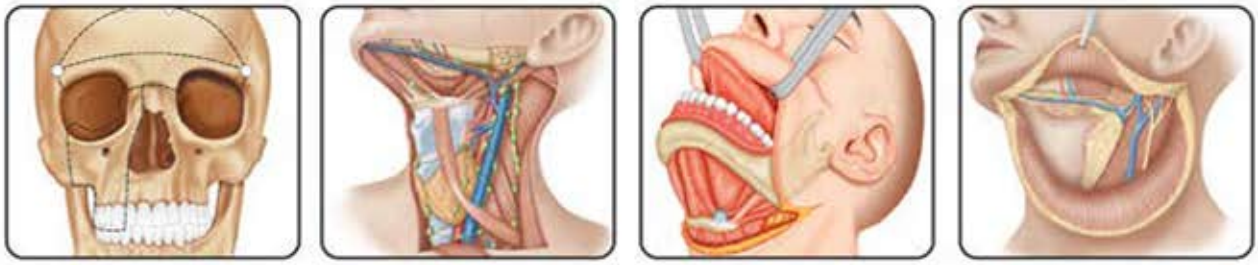

Series Editor

Robert T Sataloff

David Goldenberg

JAYPEE

SURGICAL TECHNIQUES IN
OTOLARYNGOLOGY
HEAD AND NECK SURGERY

Series Editor: **Robert T Sataloff** MD DMA FACS

HEAD AND NECK SURGERY

Author

David Goldenberg MD FACS
Chief, Division of Otolaryngology—Head and Neck Surgery
Steven Baron Professor of Surgery and Medicine
Division of Otolaryngology—Head and Neck Surgery
The Penn State University
Milton S Hershey Medical Center
Hershey, Pennsylvania, USA

JAYPEE BROTHERS



The Health Sciences Publisher
Philadelphia | New Delhi | London | Panama

Contents

Section 1: Sinonasal Cancer
Section Editor: *Francis Hall*

1. Medial Maxillectomy **3**

Robert Deeb

- Overview *3*
- Indications *3*
- Surgical Techniques *4*
- Postoperative Care *7*
- Complications *7*

2. Endoscopic Medial Maxillectomy **9**

Liat Shama, Francis Hall

- Evolution *9*
- Indications *9*
- Imaging *10*
- Contraindications *10*
- Equipment and Setup *11*
- Operative Steps *11*
- Maxillary Antrostomy *11*
- Endoscopic Medial Maxillectomy *12*
- Modified EMM *13*
- Preservation of the Inferior Turbinate *14*
- Preservation of the Nasolacrimal Duct *14*
- Pterygopalatine and Infratemporal Fossa *14*
- Postoperative Care *14*

3. Maxillectomy **19**

Rosemary B Ojo, Ralph Abi-Hachem, Bradley J Goldstein

- Anatomy *19*
- Vasculature *20*
- Nerves *21*
- Orbital Detail *21*

JAYPEE BROTHERS

- Surgical Procedures *21*
- Total Maxillectomy *21*
- Surgical Steps *22*
- Orbit *26*
- Closure and Reconstruction *26*
- Postoperative Care *27*
- Complications *28*

4. Anterior Craniofacial Resection **31**

Francis Hall, Ian Lee

- Presentation and Investigation *32*
- Patient Selection *33*
- Planning for Surgery *33*
- Postoperative Care *41*
- Complications *41*
- Results *43*

5. Endoscopic Anterior Skull Base Resection and Endoscopic Repair of Skull Base Defects **45**

Liat Shama, Francis Hall

- Endoscopic Anterior Skull Base Resection *45*
- Endoscopic Repair of Skull Base Defects *49*

Section 2: Oral Cavity and Oropharynx
Section Editor: *Steven S Chang*

6. Surgical Management of Lip Cancer **55**

Theresa Guo, Steven S Chang

- Background *55*
- Anatomy *56*
- Treatment *57*
- Postoperative Care *63*

7. Floor of Mouth Resection **65**

Sun M Ahn, Steven S Chang

- Relevant Anatomy *65*
- Surgical Considerations *66*
- Surgical Technique *66*

8. Surgical Management of Oral Tongue Cancer **71**

Chris R Roxbury, Steven S Chang

- Relevant Anatomy *71*
- Evaluation of the Patient/Indications for the Procedure *72*

JAYPEE BROTHERS

- Surgical Technique *73*
- Surgical Management of the Neck *74*
- Complications, Functional Consequences, and Postoperative Considerations *75*

9. Composite Resection **77**

Jason YK Chan, Eddy WY Wong, Alexander C Vlantis

- Background and History *77*
- Indications *77*
- Physical Examination *77*
- Imaging *77*
- Surgical Procedure *78*
- Reconstruction of the Defect *81*
- Complications *83*

10. Mandibulotomy **85**

Ryan Orosco, Steven S Chang

- Indications and Patient Selection *85*
- Mandibulotomy Surgical Technique *86*
- Reconstruction *88*
- Postoperative Care and Complications *89*

11. Segmental and Marginal Mandibulectomy **91**

Ryan Orosco, Steven S Chang

- Segmental versus Marginal Mandibulectomy *91*
- Indications and Patient Selection *91*
- Surgical Technique *93*
- Reconstruction *96*
- Postoperative Care *97*

Section 3: Surgery of the Larynx and Hypopharynx
Section Editor: *David Goldenberg*

12. Surgery for Larynx Cancer **101**

Richard Goldman, Joseph Curry, Adam Luginbuhl, David Cognetti

- Anatomy *101*
- Function *102*
- Open Partial Laryngectomy *102*
- Total Laryngectomy *111*

13. Surgery for Hypopharyngeal Cancer **119**

Kim Atiyeh, David Myssiorek

- Anatomy *119*
- Pathology *120*
- Behavior of Hypopharyngeal Cancer *120*

JAYPEE BROTHERS

- Treatment of Hypopharyngeal Cancers *120*
- Transoral Approach to the Hypopharynx *126*
- Total Laryngectomy with Partial Pharyngectomy *128*
- Treatment of the Neck *130*

14. Microlaryngoscopic Laser Excision of Glottic Malignancies **133**

Garret W Choby, Robert L Ferris

- Indications *133*
- Surgical Technique *133*

15. Transoral Robotic Surgery of the Larynx **139**

J Kenneth Byrd, Robert L Ferris

- Limitations *140*
- Preoperative Planning *140*
- Contraindications *140*
- TORS Supraglottic Laryngectomy: Surgical Procedure *140*

Section 4: Neck Dissections
Section Editor: *Neerav Goyal*

16. Radical Neck Dissection **145**

Ali Khaku, David Goldenberg, Frank G Garritano

- Classification, Pertinent Anatomy, and Surgical Landmarks by Level *145*
- Indications *148*
- Contraindications *149*
- Treatment *149*
- Risk Factors and Complications *154*
- Postoperative Care *156*

17. Modified Radical Neck Dissection **159**

Darrin V Bann, Benjamin Oberman, David Goldenberg

- Anatomy *159*
- Indications *162*
- Surgical Technique *162*
- Postoperative Care *168*
- Complications *168*

18. Selective Neck Dissection **173**

Vijay A Patel, David Goldenberg, Neerav Goyal

- Classification, Pertinent Anatomy, and Surgical Landmarks by Level *173*
- Indications and Surgical Technique of Selective Neck Dissection *176*
- Complications *185*
- Postoperative Care *188*

JAYPEE BROTHERS

Section 5: Thyroid
Section Editor: *Neerav Goyal*

19. Thyroidectomy **193**

Neerav Goyal, Darrin V Bann, David Goldenberg

- Anatomy and Embryology *193*
- Indications and Contraindications for Surgery *195*
- Surgical Technique *196*
- Complications *200*

20. Parathyroid Surgery **203**

Darrin V Bann, Neerav Goyal, David Goldenberg

- Anatomy and Embryology *203*
- Indications for Parathyroidectomy *204*
- Preoperative Localization Studies *205*
- Operative Techniques *206*
- Postoperative Care and Complications of Parathyroidectomy *213*

Section 6: Salivary and Parapharyngeal Space Tumors
Section Editor: *Jason G Newman*

21. Parotidectomy **219**

Steven M Sperry, Jason G Newman

- Anatomy *219*
- Parotidectomy—Indications and Contraindications *222*
- Special Considerations: Nerve Monitoring *223*
- Instruments and Operative Considerations *223*
- Technique: Incisions *224*
- Technique: Skin Flap Elevation *225*
- Technique: Facial Nerve Identification *225*
- Technique: Reconstruction *226*
- Superficial Parotidectomy *227*
- Total Parotidectomy *231*
- Complications *233*

22. Submandibular Gland Excision **235**

Mihir R Patel, Jason G Newman

- Surgical Indications—Submandibular Gland Excision *235*
- Surgical Technique—Submandibular Gland Excision *235*
- Surgical Complications—Submandibular Gland Excision *238*

JAYPEE BROTHERS

23. Tumors of the Parapharyngeal Space **241**
Courtney B Shires, Jonathan Giurintano, Jason G Newman
- Anatomy *241*
- Presentation *242*
- Evaluation *243*
- Tumors *243*
- Surgical Approaches *246*

24. Surgery for Carotid Body Paraganglioma **253**
Gina D Jefferson, Jacqueline Wulu, Barry L Wenig
- Epidemiology *253*
- Presentation *253*
- Surgical Anatomy *254*
- Radiographic Evaluation *254*
- Further Evaluation *255*
- Management *255*

Section 7: Surgery for Skin Cancer
Section Editor: *Genevieve A Andrews*

25. Surgical Management of Nonmelanoma Cutaneous Malignancies of the Head and Neck **263**
Vijay A Patel, Genevieve A Andrews
- Treatment *265*

26. Surgical Management of Cutaneous Melanoma of the Head and Neck **271**
Marcus J Magister, Irina M Chaikhoutdinov, Genevieve A Andrews
- Treatment *271*
- Preoperative Evaluations *273*
- Indications *275*
- Surgical Technique *276*
- Complications *278*
- Postoperative and Follow-up Care *280*

Index *285*

JAYPEE BROTHERS

CHAPTER

3

Maxillectomy

Rosemary B Ojo, Ralph Abi-Hachem, Bradley J Goldstein

JAYPEE BROTHERS

INTRODUCTION

The standard operation for cancer involving the maxilla is maxillectomy. Limited operations, such as medial maxillectomy (either via an open or endoscopic approach), may be appropriate for benign or early stage malignant lesions. Extensive maxillectomies, such as total and subtotal maxillectomies, are performed to resect malignant and extensive benign tumors of the maxillary bone and associated soft tissues. Total maxillectomy may also be indicated for resection of invasive fungal disease, such as mucormycosis, in immune compromised patients, especially if there is an ability to correct the underlying medical process, i.e. diabetic ketoacidosis. Multiple surgical approaches have been developed to resect the maxilla over the past several decades, including lateral rhinotomy (LR), Weber-Ferguson extension (WFE), or midface degloving. These approaches are still widely used. Total maxillectomy refers to surgical resection of the entire maxilla. Resection includes the floor and medial wall of the orbit and the ethmoid sinuses. The surgery may be extended to include orbital exenteration and sphenoidectomy, and resection of the pterygoid plates. It is generally indicated for malignancies involving the maxillary sinus, maxillary bone, and/or orbit and ethmoids, especially tumors for which negative margins would not be possible via an endoscopic resection or limited maxillectomy. Total maxillectomy is potentially complicated by injury to the orbital contents, lacrimal drainage apparatus, optic nerve, ethmoidal arteries, intracranial contents, and may be accompanied by brisk bleeding. A comprehensive understanding of the three-dimensional anatomy of the maxilla and the surrounding structures is, therefore, essential.

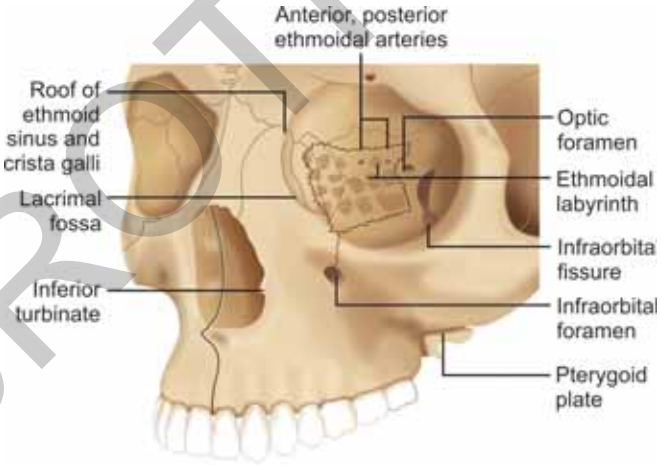

Fig. 3.1: Bony anatomy associated with maxillectomy procedures. Note especially the position of the ethmoidal arteries along the medial orbital wall; this level marks the position of the anterior skull base.

ANATOMY

The bony anatomy involved in maxillectomy procedures is shown in Figure. 3.1.

Critical surgical landmarks include:

- The level of the floor of the anterior cranial fossa (fovea ethmoidalis and cribriform plate), which corresponds with the position of the anterior and posterior ethmoidal foramina located along the frontoethmoidal suture line.
- The proximity of posterior ethmoidal foramen and artery to the optic nerve within the optic foramen.

Another bony structure requiring attention is the palate (Fig. 3.2). In a total maxillectomy, osteotomies will be performed to permit resection of the maxillary floor and hard palate, as indicated. Soft tissue structures of

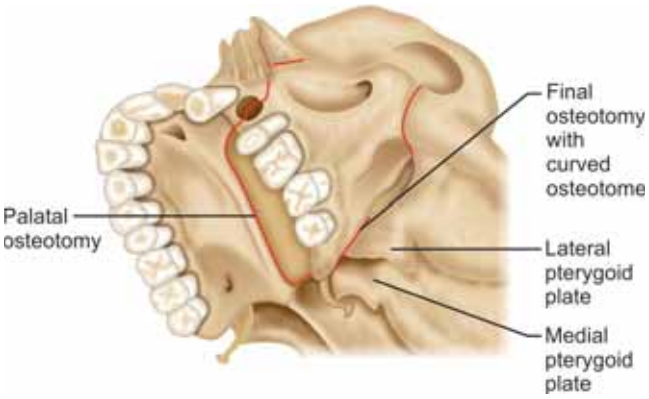

Fig. 3.2: Inferior view of the bony anatomy associated with maxillectomy procedures. Note the typical position of osteotomies used to resect the hard palate.

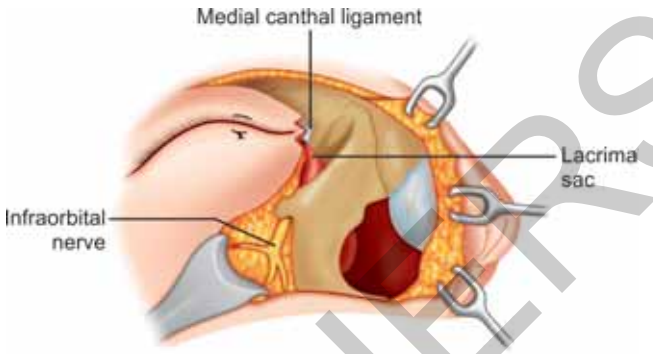

Fig. 3.3: Important soft tissue structures include the lacrimal sac and the infraorbital nerve, depicted here. The lacrimal sac will be transected during maxillectomy.

note include the lacrimal sac and infraorbital nerve. The lacrimal sac is transected at surgery in the lacrimal fossa (Fig. 3.3). Also, the infraorbital nerve is included in the specimen if necessary (Fig. 3.3). Immediately posterior to the maxillary sinus is the pterygopalatine fossa, in which the internal maxillary artery and its branches as well as the sphenopalatine ganglion and its branches are encountered. The pterygopalatine fossa communicates laterally with the infratemporal fossa via the pterygomaxillary fissure, and medially with the nasal cavity via the sphenopalatine foramen.

VASCULATURE

During maxillectomy, blood supplies from both the internal and external carotid systems are encountered.

The *arterial supply* relevant to maxillectomy is as follows:

- External carotid branches include the following:
  - *Facial/external maxillary artery* encountered during soft tissue approach.
  - *Internal maxillary artery* passes through the pterygomaxillary fissure to enter the pterygopalatine fossa. Branches of the internal maxillary artery of surgical significance include:
    - *Greater palatine artery* (descending palatine) that passes inferiorly from the pterygopalatine fossa through the pterygopalatine canal and emerges from the greater palatine foramen of the hard palate. It then runs anteriorly medial to the superior alveolus and enters the incisive foramen.
    - *Infraorbital artery* courses in the infraorbital groove and canal with the infraorbital nerve in the floor of the orbit/roof of antrum and exits anteriorly via the infraorbital foramen to supply the overlying soft tissues of the face.
    - *Sphenopalatine artery* enters the nasal cavity through the sphenopalatine foramen at the back of the superior meatus.
    - *Posterior lateral nasal arteries* are the branches of the sphenopalatine artery.
    - *Posterior septal artery* is a branch of the sphenopalatine artery that crosses the posterior nasal cavity just above the posterior choana to end on the nasal septum; one branch descends in a groove in the vomer to enter the incisive canal and anastomose with the greater palatine artery.
- *Internal carotid branches* include the following:
  - *Anterior ethmoidal artery* originates from the ophthalmic artery and enters the orbit through the anterior ethmoidal foramen located approximately 25 mm from the anterior lacrimal crest.
  - *Posterior ethmoidal artery* originates from the ophthalmic artery and enters the orbit through the posterior ethmoidal foramen. It is located approximately 35 mm from the anterior lacrimal crest and 12 mm (8–19 mm) from the anterior ethmoidal foramen.
  - *Ophthalmic artery* emerges with the optic nerve from the optic foramen, 44 mm from the anterior lacrimal crest and approximately 6 mm (5–11 mm) from the posterior ethmoidal foramen.

JAYPEE BROTHERS

– *Veins* encountered during maxillectomy include the *angular vein* at the medial canthus, and a *pterygoid venous plexus* in the pterygopalatine fossa, located in proximity to internal maxillary artery branches. This plexus may be a source of troublesome bleeding following final osteotomies to release the specimen.

NERVES

The maxillary division of cranial nerve V (V2) enters the pterygopalatine fossa via foramen rotundum. The only branch of surgical significance is the infraorbital nerve. It runs in the floor of the orbit/roof of the antrum to exit from the infraorbital foramen (*see* Fig. 3.3). The other cranial nerve that requires consideration during maxillectomy is cranial nerve II (the optic nerve), which is sacrificed during orbital exenteration. Cranial nerve I fibers (the olfactory nerves) are encountered in the cribriform plate region, which is preserved unless craniofacial resection is necessary.

ORBITAL DETAIL

During dissection of the orbit, the following structures are encountered: medial palpebral ligament, orbital septum, lacrimal sac, periosteum, anterior and posterior ethmoidal arteries, and inferior orbital fissure. During orbital exenteration, the superior orbital fissure is also encountered.

The orbital septum is a connective tissue structure that attaches circumferentially to the periosteum of the orbital margin and acts as a diaphragm that retains the orbital contents. Laterally, it is attached to the orbital margin 1.5 mm anterior to the attachment of the lateral palpebral ligament at the lateral orbital tubercle. The medial canthal tendon is a fibrous band that fixes the tarsal plates to the medial orbital wall. It is intimately related to the lacrimal drainage system. It lies anterior to the canaliculi, but a deep head inserts into the posterior lacrimal crest and onto the fascia of the lacrimal sac. The lacrimal sac is located in the lacrimal fossa, which is bound medially by the lacrimal bone and the frontal process of the maxilla. It is related anteriorly, laterally, and posteriorly to the medial canthal tendon. The inferior orbital fissure is situated in the floor of the orbit and separates the sphenoid bone from the maxilla. It transmits the maxillary nerve and a few minor nerves, but no vessels of surgical significance. The superior orbital fissure lies between the lesser and greater wings of the sphenoid bone. Important anatomical structures that pass through the fissure are cranial nerves III, IV, VI; and the superior and inferior divisions of ophthalmic vein.

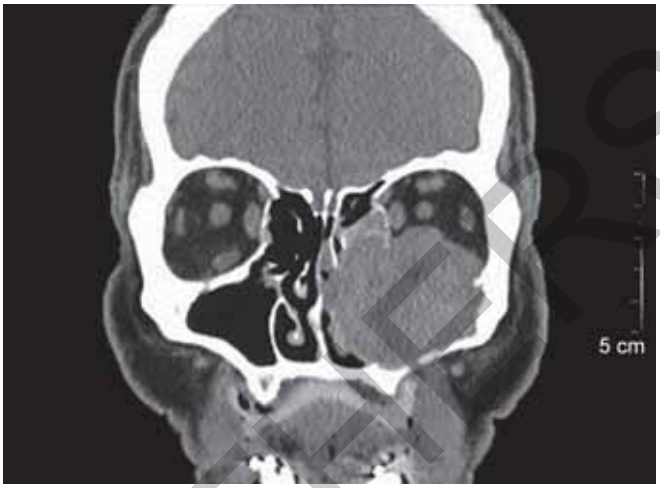

Fig. 3.4: Coronal CT image shows a left sinonasal mass based at the maxillary sinus with orbital involvement. Biopsy confirmed a malignancy, mucosal melanoma. Total maxillectomy with orbital exenteration was performed.

SURGICAL PROCEDURES

Indications/Contraindications

Maxillectomy is indicated for malignant neoplasm of the maxilla (Fig. 3.4). It may also be indicated for resection of invasive fungal disease in an immunocompromised setting. Contraindications include comorbidities that would preclude safe general anesthesia, or extensive disease that would preclude an ability to obtain adequate margins of resection.

TOTAL MAXILLECTOMY

Total maxillectomy involves resection of the entire maxilla, including the orbital floor and medial wall of the orbit and the ethmoid sinuses (Figs. 3.5A to C). The surgery may be extended to include resection of the lateral orbital wall and zygoma, exenteration of the orbit, sphenoidectomy, and resection of the pterygoid plates.

Radiological Evaluation

CT scanning is an important means of determining the superior (orbit and roof of ethmoids), posterior (pterygoid plates), lateral (zygoma and infratemporal fossa), and medial extent of the tumor and, therefore, the resection

JAYPEE BROTHERS

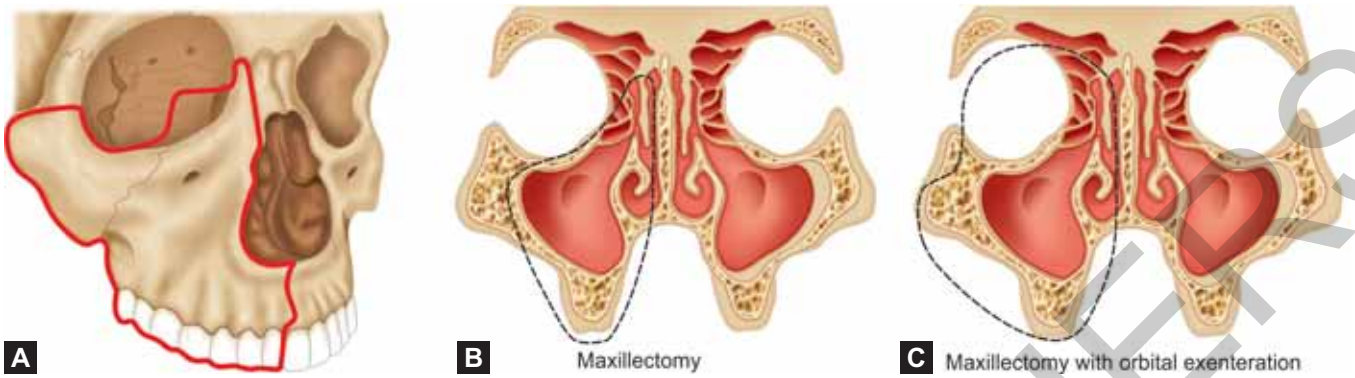

Figs. 3.5A to C: Schematic depiction of the extent of tissue resection in maxillectomy, with or without orbital exenteration.

required. If a tumor involves orbital fat and/or muscle, then orbital exenteration is generally recommended (*see* Fig. 3.4). Tumor extension to involve the pterygoid muscles may preclude maxillectomy, as obtaining clear margins becomes unlikely. Obvious intracranial extension may require neurosurgical involvement or may preclude resection.

Magnetic resonance imaging (MRI) with contrast will help delineate the tumor from the surrounding soft tissue, differentiate between tumor bulk and secretions in obstructed sinuses, and assess for perineural spread as well as extension of malignant tumors into Meckel's cave and the pterygomaxillary and infratemporal fossa.

Angiography with carotid flow study is indicated in patients with tumor surrounding the carotid artery. A balloon occlusion test is recommended to assess the risk of ischemic stroke if sacrifice of the carotid artery is considered.

Preoperative consent includes discussing the need for a tracheostomy, the facial incisions, loss of sensation in the infraorbital nerve distribution, diplopia, epiphora, enophthalmos, telecanthus, potential injury to the optic nerve, and cerebrospinal fluid (CSF) leak.

The operation is done under general anesthesia, with orotracheal intubation. If the eye is to be preserved then tarsorrhaphy should be done. The eyelids are sutured together with 4-0 silk taking care not to invert the eyelashes so as to avoid corneal abrasions, unless an orbital exenteration is planned. A tracheostomy is then done. Perioperative broad-spectrum antibiotics are administered for 24 hours. Lidocaine 1% with 1:100,000 epinephrine is injected along the planned skin incisions. The nasal cavity is decongested with a topical vasoconstrictor such as Afrin or 4% topical cocaine.

SURGICAL STEPS

Approaches

Maxillectomy may be done via LR or midfacial degloving approach (Figs. 3.6A and B). The midfacial degloving approach avoids facial scars and is suited to resections that do not extend above the orbital floor, i.e. do not include resection of the lamina papyracea and ethmoids. If the resection requires removal of the medial wall of the orbit and the ethmoids, LR provides better access. A Weber-Ferguson extension of the LR permits orbital exenteration.

Procedures

Soft Tissue Resection

- A tarsorrhaphy stitch is placed prior to skin prep.
- Midfacial degloving approach requires a sublabial mucosal incision with electrocautery along the gingivobuccal sulcus onto the maxilla and extended to the maxillary tuberosity (Figs. 3.6A and B).
- A LR incision is performed with a #15 blade; with a Weber-Ferguson approach, the lower lid incision is placed close to the palpebral margin so as to avoid edema of the lower lid above the scar following surgery.
- The remainder of the soft tissue dissection may be done with electrocautery. The incision is extended onto the nasal bone and maxilla (Figs. 3.7A and B). The angular vessels will need to be cauterized or ligated adjacent to the medial canthus of the eye. The lower lid skin is elevated down to the inferior orbital rim.
- The soft tissues of the face are elevated off the anterior maxilla using cautery or a freer elevator, remaining hard on bone while performing this dissection. Once

JAYPEE BROTHERS

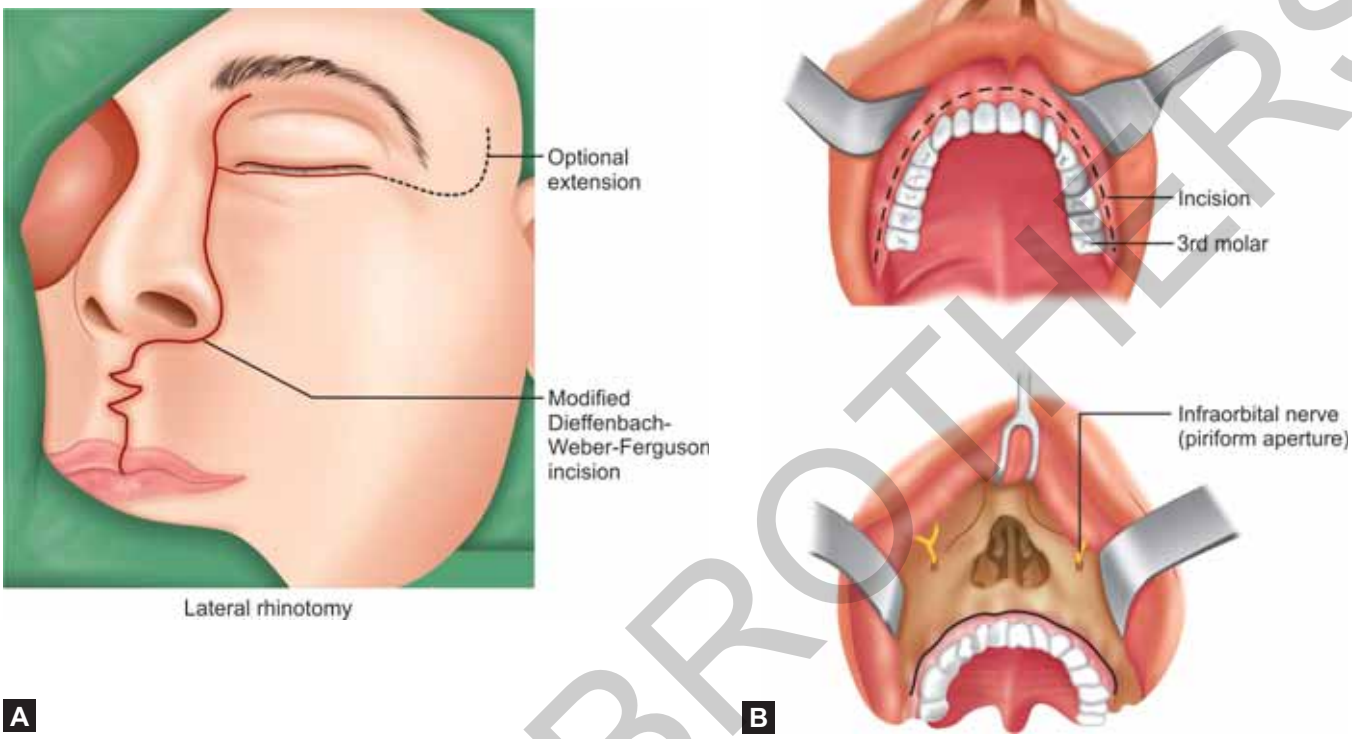

Figs. 3.6A and B: Incisional approaches for maxillectomy. The lateral rhinotomy, with or without extension, provides the best superior exposure and is therefore most useful for total maxillectomy. The dissection involved in the midface degloving exposure is depicted; however, this approach is most suitable for inferior maxillectomies.

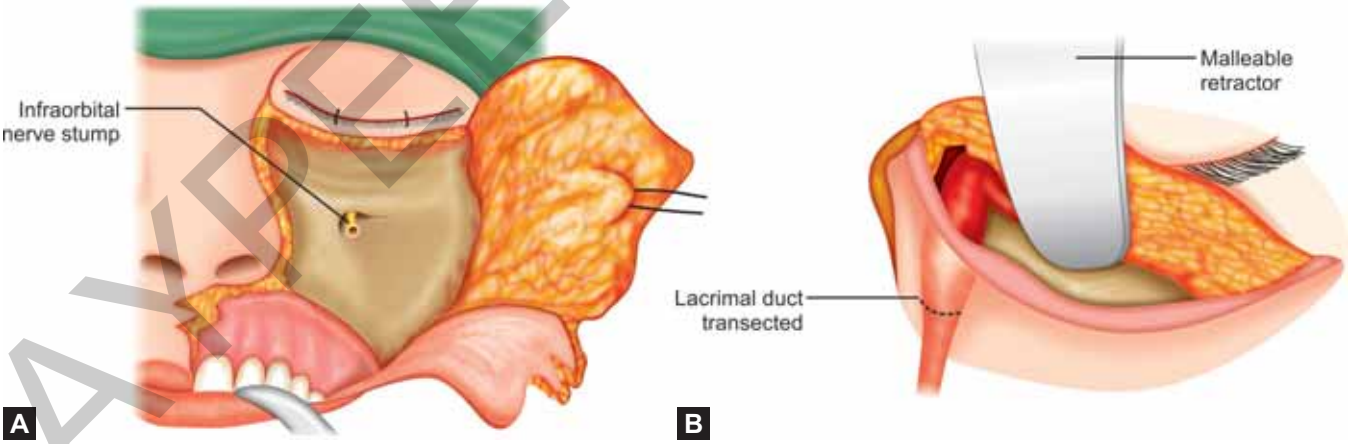

Figs. 3.7A and B: Soft tissue dissection and exposure of the anterior maxilla, infraorbital nerve, and medial orbit. Note transection of the lacrimal sac.

the entire face of the maxilla is exposed, the infraorbital nerve and vessels can be transected with cautery (Figs. 3.7A and B); if there is concern about perineural invasion, the nerve can be sampled with intraoperative frozen pathology sections to ensure clear margins. Dissection is continued around the maxilla up to

JAYPEE BROTHERS

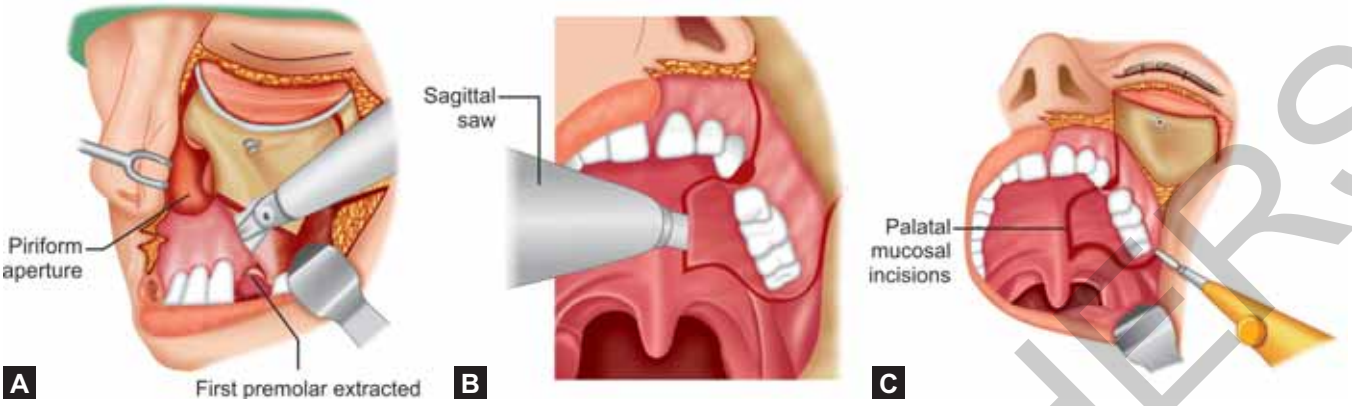

Figs. 3.8A to C: Soft tissue dissection along the nasal aperture and palate. This dissection will permit subsequent performance of osteotomies.

the pterygomaxillary fissure and the zygoma. Sharp dissection beyond the fissure is avoided, to prevent transecting the internal maxillary artery.

- The medial palpebral ligament, anterior lacrimal crest, lacrimal sac in the lacrimal fossa, and posterior lacrimal crest are next identified. The medial palpebral ligament is divided and then the lacrimal sac is elevated from its fossa. The sac is transected as distally as possible to facilitate fashioning a dacryocystorhinostomy (DCR) (*see* Figs. 3.7A and B).
- Next, the medial and inferior orbit is exposed. The orbital contents are elevated in a subperiosteal plane from the lamina papyracea and frontal bone taking care not to fracture or penetrate the paper-thin bone of the lamina papyracea.
- The frontoethmoidal suture must next be identified. This is a crucial surgical landmark, as it corresponds with the level of the cribriform plate and the anterior and posterior ethmoidal foramina. Gently retract the orbital contents laterally and identify the anterior ethmoidal artery as it bridges the divide between the anterior ethmoidal foramen and the periorbita (*see* Fig. 3.1). The anterior ethmoidal artery is ligated and divided, thereby providing access to the posterior ethmoidal artery. It is generally not necessary to divide this vessel.
- The floor of the orbit is stripped in a subperiosteal plane. Care is taken to prevent tearing the periosteum at the inferior orbital margin at the attachment of the orbital septum so as to avoid entering the orbit and causing extrusion of orbital fat.
- The soft tissues from the bone up to the anterior free margin of the nasal aperture are released with bovie electrocautery (Figs. 3.8A to C). The nasal ala is retracted and the lateral wall of the nasal vestibule is incised to expose the ipsilateral nasal cavity and inferior turbinate, taking care not to injure the inferior turbinate or septum, to prevent bleeding.
- Using a sweetheart retractor in the mouth to retract the tongue, the hard and soft palate is visualized. One may then identify the maxillary tuberosity and the bony spines of the pterygoid plates immediately posterior to the tuberosity.
- Using electrocautery, an incision is made in the mucosa of the hard palate along the planned medial resection margin, and the sublabial incision is extended laterally around the maxillary tuberosity, and into the groove between the tuberosity and the pterygoid plates. Removal of a tooth may be helpful. Palpation to define the posterior edge of the hard palate will permit division of the attachment of the soft palate to the hard palate with electrocautery, thereby entering the nasopharynx. Bleeding from branches of the greater and lesser palatine arteries should be anticipated and cauterized. This completes the inferior soft tissue dissection.

Bony Resection

The extent of the bony resection is tailored to the primary tumor and may include the lateral wall of the orbit and zygoma, especially if the antrum is seen to extend into the zygoma on CT imaging. The sequence of the osteotomies is planned to reserve troublesome bleeding to the end of the procedure.

- Osteotomies are shown in Figure 3.9. Osteotomy is made through the inferior orbital rim and along the orbital floor. A sharp osteotome/oscillating sagittal saw is used to cut through the malar buttress/inferior

JAYPEE BROTHERS

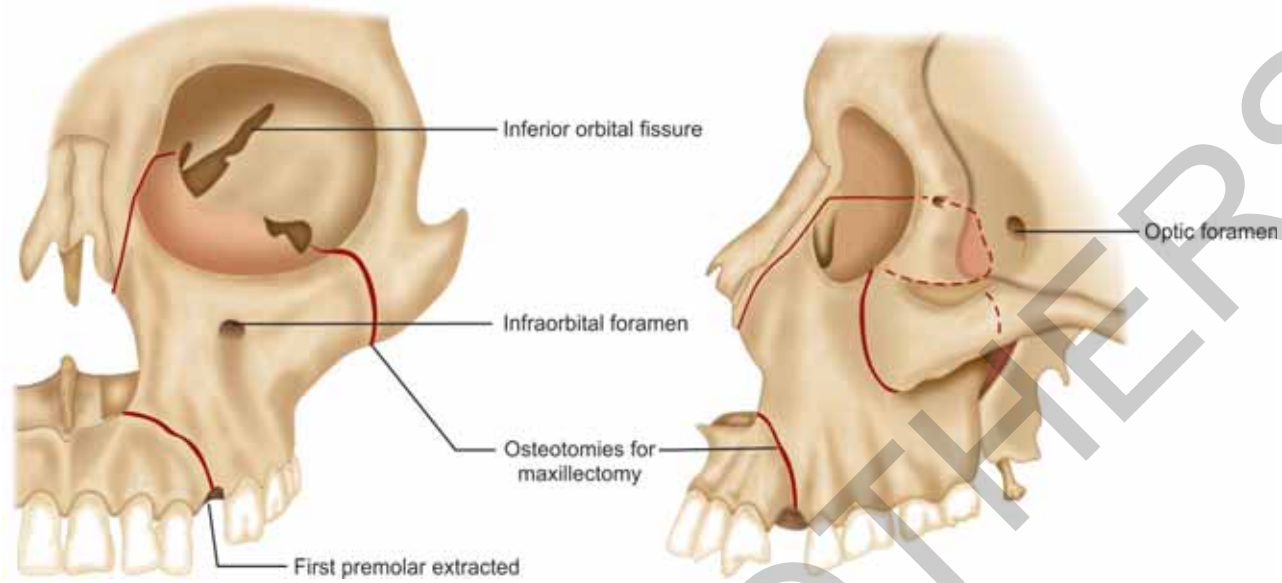

Fig. 3.9: Osteotomies performed in maxillectomy. *See* the text for details regarding each bone cut.

orbital rim. This osteotomy is placed lateral to the antrum as seen on the CT scan so as not to enter the antrum.

- While retracting and protecting the orbital contents with a narrow malleable retractor, osteotomy is then continued posteriorly through the thin bone of the orbital floor/antral roof using a sharp osteotome and aiming for the infraorbital fissure.
- Next is osteotomy through frontal process of maxilla and lacrimal bone. This thick bone is best transected with a Kerrison's rongeur or oscillating saw. There is often persistent minor bleeding from the bone that may be controlled with bone wax or cautery. The osteotomy is directed toward, but kept a few millimeters below, the level of frontoethmoidal suture line.
- Osteotomy is then made through lamina papyracea and anterior ethmoids. This osteotomy is done by gently tapping on an osteotome to enter the ethmoid air cell system while carefully retracting the orbital contents laterally. It is critical that this osteotomy be kept a few millimeters below the level of the frontoethmoidal suture line and the ethmoidal foramina so as to avoid fracturing or penetrating through the cribriform plate resulting in a CSF leak. The osteotomy stops short of the posterior ethmoidal artery and then is directed inferiorly toward the orbital floor so as to safeguard the optic nerve.
- Palatal osteotomy can be performed using a sharp osteotome/power saw is used to cut vertically through the superior alveolus and hard palate. The placement of this osteotomy is dependent on the palatal extent of the tumor. It is often preferable to extract a tooth and to place the osteotomy through the dental socket, rather than to place it between two teeth as this might devitalize the adjacent two teeth and it makes soft tissue closure more difficult. The palatal osteotomy is extended to the posterior margin of the hard palate. Osteotomy of nasal septum is only required when the palatal osteotomy is placed across the midline. The nasal septum is then divided parallel to the nasal floor with an osteotome or heavy scissors.
- Osteotomy to separate maxillary tuberosity from pterygoid plates. This is the final osteotomy, and is done by tapping with a (curved) osteotome in the groove between the maxillary tuberosity and the pterygoid bone. Superiorly this cut ends in the pterygomaxillary fissure and the pterygopalatine fossa. The maxillectomy specimen can now be gently downfractured (Figs. 3.10A and B).
- The internal maxillary artery tethers the specimen laterally, and is clipped and divided where it enters the pterygomaxillary fissure. If the artery is inadvertently transected, it is clipped and ligated. If the artery is not apparent, then it should be specifically looked for as it may have gone into spasm and may bleed later. The specimen is removed and inspected to determine the adequacy of the tumor resection.
- The remnants of the ethmoids are carefully inspected. An external ethmoidectomy may safely be completed

JAYPEE BROTHERS

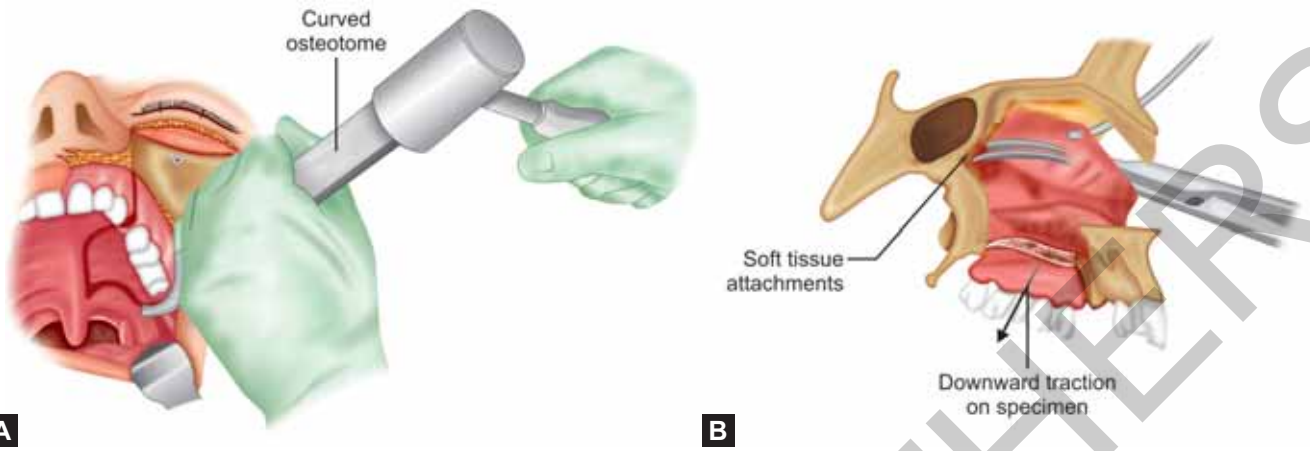

Figs. 3.10A and B: Maxillectomy: posterior osteotomies and specimen delivery.

up to the cribriform plate. The need for external frontoethmoid-ectomy +/- sphenoidectomy is determined, and evidence of a CSF leak is excluded. Arterial and venous bleeding occurs from the pterygoid venous plexus; it may initially be controlled with packing. Meticulous hemostasis is achieved with bipolar cautery, suture ligatures, clips, bone wax, and topical hemostatic agents such as Gelfoam.

ORBIT

Orbital exenteration is generally indicated when tumor has extended through periosteum to involve fat and/or muscle and/or the globe; the eyelids; and the lacrimal apparatus. Involvement limited to the bone or periosteum can be managed by resecting the involved periosteum. The clearest indications for orbital exenteration are those involving malignant tumors with no hope of salvaging vision in the affected eye such as squamous cell carcinoma and other epithelial malignancies. Whenever possible the eyelids are preserved (lid-sparing versus lid-sacrificing exenteration) so they may be sutured together at completion of the surgery by making palpebral incisions just above and below the eyelashes. It gives excellent color match to surrounding skin and heals relatively quickly.

The skin is then elevated from the tarsal plates with monopolar cautery up to the orbital rims circumferentially. The periosteum is incised circumferentially just medial to the orbital rim, exposing the underlying bone. Take care not to injure the supraorbital nerve so as to preserve sensation to the forehead.

The orbital contents are mobilized in the relatively avascular subperiosteal plane inferiorly, laterally, and superiorly. This is achieved by simply stripping the periosteum from the bone with a Freer's dissector, except along the inferior orbital fissure where the tissues are divided with scissors.

Transect the ocular muscles and optic nerve and ophthalmic vessels at the orbital apex. Avoid undue traction on the optic nerve as this can injure the contralateral optic nerve. Exposure may be improved by decompressing the globe with a large bore needle. Use curved scissors to transect the orbital apex and to deliver the orbital contents. Pack the orbit for a few minutes, and then use bipolar cautery or a ligature to control the brisk bleeding from the ophthalmic artery.

Postoperative management of the orbital cavity can be managed in a number of ways. Patients may be left with the orbital cavity exposed +/– an (immobile) ocular prosthesis. When wearing a prosthesis is not an option, patients prefer to have the cavity filled with a flap. Another option is to leave to granulate that requires a skin graft. Suturing the eyelids together and close to the cheek advancement flap is another viable option.

CLOSURE AND RECONSTRUCTION

The simplest option is healing by secondary intention or granulation. The advantages of such healing are shorter operating time, good color match to surrounding tissue, and excellent visibility for monitoring of possible recurrence of disease. However, its disadvantages include a long healing time and the necessity for several painful dressing changes.

Split-thickness skin grafts (Fig. 3.11), most commonly taken from the thigh, are frequently used to line the orbital

JAYPEE BROTHERS

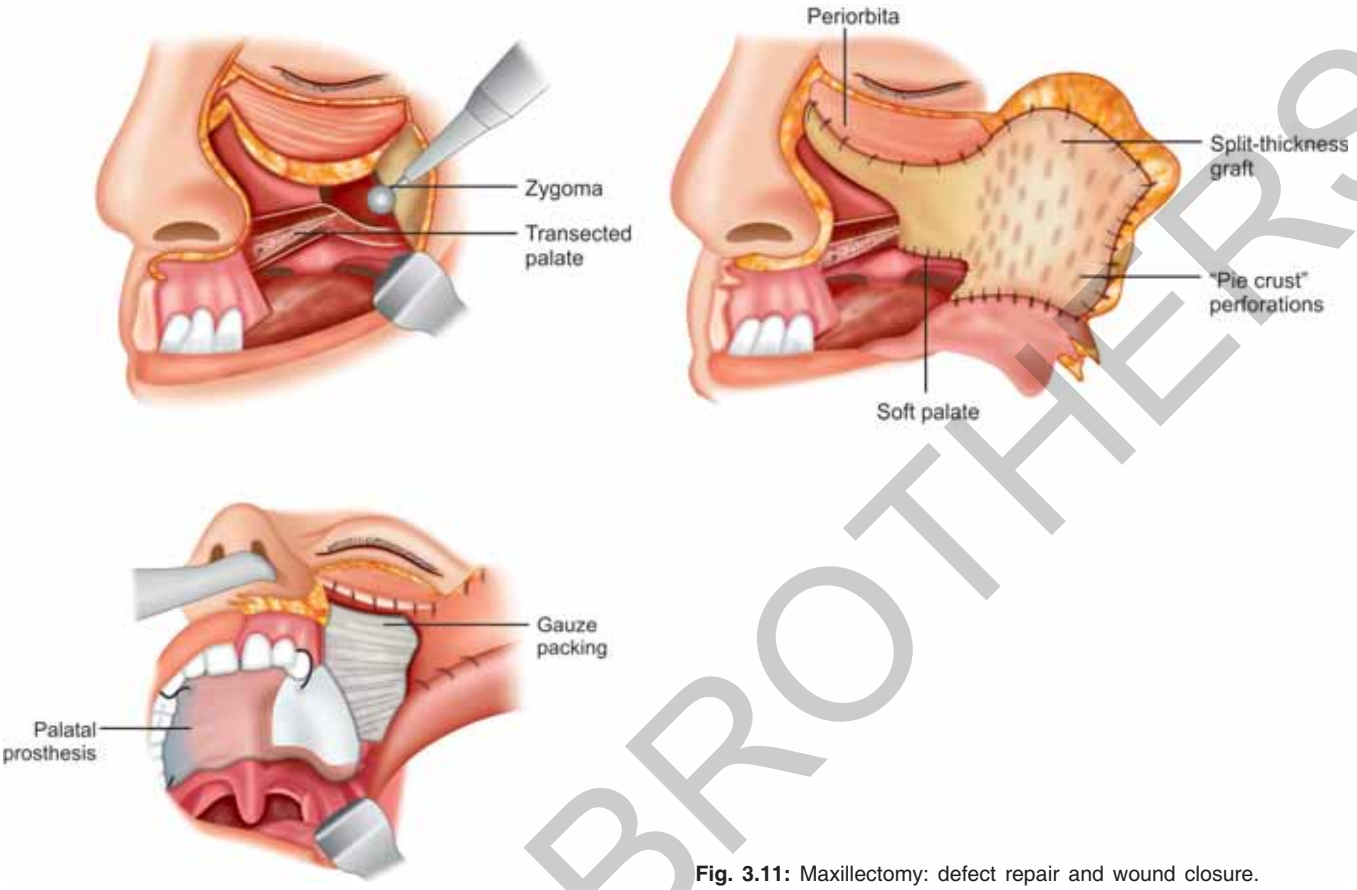

Fig. 3.11: Maxillectomy: defect repair and wound closure.

cavity when total exenteration with removal of periosteum is performed; they assist in faster healing and provide excellent monitoring for recurrence.

Local or free tissue flaps are most commonly performed particularly for defects resulting from concurrent partial or complete maxillectomy. This includes radial forearm free flap, rectus abdominis flap, fibular free flap, and scapula free flap are all excellent options of reconstruction.

These flaps provide good vascularized tissue in the setting of radiation therapy. However, it requires high specialized microsurgical techniques, donor site morbidity, and longer operative time. Prosthesis may be molded by a prosthodontist and affixed with topical adhesive. Prosthesis can be magnetically fixed to osseointegrated dental implant.

POSTOPERATIVE CARE

Oral hygiene is promoted through the use of irrigation with chlorhexidine gluconate in a "swish and spit" technique. Although routine tracheostomy may not be necessary for all total maxillectomy procedures, temporary tracheostomy is often utilized, for instance if a flap reconstruction or obturator and packing may lead to potential airway obstruction. The tracheostomy tube is typically changed by postoperative day 3–5 and capped soon after, with decannulation prior to discharge from the hospital. Arrangements should be made so that the prosthodontist is available on approximately the fifth postoperative day when the surgical splint and packing are removed. After removal of the obturator, the patient should be seen immediately by the prosthodontist for insertion of an interim prosthesis, which will allow the patient to continue with an oral diet as healing continues. When postoperative radiation therapy is deemed necessary, the changes incurred may prevent final modification of the prosthesis until the radiation therapy has been completed and wound contracture has stabilized. The final prosthetic repair should facilitate chewing and help restore appearance when teeth are added to the prosthesis. Monitoring of the vascular anastomosis of a free flap is accomplished with the use of Doppler ultrasonography. The vascularity

JAYPEE BROTHERS

of the free flap can be assessed clinically by looking for cutaneous blanching. Other standard postoperative care is followed, including deep vein thrombosis prophylaxis, early ambulation, and appropriate nutrition.

COMPLICATIONS

Possible postoperative complications following total maxillectomy can include the following, divided into early or late problems.

Early Complications

- *Orbit/skull base*: Most of the major potential intraoperative complications associated with total maxillectomy have to do with the central nervous system and the orbit. If an osteotomy is performed superior to the level of the anterior ethmoid artery and frontoethmoid suture, it is possible to enter the cranial cavity with resultant leakage of CSF. Extending the dissection medial to the attachment of the middle turbinate will also precipitate CSF leakage. This complication should be recognized and repaired immediately. If an actual defect in the dura is noted, a septal mucosal flap or a flap from the middle turbinate may be used. Most CSF leaks can be controlled when they are encountered.

  The proximity of the orbit puts the eye at risk in all operations involving the lateral nasal wall. Injury to the orbit and the optic nerve is a potentially serious complication. Note that during orbital exenteration, intraoperative bradycardia can occur when the optic nerve is transected.

  If preserving the eye, it is important to not lacerate the periorbita to avoid herniation of fat with the subsequent possibility of enophthalmos. If such lacerations occur, effort should be made to replace the herniated fat within the periorbita to close the laceration. If the periorbita has been removed, it may be replaced with temporalis fascia. Carrying the osteotomies too far posteriorly or not being precise with the soft tissue cuts may result in direct injury to the optic nerve. Preserving the posterior third of the lamina papyracea and being cautious with the osteotomies can prevent inadvertent optic nerve injury.
- *Bleeding*: It may occur from a raw surface area or granulation tissue from the wound. In these instances, it is controlled using silver nitrate or packing of the maxillectomy cavity. However if more severe bleeding occurs, the origin can be arterial from one of the main branches or venous from the pterygoid plexus. In that case, bleeding is temporized by packing the maxillectomy cavity and controlled in the operating room using either an endoscopic or an open approach based on the source of bleeding and the surgeon's preference.
- *Infection*: Cellulitis and infection of the maxillectomy cavity are best treated using culture directed antibiotics, frequent irrigation with nasal saline, and removal of the crust from within the cavity. It can lead to venous retrograde seeding of the infection with subsequent cavernous sinus thrombosis and intracranial abscess.
- *Wound breakdown*: This is seen with reconstruction of the maxillectomy defect using either a skin graft or a free flap. The skin graft should be well bolstered for 5–7 days in order for the graft to heal appropriately.
- Loss of the reconstructive flap: If the surgical defect is reconstructed using a free flap and there is an issue with flap perfusion especially in the first 48 hours, then the microvascular surgeon should be promptly alerted and decide whether or not to re-explore the flap to salvage it.
- *Diplopia*: It can occur in the immediate postoperative period and is due to edema of the orbital soft tissue content or injury to the oculomotor muscle and/or its innervation. It is managed conservatively with steroids. Diplopia may be alleviated by alternating an eye patch.

  Entrapment of the muscle within the osteotomy site can also lead to diplopia. Prompt diagnosis and urgent surgical release are the key steps in order to prevent any long-term sequelae.
- Lower lid edema.

Late Complications

- *Epiphora*: The nasolacrimal duct is transected during total maxillectomy, and subsequent scarring and stenosis of the lacrimal duct will lead to epiphora. Patients should be treated with an open DCR at the time of the maxillectomy or cannulation of the lacrimal canaliculi for 3–6 months in order to prevent epiphora. Endoscopic endonasal DCR at a later stage also has a high success rate in this patient population.
- *Paresthesia of the cheek*: It occurs due to injury or sacrifice of the infraorbital nerve. Infraorbital sensation should be assessed preoperatively to determine if the nerve is involved by the tumor.

JAYPEE BROTHERS

- *Atrophic rhinitis*: It will lead to nasal crusting and overgrowth of bacteria. Frequent irrigation using saline solution and debridement during clinic visit help maintain nasal hygiene.
- *Enophthalmos/hypophthalmos*: It is caused by loss of support at the inferior and/or medial orbital walls.
- Ectropion, diplopia
- Dystopia, facial contracture, other cosmetic deformity
- Oral incompetence
- *Speech dysfunction*: If the reconstruction using either an obturator or a free flap is not sealing the nasal cavity from the oral cavity then speech might be unintelligible and will require further reconstructive consideration.
- *Eustachian tube dysfunction*: If the posterior limit of the resection is involving the tensor veli palatine, there is an increased risk of eustachian tube dysfunction with subsequent middle ear effusion, which is treated with a ventilation tube.

FURTHER READING

1. Brickman DS, Reh DD, Schneider DS, et al. Airway management after maxillectomy with free flap reconstruction. Head Neck. 2013;35:1061-5.
2. Brown JS, Shaw RJ. Reconstruction of the maxilla and midface: introducing a new classification. Lancet Oncol. 2010; 11(10):1001-8.
3. Clark RK, Chow TW, Luc HW, et al. Prosthodontic aspects of a new method for functional reconstruction following maxillectomy. J Prosthet Dent. 1995;73(6):559-62.
4. Cordeiro PG, Santamaria E, Kraus DH, et al. Reconstruction of total maxillectomy defects with preservation of the orbital contents. Plast Reconstr Surg. 1998;102(6):1874-84.
5. Cordeiro PG, Santamaria E. A classification system and algorithm for reconstruction of maxillectomy and midfacial defects. Plast Reconstr Surg. 2000;105:2331-46.
6. Essig GF, Newman SA, Levine PA. Sparing the eye in craniofacial surgery for superior nasal vault malignant neoplasms: analysis of benefit. Arch Facial Plast Surg. 2007;9(6):406-11.
7. Hanna EY, Westfall CT, Myers EN, et al. Cancer of the nasal cavity, paranasal sinuses, and orbit. In: Myers EN, Suen JY, Myers JN, (Eds). Cancer of the Head and Neck. Philadelphia, PA: Saunders; 2003. pp. 155-206.
8. Kazaoka Y, Shinohara A, Yokou K, et al. Functional reconstruction after a total maxillectomy using a fibula osteocutaneous flap with osseointegrated implants. Plast Reconstr Surg. 1999;103:1244-6.
9. Keyf F. Obturator prostheses for hemimaxillectomy patients. J Oral Rehabil. 2001;28:821-9.
10. Lin HS, Wang D, Fee WE, et al. Airway management after maxillectomy: routine tracheostomy is unnecessary. Laryngoscope. 2003;113:929-32.
11. Martin JW, Austin JR, Chambers MS, et al. Postoperative care of the maxillectomy patient. ORL Head Neck Nurs. 1994;12:15-20.
12. Muneuchi G, Miyabe K, Hoshikawa H, et al. Postoperative complications and long-term prognosis of microsurgical reconstruction after total maxillectomy. Microsurgery. 2006;26:171-6.
13. Myers E. Operative Otolaryngology Head and Neck Surgery, 2nd edition. Philadelphia, PA: Elsevier-Saunders. 2008.
14. Myers EN, Aramany MA. Rehabilitation of the oral cavity following resection of the hard and soft palate. Trans Am Acad Ophthalmol Otolaryngol. 1977;84:941-8.
15. Triana RJ, Uglesic V, Virag M, et al. Microvascular free flap reconstructive options in patients with partial and total maxillectomy defects. Arch Facial Plast Surg. 2000;2(2): 91-101.

JAYPEE BROTHERS

Surgical Techniques in Otolaryngology—Head & Neck Surgery

HEAD & NECK SURGERY

Head and Neck Surgery is part of a comprehensive series entitled "Surgical Techniques in Otolaryngology—Head & Neck Surgery". Other atlases in this series are devoted to various specialties within the field, including Otologic and Neurotologic Surgery, Laryngeal Surgery, Pediatric Otolaryngologic Surgery, Facial Plastic and Reconstructive Surgery and Sinonasal Surgery.

Twenty-six chapters are included in this volume. Separate sections cover sinonasal cancer, oral cavity and oropharynx, surgery of the larynx and hypopharynx, neck dissections, the thyroid, salivary and parapharyngeal space tumors, and surgery for skin cancer.

Procedures discussed include maxillectomy, anterior craniofacial resection, endoscopic anterior skull base resection, floor of mouth resection, mandibulotomy, mandibulectomy, microlaryngeal laser excision, transoral robotic surgery for the larynx, radical and selective neck dissections, thyroidectomy, parotidectomy, submandibular gland excision, and others. Specific disorders covered include lip cancer, oral tongue cancer, larynx cancer, tumors of the parapharyngeal space, carotid body paraganglioma, non-melanoma cutaneous malignancies of the head and neck, and melanoma. Numerous intraoperative photographs and illustrations are included. This volume is a practical guide for otolaryngologists of all levels.

Available at all medical bookstores
or buy directly from Jaypee Brothers
at www.jaypeebrothers.com or www.jpmedpub.com



JAYPEE BROTHERS
Medical Publishers (P) Ltd.
www.jaypeebrothers.com
Join us on facebook.com/JaypeeMedicalPublishers

Shelving Recommendations
OTORHINOLARYNGOLOGY
HEAD AND NECK SURGERY

