rothers.com, for detailed information on medicine books, visit our website www.jaypeebrothers.com, for detailed information on medicine books

Free SYNAPZ Format Book

2nd Edition

SYNAPZ

The Complete Final MBBS Manual





Editors
McEnroe D Mordom
Mridulal A
Randeep AM

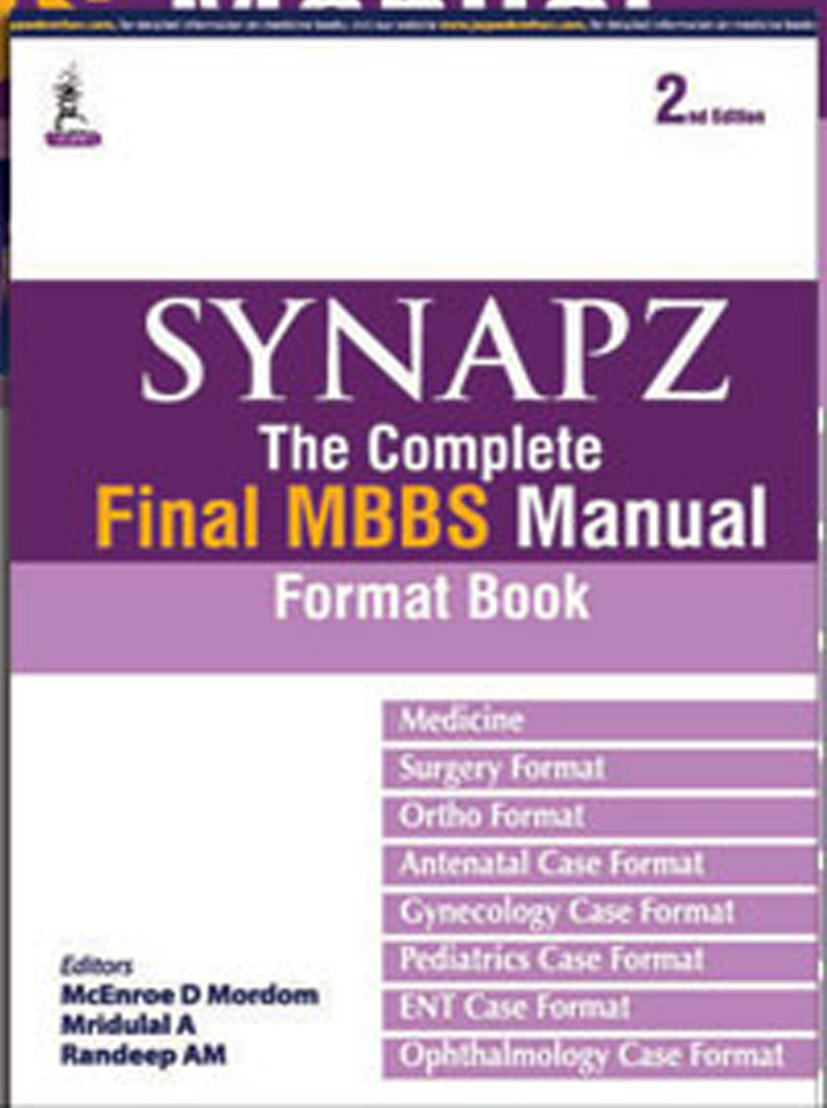

Contents

1. Medicine **1**

- Cardiovascular System *1*
- Respiratory System *14*
- Gastrointestinal System *26*
- Nervous System *45*
- Renal System *64*
- Objective Structured Clinical Examination (Medicine) *66*
- Charts *79*
- Drugs *81*
- Drugs of Choice for Microbial Pathogens *86*
- Drugs of Choice *90*
- Mnemonics *91*

2. Surgery **100**

- Swelling or Lump *100*
- Thyroid Swelling *103*
- Carcinoma Breast *114*
- Carcinoma Stomach *122*
- Obstructive Jaundice *127*
- Abdominal Examination *128*
- Abdominal Lump *131*
- Peripheral Vascular Disease and Gangrene *136*
- Salivary Gland *141*
- Varicose Vein *145*
- Malignant Melanoma *149*
- Carcinoma of Tongue *151*
- Carcinoma Penis *152*
- Fournier's Gangrene *152*
- Swellings of Neck *153*
- Ulcer *155*
- Varicocele *160*
- Hernia *161*
- Hydrocele *165*
- Surgical Procedures *167*

3. Orthopedics **177**

- Stages and Phases of Fracture Healing *177*
- Classification of Tumors of Bone *188*
- Nails *192*

4. Obstetrics **193**

- Normal Pregnancy *193*
- Malpresentations *199*
- Gestational Diabetes Mellitus *203*
- Management of Gestational Diabetes Mellitus *204*
- Hypertensive Disorders of Pregnancy *208*
- Intrauterine Growth Restriction *212*

- Multiple Pregnancy *215*
- Heart Disease Complicating Pregnancy *219*
- Previous Cesarean Section *222*
- Bad Obstetric History *225*
- Anemia Complicating Pregnancy *227*
- Rh Isoimmunization *229*
- Contracted Pelvis *231*
- Antepartum Fetal Surveillance *233*
- Ultrasonography in Obstetrics *234*
- Postpartum Hemorrhage *234*
- Ectopic Pregnancy *236*
- Mnemonics *236*

5. Gynecology **238**

- Dysfunctional Uterine Bleeding *238*
- Genital Prolapse *240*
- Fibroid or Ovarian Tumor *243*
- Carcinoma of Cervix *247*
- Carcinoma of Endometrium *249*
- Vesicular Mole (Hydatidiform Mole) *249*
- Operative Procedures *252*
- Objective Structured Clinical Examination Questions *254*
- Infertility *255*

6. Pediatrics **258**

- Cardiovascular System *258*
- Respiratory System *268*
- Renal System *273*
- Gastrointestinal System *277*
- Hematological Disorders *282*
- Nervous System *290*
- Growth and Development *296*
- Nutrition *297*
- Newborn Infants *303*
- Pediatric Surgery *304*
- Objective Structured Clinical Examination (Pediatrics) *306*
- Case Charts *310*
- Drugs *313*
- Vaccines *314*
- X-ray and Instruments *317*
- Developmental Milestones *320*
- Newborn Period *322*

Appendix **324**

Diagrams **328**

Question Bank **350**

Index *385*

2 CHAPTER

Surgery

SWELLING OR LUMP

History of Present Illness

1. *Duration*: Shorter—benign; Longer—malignant
2. *Mode of onset*: Sudden or gradual
3. Associated symptoms
4. *Pain*: Nature, site, time of onset, radiation, difficulty in respiration/swallowing
5. Fever
6. Impairment of function
7. *Progress of swelling*: Stationary or continued
8. History of trauma
9. *Secondary changes*: Softening, ulceration, fungation, inflammatory changes
10. *History of recurrence*: Malignant—recurs after removal
11. *Cystic swelling*: If cyst wall not completely removed
12. History of loss of appetite and weight loss.

History of Past Illness

Similar illness, TB, syphilis.

Personal History

Betel chewing (Nut, slaked lime, tobacco) responsible for growth in cheek, tongue, mouth, lip.

Family History

Similar illness; TB; von Recklinghausen's disease.

General Examination

1. PICCLE (**P**allor, **I**cterus, **C**yanosis, **C**lubbing, **L**ymph node enlargement, **E**dema).
2. Vitals
3. Local examination (L/E).

Inspection

1. Site
2. Shape
3. Size
4. Surface—cauliflower (Squamous cell carcinoma) irregular numerous branched (Papilloma).

JAYPEE BROTHERS

5. Extent
6. Color—blue (Ranula); black (Nevus, melanoma); red (Hemangioma)
7. Margin—well defined, poorly defined
8. Number
9. Pulsation
10. Impulse on cough—meningocele, hernia
11. Skin over swelling
12. Any sinuses, scar, prominent veins.

Palpation

1. Local rise of temperature and tenderness
2. Site, size, shape, number, extent, surface, margin
3. Consistency
4. Fluctuation
5. Transillumination
6. Impulse on cough
7. Pulsatility—transmitted (swelling superficial to artery); expansile (originates from arterial wall)
8. Reducibility
9. Compressibility
10. Fixity to overlying skin—papilloma, epithelioma, sebaceous cyst
11. Skin over the swelling—pinchable (if not fixed to skin)
12. Relation to superficial and deep part—skin, subcutaneous (s/c) tissue, muscle, tendon, bone, joint, vessels.

Examination of Regional Lymph Node

Percussion

Auscultation
Bruit-aneurysm.

Measurements
Compare with opposite side in case of wasting.

Movements
Examine the movement of nearby joints.

Examination of Pressure Effects

1. Arterial pulse—weak distal to swelling
2. Nerve—wasting, paresis, paralysis
3. Vein—distal edema, venous engorgement.

Diagnosis
1. Anatomical location 2. Pathological nature 3. Complication.

Anatomical	Pathological
Skin, subcutaneous (s/c) tissue, muscle, tendon, bones, joints	Congenital, traumatic, inflammatory-acute and chronic
Vessels, arteries	Neoplasm—benign and malignant

Example: Lipoma—this person having benign subcutaneous tissue swelling probably lipoma without any features of complication.

Investigations

1. Routine (R/E) investigations of blood and urine
2. X-ray of swelling—to find out bony erosion
3. X-ray chest—to rule out pulmonary metastasis
4. Fine needle aspiration cytology (FNAC)

JAYPEE BROTHERS

5. Aspiration—for cystic swelling
6. Angiography—for aneurysms
7. Biopsy
8. USG, CT, MRI (only for special situations).

Discussion

Common Swellings of Soft Tissue

Lipoma

Clinical features

1. Ubiquitous
2. Pseudofluctuant
3. Free from skin and deeper tissue
4. Commonly subcutaneous lipoma
5. Slipping edge.

Complications

1. Myxomatous degeneration
2. Infection
3. Saponification
4. Malignant change to liposarcoma
5. Ulceration due to repeated trauma.

Management

Investigation + treatment (Rx)—excision.

Sebaceous Cyst

Commonly on scalp and scrotum, has connection with a hair follicle in majority of cases. Adherent to skin at punctum and is fluctuant.

Complications

1. Infection
2. Calcification
3. Rupture and sinus formation
4. Carcinomatous changes
5. Cock's peculiar tumor
6. Sebaceous horn.

Management

Investigation + treatment (Rx)—incision and avulsion of cyst with wall.

Classification of Tumors

1. **Congenital**
   a. Dermoid cyst
   b. *Hemangioma*:
      i. Capillary
      ii. Cavernous
      iii. Plexiform
      iv. Congenital AV fistula
      v. Glomangioma.
2. **Traumatic**
   a. Hematoma
   b. Implantation dermoid.
3. **Inflammatory**
   a. Erysipelas—spreading cuticular lymphangitis
   b. Cellulitis—spreading of inflammation of subcutaneous and facial tissues leading to suppuration, sloughing or even gangrene
   c. Abscess-pyogenic, pyemic and cold
   d. Boil furuncle
   e. Carbuncle.
4. **Neoplastic**

JAYPEE BROTHERS

I. **Benign neoplasms**
   1. *Papilloma*: Overgrowth of all layers of skin.
   2. *Fibroma*: Tumors of fibrous tissue.
   3. *Lipoma*: Encapsulated subcutaneous lipoma, diffuse variety, multiple lipoma.
   4. *Neurofibroma*: This tumor contains both neural (abdermal) and fibrous (mesodermal elements)
      a. Local neurofibroma
      b. Generalized neurofibromatosis—von Recklinghausen's disease, congenital autosomal dominant, associated with light brown pigmentation, acoustic neuroma, pheochromocytoma
      c. Plexiform neurofibromatosis-branches of fifth cranial nerve
      d. Elephantiasis neurofibromatosis
      e. Pachydermatocele.
   5. *Schwannoma (neurilemmoma)*: Schwann cell neurilemma, benign well encapsulated tumor.
   6. *Lymphangioma*:
      a. Simple/capillary lymphangioma b. Cavernous lymphangioma c. Cystic hygroma.
   7. *Moles (pigmented nevus, freckles, benign melanoma)*:
      a. Hairy mole
      b. Nonhairy or smooth moles
      c. Blue nevus
      d. Junctional nevus
      e. Compound nevus
      f. Juvenile mole
      g. Hutchisons freckle (lentigo).

II. **Malignant**
   1. Basal cell carcinoma 2. Squamous cell carcinoma 3. Malignant melanoma
   4. Sarcoma 5. Synovial sarcoma.

   Other swellings
   a. Sebaceous cyst b. Condyloma c. Warts
   d. Keloid and hypertrophic scar e. Callosity and corn f. Keratoacanthoma
   g. Seborrheic wart h. Solar keratosis i. Bowen's disease.

THYROID SWELLING

History

1. Age
   a. *Teenage girls*: Simple goiter
   b. *Women of 20 to 30*: MNG and SNT
   c. *Young girls*: Papillary CA, primary toxic goiter
   d. *Middle aged women*: Hashimoto's disease, follicular CA
   e. *Old age*: Anaplastic CA.
2. Sex
   a. *Female*: Male—3:1
   b. History of swelling—onset, duration, rate of growth.
   c. Associated with pain—inflammatory conditions are painful—goiter and CA are painless
   d. *History of pressure effect*:
      i. Dyspnea
      ii. Dysphagia
      iii. Hoarseness of voice
      iv. Stridor
   e. History of precipitating emotional or psychic trauma
   f. Physiological stress—puberty, pregnancy, lactation, menopause
   g. History of endemicity.

Symptoms of Primary Thyrotoxicosis

1. Loss of weight in spite of good appetite 2. Excessive sweating
3. Insomnia 4. Protruding eyes (exophthalmos)

JAYPEE BROTHERS

5. Intolerance to heat
6. Smooth and moist skin—irritability
7. Tremor of hands
8. Diplopia (ophthalmoplegia).

Symptoms of Secondary Thyrotoxicosis (Cardiovascular)

1. Palpitation
2. Dyspnea on exertion
3. Swelling of ankles
4. Chest pain.

Symptoms of Hypothyroidism (Myxedema)

1. Increase of weight in spite of poor appetite
2. Dry skin
3. Loss of memory
4. Loss of hair and eyebrows (lateral 1/3rd)
5. Constipation
6. Intolerance to cold
7. Dull expression
8. Puffiness of face
9. Fatigability
10. Lethargy.

Past History

1. *History of radiation*: Papillary CA
2. *History of HTN + thyroid swelling*: Sipple's syndrome
3. *History of similar illness*: Recurrence
4. History of intake of drugs.

Personal History

1. Sleep decreased—hyperthyroidism
2. Menstrual history in females
3. Diet—excessive use of cabbage—goitrogens (brassica family).

Family History

Medullary CA, papillary CA, MNG run in family.

General Examination

Body built and nourishment
1. *Thin and underweight*: Thyrotoxicosis
2. *Obese and overweight*: Hypothyroidism.

Facies

1. *Thyrotoxicosis*: Facial expressions of excitement, tension, nervousness, agitations with exophthalmos
2. *Hypothyroidism*: Puffy face without expression.

Skin

1. *Thyrotoxicosis*: Hot and moist palm
2. *Myxedema*: Dry and inelastic skin.

Local Examination

Inspection

1. *Pizzillo's method*: Hands are placed behind the head, push the head against resistance
2. Shape, size
3. Extent
   a. Vertically—from lower part of thyroid cartilage to 1 cm above suprasternal notch
   b. Horizontally—from anterior border of sternocleidomastoid (SCM) on both side.

JAYPEE BROTHERS

4. Moving with deglutition
5. Lower border visible or not
6. Plane of swelling—deep to deep fascia
7. Skin over the swelling—dilated veins, sinus, scar, fistula, visible pulsations
8. Pemberton's sign—ask patient to lift the hands so that hand touches the ear lobes.

Dilated vein (obstruction of superior vena cava)—Retrosternal goiter.

Sipple's syndrome (Men Type 2)
- Hyperparathyroidism
- Pheochromocytoma
- Medullary carcinoma thyroid.

Pendred's syndrome (Peroxidase enzyme deficiency)
- Congenital deafness
- Goiter
- Hypothyroidism.

Palpation

Three Berry's in Thyroid

Berry's sign: Absent carotid pulsations (anaplastic carcinoma).

1. Palpated with neck slightly flexed
2. Palpation of each lobe
   a. *Lahey's method*: In front of the patient
   b. *Crile's method*: Thumb on thyroid gland on swallow
   c. *Naffziger's method*: Stand behind the patient
3. Local rise of temperature or tenderness
4. Site, size, shape, extent, consistency, margin
5. Surface
   a. *Smooth*: Primary thyrotoxicosis
   b. *Bosselated*: Multinodular goiter (MNG)
6. Mobility
7. Get above the swelling
8. Plane of the swelling—deep to deep fascia
9. *Kocher's test (Test for large swelling)*: Push the thyroid swelling laterally—stridor.

Vitals

1. *Pulse rate*: Rapid and irregular—secondary thyrotoxicosis
2. *Sleeping pulse rate*: Access the degree of toxicity
   a. *Mild*: < 90/min
   b. *Moderate*: 90 to 110/min
   c. *Severe*: 110/min.

Signs of Toxicity

I. *Eye Signs*

1. *Lid retraction*: Over activity of involuntary part of muscle—Smooth part of levator palpebrae superioris and Mullers muscles supplied by cervical sympathetic plexus
2. *Exophthalmos*: Due to infiltration of retrobulbar connective tissue with mucopolysaccharide, immunoglobulins, fluid occurs probably due to lymphatic/venous obstruction
   a. *von Graefe's sign (lid lag)*
   b. *Joffroy's sign (wringling of forehead absent)*
   c. *Stellwag's sign (infrequent blinking of eyes)*: Due to toxic contraction of striated fibers of levator palpebrae superioris
   d. *Möbius sign (inability to converge the eyeball)*
   e. *Dalrymple's sign (upper sclera visible)*: Due to retraction of upper eyelid

JAYPEE BROTHERS

3. *Ophthalmoplegia*: Weakness of ocular muscles
   Muscles affected—superior and lateral rectus, inferior oblique.
4. *Chemosis (edema of conjunctiva)*:

II. *Delayed Ankle Jerk (Hypothyroidism)*

III. *Tachycardia*

IV. *Tremor*

V. *Moist Skin*

VI. *Thyroid Bruit*

Cardiovascular System Changes

Inc heart rate (HR) → ectopics → AF → VT → VF.

Mechanism of Eye Signs

1. **Lid lag and lid spasm** are due to hyperthyroidism and are also seen in secondary hyperthyroidism and disappears on correcting hyperthyroidism.
2. **Diplopia** develops in Grave's disease due to weakness of elevators especially internal oblique.
3. **Edema** of the eye lid conjunctival congestion and chemosis are due to compression of ophthalmic vein.
   Thyroidectomy or radio iodine therapy are contraindicated in proptosis of recent onset as it may produce malignant **exophthalmos**.

Percussion

1. Normally resonant over manubrium sterni
2. Dull in retrosternal goiter.

Auscultation

1. Lateral aspect of upper lobe
2. Bruit due to increased vascularity.

Skull and Spine

Cardiovascular System (CVS)

Gastrointestinal System (GIT)

Respiratory

Position of trachea.

Diagnosis

Treated multinodular thyroid without any features of thyrotoxicosis or malignancy.

Investigations

1. Blood and urine R/E
2. Thyroid function test
3. X-ray neck—retrosternal thyroid
4. Indirect laryngoscopy

JAYPEE BROTHERS

5. FNAC—cannot distinguish between follicular adenoma and CA
6. Isotope scan I-123
7. Bone scan
8. Thyroid antibodies
9. Trucut biopsy
10. Serum cholesterol increased in hypothyroidism
11. Serum calcitonin increased in medullary CA (normal < 0.08 mg/L)
12. USG, CT, MRI.

Thyroid Function Test

1. T4 (10–30) nmol/L
2. T3 (3.5–7.5) micromol/L
3. TSH (0.3–3.3) milliunit/L.

Treatment

Medical

Hyperthyroidism

1. Thyroid inhibitors (Inhibiting thyroid hormone synthesis) methimazole, carbimazole, propylthiouracil
2. *Inhibit iodide trapping*: Thiocyanates, perchlorates, nitrates
3. *Destroy thyroid tissue*: Radioactive iodine I-131, I-125, I-123
4. β *blockers (Prevent T4 → T3)*: Propranolol.

Hypothyroidism

Thyroxine doses OD.

Surgical

Preoperative Preparations

1. Carbimazole 30–40 mg/day for 8 to 12 weeks after 12 weeks reduce the dose to 5 mg 8th hourly
2. Last dose given on evening before surgery
3. Thyroxine added to maintain the euthyroid state
4. Lugol's iodine (5–10 drops) orally with milk (to decrease vascularity and size of tumor)
5. Potassium iodide (KI)/Sodium iodide (NaI) (60 mg tid) alternative to Lugol's iodine—10 days before operation
6. Propranolol (40 mg TDS) or nadolol (160 mg once daily)—inhibit the conversion of T4 → T3
7. Indirect laryngoscopy (ENT consultation) medicolegal purposes
8. Three drug regime—Antithyroid + Lugol's iodine + β blocker.

Block and Replacement Surgeries

T3 (20 mg up to 4 times daily) or T4 (0.1 mg/day) + antithyroid drugs → Less danger of producing thyroid insufficiency and increase in size of goiter.

Thyroxine Doses

1. Supplementary 0.1 mg
2. Replacement 0.2 mg
3. Suppressive 0.3 mg.

Thyroid Surgeries

1. Isthumusectomy
2. *Lobectomy*: Total lobectomy + isthumusectomy
3. *Subtotal thyroidectomy*: Total lobectomy + total lobectomy+ isthumusectomy
4. *Near total thyroidectomy*: Total lobectomy + isthumusectomy + subtotal lobectomy.

JAYPEE BROTHERS

Strap Muscles of Neck

1. *Superficial*: Sternohyoid, omohyoid
2. *Deep*: Thyrohyoid, sternothyroid.

Postoperative assessments

1. Indirect laryngoscopy
2. Serum Ca after surgery
3. Withhold the thyroxine until HPR results are available and proceed accordingly
4. Life long follow-up for thyrotoxicosis
5. Propranolol should be continued for 7 days postoperative as it does not inhibit thyroxin synthesis but acts on the end organs.

Postoperative Complications

Immediate

1. *Hemorrhage*: Tension hematoma; subcutaneous hematoma.
2. *Respiratory obstruction*: Collapse of trachea; laryngeal edema; tension hematoma.
   Rx: Release tension hematoma; endotracheal tube (ET) intubation; steroids reduce edema tracheostomy (rarely); needle tracheostomy (temporary measure).
3. *RLN paralysis*
   a. Unilateral/bilateral
   b. Transient/permanent—recovers in 3 weeks to 3 months.
4. *Thyroid crisis or thyroid storm*
   a. Acute exacerbation of hyperthyroidism
   b. Occurs in a thyrotoxic patient inadequately prepared for thyroidectomy.

Management of thyroid crisis

General

1. IV fluids
2. Cooling the patient with ice packs
3. Oxygen administration
4. Diuretics for cardiac failure
5. Digoxin for uncontrolled AF
6. Sedation
7. Hydrocortisone IV.

Specific

1. Carbimazole 10–20 mg 6th hourly
2. Lugol's iodine 10 drops 6th hourly orally or NaI IV
3. Propranolol 40 mg 6th hourly orally.

Late Complications

Hypoparathyroidism (hypocalcemia)

1. Due to removal of parathyroid gland or damage to parathyroid end artery
2. Occurs at the end of 2nd day (half-life of parathyroid is 2 to 5 days).

Symptoms

1. Perioral numbness
2. Carpal spasm
3. Tingling sensation of fingers
4. Tetany
5. Severe painful cramps
6. Laryngeal spasm.

Management: 10% calcium gluconate IV 10 mL slowly for 10 minutes.

1. *Thyroid insufficiency*: Occurs within 2 years
2. Wound infection
3. *Hypertrophic/keloid scar Rx*: Intradermal injection of corticosteroid
4. Stitch granuloma
5. Laryngeal paralysis.

JAYPEE BROTHERS

Berry's Ligament

Berry picking: Removal of lymph nodes.

Stages of development of thyrotoxic arrhythmias.

1. Multiple extrasystole
2. Paroxysmal atrial tachycardia
3. Paroxysmal atrial fibrillation
4. Persistent atrial fibrillation not responding to digoxin.

Sites of Aberant Thyroid Tissue

1. Lingual
2. Cervical
3. Intrathoracic.

Neuberg's artery: Thyroid ima artery
Koker's vein: Vein between middle and inferior thyroid vein draining into internal jugular vein (IJV).
Nerve of galagussi: External laryngeal nerve—supplying cricothyroid.

Multiple Endocrine Neoplasia

MEN 1 or Wermer Syndrome

1. Pituitary adenoma or hyperplasia
2. Parathyroid adenoma or hyperplasia
3. Pancreatic islet cell hyperplasia, adenoma or carcinoma
4. Less common manifestations—foregut carcinoids; pheochromocytoma; subcutaneous or visceral lipomas.

MEN 2A or Sipple Syndrome

1. Medullary carcinoma of thyroid
2. Pheochromocytoma
3. Parathyroid adenoma or hyperplasia
4. Hirschsprung's disease
5. Cutaneous lichen amyloidosis.

MEN 2B

1. Medullary carcinoma of thyroid
2. Pheochromocytoma
3. Marfanoid features
4. Mucocutaneous and gastrointestinal neuromas.

Multinodular Goiter—Stages

Stage 1: Diffuse hypertrophy and hyperplasia of gland
Stage 2: Fluctuating levels of thyroid stimulating hormone (TSH)
Stage 3: Active lobules undergo central necrosis leads to nodular formation.

Complications of Multinodular Goiter

1. Acute respiratory obstruction due to hemorrhage
2. Secondary thyrotoxicosis
3. Calcification
4. Carcinomatous changes.

Treatment

1. *If asymptomatic*: No surgery
2. *If symptomatic*: Subtotal thyroidectomy after toxic symptoms are decreased—postoperative thyrotoxins.

JAYPEE BROTHERS

Indications for Operation

1. Malignancy
2. Toxic adenoma
3. Pressure symptoms
4. Cosmetic
5. Patient wishes.

Wayne's Clinical Diagnostic Index

Score

1. < 11 Hypothyroidism
2. 11–13 Euthyroid
3. > 13 Hyperthyroidism
4. > 19 Toxic.

Eye Manifestations in Toxic Goiter (No Specs Criteria)

Grade 0 : **N**o signs
Grade 1 : **O**nly signs
Grade 2 : **S**ymptoms present—diplopia, periorbital edema
Grade 3 : **P**roptosis > 1.5 cm
Grade 4 : Extraocular manifestations
Grade 5 : **C**orneal ulcer
Grade 6 : **S**ight loss.

Clinical Features of Hyperthyroidism

1. Weight loss
2. Tachycardia
3. Atrial fibrillation/heart failure
4. Eye signs—lid lag, lid retraction, exophthalmos (Grave's disease)
5. Sweating
6. Thyroid gland enlargement and bruit (Grave's disease)
7. Fine distal tremor
8. Thinning of hair
9. Proximal weakness; cannot rise from squat
10. Chorea.

Clinical Features of Hypothyroidism

1. Weight gain
2. Shallow complexion and dry skin
3. Thinning of scalp and lateral eyebrow hair
4. Cold intolerance
5. Deepened gruff voice
6. Slow physical and mental activity
7. Unsteadiness and slightly slurred speech
8. Tingling in toes and fingers
9. Aching muscles with cramp
10. Mild proximal weakness
11. Slow pulse and shortness of breath.

Causes for Hypothyroidism (GET AIDS)

1. **G**oitrogens
2. **E**ndemic
3. **T**hyroid agenesis
4. **A**utoimmune—Chronic lymphoma, Hashimoto's disease
5. **I**atrogenic
6. **D**yshormonogenesis
7. **S**econdary to pituitary or hypothalamic disease.

Myxedema Coma

Clinical Features

1. Altered mental state
2. Hypothermia
3. Precipitating cardiac failure
4. Infection.

Management

1. Slow warming of body
2. Broad spectrum antibiotics IV
3. Injection hydrocortisone divided dose
4. 500 ng T4 /10 mg T3 IV/orally every 4 to 6th hourly.

JAYPEE BROTHERS

Thyroiditis

Autoimmune Thyroiditis

Clinical features
Bosselated goiter (hyperthyroidism)—initially and later hypothyroidism due to fibrosis sudden and painful, common after menopause associated with papillary CA, malignant lymphoma.

Diagnosis
1. Raised thyroid antibody titer
2. Thyroid function test (TFT) gives hypothyroid status
3. FNAC.

Treatment
1. Replacement dose 0.2 mg TID
2. Steroid—if goiter increases in size or no response to thyroxin
3. Thyroidectomy—if goiter is large and causes discomfort.

Granulomatous Thyroiditis

Granulomatous thyroiditis (Subacute thyroiditis, De Quervain's thyroiditis)—due to viral infection.

Clinical features
Pain in neck, fever, malaise, firm irregular enlargement of one/two lobes.

Diagnosis
1. Raised ESR
2. Thyroid antibodies absent
3. Serum T4 level high normal or slightly raised
4. I-131 reuptake decreased.

Treatment
Subsides spontaneously within few months.
Prednisolone 10 to 20 mg once daily (OD) for 7 days (dose is gradually reduced over next month).

Riedel's Thyroiditis

1. Thyroid tissue is replaced by cellular fibrous tissue which infiltrates—muscles, adjacent structures, parathyroid, recurrent nerves, carotid sheath
2. Goiter may be U/L or B/L
3. Very hard and fixed–hypothyroidism.

Diagnosis
Wedge biopsy.

Treatment
High dose steroid.
Thyroxine replacement dose.
Isthmusectomy—reduction in size of goiter.

Risk of Malignancy in Thyroid Swelling

Rule of Twelve

Isolated thyroid swelling		**Dominant thyroid swelling**	
Solid 24%	Cystic 12%	Solid 12%	Cystic 6%
Male 48%	Female 12%	Male 24%	Female 6%
Male 24%	Female 6%	Male 12%	Female 3%
Generalized thyroid swelling 3%			

JAYPEE BROTHERS

for detailed information on medicine books, visit our website www.jaypeebrothers.com, for detailed information on medicine books, visit our websi

SYNAPZ

The Complete Final MBBS Manual

Salient Features

- Thoroughly revised and updated edition
- Authentic references from latest editions of standard textbooks
- Provides essential facts in a way which is easy to remember
- Mnemonics make the subject easier and interesting
- Drug of choice for the common medical conditions are given in tabular form
- Evidence-based guidelines to tackle objective structured clinical examinations
- Stepwise operative procedures, neatly narrated
- Numerous diagrams, tables, flow charts and instruments have been incorporated to enable grasping of maximum information in minimum time
- A collection of Frequently Asked Questions consisting of essays and short notes
- Useful for quick revision in all topics, before going for clinical examination and also useful for postgraduate students.

Available at all medical bookstores
or buy online at www.jaypeebrothers.com

JAYPEE BROTHERS
Medical Publishers (P) Ltd.
www.jaypeebrothers.com

Join us on facebook.com/JaypeeMedicalPublishers

ISBN 978-93-5152-890-6