ed information on obstetrics & gynecology books, visit our website **www.jaypeebrothers.com,** for detailed information on obstetrics & gynecology books, visit our website **www.jaypeebrothers.com**

Ian Donald

JAYPEE

# *Donald School*
# *Atlas of Advanced Ultrasound in*
# OBSTETRICS & GYNECOLOGY

Includes DVD-ROM

**Ritsuko Kimata Pooh**
**Asim Kurjak**

*Foreword*
**Frank A Chervenak**

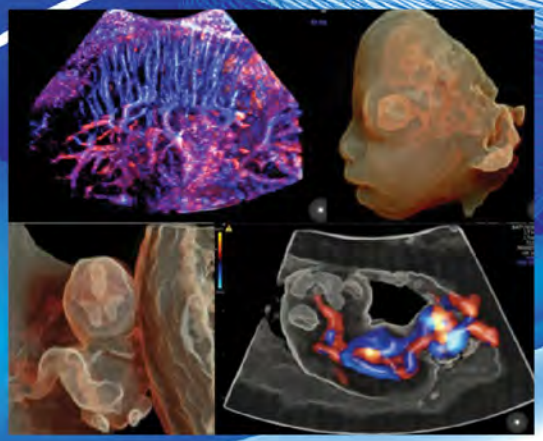

# Contents


| | | |
|---|---|---|
| Special Chapter | **Brand New Technology of HDlive Silhouette and HDlive Flow Images**<br>**(See video clip 1 )**<br>*Ritsuko Kimata Pooh* | **1** |
| **1.** | **Early Normal Pregnancy (Before 11 Weeks)**<br>**(See video clip 2 )**<br>*Ritsuko Kimata Pooh* | **39** |
| **2.** | **Early Abnormal Pregnancy (Before 11 Weeks)**<br>**(See video clip 3 )**<br>*Asim Kurjak, Ritsuko Kimata Pooh* | **65** |
| **3.** | **Normal Fetus in the 1st Trimester (11 to $13^{+6}$ Weeks)**<br>**(See video clip 4 )**<br>*Ritsuko Kimata Pooh* | **89** |
| **4.** | **Fetal Abnormality in the 1st Trimester (11 ≤$13^{+6}$ Weeks)**<br>**(See video clip 5 )**<br>*Ritsuko Kimata Pooh* | **111** |
| **5.** | **Normal and Abnormal Placenta, Membranes and Cord in the 1st Trimester (≤$13^{+6}$ Weeks)**<br>**(See video clip 6 )**<br>*Ritsuko Kimata Pooh* | **255** |

| | | |
|---|---|---|
| 6. | **Late Abnormalities in the 2nd and 3rd Trimesters (≥14$^{+0}$ Weeks)**<br>**(See video clip 7)**<br>*Ritsuko Kimata Pooh* | **287** |
| 7. | **Placenta, Membranes and Cord: Normal and Abnormal**<br>**(See video clip 8)**<br>*Giuseppe Calì* | **619** |
| 8. | **Basic Ultrasound in Gynecology and Infertility**<br>**(See video clip 9)**<br>*Asim Kurjak* | **651** |
| 9. | **Infertility**<br>**(See video clip 10)**<br>*Sonal Panchal* | **679** |
| 10. | **HDlive Images in Gynecology and Reproduction**<br>**(See video clip 11)**<br>*Fernando M Bonilla-Musoles* | **785** |
| 11. | **Ultrasound and the Pelvic Floor**<br>**(See video clip 12)**<br>*Ashok Khurana* | **855** |
| *Index* | | *879* |

CHAPTER

2

# Early Abnormal Pregnancy (Before 11 Weeks)

— Asim Kurjak, Ritsuko Kimata Pooh

JAYPEE BROTHERS

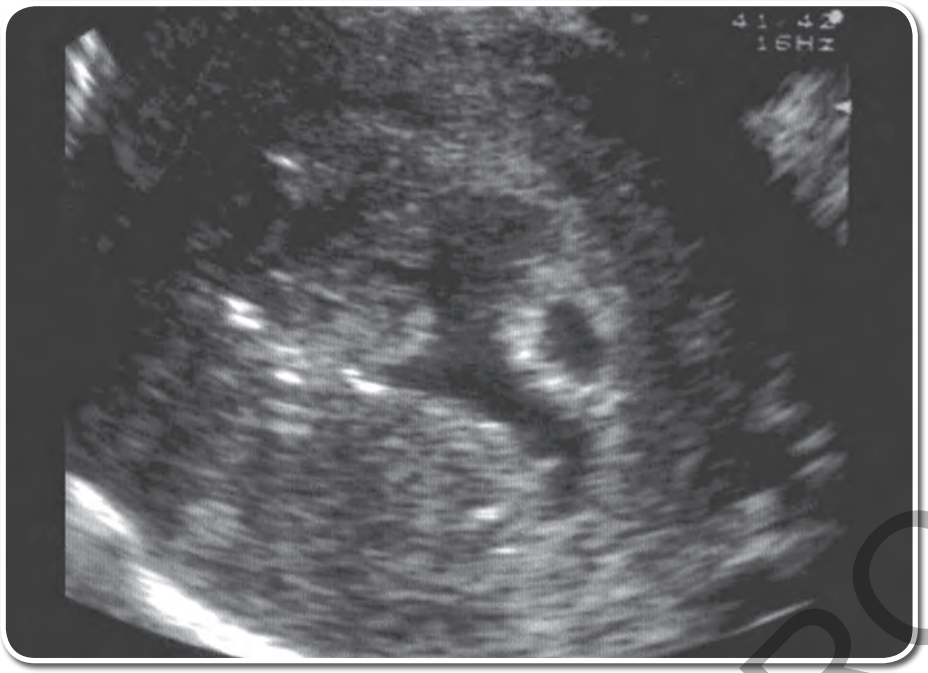

Figure 1: Progressive abortion.
Disorganized ehogenic debris, fluid and residual trophoblastic debris are visible




Figure 2: Missed abortion.
Avascular embryo at 7th week is demonstrated

JAYPEE BROTHERS

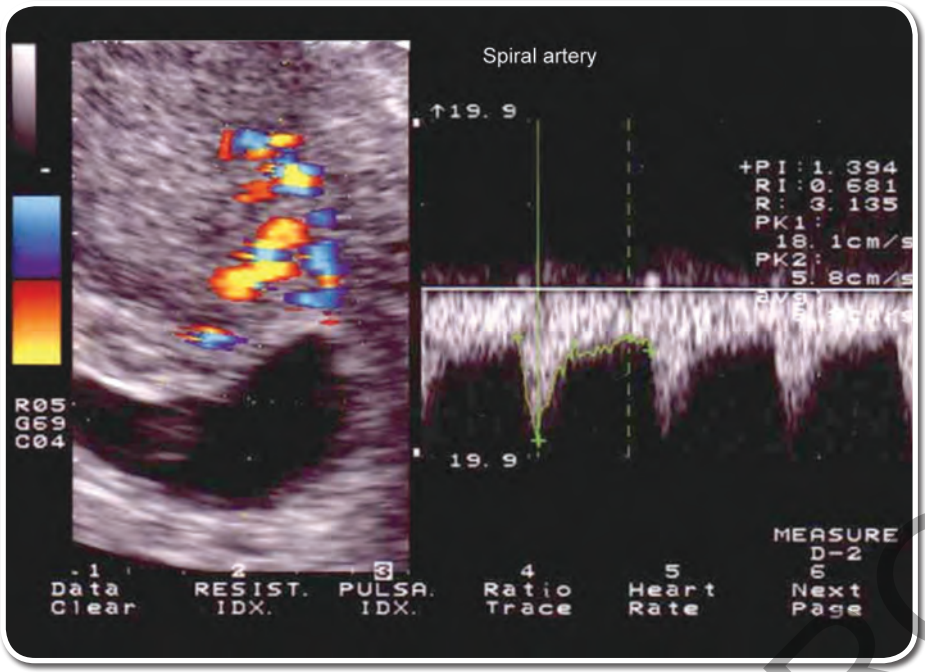


**Figure 3: Spiral artery flow in missed abortion. Increased RI (resistive index) of spiral arteries within the intravillous space in a case of missed abortion**

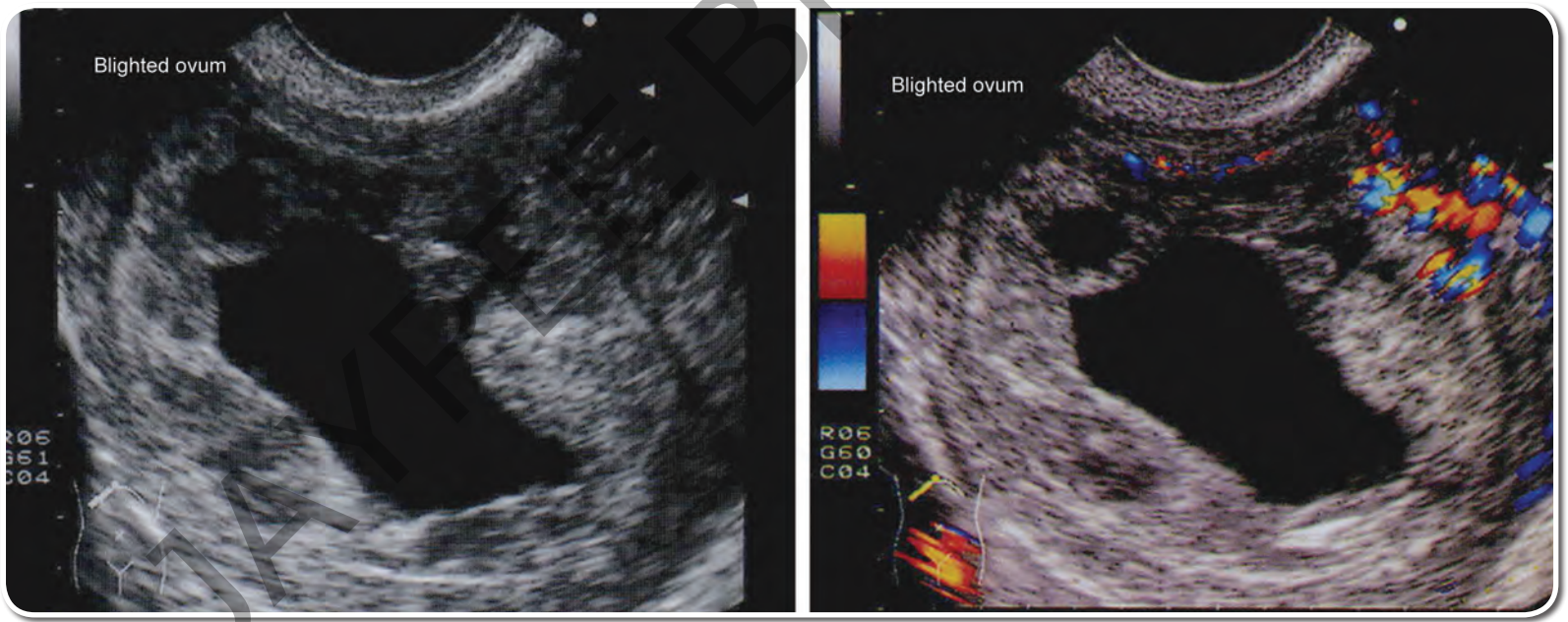


**Figure 4: Blighted ovum. Absence of embryonic echoes within a gestational sac**

JAYPEE BROTHERS

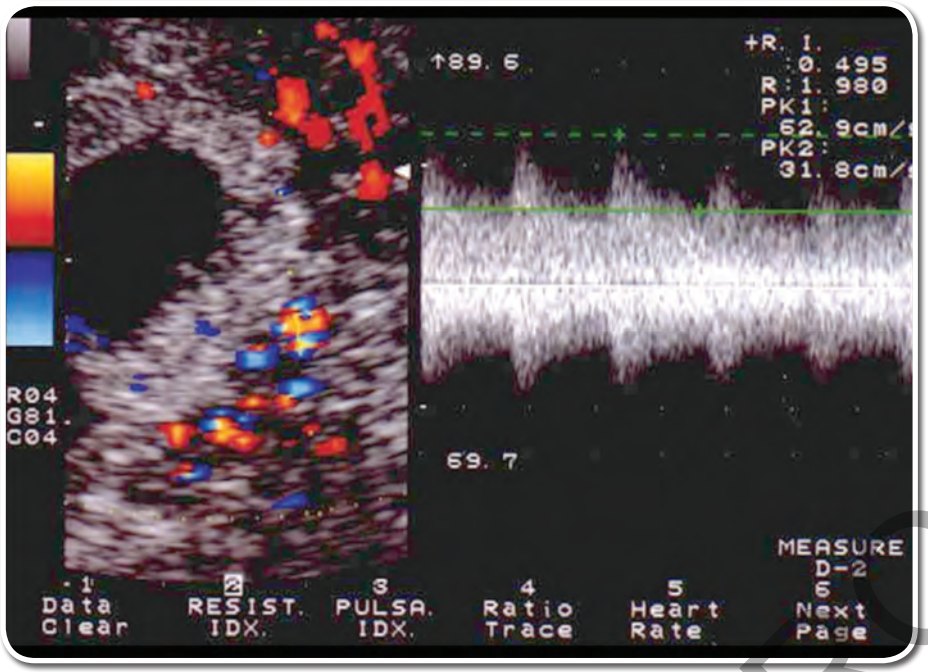


**Figure 5: Blighted ovum, spiral artery flow. Increased intervillous circulation is confirmed by pulsed Doppler**

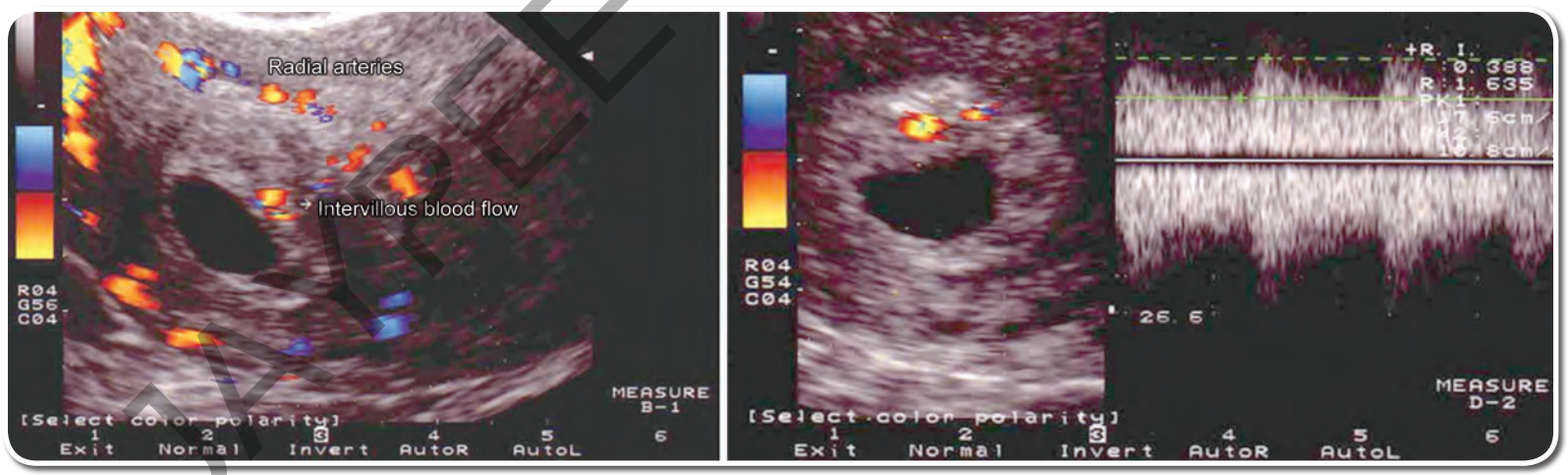


**Figure 6: Blighted ovum, spiral artery flow.**
**Increased intervillous circulation with decreased RI within the intervillous space is confirmed by pulsed Doppler**

JAYPEE BROTHERS

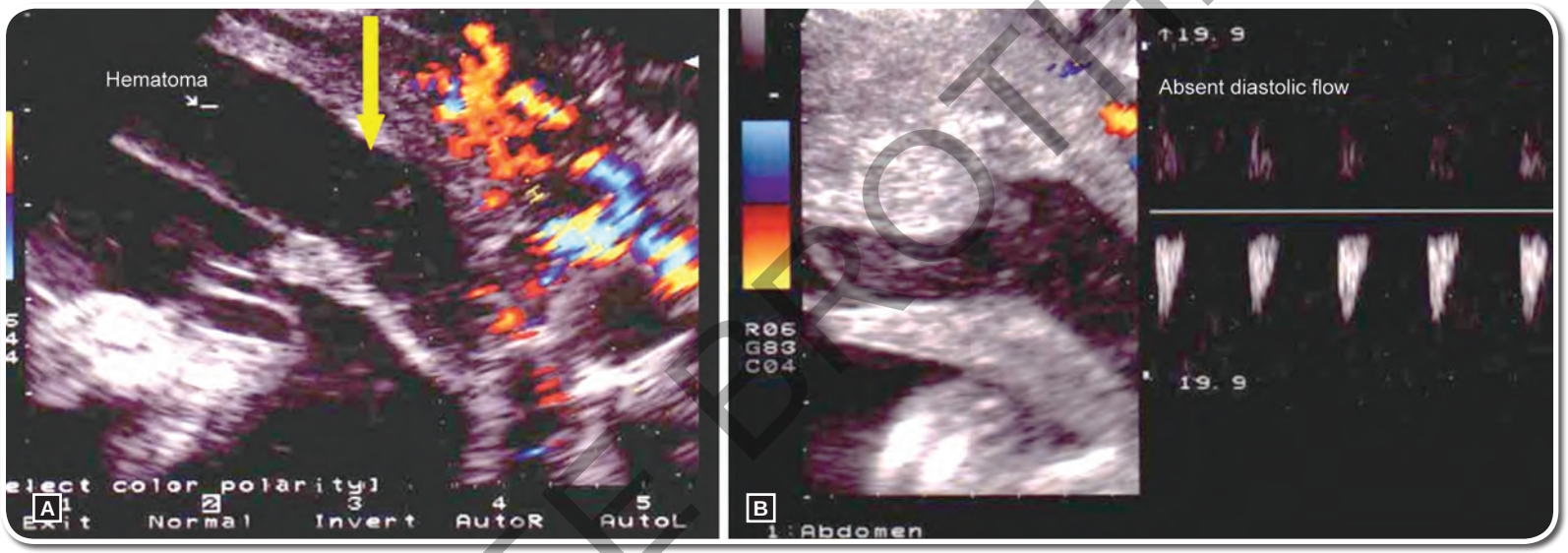


**Figure 7: Subchorionic hematoma.**
**(A) Echo-free space (arrow) is visible. (B) Absent diastolic flow of spinal artery in a case of subchorionic hematoma**

JAYPEE BROTHERS

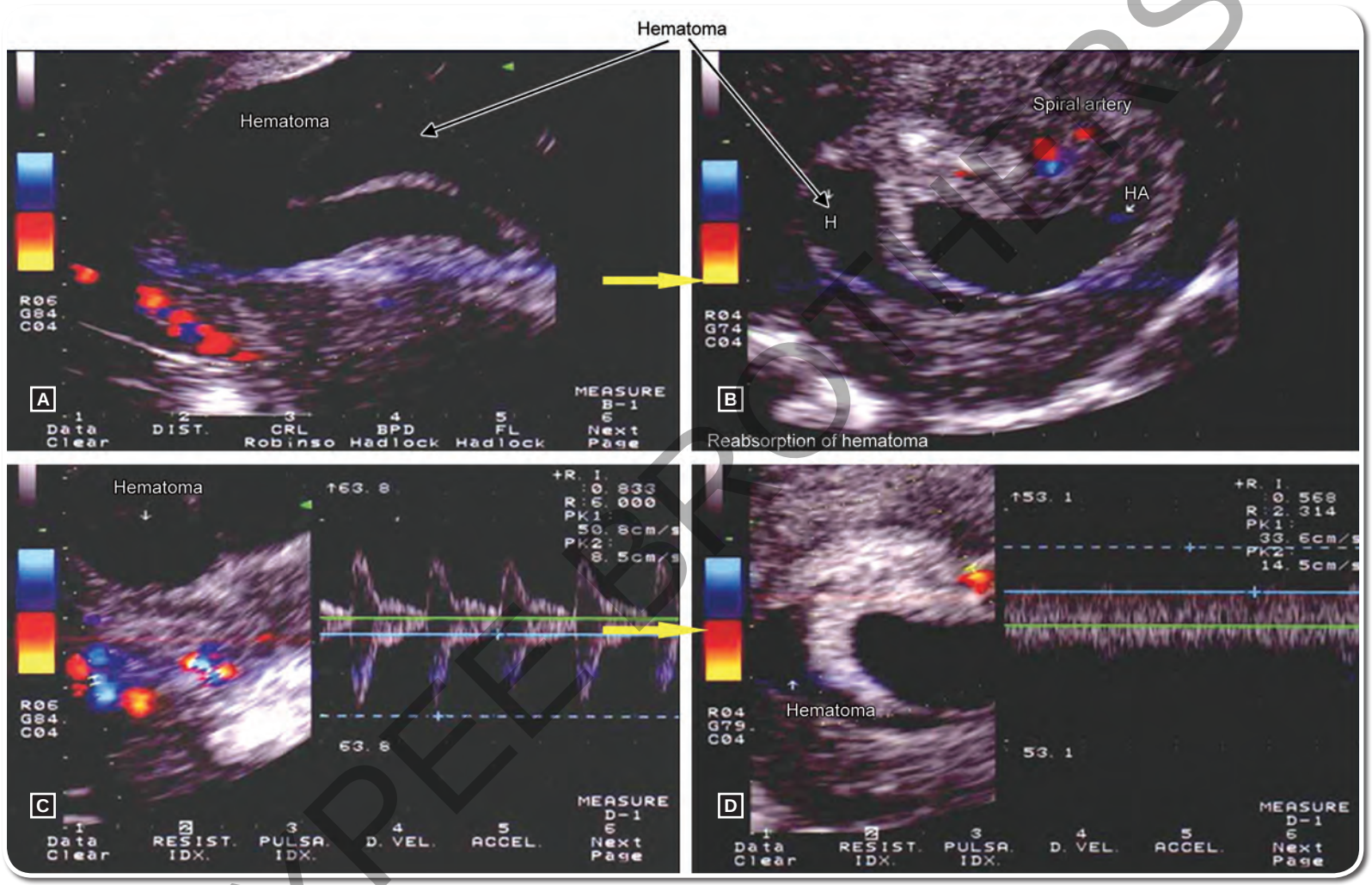


**Figures 8A to D: Spiral artery flow change after reabsorption of subchorionic hematoma.**
**(A) Large hematoma is demonstrated. (B) Pulsed Doppler image. Increased RI of spiral artery is depicted.**
**(C) Reduced size of hematoma after reabsorption is visible. (D) Increased diastolic flow with low RI (resistive index) of spiral artery is depicted**

JAYPEE BROTHERS

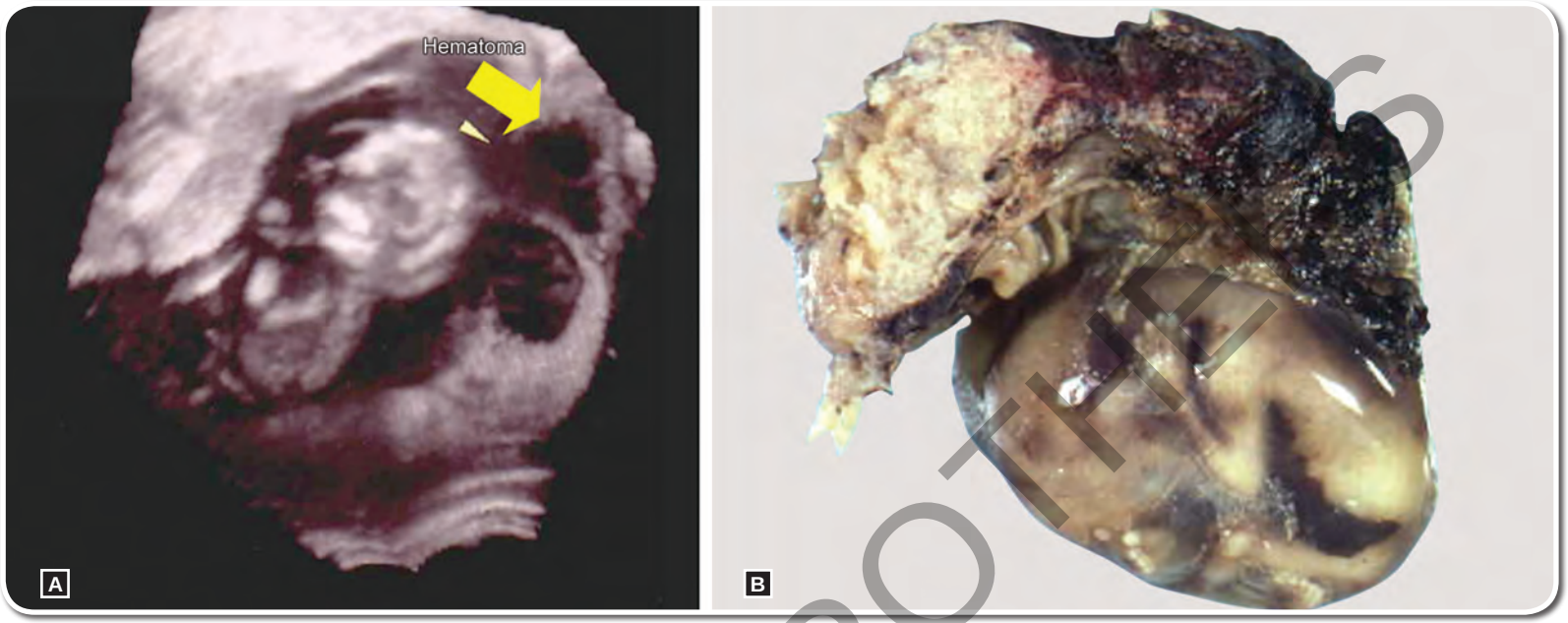


**Figures 9A and B: Subchorionic hematoma with intrauterine fetal demise. (A) Echo-free space (arrow) is hematoma. (B) Picture from aborted fetus**




**Figure 10: Dichorionic gestation with one blighted twin, differential diagnosis from subchorionic hematoma.**
**Echogenic ring and thick wall separating the gestational sac indicate blighted twin not subchorionic hematoma**

JAYPEE BROTHERS

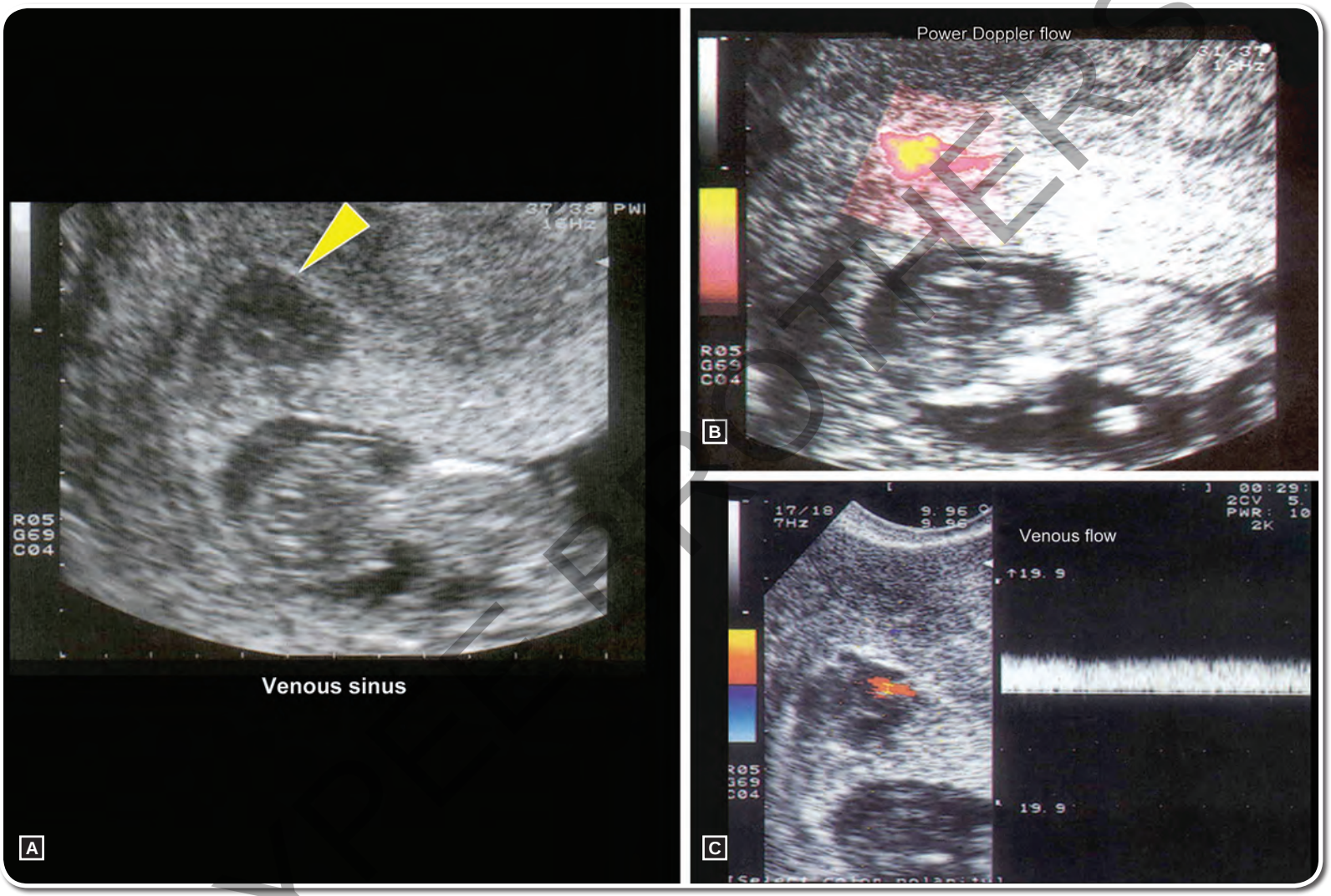


**Figures 11A to C: Venous sinus, differential diagnosis from subchorionic hematoma.**
**(A) 2D image demonstrates the echo-free space (arrowhead) and subchorionic hematoma was suspected. (B) Power Doppler image shows the vascularity inside echo-free space with venous flow. (C) The space was venous sinus not subchorionic hematoma**

JAYPEE BROTHERS

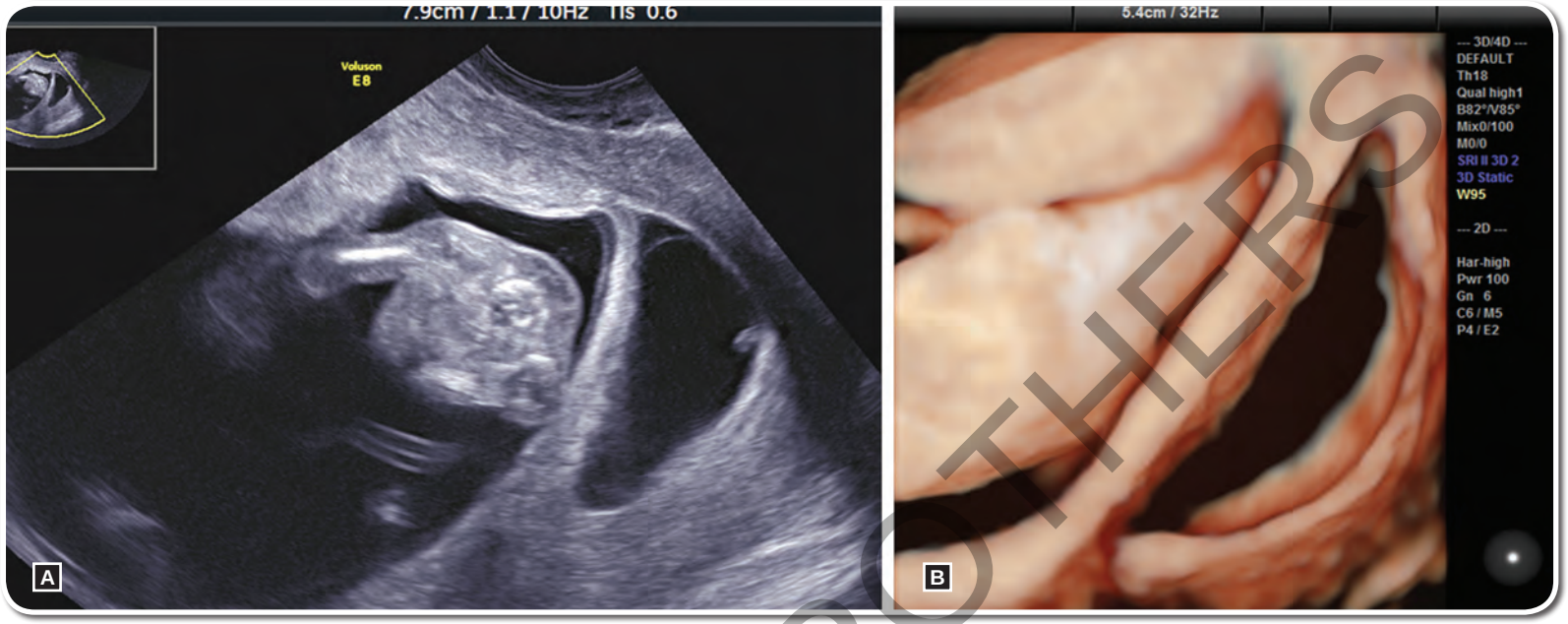


**Figures 12A and B: Vanishing twin at 12 weeks. (A) 2D image. (B) 3D HDlive image**

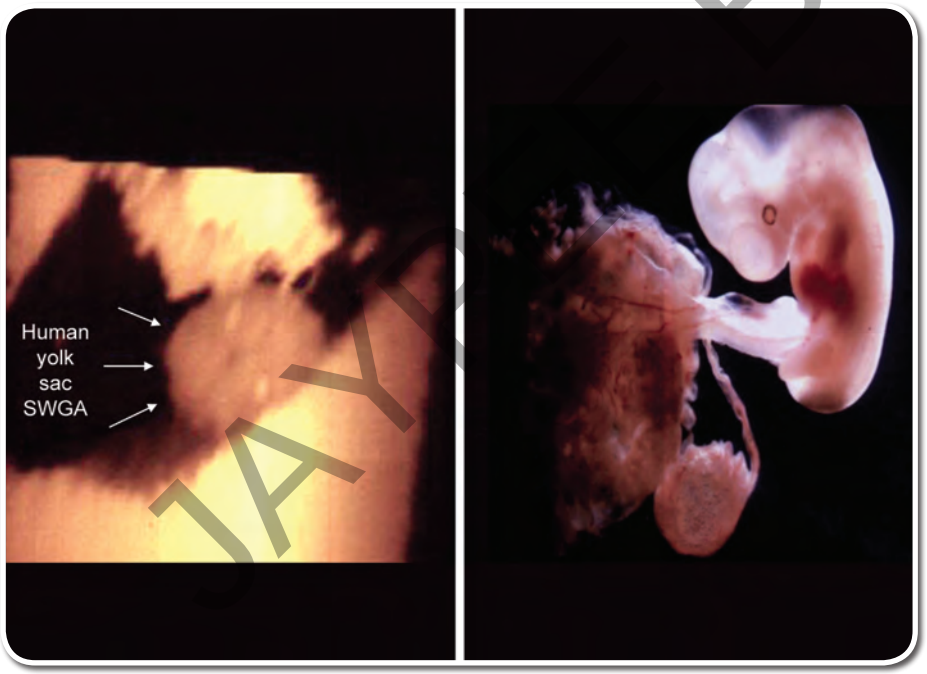


- The 1st structure to be visualized
- It is an extra-amniotic structure
- The inner diameter during the 1st trimester is 3–6 mm:
  - 4–5 mm in diameter until 7–8 weeks
  - 6 mm by the end of the 9th week
  - After the 9th week it starts its regressing and disappears at the 12th week
- Function
  - Protein secretion
  - Primary source of blood and germ cells
- Morphological differentiation
  - Physiological midgut herniation
  - Early abdominal wall defect

**Figure 13: Normal yolk sac**

JAYPEE BROTHERS

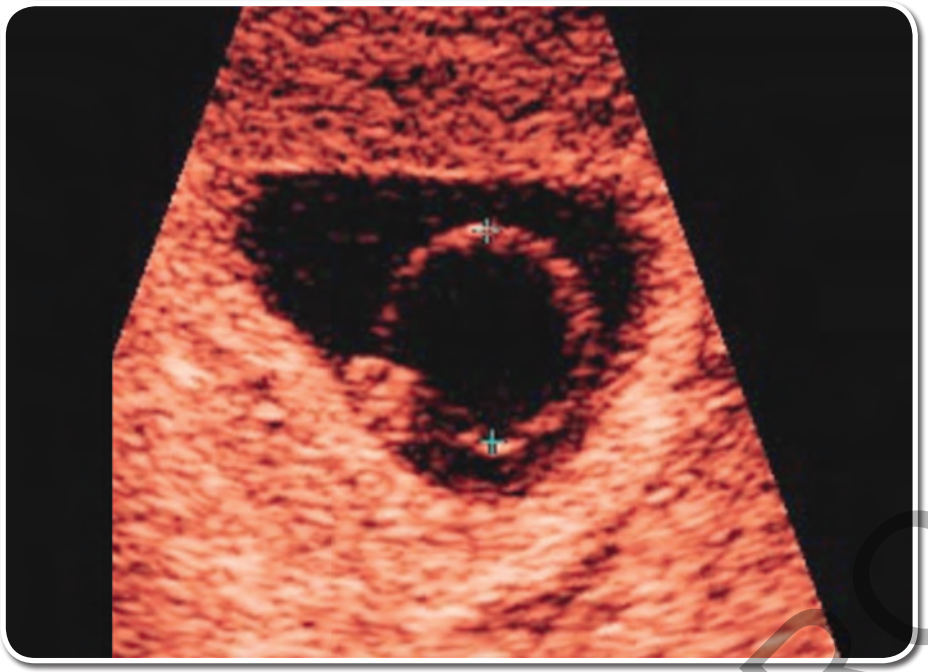

Figure 14: Large yolk sac.
Large yolk sac with dead embryo is observed

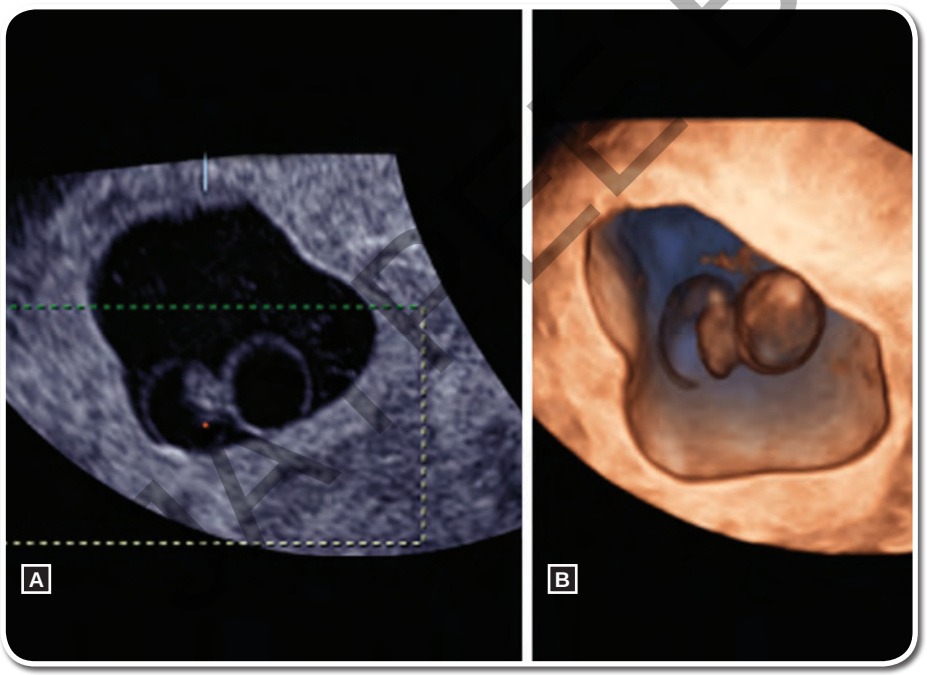


Figure 15A and B: Large yolk sac.
(A) 2D image. (B) 3D HDlive image. Large yolk sac is one of the ominous signs of fetal loss

JAYPEE BROTHERS

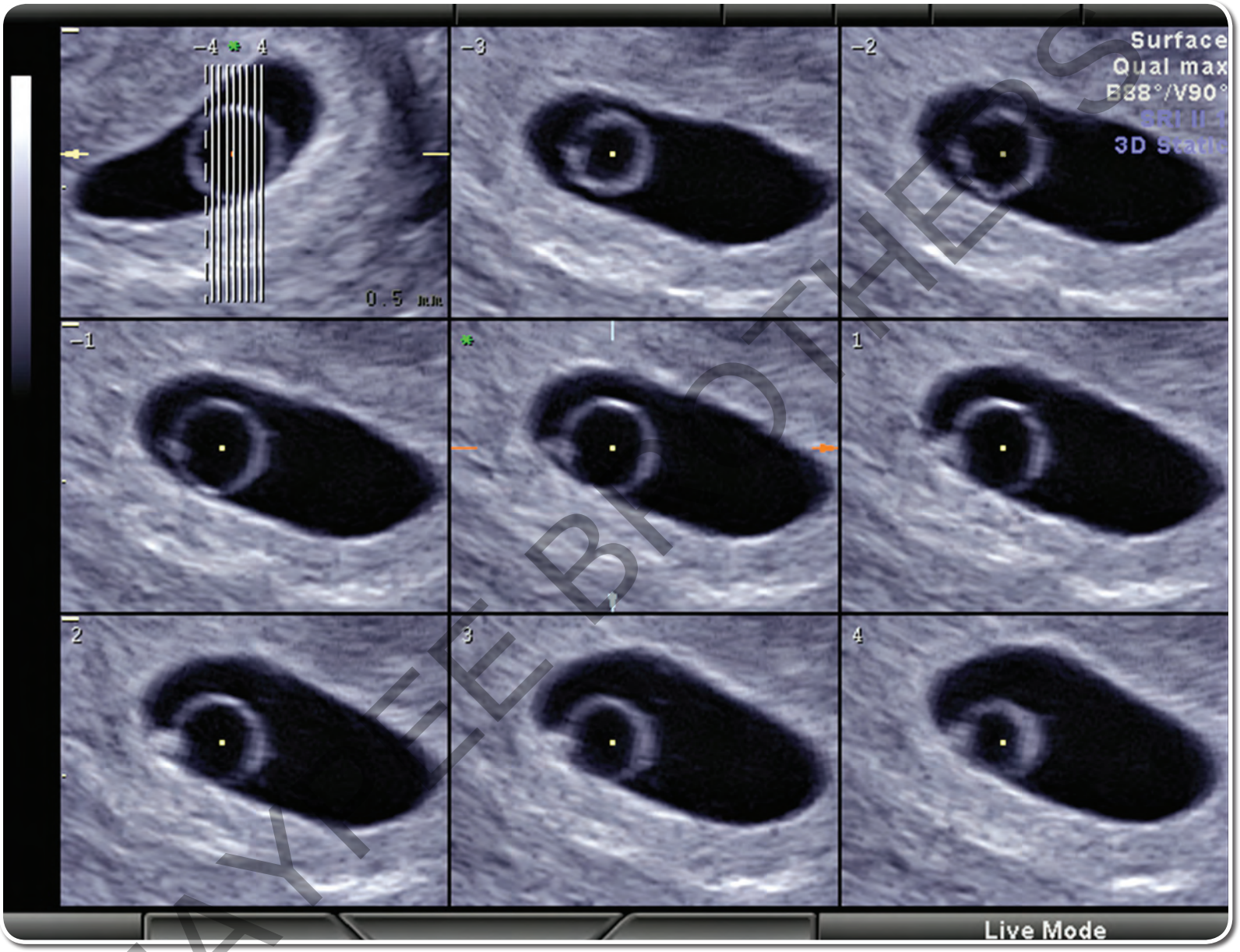


JAYPEE BROTHERS

**Figure 16: Tomographic imaging of large yolk sac at 6 weeks of gestation.**
**Large yolk sac with normal fetal heartbeat was observed. Fetal demise was confirmed at 8 weeks. Villous chromosome examination resulted in 47, XY, +22**

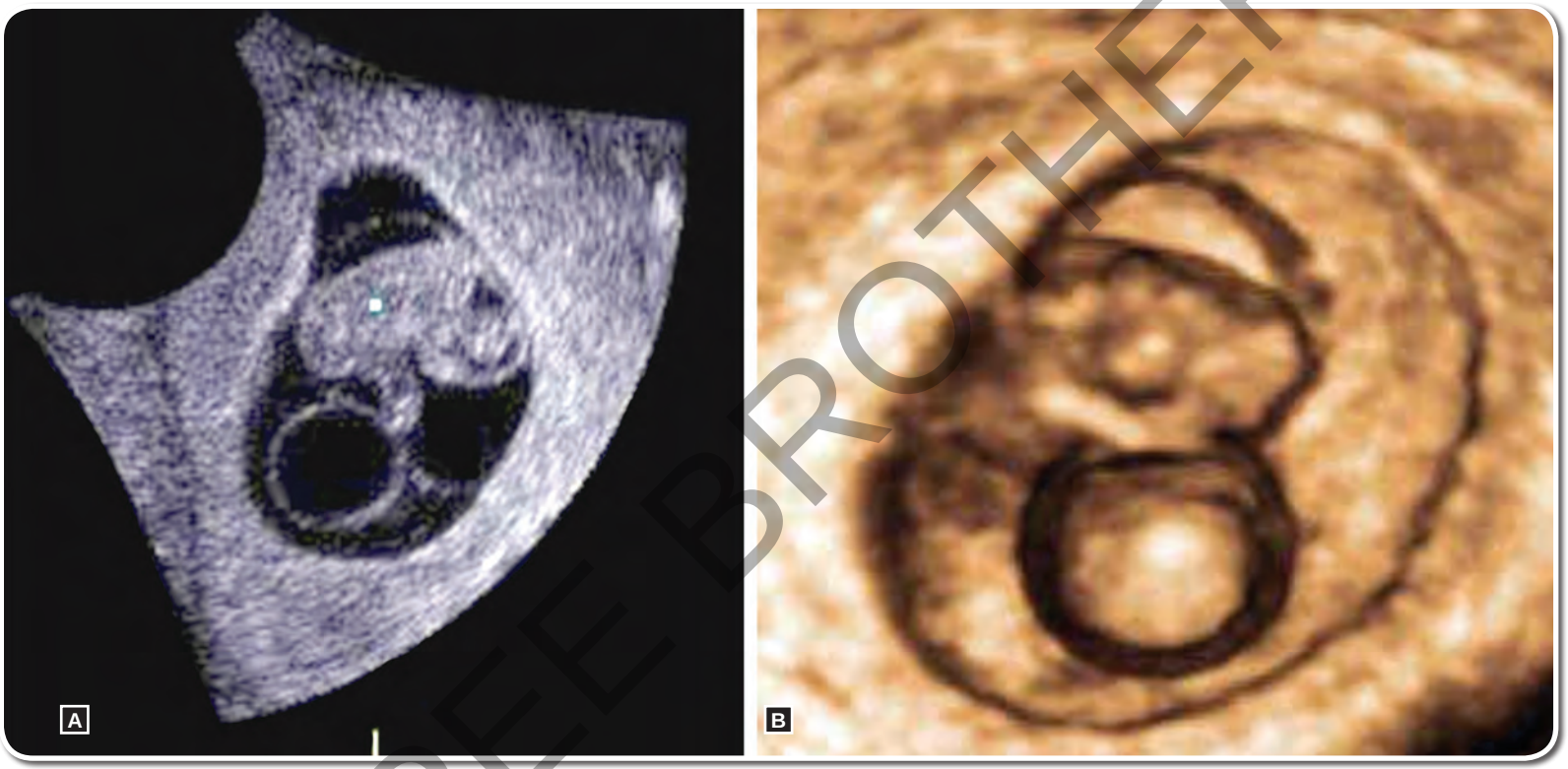


**Figures 17A and B: Large yolk sac at 8 weeks of gestation.**
**(A) 2D sagittal section of the fetus. Normal appearance of 8-week-fetus and amniotic membrane are visible, but large yolk sac with 12 mm of diameter is demonstrated. (B) 3D image. Intrauterine fetal demise was confirmed 30 hours later. Villous chromosome examination resulted in doubled trisomy of 48, XY, +15,+21**

JAYPEE BROTHERS

detailed information on obstetrics & gynecology books, visit our website **www.jaypeebrothers.com,** for detailed information on obstetrics & gynecology books, visit our website **www.jaypeebrothe**

*Donald School*
# *Atlas of Advanced Ultrasound in* OBSTETRICS & GYNECOLOGY

*Donald School Atlas of Advanced Ultrasound in Obstetrics and Gynecology* is a compilation of ultrasound images in the all fields of obstetrics and gynecology. Ultrasound technology has been greatly advanced and rapidly revealed the pathophysiology from the beginning of life. 'Fetal Diagnosis' is diagnosis of 'Fetus' and it is reasonable that many have doubts about prenatal diagnosis without observing the fetus. For accurate diagnosis and proper management, multidisciplinary approach should be required with genetic and pathological investigation combined with precise imaging.

This book shows how accurately and how precisely the state-of-the-art fetal ultrasound can reveal detailed morphology. Sonographic images often provide more important clinical information than molecular genetic technology. Recent up-to-date advanced high definition live technology, HDlive Silhouette and HDlive flow (in Special Chapter) released on October of 2014 detect more and more accurate and objective phenomena and provide us hints for further research investigation.

Ultrasound is the very first modality with noninvasive, direct-viewing, all-inclusive technology and infinite potential. Our very last words for practitioners are '*Fetus First*' and '*Ultrasound, Ultrasound and Ultrasound…*'

**Ritsuko Kimata Pooh** MD PhD is the President, CRIFM Clinical Research Institute of Fetal Medicine PMC, Osaka, Japan. She is specialized in fetal neurology, sonoembryology, and sonogenetics. She has previously published 2 textbooks on *Fetal Central Nervous System, Diagnosis and Management* and *Fetal Neurology*.



**Asim Kurjak** MD PhD is Professor of Obstetrics and Gynecology at Medical School Universities of Zagreb and Sarajevo. He is the Rector of DIU Libertas International University and Director of Ian Donald Inter-University of Medical Ultrasound. He has published over 400 peer-review original research articles, and has contributed to over 100 textbooks.



**Available at all medical bookstores or buy online at www.jaypeebrothers.com**

**JAYPEE BROTHERS Medical Publishers (P) Ltd.**
**www.jaypeebrothers.com**

Join us on facebook.com/JaypeeMedicalPublishers

Shelving Recommendation
**OBSTETRICS & GYNECOLOGY**

ISBN 978-93-5152-919-4