mation on PGMEE books, visit our website www.jaypeebrothers.com, for detailed information on PGMEE books, visit our website www.jaypeebrothers.com



2nd Edition

Chief Editors
Rajamahendran
Antan Uresh Kumar
J Madhan
A Balaji

KONCPT 20 Authors

for Tamil Nadu PG Entrance Examination

Volume 2

Orthopaedics, Medicine, Surgery, Obstetrics, Gynaecology, Paediatrics, Psychiatry, Radiodiagnosis and Radiotherapy, Anaesthesia, and Dermatology

- Last 15 years original TNPG questions from 2001 to 2015.
- Written/Reviewed by 20 different subject specialists.
- 100 percent authenticated points.
- Highly recommended for AIPG also.

Contents

1. **Orthopaedics** 1
   P Selvaraj
2. **Medicine** 139
   Suthantira Kannan S
3. **Surgery** 285
   R Rajamahendran
4. **Obstetrics** 502
   Anuradha Dhanasekharan
5. **Gynaecology** 617
   Anuradha Dhanasekharan
6. **Paediatrics** 698
   Aparna C
7. **Psychiatry** 839
   K Raman
8. **Radiodiagnosis and Radiotherapy** 874
   K Vino Bharath
9. **Anaesthesia** 943
   Prem Kumar
10. **Dermatology** 995
    J Madhan, M Garthick Arivudainambi

CHAPTER 1

Orthopaedics

P Selvaraj

BASIC SCIENCE

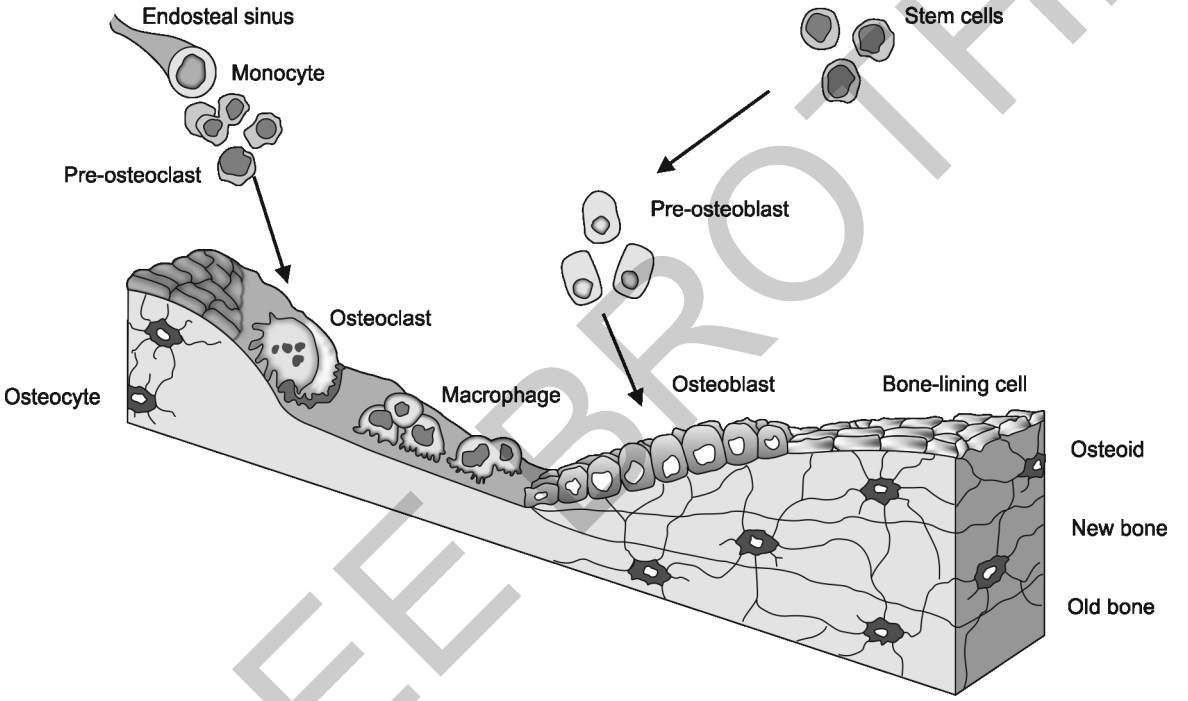

Fig. 1: Bone cells

COMPOSITION OF BONE

- Inorganic (Mineral) --~65% of dry weight
- Organic (Matrix) --~35% of dry weight

Organic Matrix: Constitutes about one third of the dry weight of bone. It consists of 90% collagen, which is the ***most abundant bone protein***, exclusively ***type I collagen***.

The non-collagenous proteins present in the bone are osteonectin;

- Osteocalcin,
- Osteopontin and
- Bone sialoprotein.

Inorganic (Minerals): The mineral amounts to about two thirds of the total dry weight of bone. Chemically it is ***Ca. Hydroxyapatite*** $(Ca_{10}(PO_4)_6(OH)_2$.

JAYPEE BROTHERS

THE BONE CELLS

1. **The osteoblasts** are derived from mesenchymal stem cells located in the bone marrow, are the cells that **synthesize the bone matrix.** Subsequently, this matrix calcifies extracellularly. Till this matrix gets mineralized it is called osteoid. (The unmineralized bone matrix is called **osteoid.**)
2. **The osteocytes:** Once the osteoblasts become encased in osteoid, they become relatively quiescent and are termed as **osteocytes.**
3. **The osteoclasts** are large, multinucleated cells, **derived from monocyte macrophage system.** The role of osteoclasts is to resorb the bone.

Osteoblasts are the main cells responsible for laying down new bone in the form of **osteoid** These cells are derived from pleuripotent stromal precursor cells (mesenchymal stem cells) and are the active cells that lay down new bone during skeletal growth and remodeling.

These cells produce **alkaline phosphatase**—an enzyme used to identify bone forming activity. As the bone matures, osteoblasts become encased in the new bone; then, they are known as ***osteocytes.***

In mature bone, osteocytes are located extremely far away from neighboring cells and communicate with other cells through long cytoplasmic processes. The osteocytes remain quiescent until stimulated by hormonal or mechanical factors to begin to reabsorb or lay down bone.

Osteoclasts are derived from circulating monocytes. They are responsible for bone resorption. Osteoclasts form a ***ruffled border*** that attaches to the osteoid and secretes proteolytic enzymes that degrade the bone matrix. As such, osteoclasts form active reabsorption cavities called **Howship lacunae.**

Bone is a dynamic entity regulated by osteoblasts, which are responsible for bone formation, and osteoclasts, which are responsible for bone resorption.

Peak bone mass is established between 20 and 30 years of age.

Markers of Bone Formation

Serum

- Osteocalcin (OC)
- Bone-specific alkaline phosphatase
- Total alkaline phosphatase
- Procollagen I C-terminal extension peptide
- Procollagen I N-terminal extension peptide

Markers of Bone Resorption:

Serum

- Tartrate-resistant acid phosphatase
- Tartrate-resistant acid phosphatase 5b C-terminal cross-linking telopeptide of type I collagen.
- N-terminal cross-linking telopeptide of type I collagen
- C-terminal cross-linking telopeptide of type I collagen generated by metalloproteinases

Urine

- Deoxypyridinoline (D-Pyr)
- Pyridinoline (Pyr)
- Hydroxyproline (Hyp)
- C-terminal cross-linking telopeptide of type I collagen (CTX)
- N-terminal crosslinking telopeptide of type I collagen (NTX)

Microscopically, a bone may be woven or lamellar.

- Woven bone, also called primary bone, is characterized by a random arrangement of cells and collagen, a relatively disoriented composition. Woven bone is associated with periods of rapid formation, such as the initial stages of fracture repair or biologic implant fixation. Woven bone, which has a low mineral content, remodels to lamellar bone.

JAYPEE BROTHERS

- **Lamellar bone** is a slower forming, mature bone that is characterized by an orderly cellular distribution and regular orientation of collagen fibers.

FORMATION OF SKELETON

- During early **fetal life** the human skeleton is mostly cartilaginous, but is subsequently largely replaced by bone.
- **In adults,** cartilage persists at the surfaces of synovial joints, in the walls of the larynx and epiglottis, trachea, bronchi, nose and external ears.
- Developmental replacement by bone is a complex process: cells in cartilaginous growth plates-which lie between ossifying epiphyses and the diaphyses of long bones-continue to proliferate, increasing the length of the bones concerned until they eventually ossify.

Two Mechanisms of Bone Formation

- The *transformation* of fibrous primitive connective tissue into bone is called **intramembranous ossification.** All flat bones viz pelvis, skull and clavicle are formed by this process.
- The **replacement** of cartilage by bone is called endochondral ossification. All long bones of the skeletal system are formed by **endochondral ossification except clavicle.**

FRACTURE HEALING

The fracture healing involves five stages:

1. Haematoma,
2. Inflammation,
3. Soft Callus Formation,
4. Hard Callus Formation,
5. Remodeling.

Hematoma induces attraction of inflammatory infiltrate. Granulation tissue gradually replaces the hematoma, fibroblasts produce collagen.

Abundant new cartilage formation marks the soft callus stage.

During hard callus stage, the callus converts to woven bone.

The **final stage** of the healing process involves slow remodeling from woven to lamellar bone and reconstruction of the medullary canal.

Wolff's law: bone remodels in response to mechanical stress. (Increasing mechanical stress leads to significant bone gain.)

BONE HEALING

The bone heals by laying of new bone tissues; this is in contrast to other tissues which usually heal by fibrous tissue giving rise to scarring.

Bone healing is important in fracture conditions irrespective of surgical or non-surgical management. There are two types of bone healing.

1. **In primary fracture healing**, the fracture unite ***without the formation of callus*** (osteonal or Haversian healing). This occurs when the fracture surfaces are rigidly held in contact by ***ORIF using Plates.***
2. ***Secondary fracture healing*** results in the ***formation of callus*** and involves the participation of the periosteum.

E.g. Fractures managed by ***casting, intramedullary nailing*** etc.

When healing progresses more slowly than average, it is referred to as **delayed union**. Failure of bone healing, or **nonunion,** results from an arrest of the healing process.

A nonunion that occurs despite the formation of a large volume of callus around the fracture site is referred to as a **hypertrophic nonunion**, in contrast to an **atrophic nonunion** where little or no callus forms and bone resorption occurs at the fracture site.

In some nonunions, cartilaginous tissue forms over the fracture surfaces and the cavity between the surfaces fills with a clear fluid resembling normal joint or bursal fluid creating a **pseudoarthrosis,** or false joint.

JAYPEE BROTHERS

Nonunion: a fracture that fails to show progressive evidence of healing over a ***4 to 6-month*** period can be considered a nonunion.

The common causes are: ***inadequate blood supply, inadequate immobilization of the fracture, soft-tissue interposition, infection***.

Nonunions have been classified according to their radiologic characteristics. **Hypertrophic nonunions** have viable bone ends, whereas **atrophic nonunions** have nonviable bone ends. This differentiation has importance both in prognosis and in determining appropriate treatment.

THE SYNOVIUM

It provides nutrients to cartilage and produces lubricants for the joint. The intimal lining of the synovium has two different cells.

- Type A *macrophage-like*
- *Type 2 fibroblast-like synoviocytes.*

Type A synoviocytes: they are bone marrow derived; represent cells of the mononuclear phagocyte system.

Type B synoviocytes: represent a resident fibroblast population in the synovial lining. They ***produce the essential joint lubricants*** hyaluronic acid (HA) and lubricin. They also synthesize normal matrix components, including fibronectin, laminin, collagens, proteoglycans, etc.

SYNOVIAL FLUID ANALYSIS

Group	Appearance	Cell Count/μL	Neutrophils%	Typical Diagnosis
Normal	Clear, colorless to straw colored.	< 100	< 25	None
I (Non-inflammatory)	Clear, straw colored, good string	200–2,000	< 25	Degenerative arthritis, internal derangement, trauma, aseptic necrosis
IIA (Mild inflammatory)	Faintly cloudy, moderate string	1,000–10,000	25–50	Systemic lupus erythematosus, rheumatoid arthritis, spondyloarthropathies.
IIB (Severe inflammatory)	Translucent but cloudy, yellow, drops like water	2,000–75,000	50–75	Moderate to severe rheumatoid arthritis, gout, pseudogout, tuberculosis.
III (Septic arthritis)	Creamy, opaque	> 50,000	> 80	Acute gout, bacterial infection

SYNOVIAL FLUID ASPIRATES

- A frankly bloody fluid: tumor, trauma, or hemophilia.
- A dark brown fluid full of hemosiderin is seen in hemophilia and pigmented villonodular synovitis.
- Fat floating on a bloody fluid indicates fracture or tumor exposing the marrow cavity to the synovial space.
- Small white clots ("rice bodies") represent tuberculous arthritis.

IMAGING IN ORTHOPAEDICS

Study	Comment
X-ray	Standard study, multiple views needed, shows bones well, but soft tissues poorly. The joint above and below a fracture should always receive plain film. Bone destruction + periosteal new bone formation: indicates infection or malignancy until proven otherwise.
CT	Best study for bony anatomy. Soft tissue seen, but not as well as MRI. Often used for comminuted fractures and preoperative planning.
MRI	Best study for soft tissues including intervertebral discs, ligaments, tendons. Also highly sensitive for osteonecrosis; T1 images weighted for fat (good for normal anatomy), T2 images weighted for water (better for pathology). Also used for preoperative planning

Contd...

JAYPEE BROTHERS

Contd...

Study	Comment
Bone scan	Radioactive isotope injected into blood. Imaging of the whole body allows visualization of areas of increased uptake. The clinical applications include 1.stress fractures 2.small bone abscess or osteoid osteoma 3. Loosening of protheses or infection of prostheses 5.avascular necrosis.
Arthrography	Contrast injected into joint followed by plain films to evaluate capsular integrity (e.g. used for rotator cuff tears)
Myelography	Contrast injected into epidural space; evaluates disc herniation, cord tumors.
Discography	Contrast injected into nucleus pulposus to evaluate disc degeneration. Not a common procedure.
Ultrasound	Good for evaluating rotator cuff pathology, CDH.

PHYSIOTHERAPY

Heat can be applied by

1. Radiation (infrared light),
2. Conduction (hot packs, paraffin, or water)
3. Conversion (diathermy or ultrasound).

Radiation and conduction are forms of ***superficial heat***, whereas conversion (diathermy or ultrasound) are forms of ***deep heat***.

Superficial heat can increase the threshold for pain, produce analgesia by acting on free nerve endings, and decrease muscle spasm.

Electrotherapy: Galvanic currents slow down pain conduction in slow unmyelinated nerve fibers (C fibers) to reduce pain. The gate control principle works with all classic forms of electrotherapy and with transcutaneous electrical nerve stimulation ***(TENS).***

Common indications for TENS are musculoskeletal pain, post-traumatic or postsurgical pain, peripheral nerve injury, neuropathic pain, phantom limb pain, and sympathetically mediated pain.

Ultrasound is a special form of heating. It interacts with skin, fat, muscles, and bones during treatment. Heating occurs mostly at tissue interfaces. Ultrasound is used for patients with localized musculoskeletal pain secondary to tendinitis or osteoarthritis of various joints.

AMPUTATIONS

During amputation surgeries, the muscles usually are divided at least 5 cm distal to the intended bone resection.

The stump may be stabilized by one of these two methods.

- Myodesis: suturing muscle or tendon to bone
- Myoplasty: suturing muscle to periosteum or to fascia of opposing musculature).

Myodesis is contraindicated in severe ischemia because of the increased risk of wound breakdown.

Complications

Infection,

Wound Necrosis

Contractures

Pain (Mechanical low back pain, Residual limb pain, painful neuroma, Phantom limb pain),

Contact dermatitis, Verrucous hyperplasia.

Ideal Bone Length

- Femur: Resect 12 cm from knee

JAYPEE BROTHERS

- Tibia: Leave at least 14 cm
- Forearm: 18 cm
- Humerus: 20 cm

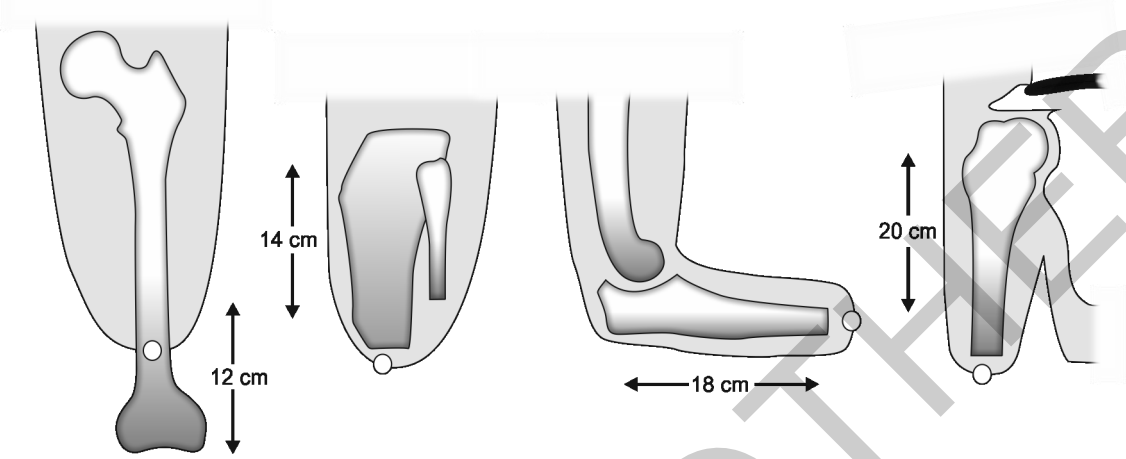

Fig. 2: Amputation levels

Midfoot Amputations

- ***Lisfranc amputation:*** a disarticulation at tarso-metatarsal joint.
- ***Chopart amputation:*** a midtrasal amputation; removes the forefoot and midfoot and saves only the talus and calcaneus.

Hind Foot Amputations

- ***Boyd's amputation*** consists of a talectomy and calcaneal-tibial arthrodesis.
- ***Pirogoff's ampuation*** consists of a talectomy with calcaneal-tibial arthrodesis after the vertical transection of the calcaneus.
- These two types of hindfoot amputations are done mostly in children to preserve length and growth centers, prevent heel pad migration, and improve socket suspension.
- ***Syme's amputation*** consists of amputation at the distal tibia and fibula 0.6 cm proximal to the periphery of the ankle joint and passing through the dome of the ankle centrally.

QUESTIONS

1. Most abundant protein in the bone? *(TN 2000)*
   a. Type 1 collagen
   b. Type 2 collagen
   c. Osteonectin
   d. Osteopontin

2. Marker of new-born formations is: *(TN 2013)*
   a. Acid phosphatase
   b. Alkaline phosphatase
   c. Hydroxyl proline
   d. Telopeptides

3. Structural support to the bone is provided by:
   a. Collagen *(TN 2013)*
   b. Bone cells
   c. Periosteum
   d. Inorganic ground substance

4. Fracture healing is characterized by: *(TN 2013)*
   a. Callus formation
   b Cartilage
   c Granulation tissue
   d Fibrous tissue

5. Fracture disease can be prevented by: *(TN 2013)*
   a External fixation
   b. Internal fixation
   c. Cast treatment
   d. Physiotherapy

JAYPEE BROTHERS

ANSWERS AND EXPLANATIONS

1. Answer (a) Type 1 collagen *(Ref: Apley's system of Orthopaedics and Fractures, 9/e p118)*
2. Answer (b) Alkaline phosphatase *(Ref: Serum Alkaline Phosphatase Concentration Reflects Osteoblastic Activity page 145,)*
3. Answer (a) Collagen Type I *(Ref: While the collagenous component lends tensile strength to bone, the crystalline mineral enhances its ability to resist compression Page 119:)*

   (Apley's system of Orthopaedics and Fractures, 9/e page 118: collagen fibres, derived from tropocollagen molecules produced by osteoblasts, make up over 80 per cent of the unmineralized matrix. They form a network which embodies proteoglycans ground substance and also acts as a scaffold on which the mineral component–crystalline hydroxyapatite – is deposited.
4. Answer (a) Callus formation *(Ref: Apley's system of Orthopaedics and Fractures, 9/e p690)*

   "Healing by callus: this is the 'natural' form of healing in tubular bones; it proceeds in five stages.'
   - Haematoma formation
   - Inflammation
   - Callus formation
   - Consolidation
   - Remodelling"
5. Answer (c) Physiotherapy *(Ref: Apley's system of Orthopaedics and Fractures, 9/e p698)*

TRAUMA

FRACTURE

Fracture is a break in the normal continuity of a bone. The clinical features are ***Severe pain Swelling, Deformity, Abnormal mobility, Crepitus.***

Based on the cause, a fracture maybe

- Traumatic
- Pathological
- Stress

Open fractures are also called as ***Compound*** fractures.

When the fractured fragments are more than two, it is known as ***comminuted*** fracture.

The fracture pattern depends on the type of load (force) acting on the bone.

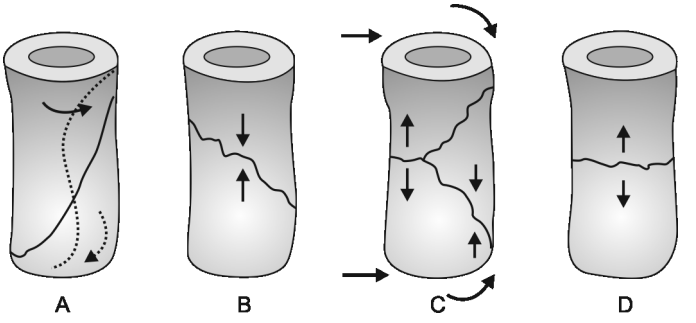

Figs 3 (A to D): Types of force and Fracture pattern

JAYPEE BROTHERS

Fx pattern	*Type of force*
(a) Spiral pattern:	twisting
(b) Oblique pattern:	compression
(c) Triangular 'butterfly' fragment:	bending
(d)Transverse pattern:	tension/direct

STRESS FRACTURES

- Occur in normal bone when the bone is subjected to ***unaccustomed*** stresses
- Commonly seen in young active adults involved in vigorous and excessive exercise- e.g. ***army or police recruits***.
- Radiographs may be normal in early satege; and may show healing/healed fracture line after a few weeks.
  - Radionuclide imaging, CT and MRI can be helpful for occult fractures.
  - Treatment is by ***rest, protection in cast***.
  - Second metatarsal neck is the most likely site for stress fracture (March fractures).

Other common sites are femoral neck, femoral shaft, tibia (medial tibial stress syndrome), calcaneum, talus and the bones of upper extremity.

PATHOLOGICAL FRACTURES

- Fractures may occur even with normal activity or trivial force if the bone has been ***weakened*** by a pathological process. (e.g. osteoporosis, osteogenesis imperfecta, Paget's disease, bone cyst or a metastasis)
- The most common cause is ***osteoporosis,*** and the most common site is ***spine.***

FAT EMBOLISM SYNDROME

- A unique orthopedic manifestation of ***ARDS*** caused by the release of marrow fat into the circulation following fractures of major bones such as pelvis, femur.
- Pathologic examination of the lungs shows fat droplets, usually diffusely distributed throughout the pulmonary vasculature.
- It can result in severe pulmonary compromise and death.

COMPARTMENT SYNDROME

- Increased intra compartmental pressures and decreased perfusion resulting in myonecrosis. **5 P's:** ***Pain, parathesias, paralysis, pallor, pulselessness*** (all are not needed for diagnosis).
- ***Pain*** is the earliest and most consistent symptoms; whereas the ***pulse*** may still be palpable even after the syndrome is fully established.
- Clinically, the affected limb is very firm and tense on palpation.
- In trauma cases, ***fracture*** is the most common cause; and severe soft tissue injury without fracture may too predispose to compartment syndrome.
- Most common fractures associated with acute compartment syndrome are leg bone (***tibial****) fracture* and ***forearm*** *bone fractures .*
- When the compartment pressure is more than 30mmHg, then ***emergency fasciotomy*** must be performed to save the limb.

VOLKMANN'S ISCHEMIC CONTRACTURE

- If a compartment syndrome is ***untreated or inadequately treated***, compartment pressures continue to increase until irreversible tissue ischemia occurs.
- Volkmann ischemic contracture is the end result of this ischemic tissue injury. The earliest changes usually involve the ***flexor digitorum profundus*** muscles in the middle third of the forearm.
- The typical clinical picture **of established Volkmann contracture** includes elbow flexion, forearm pronation, wrist flexion, thumb adduction, metacarpophalangeal joint extension, and finger flexion.
- Clinically, passive extension of fingers is possible only after the wrist is flexed. This is called ***Volkmann's sign.***

OPEN FRACTURE OR COMPOUND FRACTURE

The fracture that involve exposure of bone to the outside environment through a traumatic wound.

JAYPEE BROTHERS

Gustillo and Anderson Classification:
(for open fractures)

- ***Grade I:*** clean wound less than 1 cm long.
- ***Grade II:*** laceration is more than 1 cm long, but there is no extensive soft-tissue damage.
- ***Grade III***: extensive wounds more than 10 cm in length, significant fracture comminution. Usually a high-energy injury . Grade III injuries are divided into subtypes A, B, and C.

Grade IIIA: open fractures have extensive soft-tissue lacerations, but ***soft-tissue coverage about the fracture is usually well preserved.*** Includes segmental or severely comminuted fractures, regardless of the size of the wound.

Grade IIIB: open fractures have extensive soft-tissue loss with ***periosteal stripping and bony exposure.*** They usually are massively contaminated.

Grade IIIC: open fractures with an ***arterial injury*** that requires repair regardless of the size of the soft-tissue wound.

Open fracture Treatment: Adequate wound irrigation and ***debridement*** are the most important steps in open fracture treatment.

EPONYMOUS FRACTURES

- ***Jefferson Fracture***: burst fractures of atlas C1.
- ***Hangman's Fracture:*** Traumatic Spondylo- listhesis of axis (C2) - mechanisms involve hyperextension and distraction.
- ***Clay shoveler's fracture*****:** An avulsion of the spinous processes of the lower cervical and upper thoracic vertebrae.
- ***Chance Fractures*****:** Seat Belt injury, due to Flexion-Distraction force involving lumbar spine.
- ***Crescent fracture***: Fracture of iliac wing on side of impact due to lateral compression of pelvis.

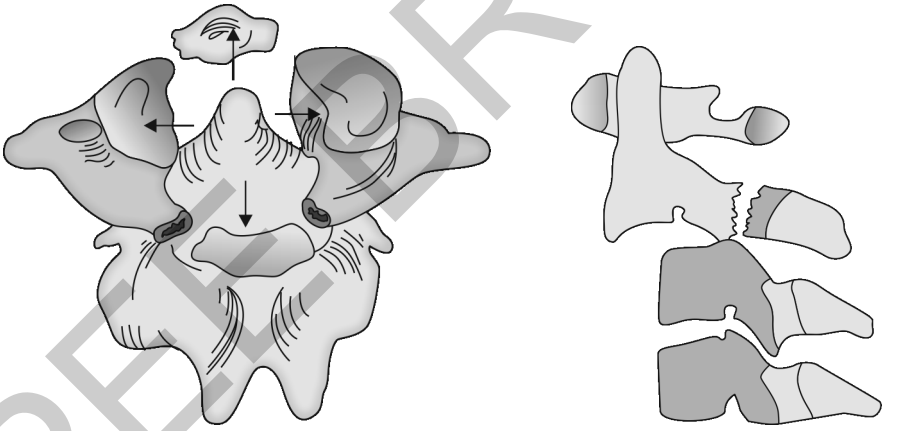

Figs 4 (A and B): A. Jefferson Fracture; B. Hangman's Fracture

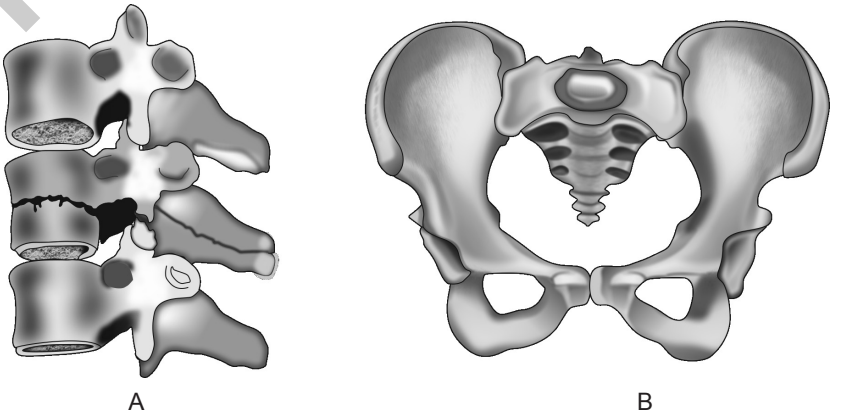

JAYPEE BROTHERS

Figs 5 (A and B): A. Chance Fractures B. Crescent fracture

- **Jumper's Fracture:** Dissociation between central and lateral portions of sacrum usually occurs with suicidal jumping on to the floor.
- ***Sentinel fracture*:** fracture through the lamina on either side of the spinous process.
- ***Monteggia fracture*:** fracture of the proximal ulna accompanied by radial head dislocation.
- ***Nightstick fractures*:** result from direct trauma to the ulna along its subcutaneous border, usually by lathi charge.
- ***Galeazzi or Piedmont fracture:*** fracture of the radial diaphysis at the junction of the middle and distal thirds with associated disruption of the distal radioulnar joint.
- ***Reverse Galeazzi fracture*:** denotes a fracture of the distal ulna with associated disruption of the distal radioulnar joint.
- ***Essex-Lopresti lesion*:** disruption of interosseous membrane of forearm bones.
- ***Laugier's Fracture:*** fracture of Trochlea distal humerus.
- **Colles fracture:** The original description was for extraarticular fractures. Present usage includes both extraarticular and intraarticular distal radius fractures. Dorsal angulation (apex volar), dorsal displacement produce the classical ***dinner fork deformity***.

Treated with cast immobilization in ***cotton-loader position***.

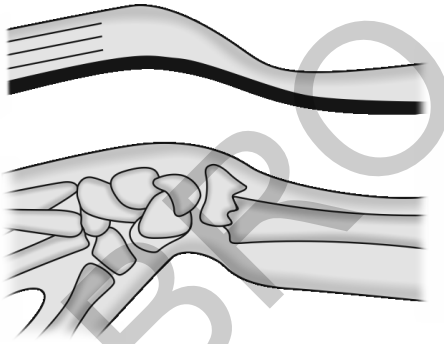

Fig. 6: Colles fracture with dinner-fork deformity

- **Smith fracture *(reverse Colles fracture)*:** fracture of distal radius with volar angulation (apex dorsal)–***garden spade deformity.***
- ***Barton fracture***: intra-articular fracture of distal radius. May be volar/dorsal. Most fractures are unstable and ***require ORIF*** with a buttress plate.
- ***Hutchinson fracture:*** (***chauffeur's fracture***, backfire fracture): Radial styloid avulsion fracture.

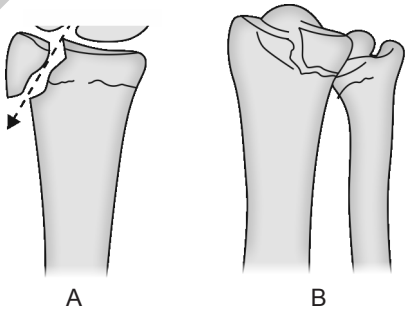

Figs 7 (A and B): A. Chauffeur's fx, B. Barton's fx

- **Gamekeeper's thumb** *or* ***skier's thumb***: Injury to the ulnar collateral ligament thumb MCP joint .
- ***Boxer's fracture:*** fracture at neck of fifth metacarpal bone.
- **Bennett fracture***:* intraarticular fracture of the base of first metacarpal- the shaft is laterally dislocated by the unopposed pull of ***Abductor Pollicis Longus***. Treated with closed reduction and percutaneous pins or ORIF.
- ***Rolando fracture:*** a Y-shaped fracture (a comminuted Bennett fracture) involving the base of the thumb metacarpal. Treated with closed reduction and percutaneous pins or ORIF.

JAYPEE BROTHERS

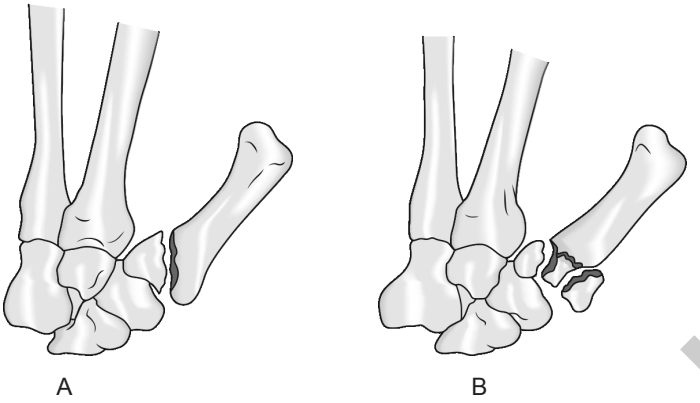

Figs 8 (A and B): A. Bennett's fx; B. Rolando's fx

- ***Hoffa's fracture:*** coronal plane fracture of the distal femur.
- ***Maisonneuve fracture*****:** an ankle injury with a fracture of the proximal third of the fibula.
- ***Curbstone fracture:*** an avulsion fracture of the posterior tibia is produced by a tripping mechanism.
- ***Pilon fracture*****:** intraarticular distal tibial fractures.

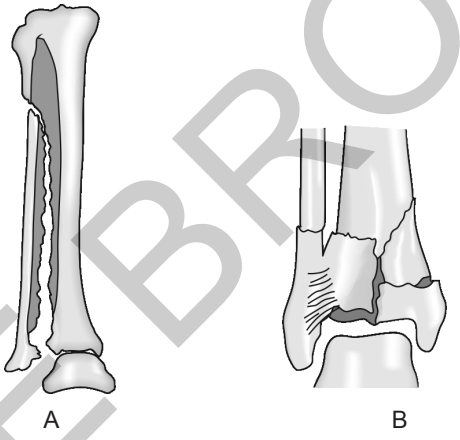

Figs 9 (A and B): A. Maisonneuve fracture; B. Pilon fracture

- ***Aviator's fracture:*** fracture through neck of talus.
- ***March fracture:*** a stress fracture of neck of second mrtatarsal bone.
- ***Pott's fracture:*** bimalleolar (medial and lateral malleoli) fracture.

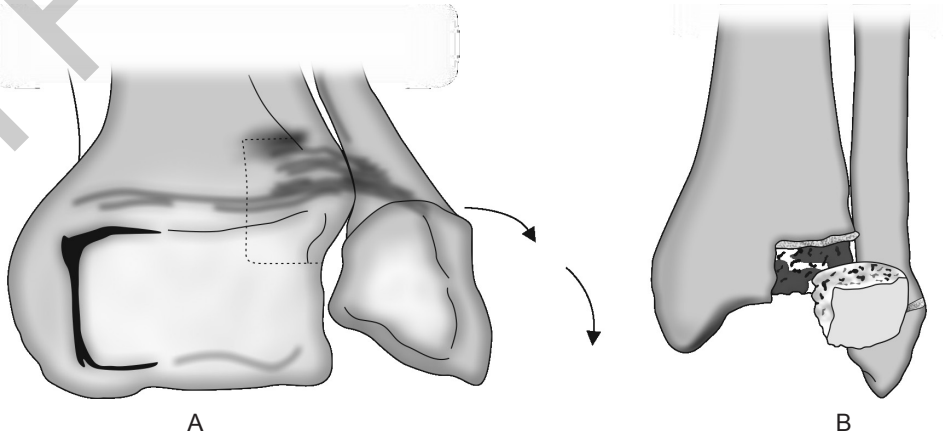

Figs 10 (A and B): Tillaux-Chaput fracture

JAYPEE BROTHERS

- ***Cotton's fracture****:* trimalleolar (medial, lateral and posterior) fracture of ankle.
- ***LeForte-Wagstaffe fracture***: anterior fibular tubercle avulsion fracture by the anterior tibiofibular ligament.
- ***Tillaux-Chaput fracture****:* avulsion of anterior tibial margin by the anterior tibiofibular ligament is the tibial counterpart of the LeForte-Wagstaffe fracture.

Toddler's Fracture: Oblique or Spiral Tibial Fracture with an Intact Fibula.

Jone's fractures: fracture of the base fifth metatarsal. Treated by short-leg cast.

Lisfranc injury: fractures/dislocation through tarsometatarsal joint.

*(**Chopart** joint is midtarsal joint).*

COMMON FRACTURE CLASSIFICATIONS

Fracture	Classification
Open Fractures	Gustilo and Anderson
Supracondylar Humerus	Gartland (based on displacement)
Proximal Humerus	Neer (4 part fractures)
Distal radius	Frykman, Fernandez
Pelvis	Young And Burgess, Tile.
Femoral Neck (pediatric)	Delbet Classification
Femoral Neck (adult)	Pauwel (based on fracture angle), Garden(based on displacement)
Intertrochanteric	Boyd and Griffin, Evans
Femoral Shaft	Winquist and Hansen (based on degree of communition)
Tibial Plateau	Schatzker
Pilon Fracture	Ruedi-Allgower
Ankle	Lauge-Hansen, Danis-Weber
Talar Neck	Hawkins
Calcaneum	Essex-Lopresti, Sanders (based on CT findings)
Physeal injuries	Salter-Harris Classification

DISCUSSIONS OF SOME SPECIFIC FRACTURES

Pelvic Fractures

Occurs with high energy trauma viz RTA, fall from height, industrial accidents.

Open book fracture: Anteroposterior compression force produces diastasis of the pubic symphysis.

Crescent fracture: lateral compression force causes ***iliac wing fracture*** on the side of impact.

Bucket-handle fracture: severe lateral compression force produces bilateral rotational instability .

Death is due to ***hypovolemic shock*** caused by disruption of the venous plexus in the posterior pelvis. It may also be caused by a large-vessel injury, such as external or internal iliac disruption producing marked hemodynamic instability.

Options for immediate hemorrhage control include:

- Military antishock trousers (MAST),
- Pneumatic antishock garment (PASG)
- Anterior external fixator,
- Wrapping of a pelvic binder
- Pelvic C-clamp.

JAYPEE BROTHERS

for detailed information on PGMEE books, visit our website www.jaypeebrothers.com, for detailed information on PGMEE books, visit our website www.jayp

KONCPT 20 Authors

for Tamil Nadu PG Entrance Examination

Salient Features

- The most important speciality of this book is that the subjects are written or reviewed by 20 different subject specialists. Hence, the points and contents in this book are 100 percent authentic.
- The pattern of the book is in this way that we have given the important theoretical aspects of each subject in a chapterwise manner at the beginning followed by the questions and explanations. This makes the readers to read in a systematic way and brings confidence to the PG aspirants.
- Mnemonics, tables, pictures and flow charts are added at appropriate places to stress the important topics.
- The facebook group- "KONCPT 20 Authors" brings all the readers and faculties under one forum so that all your doubts can be clarified.
- The book contains authenticated repeat questions from 2001 to 2015 in a subjectwise and chapterwise manner.
- The division of the book in two volumes makes the authors to carry and read in an easy way.

Available at all medical bookstores
or buy online at www.jaypeebrothers.com



JAYPEE BROTHERS
Medical Publishers (P) Ltd.
www.jaypeebrothers.com

Join us on facebook.com/JaypeeMedicalPublishers

ISBN 978-93-5152-926-2