t our website **www.jaypeebrothers.com,** for detailed information on otolaryngology books, visit our website **www.jaypeebrothers.co**

Includes Interactive
DVD-ROM

Minimal Access Skull Base Surgery

Open and Endoscopic Assisted Approaches

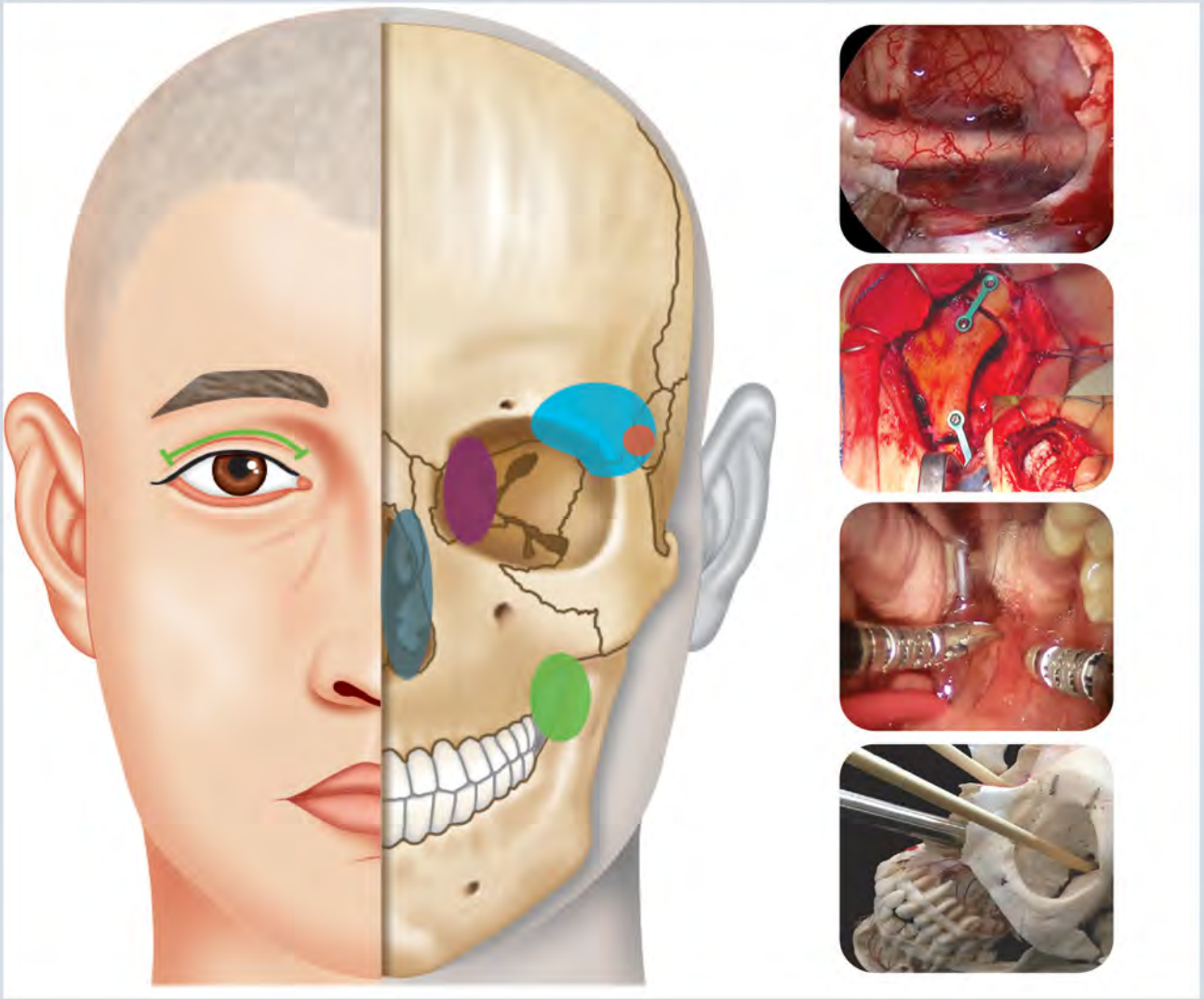

Kofi Boahene
Alfredo Quiñones-Hinojosa

JAYPEE

Contents

Section 1: General

1. **The 'Dilemma' of Modern Skull Base Surgery: Selecting the Correct Approach** **3**
   Nasser K Yaghi, Shaan M Raza
   - Historical Perspective *3*
   - Evolution of Modern Skull Base Techniques *3*
   - Understanding the Goals of Surgery *4*
   - Understanding the Extent of Skull Base Involvement *5*
   - QOL Expectations *5*
2. **Imaging of the Skull Base** **8**
   Mehmet E Adin, Ari M Blitz, Nafi Aygün
   - Imaging Techniques *8*
   - Anterior Skull Base *11*
   - Central Skull Base *18*
3. **Surgical Pathology of the Skull Base** **27**
   William Robert Bell, Fausto J Rodriguez
   - Specific Entities *27*
4. **Anesthetic Requirements and Pearls for Skull Base Surgery** **43**
   Jaymarc Iloreta, James Evans, Marc Rosen
   - Basic Pharmacology and Pharmacokinetics *43*

Section 2: Transorbital and Supraorbital Approaches

5. **Surgical Anatomy of the Orbit for Transorbital Approaches to Anterior Skull Base Lesions** **55**
   Jordina Rincon-Torroella, Ahmed Abd Elazim, Alfredo Quiñones-Hinojosa, Prem Subramanian
   - Review of the Orbital Anatomy and Surgical Correlation *56*
   - Patient Selection *58*
   - Indications for the Transorbital Approach *58*
   - Technical Aspects *58*
   - Postoperative Management *58*
   - Illustrative Case *59*
6. **Transorbital Approaches: Minimally Invasive Access to the Anterior Skull Base** **62**
   Holger G Gassner, Franziska Schwan, Karl-Michael Schebesch
   - Anatomy *62*
   - Technique *63*
   - Principles of Therapeutic Management *65*
   - Indications *66*
   - Clinical Studies/Literature Review *69*
   - Discussion *71*
7. **Transpalpebral Orbitofrontal Approaches to Intracranial Lesions** **73**
   Arnau Benet, Jordina Rincon-Torroella, Monirah Albathi, Prem Subramanian, Kofi Boahene, Alfredo Quiñones-Hinojosa
   - Indications *73*

- Preoperative Evaluation *74*
- Operative Technique *74*
- Postoperative Care *77*
- Illustrative Case *78*

8. Supraorbital Craniotomy Keyhole Technique **79**
Varun Puvanesarajah, Eric W Sankey, Sheng-fu Larry Lo, Jason A Liauw, Michael Lim
- Indications *79*
- Preoperative Evaluation *80*
- Technical Notes *80*
- Postoperative Management *83*
- Illustrative Case *83*

9. Endoscopic Decompression of the Orbital Apex **85**
Josef Shargorodsky, Andrew Lane
- Indications *85*
- Preoperative Evaluation *86*
- Technical Notes *86*
- Postoperative Management *87*
- Illustrative Case *87*

Section 3: Transnasal Approaches

10. Surgical Anatomy for Endoscopic Endonasal Skull Base Surgery **91**
Arnau Benet, Kofi Boahene
- EEA Modules to the Ventral Skull Base *97*

11. Transnasal Endoscopic Assisted Transcribriform Approach to Skull Base Lesions **98**
Thomas Kühnel
- Indications *98*
- Preoperative Evaluation *100*
- Technical Notes *100*
- Case Illustration *102*
- Management of Complications *103*
- Postoperative Management *104*
- Illustrative Cases *104*

12. Endoscopic Endonasal Transsphenoidal and Transplanum Approach **105**
Timothy R DeKlotz, Eric W Wang, Carl H Snyderman, Juan C Fernandez-Miranda, Paul A Gardner
- Indications *105*
- Preoperative Evaluation *105*
- Technical Notes *106*
- Postoperative Management *110*
- Illustrative Case *111*

13. Endoscopic Endonasal Transpterygoid Approaches **113**
Ali Jamshidi, Edward Kerr, Daniel M Prevedello, Bradley A Otto, Leo Ditzel Filho, Ricardo L Carrau
- Indications *113*
- Preoperative Evaluation *114*
- Surgical Technique *115*
- Postoperative Management *119*
- Illustrative Cases *120*

14. Transnasal Endoscopic Assisted Approach to the Mid-Cranial Base and Infratemporal Fossa **124**
Carl H Snyderman, Paul A Gardner, Eric W Wang , Juan C Fernandez-Miranda
- Indications *125*
- Preoperative Evaluation *126*
- Technical Notes *126*
- Postoperative Management *129*
- Illustrative Case *129*

15. Endoscopic Approaches to Lesions in the Cavernous Sinus **131**
Shaan M Raza, Theodore H Schwartz
- Anatomic Considerations *131*
- Considerations for Approach Selection *132*
- Endoscopic Transsphenoidal Approach to the Cavernous Sinus *132*
- Endoscopic Transpterygoidal Approach *133*
- Reconstruction *134*
- Vascular Considerations *135*
- Illustrative Cases *135*

16. Endoscopic Management of Petrous Apex Lesions **138**
Sergei Terterov, Jasvinder Nangiana, Garni Barkhoudarian, Isaac Yang
- Indications *138*
- Preoperative Evaluation *139*
- Technical Notes *139*
- Postoperative Management *140*

17. Transnasal Endoscopic Assisted Approach to the Clivus and Craniocervical Junction **143**
Eric W Wang, Paul A Gardner, Juan C Fernandez-Miranda, Carl H Snyderman
- Indications *144*
- Preoperative Evaluation *145*
- Technical Notes *145*
- Postoperative Management *150*
- Illustrative Case *150*

Section 4: Transoral Approaches

18. Endoscopic Assisted Transoral Approach to the Parapharyngeal Space **155**
Iacopo Dallan, Mario Turri-Zanoni, Paolo Battaglia, Veronica Seccia, Augusto Pietro Casani, Stefano Sellari-Franceschini
- Indication and Preoperative Evaluation *155*
- Technical Notes *156*
- Drawbacks and Possible Limitations *157*
- Review of Literature *158*
- Illustrative Case *160*

19. Endoscopic Assisted Paramandibular Approach to Infratemporal Fossa and Parapharyngeal Spaces **163**
Monirah Albathi, Kofi Boahene
- Indications *163*
- Preoperative Evaluation and Consideration *163*
- Technical Notes *165*
- Postoperative Management *169*
- Illustrative Case *169*

20. Evolution of Transoral Robotic-Assisted Approaches to the Skull Base 172
Jeremy D Richmon
- Evolution from Open to Robotic Techniques *172*
- Approaches to the Skull Base *173*
- Challenges and Future Directions *178*
- Illustrative Case *179*

Section 5: Management of Selected Skull Base Lesions

21. Endoscopic Transsphenoidal Approach to Pituitary Lesions 185
Peter Valentin Tomazic, Hannes Braun
- Special Anatomy of the Sphenoid Sinus and Sella *185*
- Indications *186*
- Preoperative Evaluation *186*
- Technical Notes *186*
- Postoperative Management *189*
- Illustrative Case *189*

22. Endoscopic Assisted Miniorbitofrontal Craniotomy in the Management of Frontal Sinus Inverting Papilloma 192
Gabriel F Santiago, Kofi Boahene, Murugappan Ramanathan Jr
- Patient Presentation and Clinical Evaluation *192*
- Surgical Management *193*
- Postoperative Management *194*
- Illustrative Case *194*

23. Transpalpebral Orbitocranial Approach to Olfactory Groove Meningiomas 197
Arnau Benet, Jordina Rincon-Torroella, Kofi Boahene, Monirah Albathi, Alfredo Quiñones-Hinojosa
- Indications *197*
- Preoperative Evaluation *198*
- Technical Notes *198*
- Postoperative Management *199*
- Illustrative Case *199*

24. Transpalpebral Orbitocranial Approach to Sellar and Suprasellar Pituitary Adenoma 203
Jordina Rincon-Torroella, Arnau Benet, Monirah Albathi, Prem Subramanian, Kofi Boahene, Alfredo Quiñones-Hinojosa
- Indications *203*
- Preoperative Evaluation *204*
- Technical Notes *204*
- Postoperative Management *205*
- Case Illustration *205*

25. Endoscopic Assisted Resection of Juvenile Nasal Angiofibroma 209
Marc Rosen, Jaymarc Iloreta, Alexander A Farag, James Evans
- Preoperative Evaluation *211*
- Treatment *214*
- Surgical Approaches *214*
- Postoperative Management/Complications *220*
- Morbidity *221*

26. Transnasal Endoscopic Assisted Management of Cerebrospinal Fluid Leak and Meningocele **223**
James Evans, Marc Otten, Mindy R Rabinowitz, Marc Rosen
- Preoperative Evaluation *225*
- Indications for Surgical Repair *228*
- Technical Notes *230*
- Postoperative Management *234*

27. Transorbital Endoscopic Assisted Management of Cerebrospinal Fluid Leak **237**
Ignacio Jusué-Torres, Kaisorn L Chaichana, Kofi Boahene, Alfredo Quiñones-Hinojosa
- Indications *238*
- Preoperative Evaluation *238*
- Technical Notes *238*
- Tips to Prevent Approach-Related Complications *239*
- Postoperative Management *240*
- Illustrative Case *240*

28. Endoscopic Management of Clival Chordoma **243**
Jasvinder Nangiana, Sergei Terterov, Garni Barkhoudarian, Isaac Yang
- Preoperative Evaluation *243*
- Technical Notes *243*
- Postoperative Evaluation *248*
- Clinical Studies *248*

29. Minicraniotomy Management of Superior Canal Dehiscence **250**
Matthew Miller, John Carey
- Presentation and Clinical Evaluation *250*
- Surgical Management *251*
- Surgical Technique *252*
- Postoperative Management *257*
- Outcomes *257*
- Illustrative Case *258*

Section 6: Skull Base Reconstruction and Postoperative Management

30. Skull Base Reconstruction **263**
Thomas S Lee, Andrew Johnson, Lenka Stankova, Yadranko Ducic
- Preoperative Evaluation and Indications *263*
- Treatment Algorithm *264*
- Endoscopic Skull Base Reconstruction *265*
- Microvascular Flap Reconstruction for Complex Skull Base Defects *279*
- Illustrative Case *286*

31. Management of Complications Associated with Endoscopic Assisted Skull Base Surgery **289**
Ignacio Jusué-Torres, Kaisorn L Chaichana, Kofi Boahene, Alfredo Quiñones-Hinojosa
- History and Advances in Endoscopic Approaches *289*
- Intracranial Complications *290*
- Endocrinologic Complications *292*
- Intranasal Complications *293*
- Intraorbital Complications *294*

Index *299*

Surgical Pathology of the Skull Base

3

William Robert Bell, Fausto J Rodriguez

JAYPEE BROTHERS

INTRODUCTION

Diagnostic pathology of lesions affecting the skull base is challenging, since almost the whole spectrum of inflammatory disorders and neoplasms encountered in surgical pathology may present for evaluation.[1] The anatomy of this region is complex, and lesions may originate from the meninges, bone, soft tissue, or peripheral nerve. Additionally, hematolymphoid disorders, neoplasms originating in the head and neck with intracranial extension (e.g. olfactory neuroblastoma, squamous cell carcinoma, salivary gland tumors), and metastases originating anywhere in the body may be encountered.

Because, surgeries performed in this region fall within the territory of neurosurgery and otorhinolaryngology, neuropathologists and head and neck pathologists are most often involved in the evaluation of these specimens. Given the versatility of the histologies that may be encountered in skull base biopsies and resections, subspecialty consultation with hematopathology or bone and soft tissue pathology are key components in the evaluation of these specimens. In the current chapter, we will be discussing the diagnostic pathologic features of some of the most common disorders that are encountered in the surgical pathology of the skull base.

SPECIFIC ENTITIES

Nonneoplastic

Inflammatory Disorders

A variety of inflammatory disorders may affect the skull base and meninges and present in the form of destructive and/or mass lesions (Figs. 3.1A to F). Granulomatous disease has a predilection for the skull base and may be infectious in origin [mycobacterial (Figs. 3.1A and B) and fungal (Fig. 3.1C)]. The presence of necrosis suggests an infectious process. Well formed granulomas are typical of sarcoidosis, which may cause diffuse superficial leptomeningeal disease with perivascular space extension, or masses mimicking meningioma.[2] Wegener's granulomatosis typically affects the respiratory tract and sinuses, but may extend intracranially to involve the meninges (Fig. 3.1D). The classic histology is the presence of large areas of necrotizing granulomatous disease and associated vasculitis.

IgG4-related meningeal disease has been recently identified as part of the spectrum of inflammatory disorders characterized by an increase in IgG4-positive plasma cells (Figs. 3.1E and F). Intracranially, the dura is a typical site of involvement in the form of a pachymeningitis.[3] Leptomeningeal and sellar involvement has also been described. Histologically, this disorder is characterized by lymphoplasmacytic inflammation, fibrosis, and phlebitis. The presence of 10 or more IgG4-positive cells by immunohistochemistry per high power field has been proposed as provisional diagnostic criteria.[3]

Noninflammatory Lesions

A variety of nonneoplastic cysts may affect the intracranial compartments, including the skull base, such as dermoid and epidermoid cysts. Mucocele, an expansion of a sinus and histologically lined by respiratory epithelium, may extend intracranially. *Calcifying pseudoneoplasm of the neuraxis* is a unique lesion that may arise anywhere in the neural axis, but frequently involves bone (Fig. 3.2A).[4]

Bone Tumors and Tumor-Like Lesions

Fibrous Dysplasia

Fibrous dysplasia is a benign fibro-osseous lesion most commonly occurring in the craniofacial skull. Clinical presentation may be monostotic or polyostotic.[5] More severe bone deformity is associated with the polyostotic type. Fibrous dysplasia is well-defined without invasion of adjacent soft tissue or bone and should be considered

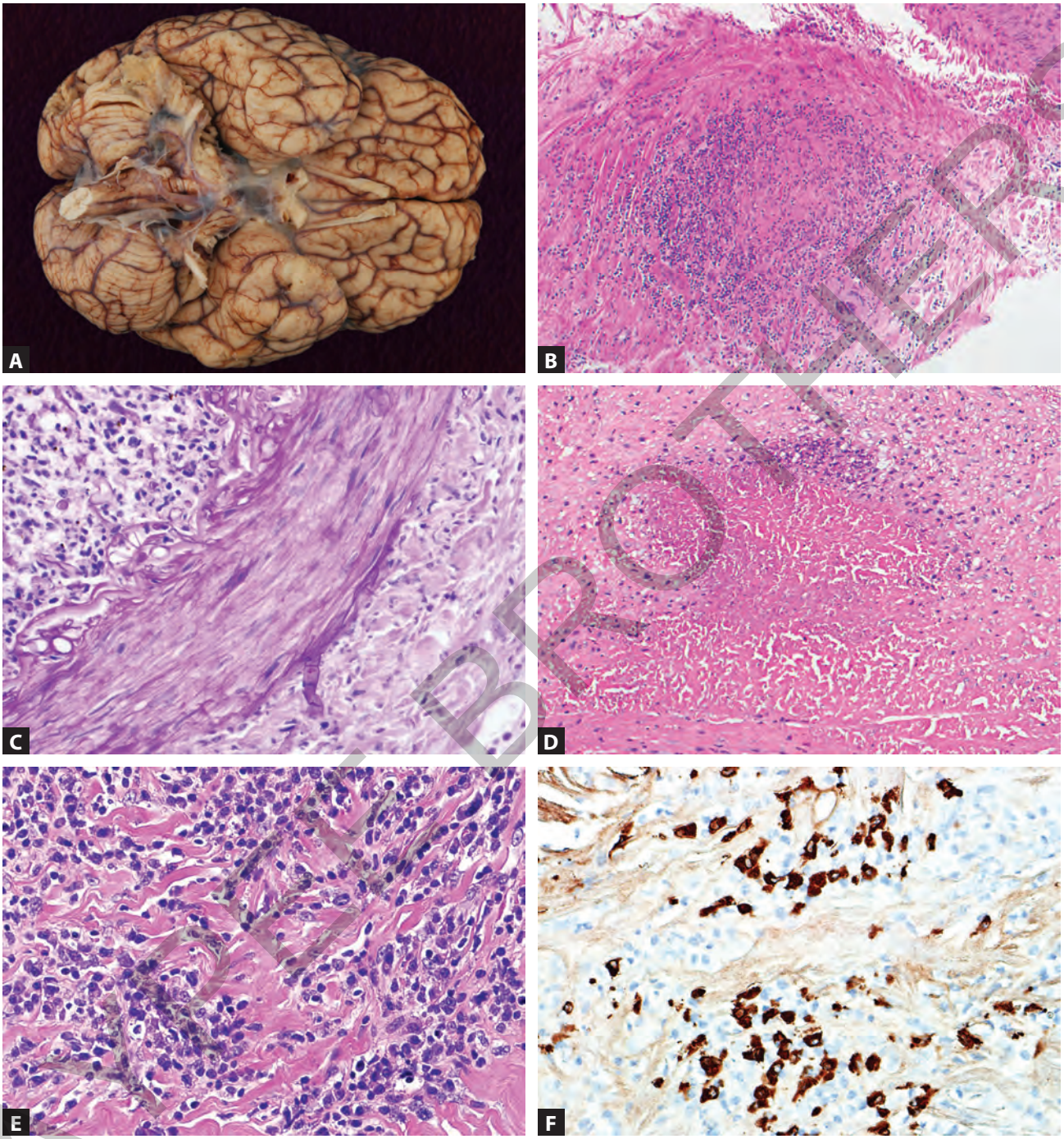

Figs. 3.1A to F: Inflammatory disorders. Many granulomatous disorders have a predilection for the basal leptomeninges, including tuberculosis (A). Microscopically, leptomeningeal thickening by fibrosis and granulomas is present (B). Invasive fungal infections may also affect the skull base. Mucormycosis in particular is characterized by prominent angioinvasion (PAS, Periodic acid schiff) (C). Other noninfectious inflammatory disorders that may affect the skull base include Wegener's granulomatosis (D) and the plasma cell-rich IgG4-related disease (E). The latter is characterized by an increase in the number of IgG4-positive plasma cells by immunohistohemistry (F).

clinically based on the radiographic growth pattern.[6] The histopathologic features consist of irregular spicules of woven bone in a background of dense fibrous stroma classically described as "Chinese Letters" (Fig. 3.2B). The bone spicules are characterized by an absence of phenotypic osteoblasts synthesizing bone. There can be

JAYPEE BROTHERS

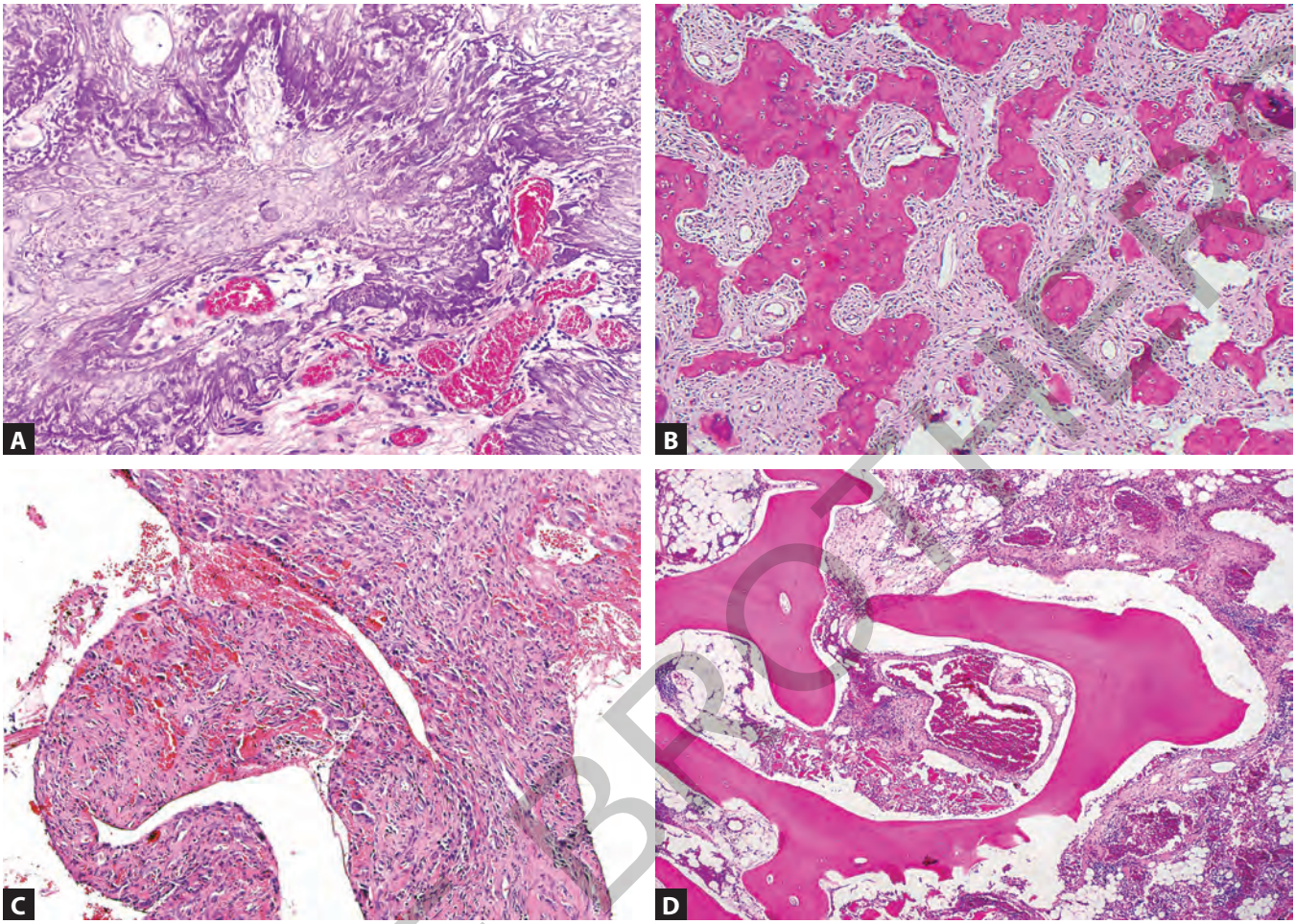

Figs. 3.2A to D: Nonneoplastic bone lesions. Calcifying pseudoneoplasm may involve bone, soft tissue, or even central nervous system parenchyma in the neural axis. The histology is distinctive, particularly aggregates of basophilic material surrounded by spindle cells (A). Other nonneoplastic lesions that may involve the craniofacial bones include fibrous dysplasia (B), giant cell reparative granuloma (C), and hemangioma (D).

a varying degree of woven bone production, ranging from minimal, where a cellular spindle cell proliferation predominates, to numerous islands of woven bone occurring in sizable fragments. Recent developments in molecular genetics have implicated a somatic mutation present in early embryogenesis causing genetic mosaicism. The gene encodes for the stimulatory G protein alpha-subunit which leads to modulation of WNT/beta catenin signaling.[5,7,8]

Other Benign Bone Lesions/Neoplasms

Osteoblastoma is a benign bone-forming neoplasm. Histologically, it is characterized by interlacing seams of osteoid with varying mineralization in a background of loose fibrovascular stroma. Numerous prominent epithelioid osteoblasts are seen in the fibrovascular stroma. Giant-cell reparative granuloma is a well-defined lytic process consisting of multinucleated osteoclast-like giant cells admixed with fibrous tissue and reactive bone in a regional pattern (Fig. 3.2C). Hemangiomas also may involve the cranial bones (Fig. 3.2D).

Osteosarcoma

Osteosarcoma, also called osteogenic sarcoma, is a high-grade neoplasm of bone where tumor cells produce osteoid to varying degrees. Within the cranium, primary osteosarcomas usually have soft tissue involvement with intraparenchymal or extracranial extension. Histologically, anaplasia, atypical mitoses, and necrosis are common. Epithelioid or spindle cell morphology is typical and by definition at least focal. Unmineralized bone or bone

JAYPEE BROTHERS

production by tumor cells is seen, so called osteoid. A chondrosarcomatous matrix or a focal angiocentric pattern may also be seen. A subset of tumors develop after radiation therapy for intracranial neoplasms.

Ewing Sarcoma

Ewing sarcoma is an infrequent small round cell bone tumor (Fig. 3.3C). In the central nervous system (CNS), the neoplasm is primarily a dural based, or may extend from bone or associated soft tissue. Frequently, these lesions mimic meningioma radiographically in either the spine or within the cranium. Pathologic features are identical to those seen in bone and soft tissue, with sheets of primitive appearing, small, round cells with clear, periodic acid-Schiff-positive cytoplasm. The typical immunophenotype is synaptophysin and neuron specific enolase (NSE) positive, at least focally, with diffuse strong membranous staining for CD99, although this is not completely specific. Diagnosis should therefore be confirmed with demonstration of translocation (11;22) (q24;q12), EWS-FLI1, EWS-ERG, or other EWS rearrangements by molecular methods.

Chordoma

Chordoma while being a slow-growing neoplasm, demonstrates local invasion, bone destruction, and frequent recurrence. This neoplasm is believed to originate from embryonic notochordal remnants, located at the ventral surface of the neural tube. It may affect the skull base, flexible spine, or sacrum.[9,10] Within the cranium, the clivus is the most commonly involved structure and most of these tumors are situated in the midline. Rarely, they may present as a sellar neoplasm.[11] Histopathologic features of chordomas were first characterized by Virchow, when he described the typical cells with bubble-like vacuoles he referred to as "physaliphorous" cells, resembling lipoblasts (Fig. 3.3D). Conventional chordoma is composed of anastomosing cords and clusters of epithelioid cells in a myxoid matrix separated into lobules by stromal septae admixed with scattered vacuolated physaliphorous cells (Fig. 3.3E). The variant chondroid chordoma displays a predominance of cartilaginous differentiation, and is sometimes difficult to distinguish from chondrosarcoma. Another morphologic variation is dedifferentiated chordoma, which demonstrates a biphasic architecture composed of typical chordoma elements and a pleomorphic sarcomatous component, often occurring after radiation therapy.

Additional insights into the biology of chordomas developed with the discovery of genetic alterations in transcription factor T gene (brachyury) in familial chordomas. The protein expression of brachyury in chordomas was later established to discriminate these tumors from other neoplasms (Fig. 3.3F).[12,13] Other immunohistochemical studies demonstrate an epithelial phenotype with reactivity for cytokeratins and epithelial membrane antigen (EMA), as well as S100 reactivity in physaliphorous cells. Dedifferentiated chordomas show minimal reactivity for epithelial markers. Poorly differentiated chordomas typically present in the pediatric population, and may be associated with SMARCB1/INI1 tumor suppressor loss.[14]

Chondrosarcoma

Intracranial chondrosarcoma is a rare malignant neoplasm that arises in the synchondroses of the basal calvarium or the dura (Fig. 3.3A). Common intracranial locations include the parasellar region, the cerebellopontine, and petrous aspect of the temporal bone region, and less commonly the meninges of the falx cerebri, tentorium, and cerebral convexity. A history of prior radiation therapy (i.e. secondary chondrosarcoma) may be present. Histologically, conventional chondrosarcoma is characterized by well-differentiated cartilage matrix containing atypical chondrocytes with variable size and shape, hyperchromatic nuclei, and occasional binucleate forms. Most of these lesions are low grade with low proliferative activity and low cellularity, without evidence of necrosis or myxoid change (Fig. 3.3B). Less frequently, high-grade features are seen with a marked increase in cellularity, scant cartilaginous matrix, and brisk mitotic activity. *Mesenchymal chondrosarcoma* is a rare subtype that may present in the craniofacial bones or the vertebrae, and less commonly in the intracranial meninges. These neoplasms display primitive small cells with islands of hyaline cartilage, and are high grade by definition with a propensity for local recurrence or distant metastasis. Among intracranial chondrosarcomas arising in the parafalx region, the majority reported are mesenchymal chondrosarcomas.[15] More recently, a recurrent *HEY1-NCOA2* fusion has been identified as a molecular feature of this unique chondrosarcoma subtype.[16]

Meningioma

Meningiomas are the most common extra-axial tumors of the CNS (Figs. 3.4A to F). While the vast majority (~80%)[17] of these tumors are slow growing WHO grade I tumors, a subset may be atypical (WHO grade II) or anaplastic (WHO grade III), and display significantly more aggressive clinical behavior. While most meningiomas are recognized

JAYPEE BROTHERS

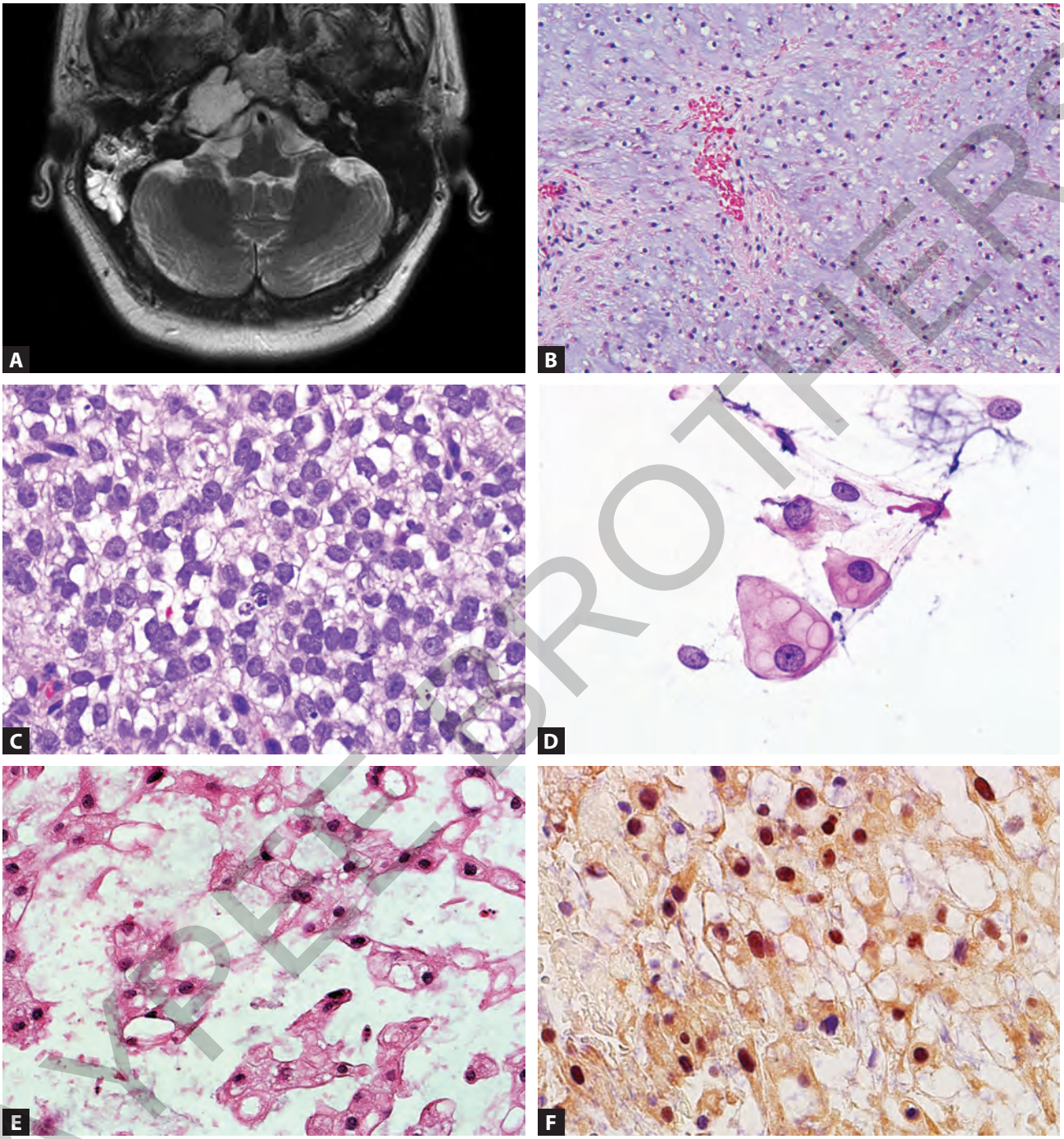

Figs. 3.3A to F: Bone neoplasms. Chondrosarcomas when involving the skull base present as eccentric (rather than midline) neoplasms (A) and are typically low grade (B). Ewing sarcoma is a cellular neoplasm composed of round cells with little variation and clear cytoplasm (C). Most characteristic features of chordoma are evident on smear preparations: physaliphorous/vacuolated epithelioid cells (D). Architectural features include cord-like arrangements in myxoid stroma (E). Detection of nuclear brachyury by immunohistochemistry is an additional diagnostically useful feature (F).

and diagnosed on hematoxylin and eosin (H&E) staining, immunohistochemistry may be useful when considering a differential diagnosis. The majority of meningiomas demonstrate staining for EMA. Progesterone receptor immunoreactivity is common in meningiomas that are lower grade and less so in higher grade lesions. Staining

JAYPEE BROTHERS

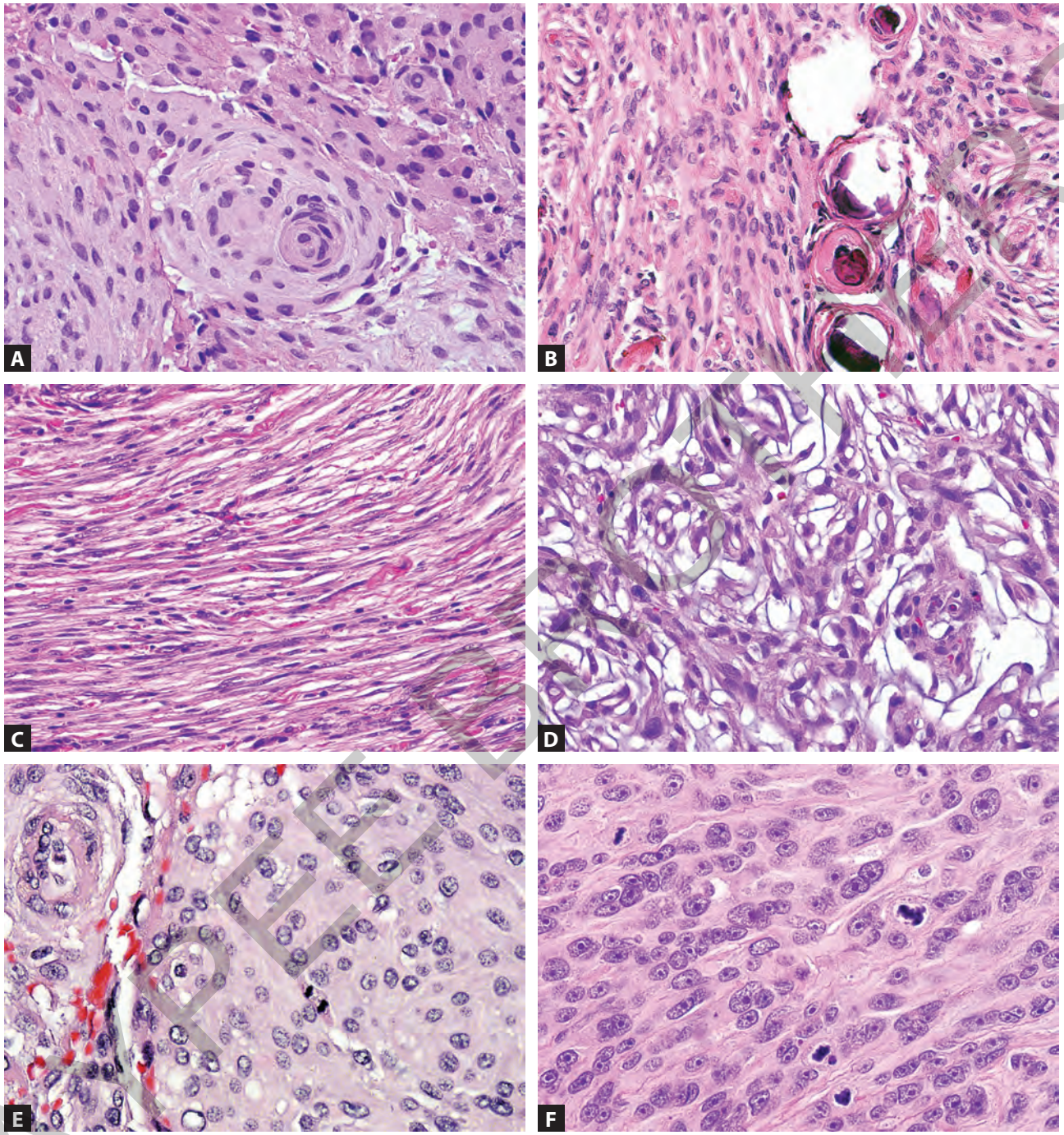

Figs. 3.4A to F: Meningiomas. Meningiomas are relatively frequent neoplasms that may arise in the skull base, characterized by the presence of whorls (A) and psammoma bodies (B) in the common meningothelial and transitional subtypes. Fibrous meningioma is characterized by spindle cells (C) and mimics mesenchymal neoplasms. Chordoid meningioma in particular engenders important differential diagnosis considerations when occurring in the skull base (D). Atypical meningioma is characterized by increased mitotic activity (E), while anaplastic meningioma has an even brisker mitotic rate, >20 mitoses per 10 high power fields (F).

may show strong immunoreactivity in a heterogeneous, patchy distribution. Our understanding of the vast histopathologic spectrum of these neoplasms, combined with the recognized molecular alterations in tumorogenesis and malignant progression, has led to an evolving grading and classification system in the past several decades.

JAYPEE BROTHERS

The morphologic variation of meningiomas is remarkable. Meningothelial meningiomas display a lobulated architecture with nests and whorls of polygonal to epithelioid cells with ill-defined cell borders (Fig. 3.4A). Fibroblastic meningiomas exhibit intersecting fascicles of spindled, fibroblast-like cells with conspicuous collagen deposition (Fig. 3.4C). Commonly, linear calcifications are seen in the collagenous stroma. When there is a predominance of collagenous stroma and spindle cell morphology, the differential diagnosis includes other spindle cell neoplasms, such as schwannoma and solitary fibrous tumor/hemangiopericytoma (SFT/HPC). Immunohistochemical studies for EMA, S100, reticulin or collagen IV and CD34 can be extremely useful for ambiguous cases. Schwannoma and fibrous meningioma both commonly display S100 immunoreactivity, but schwannomas possess basal lamina for which histochemical reticulin staining or collagen IV immunostaining can readily be demonstrated. Transitional meningiomas demonstrate a mixture of meningothelial and fibroblastic architectural features. Psammomatous meningiomas, as the name implies, contain numerous psammoma bodies (Fig. 3.4B). Angiomatous meningiomas contain numerous, often hyalinized vessels, and may be associated with adjacent cerebral edema. This variant of meningioma is often seen in association with the microcystic subtype. Considerably less common WHO grade I histologic subtypes comprise the secretory, microcystic, lymphocyte-rich, and metaplastic. Secretory features demonstrate epithelial differentiation with glandular, luminal-like spaces containing eosinophillic pseudopsammomatous globules that are periodic acid-Schiff positive and carcinoembryonic antigen positive. Microcystic meningioma is characterized by a cob-web lattice, and microcystic architecture. Lymphocyte-rich meningiomas are for the most part obscured by dense infiltrates of lymphocytes and plasma cells. Metaplastic meningioma represents any type of meningioma with areas of mesenchymal "metaplasia" such as lipomatous, cartilaginous, osseous, xanthomatous, or myxoid.

Criteria for atypical meningioma (WHO grade II) diagnosis are outlined in the 2007 WHO grading classification.[18] Major criteria include mitotic index of 4 or more per 10 high power fields, or brain invasion with tongue-like protrusion of tumor into adjacent brain parenchyma (Fig. 3.4E). Atypical meningioma may also be diagnosed on the basis of the presence of at least three of five features including (1) sheet-like architecture, (2) small cell formation, where cytologic features show lymphoid-like cells with high nuclear:cytoplasmic ratios, (3) regions of high cellularity, (4) macronucleoli, or (5) areas of spontaneous necrosis, not iatrogenically induced. Additionally, specific histologic subtypes (clear cell and chordoid) of meningioma are defined as grade II. Clear cell meningioma shows sheets of polygonal cells with clear or vacuolated cytoplasm that demonstrate glycogen accumulation with diastase-digestible periodic acid-Schiff-positive staining. This subtype typically demonstrates prominent stromal hyalinization with minimal whorls or psammoma body formation. Chordoid meningioma displays copious basophilic stroma with epithelioid cells arranged in ribbons or cords (Fig. 3.4D) resembling chordoma, which raises the important differential diagnosis with chordoma proper and other chordoid neoplasms, particularly when involving the skull base.

Anaplastic meningioma has a greatly increased risk for recurrence and death. Histologic features include overt cellular anaplasia that may show sarcoma, carcinoma, or melanoma-like cytologic features or exuberant mitotic activity of 20 or greater mitoses per 10 high power fields (Fig. 3.4F). The papillary and rhabdoid meningioma variants are currently WHO grade III by definition. As with other meningioma subtypes, the diagnosis is given when this architectural pattern predominates (usually >50% of the tumor volume).

Regarding genetic features, the most frequent cytogenetic alteration in meningioma is monosomy 22 or partial deletion of 22q involving the *NF2* gene.[19] Mutation of the *NF2* gene is found in most sporadic meningiomas, particularly in transitional and fibroblastic meningioma subtypes.[20] Progression to higher grade atypical and anaplastic meningioma is associated with segmental loss of chromosome arms 1p, 6p, 10q, 14q, and 18q, among others. Of interest, recent high-resolution genomic analyses have demonstrated that meningiomas involving the skull base contain different genetic alterations depending on anatomic location, with NF2/Ch22 alterations being more frequent in lateral skull base and hemispheric examples.[21]

Nonmeningothelial Dural-Based Tumors

A variety of benign and malignant mesenchymal neoplasms may involve the dura and skull base. For practical purposes, the extra-axial/dural compartments may be considered soft tissues, and therefore when a neoplasm encountered in this location is not meningothelial, the differential diagnosis may be wide (Figs. 3.5A to F).

JAYPEE BROTHERS

Solitary Fibrous Tumor and Hemangiopericytoma

While once thought to be distinct entities, SFT/HPC are now considered a single category of fibroblastic/myofibroblastic tumors in the 2013 WHO classification of tumors of soft tissue and bone (Figs. 3.5A and B).[22] In the CNS, this tumor is usually a well-circumscribed, dural-based spindle cell neoplasm with a collagenous background and variable branching vascular network termed "staghorn vessels". Immunoreactivity for CD34 is variable, being strong and diffuse in tumors with classic solitary fibrous tumor histology, while sparse or altogether negative in some tumors in the HPC end of the spectrum. Interestingly, recent studies have demonstrated a specific *NAB2-STAT6* gene fusion in almost all of these tumors (SFT or HPC).[23,24] Additionally, STAT6 nuclear expression, as detected by immunohistochemical labeling, has been demonstrated to be highly sensitive and specific for SFT/HPC, and therefore may be useful to distinguish this tumor from various histologic mimics.[25]

Inflammatory Myofibroblastic Tumor

Inflammatory myofibroblastic tumor (IMT) is characterized by a neoplastic proliferation of spindled myofibroblasts admixed with an inflammatory infiltrate composed primarily of lymphocytes and plasma cells (Fig. 3.5C). In the past, the designation inflammatory pseudotumor or plasma cell granuloma has been used to describe a broad, generic terminology for mass lesions simulating a neoplastic process while largely considered to be reactive. These lesions are uncommon and predominantly occur in children and young adults in the soft tissue or viscera and may affect all organ systems, with the lung being the most frequent visceral site affected. Intracranial IMTs have been reported to be dural based (most frequent), intraparenchymal, intraventricular, or sellar.[26,27] Clonal cytogenetic abnormalities characterized by recurrent translocations and fusions involving the Anaplastic Lymphoma Kinase (*ALK*) gene at chromosome 2p23 and various partners (i.e. tropomyosin family genes TPM3 and TPM4) were described in IMT.[28] *ALK* gene rearrangements have been demonstrated in approximately half of IMTs, particularly in young patients, and frequently associated with increased ALK protein. Other immunohistochemical markers variably immunoreactive in IMT include vimentin, muscle-specific actin, smooth muscle actin, and less commonly desmin and cytokeratin.[29]

Melanocytic Neoplasms

A variety of primary melanocytic neoplasms may involve the dura, skull base, and spine (Fig. 3.5D). These range from melanocytic (WHO grade I) to intermediate grade melanocytic tumors, and overtly malignant melanoma.[30]

Sellar Lesions

Pituitary tumors represent a relatively frequent group affecting the skull base. Symptoms may herald the presence of a lesion due to the production of excess hormone or reach adequate size to produce compressive symptoms on the optic tract. Adenomas may be diffusely infiltrating extending into the dura mater or adjacent bone and into the cavernous sinus or into the mucosa of the nasal and paranasal sinuses. Rarely these lesions may invade the clivus or the brain parenchyma.

The morphologic and phenotypic spectrum of pituitary adenoma is wide (Figs. 3.6A, C and D), and diagnostic evaluation may require detailed immunohistochemistry studies and/or electron microscopy. With respect to clinical behavior, atypical adenomas have been defined as having increased proliferative activity with conspicuous mitotic activity, increased MIB-1 labeling index exceeding 3%, and significant p53 immunoreactivity. Pituitary carcinomas, while usually well-differentiated histologically, are defined as tumors of adenohypophyseal origin having undergone systemic or craniospinal metastasis or aggressive brain parenchymal invasion (Fig. 3.6B).

Craniopharyngioma

Craniopharyngiomas are typically suprasellar neoplasms with frequent cystic components. Adamantinomatous craniopharyngioma, the most frequent subtype, is characterized by lobules of epithelial cells in sheets and anastomosing trabeculae with peripheral palisading and loosely textured core termed "stellate reticulum" with nests of keratinizing squamous epithelium containing ghost cells. i.e. "wet keratin" (Fig. 3.6E). Papillary craniopharyngioma is a less common variant, composed of sheets of well-differentiated, nonkeratinizing squamous epithelium with papillary fibrovascular cores (Fig. 3.6F). Occasional collagen and epithelial whorls may mimic keratin pearls and stellate reticulum is absent. Recent whole-exome sequencing studies have further separated these two subtypes at the molecular level, with the adamantinomatous subtype containing frequent *CTNNB1* (β-catenin) mutations and the papillary subtype *BRAF* (V600E) mutations.[31]

JAYPEE BROTHERS

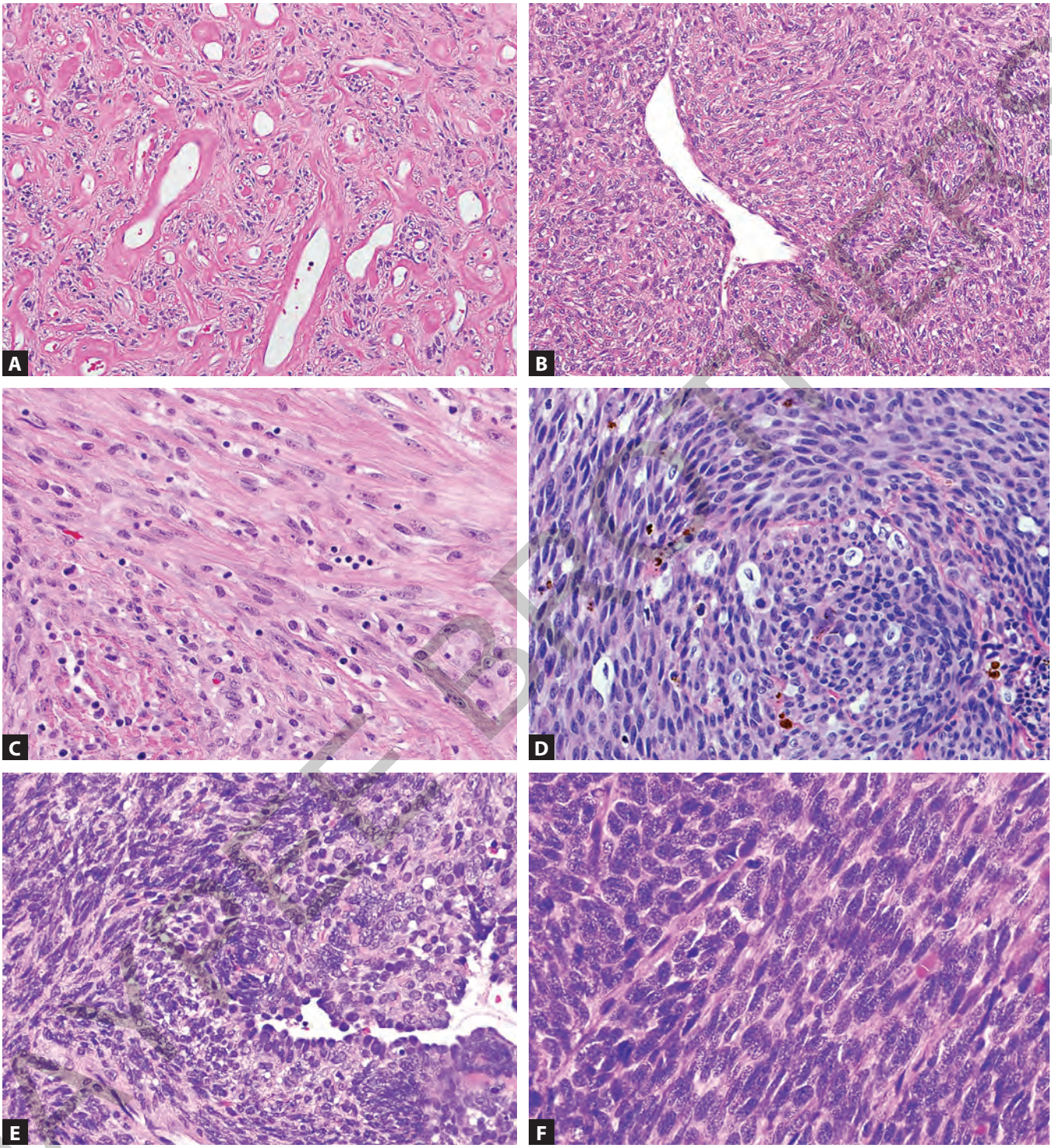

Figs. 3.5A to F: Nonmeningothelial dural-based neoplasms. Solitary fibrous tumor is a mesenchymal neoplasm that may present as a dural mass, characterized by rope-like collagen and microvascular hyalinization (A). Dural hemangiopericytoma is a cellular, malignant neoplasm containing gaping/staghorn vessels (B), originally misclassified as a meningioma variant, but more recently confirmed to lie in the spectrum of solitary fibrous tumor by morphologic and molecular studies. Other spindle cell neoplasms that may involve dura and skull base in primary or metastatic forms include inflammatory myofibroblastic tumor (C), melanocytoma (D), and a variety of sarcomas, including synovial sarcoma (E) and leiomyosarcoma (F).

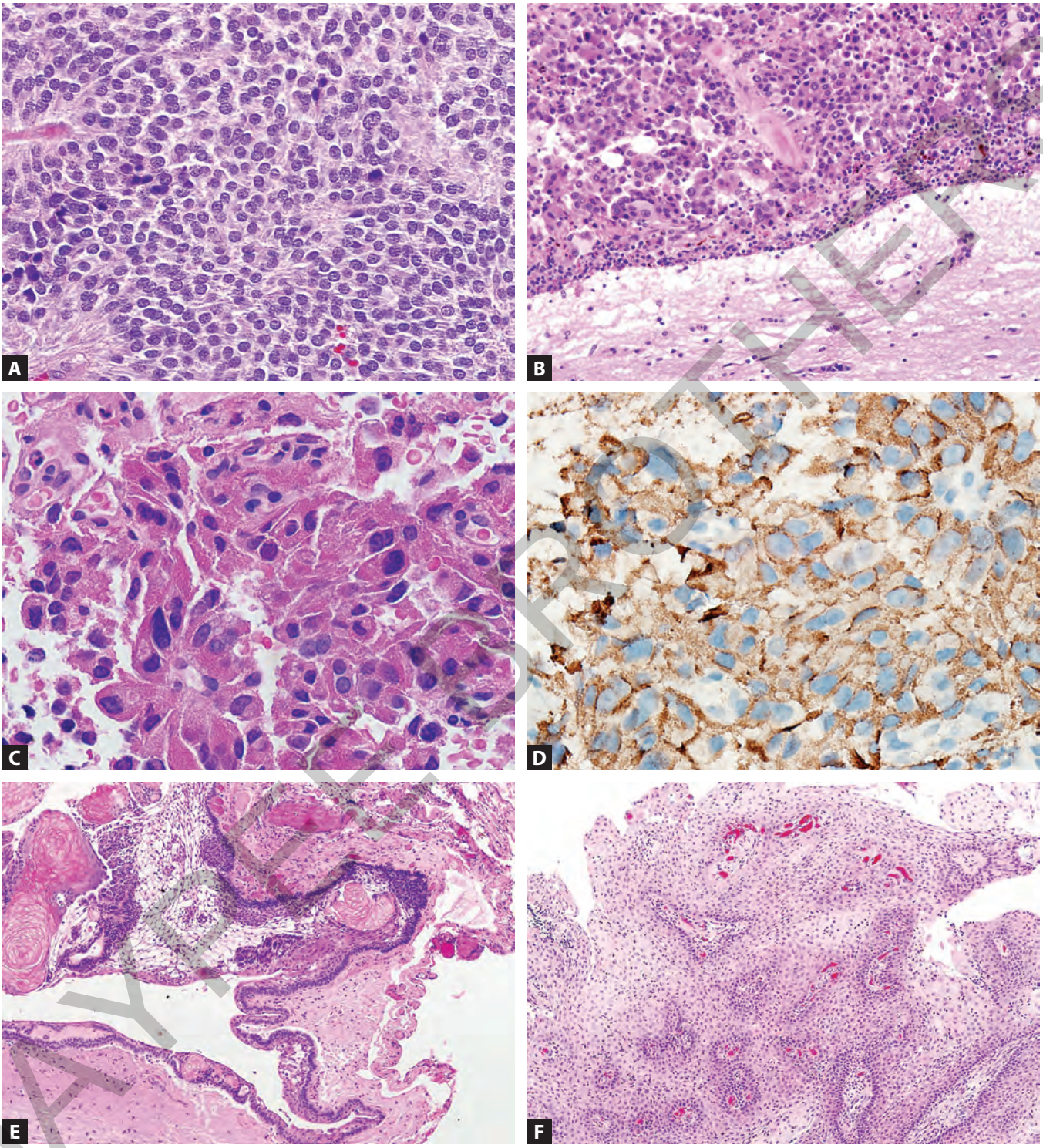

Figs. 3.6A to F: Sellar/suprasellar neoplasms. Pituitary adenomas have remarkable morphologic and functional diversity, but are frequently recognized microscopically by loss of a normal pituitary architecture and the presence of a single cell type (A). Pituitary carcinomas are relatively rare, but defined by the development of distant metastases or extensive leptomeningeal spread (B). Somatotroph adenomas associated with acromegaly are frequently composed of brightly eosinophilic cells (C) with variable immunoreactivity for growth hormone (D). Craniopharyngioma subtypes include adamantinomatous (E) and papillary (F).

JAYPEE BROTHERS

Hematopoietic Neoplasms

Plasmacytoma/Multiple Myeloma

Intracranial plasmacytoma may occur as first presentation or secondary spread of multiple myeloma, or as a solitary extramedullary plasmacytoma. Within the cranium, plasmacytoma may be localized to the leptomeninges, within the brain parenchyma, cerebral ventricles, or (most commonly) within the skull base. Histology shows neoplastic cells with eccentric nuclei, perinuclear huff, and clock-faced chromatin (Fig. 3.7A). Immunohistochemistry is positive for CD79a, CD138, and CD38. Kappa or lambda light chain restriction is confirmed most commonly by immunohistochemistry or in situ hybridization methods (Fig. 3.7B).

Lymphoma

Most lymphomas involving the CNS and surrounding tissues represent large B-cell lymphomas, primary or secondary (Figs. 3.7C and D). Intra- and extracranial extension and bone destruction of the skull bone is more commonly seen in cranial lymphomas. Among low grade lymphomas, marginal zone lymphoma may present as an extra-axial mass, classically mimicking meningioma.[32]

Histiocytoses

The histiocytoses represent a spectrum of reactive and neoplastic entities that may be localized/self-limited or present with progressive systemic symptoms. When involving the CNS, they affect the sellar region, skull base, and meninges. Specific subtypes include Rosai-Dorfman disease (Fig. 3.7E), juvenile xanthogranuloma, Langerhans cell histiocytosis, and Erdheim-Chester disease (Fig. 3.7F). Of therapeutic relevance, *BRAF* (V600E) mutations are present in approximately half of Langerhans cell histiocytosis and Erdheim-Chester cases.[33]

Head and Neck Tumors

Squamous Cell Carcinoma

Squamous carcinoma is the most common malignant epithelial-derived neoplasm of the sinonasal tract (Fig. 3.8A). Conventional squamous cell carcinoma includes keratinizing and nonkeratinizing subtypes, papillary squamous carcinoma, verrucous carcinoma, spindle cell squamous carcinoma, basaloid squamous cell carcinoma, and adenosquamous carcinoma.[34] All of these tumors may involve the cranium and skull base by direct extension, metastases, or through perineurial spread. Conventional squamous cell carcinoma commonly demonstrates keratinization. With less differentiated tumors, keratinization is less prominent, and increasing nuclear atypia and mitotic activity are typically observed. In areas of invasion, reactive desmoplasia with collagen deposition is prominent and may be associated with chronic inflammation.

Nonkeratinizing squamous carcinoma may display a papillary or an endophytic growth pattern. Tumor cells are elongated with a columnar appearance and perpendicular to the surface. Keratinization is absent or minimal and typically nuclear pleomorphism, high nuclear cytoplasmic ratios, hyperchromasia, and increased mitotic activity are evident. Papillary, exophytic squamous cell carcinoma is an uncommon variant and may simulate a benign papilloma clinically, but histologic examination reveals malignant cytology. Human papilloma virus has been detected in a subset of papillary squamous cell carcinoma and pre-existing papillomas.[35]

Verrucous carcinoma is a variant that demonstrates local destruction of adjacent tissue, but without metastatic spread. Tumor cells are well-differentiated, with bland uniform squamous cells without significant dysplastic features and mitoses are usually restricted to the basal layer. Characteristic surface keratinization with "church-spire" keratosis and broad rete pegs pushing into the underlying stroma are classic. Commonly, chronic inflammation is prominent in the stroma.

Spindle cell squamous carcinoma is characterized by a proliferation of undifferentiated malignant spindled cells in association with a differentiated squamous cell component showing severe dysplasia. In some instances, the tumor may only be represented by the spindle cell component, where hypercellularity with pleomorphic, hyperchromatic nuclei, brisk mitotic activity, and necrosis is evident. Cytokeratin immunoreactivity is usually present in a subset of tumor cells, but may be negative in up to 40% of cases. p63 immunohistochemical staining may be helpful.

Basaloid squamous cell carcinoma is a high-grade, deeply invasive squamous cell carcinoma that less commonly involves the sinonasal tract. Histopathology may demonstrate solid, lobular, nested, cribriform, trabecular, or gland-like growth patterns. Closely packed cells with hyperchromatic nuclei, minimal cytoplasm, and brisk mitotic activity are typical.

JAYPEE BROTHERS

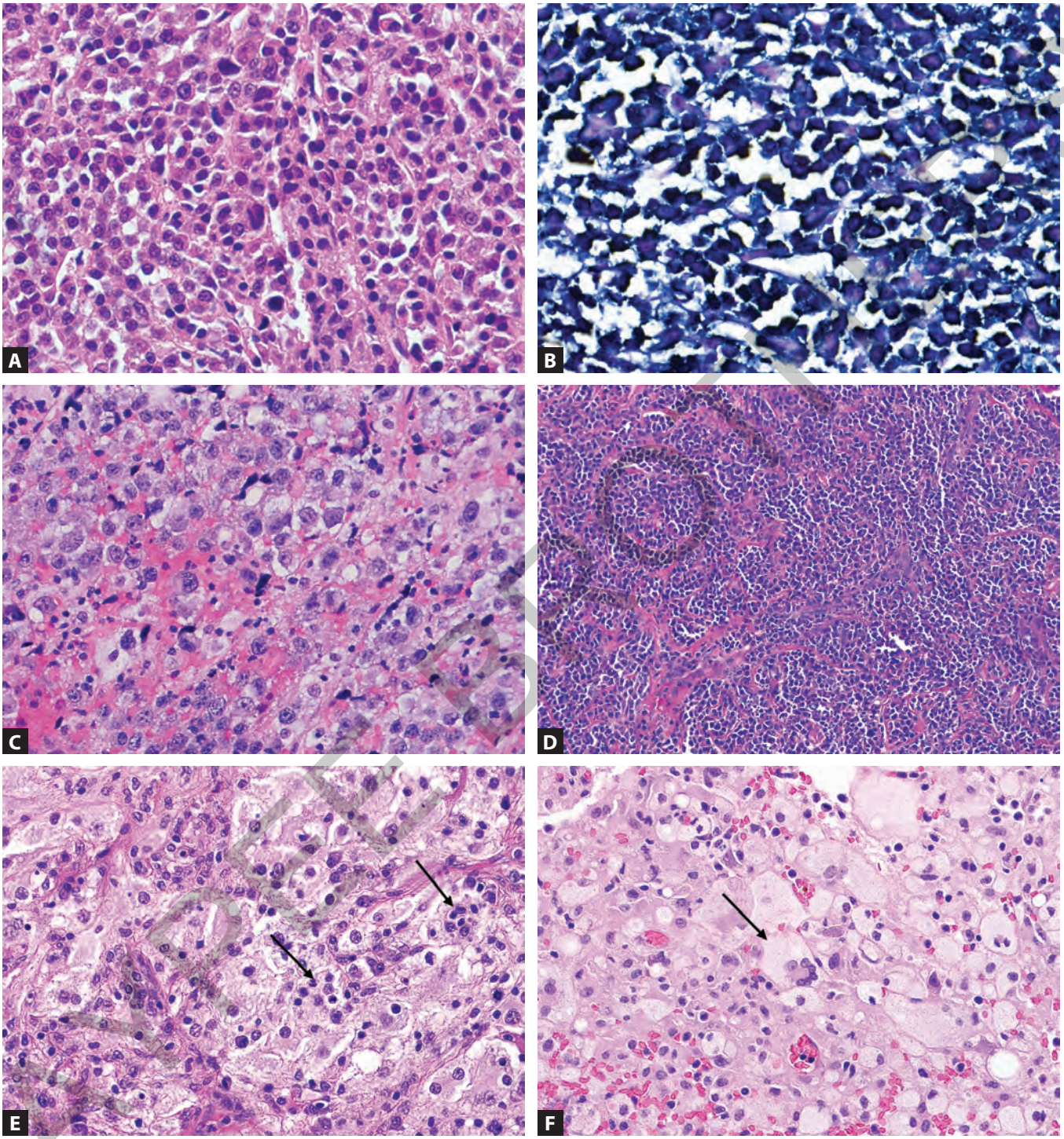

Figs. 3.7A to F: Hematopoietic neoplasms. Plasmacytoma may involve the skull base and is characterized by a clonal proliferation of neoplastic plasma cells (A). Clonality may be recognized by expression of a single light chain type, in this case kappa mRNA (chromogenic in situ hybridization) (B). Most lymphomas that involve the central nervous system and cranium are B-cell lymphomas, particularly large B-cell lymphoma (C). Marginal zone lymphomas are low grade, indolent lymphomas that usually present as dural-based masses (D). Histiocytoses that may spread intracranially and involve the skull base are Rosai-Dorfman disease (characterized by foamy histiocytes containing hematopoietic cells, i.e. emperipolesis, arrows) (E) and Erdheim-Chester disease (frequently containing "Touton-like" giant cells, arrow) (F).

JAYPEE

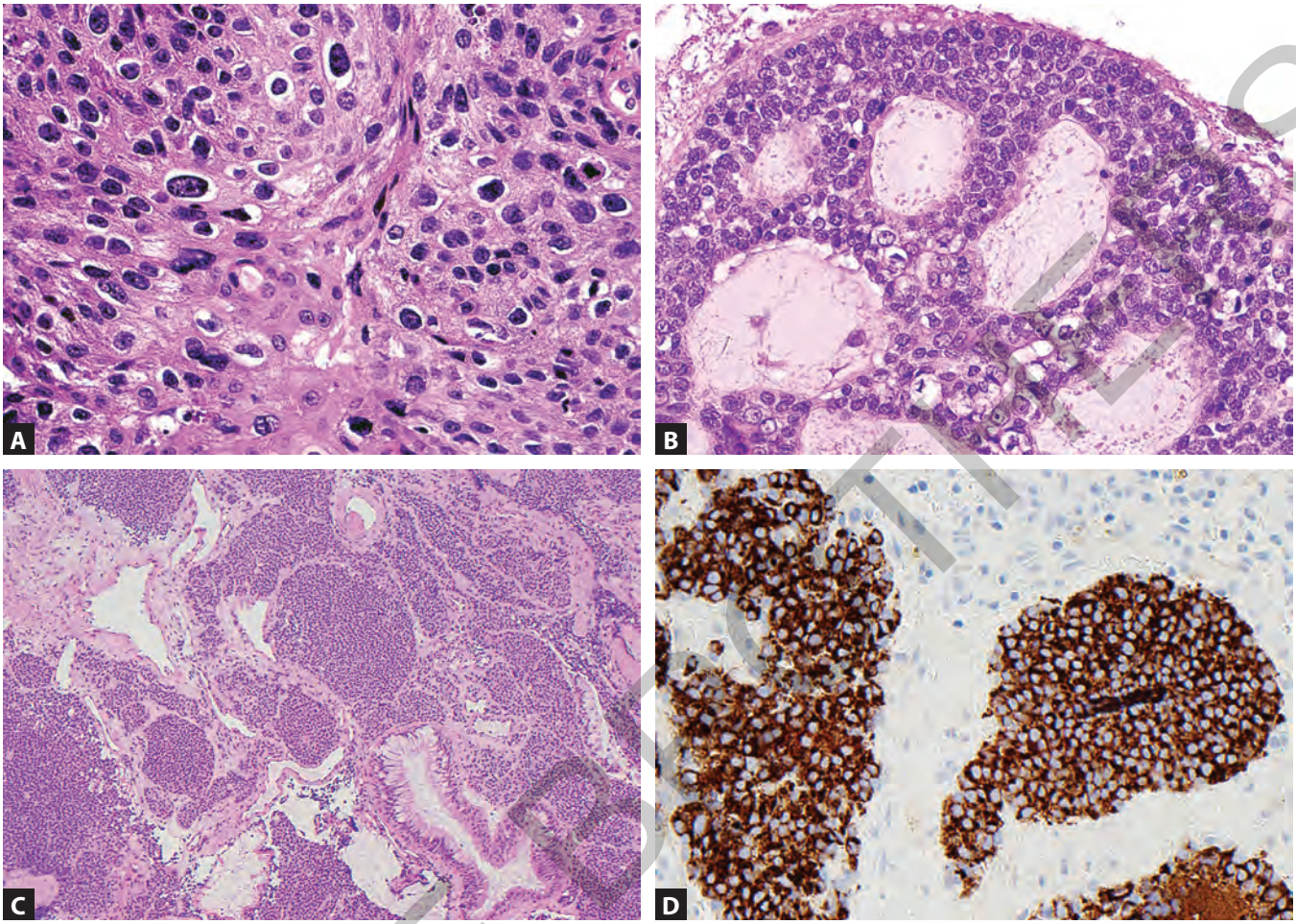

Figs. 3.8A to D: Head and neck neoplasms. Tumors of the head and neck proper that may spread intracranially and involve the skull base include squamous cell carcinoma (A), salivary gland-type tumors such as adenoid cystic carcinoma (B), and olfactory neuroblastoma (C). Olfactory neuroblastoma is characterized by nests of round cells, which strongly express synaptophysin (D).

Adenosquamous carcinoma is an uncommon high-grade subtype, where histologic features demonstrate areas of both adenocarcinoma and squamous carcinoma. Typically, the squamous component displays surface involvement with individual cell keratinization, intercellular bridges, and keratin pearls. The adenocarcinomatous component is usually in the submucosa with areas of glandular differentiation and intracellular and intraluminal mucicarmine, PAS-positive material.

Olfactory Neuroblastoma

Olfactory neuroblastoma or esthesioneuroblastoma is a malignant neoplasm that typically arises in the cribriform plate region with frequent involvement of the ethmoid sinuses. Histopathology shows uniform round cells with vesicular nuclei, indistinct cell borders, and surrounding neurofibrillary, synaptophysin-positive material (Figs. 3.8C and D). Homer Wright rosettes and rare Flexner Wintersteiner rosettes may be seen. Subclassification is based on four grades as defined by Hyams, where higher grade lesions show increasing anaplasia, hyperchromasia, and mitotic activity compared to grades I and II.

Salivary Gland Tumors

A variety of salivary gland neoplasms may involve the skull base. These usually arise in association with salivary gland tissue proper (parotid, submandibular, minor), but may also develop in the sellar region, petrous bone, and even the cerebellopontine angle, presumably from ectopic salivary gland rests. These neoplasms usually have various degrees of epithelial and myoepithelial differentiation.

JAYPEE BROTHERS

Pleomorphic adenoma is one of the most common salivary gland subtypes, consisted of cells with epithelial and myoepithelial differentiation, and associated chondromyxoid stroma. Typically, the lesion is encapsulated by a thin fibrous tissue. Classic architecture of the tumor consists of tubular islands surrounded by a myoepithelial perimeter in a background of chondromyxoid stroma. Carcinoma ex pleomorphic adenoma denotes malignant transformation of a long-standing pleomorphic adenoma or in a tumor with multiple recurrences.

Conversely, adenoid cystic carcinoma is a highly invasive neoplasm composed of basaloid cells with myoepithelial and basal cell differentiation with cribriform, tubular, or solid growth patterns in a myxoid or hyaline stroma (Fig. 3.8B). Histologic examination usually demonstrates infiltrative growth. Extensive perineural invasion is a hallmark of this tumor, which facilitates spread in the head and neck and cranial structures. Other salivary gland type tumors include mucoepidermoid carcinoma and myoepithelioma/myoepithelial carcinoma, among others.

Nerve Sheath Tumors

Schwannoma is the most frequent intracranial nerve sheath tumor that is evaluated on biopsy material. Most often, it arises at the cerebellopontine angle, in association with the vestibular branch of cranial nerve VIII. However, it may involve other cranial nerve branches along the temporal bone or sella/parasellar region. Additionally, it may achieve enormous size at this site.[36] Bilateral vestibular schwannoma represents an important criterion for neurofibromatosis type 2. Schwannomas at all sites are characterized by variable proportions of compact areas (Antoni A) and loose, macrophage-rich areas (Antoni B) (Figs. 3.9A and B). Hyalinized vessels and perivascular hemosiderin deposition are frequent. Verocay bodies (i.e. characteristic palisades with an acellular center) are characteristic, almost diagnostic features of schwannoma. However, Verocay bodies may not be as frequent in vestibular schwannomas. Neurofibromas and malignant nerve sheath tumors may also arise intracranially (Figs. 3.9C and D), although they are relatively rare by comparison. A subset develop in patients satisfying criteria for neurofibromatosis type 1.[37]

Miscellaneous

Given the histologic diversity of skull base components and its intimate anatomic relation with both the head and neck and CNS, a variety of neoplasms may involve the skull base secondarily. These include paraganglioma and endolymphatic sac tumors, which are typically centered in the petrous bone and may be associated with local destruction, as well as gliomas, gliosarcomas, and embryonal tumors extending directly from the CNS or through leptomeningeal spread.

Metastases

A variety of metastatic tumors may involve the skull base structures (Figs. 3.10A and B). Common culprits include adenocarcinoma (Fig. 3.10B) (lung and breast primaries), squamous cell carcinoma (lung, head and neck primaries), and melanoma(Fig. 3.10A).

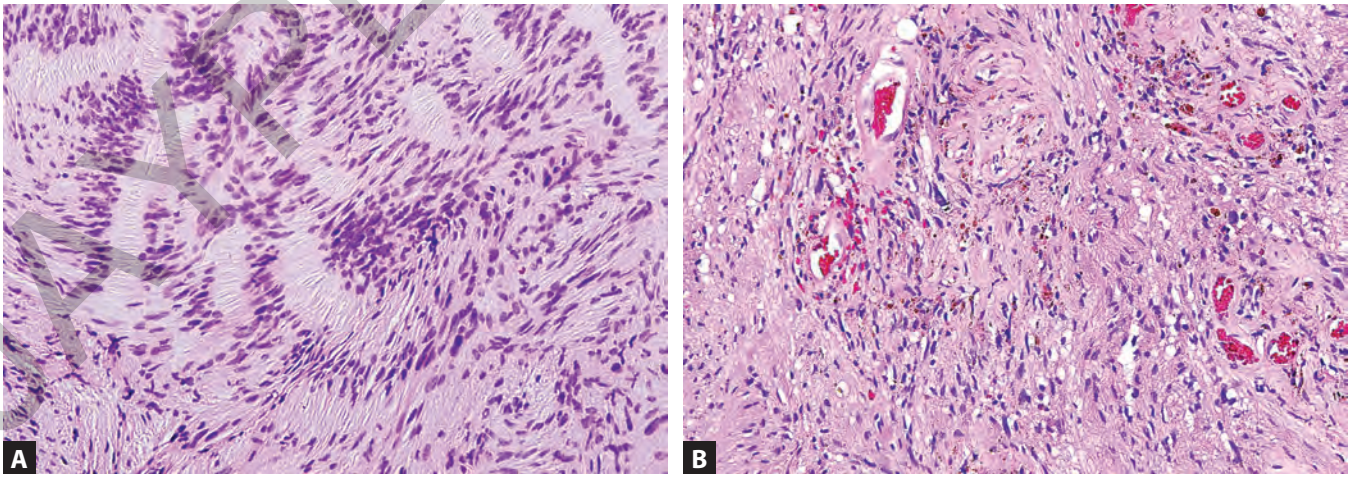

Figs. 3.9A and B: Nerve sheath tumors. Most intracranial nerve sheath tumors are schwannomas, characterized by the presence of Verocay bodies (A) and hyalinized vessels with associated hemosiderin (B).

JAYPEE BROTHERS

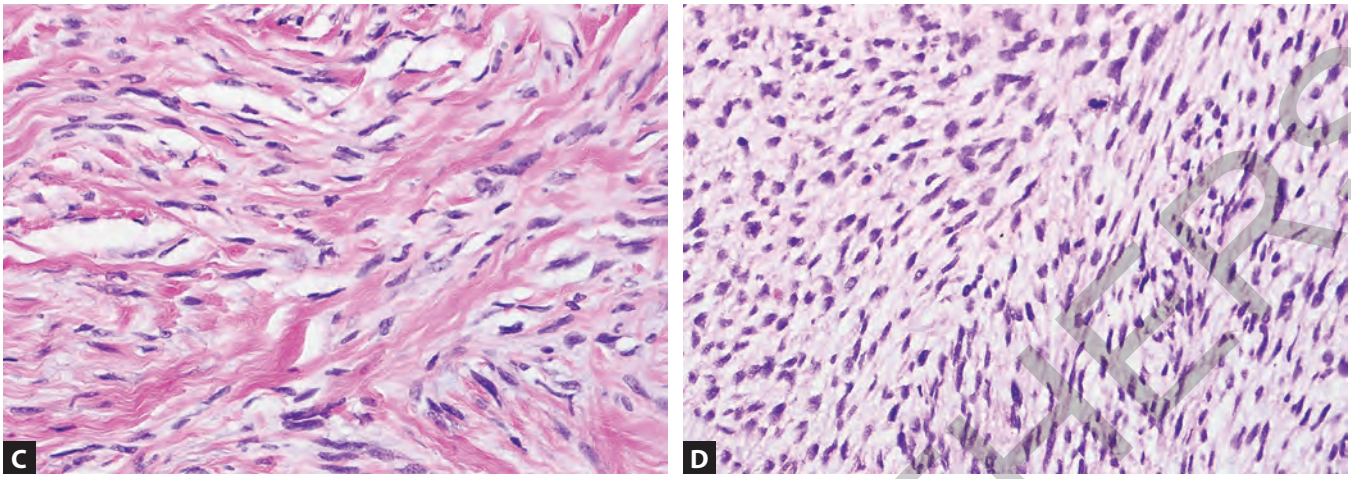

Figs. 3.9C and D: Other nerve sheath tumors may arise intracranially and can extensively involve the skull base including neurofibromas (C) and malignant peripheral nerve sheath tumors (D), particularly in the setting of neurofibromatosis type 1.

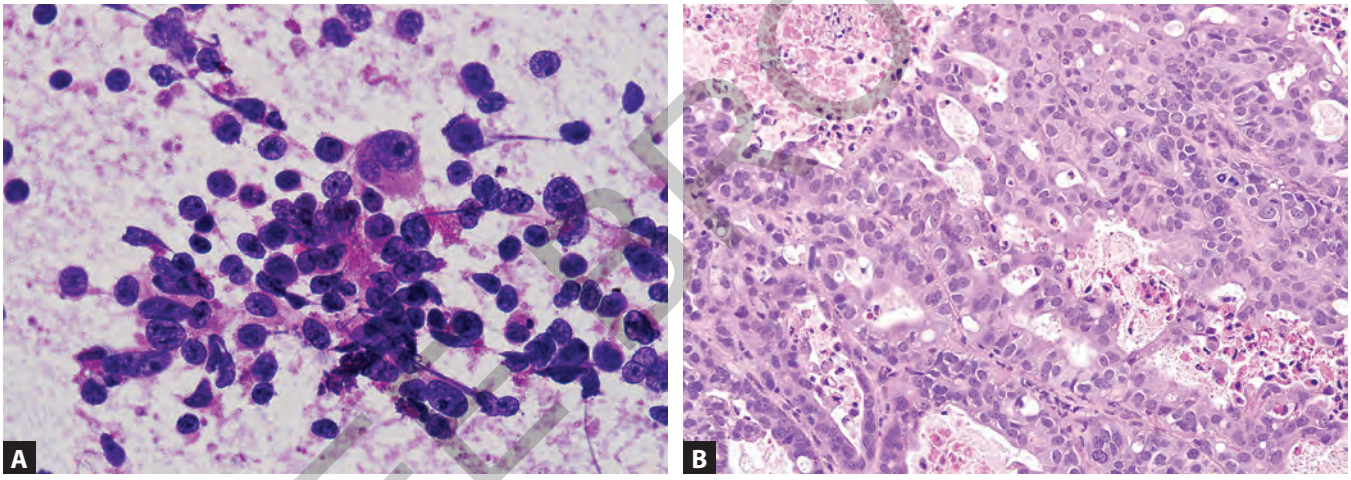

Figs. 3.10A and B: Metastases. Metastases not uncommonly involve intracranial structures. Common neoplasms include melanoma, which may be recognized in smear preparations (A) and adenocarcinomas (B).

REFERENCES

1. Radner H, Katenkamp D, Reifenberger G, et al. New developments in the pathology of skull base tumors. Virchows Arch. 2001;438:321-35.
2. Rodriguez F, Link MJ, Driscoll CL, et al. Neurosarcoidosis mimicking meningioma. Arch Neurol. 2005;62:148-9.
3. Lindstrom KM, Cousar JB, Lopes MB. IgG4-related meningeal disease: clinico-pathological features and proposal for diagnostic criteria. Acta Neuropathol. 2010;120:765-76.
4. Bertoni F, Unni KK, Dahlin DC, et al. Calcifying pseudoneoplasms of the neural axis. J Neurosurg. 1990;72:42-8.
5. Riddle ND, Bui MM. Fibrous dysplasia. Arch Pathol Lab Med. 2013;137:134-8.
6. McCarthy EF. Fibro-osseous lesions of the maxillofacial bones. Head Neck Pathol. 2013;7:5-10.
7. Pollandt K, Engels C, Kaiser E, et al. Gsalpha gene mutations in monostotic fibrous dysplasia of bone and fibrous dysplasia-like low-grade central osteosarcoma. Virchows Arch. 2001;439:170-5.
8. Weinstein LS. G(s)alpha mutations in fibrous dysplasia and McCune-Albright syndrome. J Bone Miner Res. 2006;21(Suppl 2):P120-4.
9. McMaster ML, Goldstein AM, Bromley CM, et al. Chordoma: incidence and survival patterns in the United States, 1973-1995. Cancer Causes Control. 2001;12:1-11.
10. Walcott BP, Nahed BV, Mohyeldin A, et al. Chordoma: current concepts, management, and future directions. Lancet Oncol. 2012;13:e69-76.
11. Thodou E, Kontogeorgos G, Scheithauer BW, et al. Intrasellar chordomas mimicking pituitary adenoma. J Neurosurg. 2000;92:976-82.

JAYPEE BROTHERS

12. Tirabosco R, Mangham DC, Rosenberg AE, et al. Brachyury expression in extra-axial skeletal and soft tissue chordomas: a marker that distinguishes chordoma from mixed tumor/myoepithelioma/parachordoma in soft tissue. Am J Surg Pathol. 2008;32:572-80.
13. Vujovic S, Henderson S, Presneau N, et al. Brachyury, a crucial regulator of notochordal development, is a novel biomarker for chordomas. J Pathol. 2006;209:157-65.
14. Mobley BC, McKenney JK, Bangs CD, et al. Loss of SMARCB1/INI1 expression in poorly differentiated chordomas. Acta Neuropathol. 2010;120:745-53.
15. Kan Z, Li H, Zhang J, et al. Intracranial mesenchymal chondrosarcoma: case report and literature review. Br J Neurosurg. 2012;26:912-4.
16. Wang L, Motoi T, Khanin R, et al. Identification of a novel, recurrent HEY1-NCOA2 fusion in mesenchymal chondrosarcoma based on a genome-wide screen of exon-level expression data. Genes Chromosomes Cancer. 2012;51:1 27-39.
17. Mawrin C, Perry A. Pathological classification and molecular genetics of meningiomas. J Neurooncol. 2010;99: 379-91.
18. Louis DN, Ohgaki H, Wiestler OD, et al. WHO Classification of Tumours of the Central Nervous System, 4th edition. IARC Press, Lyon, France; 2007.
19. Ruttledge MH, Xie YG, Han FY, et al. Deletions on chromosome 22 in sporadic meningioma. Genes Chromosomes Cancer. 1994;10:122-30.
20. Wellenreuther R, Kraus JA, Lenartz D, et al. Analysis of the neurofibromatosis 2 gene reveals molecular variants of meningioma. Am J Pathol. 1995;146:827-32.
21. Clark VE, Erson-Omay EZ, Serin A, et al. Genomic analysis of non-NF2 meningiomas reveals mutations in TRAF7, KLF4, AKT1, and SMO. Science. 2013;339:1077-80.
22. Fletcher CD, Bridge J, Hogendoorn PC, et al. WHO Classification of Tumours of Soft Tissue and Bone, 4th edition. IARC Press, Lyon, France; 2013.
23. Chmielecki J, Crago AM, Rosenberg M, et al. Whole-exome sequencing identifies a recurrent NAB2-STAT6 fusion in solitary fibrous tumors. Nat Genet. 2013;45:131-2.
24. Robinson DR, Wu YM, Kalyana-Sundaram S, et al. Identification of recurrent NAB2-STAT6 gene fusions in solitary fibrous tumor by integrative sequencing. Nat Genet. 2013; 45:180-5.
25. Doyle LA, Vivero M, Fletcher CD, et al. Nuclear expression of STAT6 distinguishes solitary fibrous tumor from histologic mimics. Mod Pathol. 2014;27:390-5.
26. Bell WR, Josue-Torres I, Quinones-Hinojosa A, et al. Inflammatory myofibroblastic tumor involving the central nervous system. Pathol Case Rev. 2013;18:257-61.
27. Swain RS, Tihan T, Horvai AE, et al. Inflammatory myofibroblastic tumor of the central nervous system and its relationship to inflammatory pseudotumor. Hum Pathol. 2008;39:410-9.
28. Lawrence B, Perez-Atayde A, Hibbard MK, et al. TPM3-ALK and TPM4-ALK oncogenes in inflammatory myofibroblastic tumors. Am J Pathol. 2000;157:377-84.
29. Coffin CM, Humphrey PA, Dehner LP. Extrapulmonary inflammatory myofibroblastic tumor: a clinical and pathological survey. Semin Diagn Pathol. 1998;15:85-101.
30. Brat DJ, Giannini C, Scheithauer BW, et al. Primary melanocytic neoplasms of the central nervous systems. Am J Surg Pathol. 1999;23:745-54.
31. Brastianos PK, Taylor-Weiner A, Manley PE, et al. Exome sequencing identifies BRAF mutations in papillary craniopharyngiomas. Nat Genet. 2014;46:161-5.
32. Tu PH, Giannini C, Judkins AR, et al. Clinicopathologic and genetic profile of intracranial marginal zone lymphoma: a primary low-grade CNS lymphoma that mimics meningioma. J Clin Oncol. 2005;23:5718-27.
33. Haroche J, Cohen-Aubart F, Emile JF, et al. Dramatic efficacy of vemurafenib in both multisystemic and refractory Erdheim-Chester disease and Langerhans cell histiocytosis harboring the BRAF V600E mutation. Blood. 2013;121:1495-500.
34. Fletcher CD. Diagnostic Histopathology of Tumors, 3rd edition. 2007. Churchill Livingstone, London, Edinburgh, New York, Philadelphia, St. Louis, Sydney, Toronto.
35. Suarez PA, Adler-Storthz K, Luna MA, et al. Papillary squamous cell carcinomas of the upper aerodigestive tract: a clinicopathologic and molecular study. Head Neck. 2000; 22:360-8.
36. Rodriguez FJ, Atkinson JL, Giannini C. Massive sellar and parasellar schwannoma. Arch Neurol. 2007;64:1198-9.
37. Scheithauer BW, Erdogan S, Rodriguez FJ, et al. Malignant peripheral nerve sheath tumors of cranial nerves and intracranial contents: a clinicopathologic study of 17 cases. Am J Surg Pathol. 2009;33:325-38.

JAYPEE BROTHERS

or detailed information on otolaryngology books, visit our website **www.jaypeebrothers.com,** for detailed information on otolaryngolo

Minimal Access Skull Base Surgery

Open and Endoscopic Assisted Approaches



A concise resource covering innovative and conventional approaches to skull base lesions.

This book combines years of practical experience of leading skull base surgeons from high-volume international centers. It brings the world of endoscopic and open skull base surgery together, highlighting the strengths of each approach in the management of selected skull base lesions.

An in-depth treatise on imaging and pathology of the skull base is provided to set the framework for a foundational understanding of common skull base disease processes.

Minimal access through natural cranial opening and potential secondary windows through the nose, orbit and oral cavity is presented to expand the versatility of the modern-day skull base surgical team.

Salient Features

- Highly illustrative images to demonstrate approaches
- Concise step-by-step guide for technical execution of approaches
- Several illustrative cases
- Selected videos demonstrating key steps of procedure
- Different views and surgical alternatives by field experts provide useful pearls and highlight nuances

---



Kofi Boahene MD FACS is an Associate Professor of Otolaryngology—Head and Neck Surgery at the Johns Hopkins University School of Medicine, Baltimore, Maryland, USA. He has written many peer-reviewed articles and book chapters on Skull Base Surgery with emphasis on minimal access approaches. Dr Boahene has also authored major textbooks in Facial Plastics and Reconstructive Surgery, an opinion article for CNN, and a personal biography 'However Far the Stream Flows'. He has been featured several times in print and broadcast media, including CNN International 'African Voices'. He is often an invited speaker for National and International conferences. Dr Boahene completed his surgical residency training in Otolaryngology—Head and Neck Surgery at the Mayo Clinic in Rochester, Minnesota, USA, where he received the Distinguished Mayo Brothers Fellowship Award for clinical excellence. He completed fellowship training in Facial Plastic Surgery, Reconstructive Microsurgery and Skull Base Surgery at the University of Minnesota, USA. Dr Boahene has been recognized by peers as an innovative surgeon and an outstanding teacher.



Alfredo Quiñones-Hinojosa MD FAANS FACS is a Professor of Neurological Surgery, Oncology, Neuroscience and Cellular and Molecular Medicine at the Johns Hopkins University School of Medicine, Baltimore, Maryland, USA. He has served as the main editor for five books including 'Schmidek and Sweet Operative Neurosurgical Techniques', the upcoming 'Video-Atlas of Neurosurgery', a personal biography 'Becoming Dr Q', and the acclaimed 'Controversies in Neuro-Oncology', which was awarded the First Prize in Oncology by the British Medical Association. Dr Quiñones has been invited to give more than 250 lectures Nationally and Internationally, including visiting professorships and being named Doctor Honoris Causa at several universities. His awards also include grants from the Howard Hughes Medical Institute Physician-Scientist Early Career Award, the Robert Wood Johnson Foundation, and the Maryland Stem Cell Foundation. Dr Quiñones has appeared in print and broadcast media, including NOVA, CNN, CBS News, NBC's The Today Show, and National Public Radio. In 2015, Forbes recognized Dr Quiñones as one of Mexico's most brilliant minds in the world, and his name featured in the Baltimore's magazine US Top Doctors and in 'Popular Science' magazine with the Brilliant 10 Scientists Award. In 2014, he was the recipient of Voices Against Brain Cancer's Neurosurgeon of the Year Award for his patient care and brain cancer research.

Available at all medical bookstores
or buy online at www.jaypeebrothers.com

JAYPEE BROTHERS
Medical Publishers (P) Ltd.
www.jaypeebrothers.com

Join us on facebook.com/JaypeeMedicalPublishers

Shelving Recommendations
OTOLARYNGOLOGY
HEAD AND NECK SURGERY
NEUROSURGERY

ISBN 978-93-5152-934-7