ebsite www.jaypeebrothers.com, for detailed information on pgmee books, visit our website www.jaypeebrothers.co

Sure Success in WBPGMEE 2015

(Fully Solved Question Paper)

Amritendu Das
Saswata Datta

Edited by
Sandeep Jain
Saptaporni Maiti

JAYPEE

Contents

WBPGMEE Fully Solved Paper 2015 **1–258**

- Anatomy *1*
- Physiology *10*
- Biochemistry *27*
- Pharmacology *35*
- Pathology *46*
- Microbiology *73*
- FSM *82*
- Preventive and social medicine *85*
- Eye *92*
- ENT *97*
- Medicine *102*
- Surgery *141*
- Gynecology and obstetrics *179*
- Pediatrics *202*
- Orthopedics *218*
- Skin *230*
- Anesthesia *235*
- Radiodiagnosis *241*
- Psychiatry *250*

Suggested Reading *259–262*

WBPGMEE Complete Solved Paper 2015

ANATOMY

Q.1. Internal trigone of bladder is formed from:

a. Mesonephric duct
b. Paramesonephric duct
c. Metanephros
d. Epiphoron

Or

Some of our friends thinks that this question was formatted like this—Internal trigone of bladder is formed from:

e. Mesonephric duct
f. Paramesonephric duct
g. Ventral part of cloaca
h. Dorsal part of cloaca

Ref—Langman 11th ed, p. 236, 238

Explanation

Since both the mesonephric ducts and ureters originate in the mesoderm, the mucosa of the bladder formed by incorporation of the ducts (the trigone of the bladder) is also

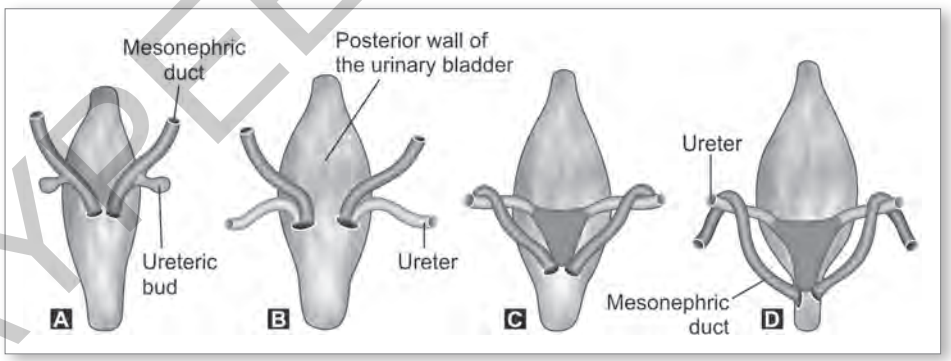

Dorsal views of the bladder showing the relation of the ureters and mesonephric ducts during development. Initially the ureters are formed by an outgrowth of the mesonephric duct (A), but with time they assume a separate entrance into the urinary bladder (B–D). Note the trigone of the bladder formed by incorporation ofhte mesonephric ducts (C, D)

Ans 1: a

JAYPEE BROTHERS

mesodermal. With time, the mesodermal lining of the trigone is replaced by endodermal epithelium, so that finally the inside of the bladder is completely lined with endodermal epithelium.

Development of Kidney

Uterine bud	Forms collecting system, i.e. ampulla pelvis major and minor calyces and collecting tubules (1–3 millions)
Metanephric mesoderm (blastema)	Forms excretory unit, i.e. nephron upto collecting ducts (renal vesicles, glomeruli, Bowman's capsule, PCT, loop of Henle and DCT)

Few points

- When the lumen of the intraembryonic portion of the allantois persists, a urachal fistula may cause urine to drain from the umbilicus.
- If only a local area of the allantois persists, secretory activity of its lining results in a cystic dilation, a urachal cyst.
- When the lumen in the upper part persists, it forms a urachal sinus.
- Exstrophy of the bladder is a ventral body wall defect in which the bladder mucosa is exposed. Epispadias is a constant feature, and the open urinary tract extends along the dorsal aspect of the penis through the bladder to the umbilicus. Exstrophy of the bladder may be caused by a lack of mesodermal migration into the region between the umbilicus and genital tubercle, followed by rupture of the thin layer of ectoderm. This anomaly is rare, occurring in 2/100,000 live births.

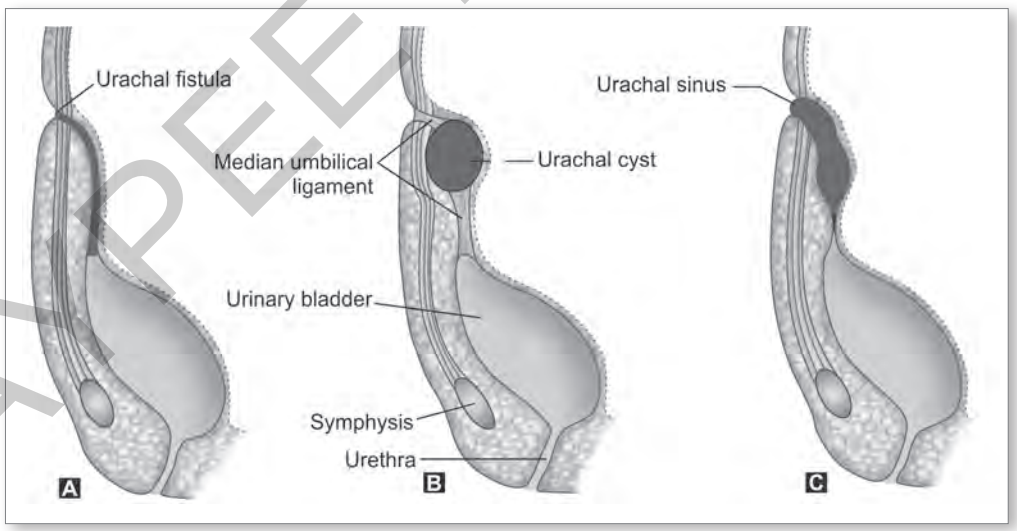

The sinus may or may not be in open communication with the urinary bladder
A. Urachal fistula. B. Urachal cyst. C. Urachal sinus.

JAYPEE BROTHERS

Cloaca

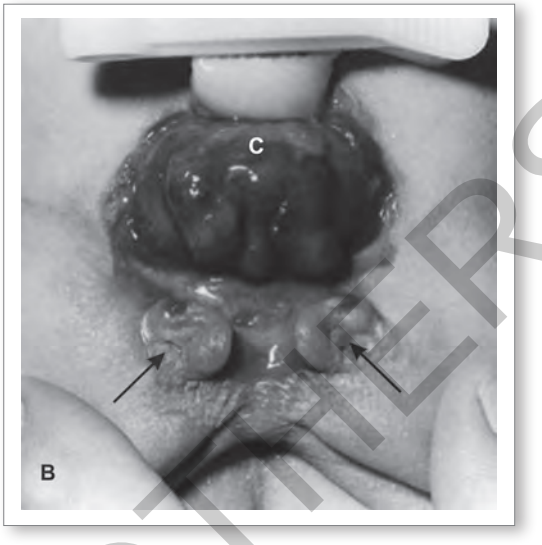

Cloaca

- Functionally, the urogenital system can be divided into two entirely different components: the urinary system and the genital system. Embryologically and anatomically, however, they are intimately interwoven. Both develop from a common mesodermal ridge (intermediate mesoderm) along the posterior wall of the abdominal cavity, and initially the excretory ducts of both systems enter a common cavity, the cloaca.
- During the fourth to seventh weeks of development, the cloaca divides into the urogenital sinus anteriorly and the anal canal posteriorly.
- Exstrophy of the cloaca is a more severe ventral body wall defect in which migration of mesoderm to the midline is inhibited and the tail (caudal) fold fails to progress. As a result, there is an extended thin layer of ectoderm that ruptures. The defect includes exstrophy of the bladder, spinal defects with or without meningomyelocele, imperforate anus and usually omphalocele. Occurrence is rare (1/30,000), and causation has not been defined, although the defect is associated with early amniotic rupture.

Q.2. Nerve supply of gemellus inferior:

a. Nerve to quadratus femoris
b. Inferior gluteal nerve
c. Pudendal nerve
d. Sciatic nerve

Ref—Chaurasia 4th ed, vol 2, p. 66, 73–75

Explanation

Muscle	Nerve supply
Gluteus maximus	Inferior gluteal nerve (L5, S1, S2)
Gluteus minimus Gluteus medius Tensor fascia lata	Superior gluteal nerve (L4, L5, S1)
Gemellus superior Obturator internus	Nerve to obturator internus (L5, S1, S2)
Gemellus inferior Quadratus femoris	Nerve to quadratus femoris (L4, L5, S1)
Obturator externus	Posterior division of obturator nerve (L2, L3, L4)
Piriformis	Ventral rami of S1, S2

Ans 2: a

JAYPEE BROTHERS

Q.3. Thyrohyoid membrane is pierced by:

a. Recurrent laryngeal nerve
b. Superior thyroid nerve
c. Superior thyroid artery and anterior thyroid nerve
d. Superior laryngeal vessels and the internal branch of the superior laryngeal nerve

Ref—Quick Review Series for BDS 1st Year Rao p. 81; Ram p. 415; Gray 20th ed (1918)

Explanation

Structure piercing thyroid membranes are:
- Superior laryngeal artery
- Internal laryngeal nerve.

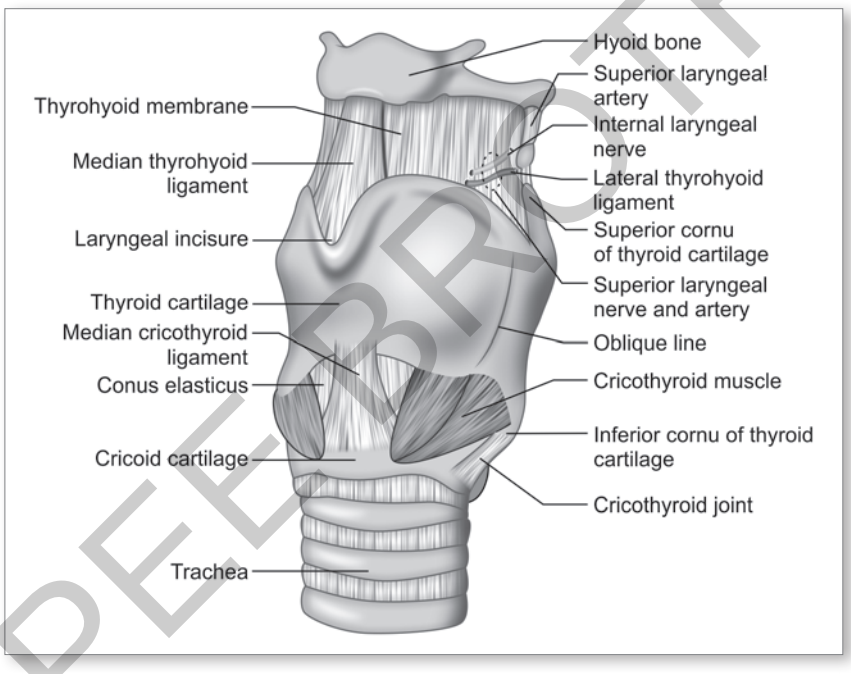

Anatomy of thyroid membranes

Structures Passing between/Piercing

- Structure **passing between two heads of gastrocnemius**: Sural nerve
- Structure **passing between two heads of lateral pterygoid**: Maxillary artery
- Structure **passing between pronator teres**: Median nerve

Contd...

Ans 3: d

JAYPEE BROTHERS

Contd...

- Structure **passing between plains of fibers of supinator**: Posterior interosseous nerve
- Structure **passing through tarsal tunnel**: Posterior tibial nerve
- Structure **passing through choroid fissure of eye**: Hyaloid artery
- Structure **passing through foramen of Vesalius**: Emissary vein
- Structure **passing through carotid sheath**: Internal carotid/common carotid artery, internal jugular vein and vagus nerve. External carotid is external to sheath
- Structure **piercing corocabrachialis**: Musculocutaneous nerve
- Structure **piercing clavipectoral fascia (encloses subclavius)**: Lateral pectoral nerve, thoracoacromial vessels and cephalic vein
- Structure **piercing thyrohyoid membrane**: Internal laryngeal nerve

Important Structures "Accompanying"

- **Axillary nerve** accompanies posterior humeral circumflex artery
- **Radial nerve** accompanies profunda brachii vessels
- **Short saphenous vein** accompanies sural nerve
- **Great saphenous vein** accompanies saphenous nerve
- **Superior thyroid vessels** accompany external laryngeal nerve
- **Superior laryngeal vessels** accompany internal laryngeal nerve
- **Interior laryngeal vessels** accompany recurrent laryngeal nerve

Q.4. Pulmonary ligament formed by:

a. Cervical pleura
b. Diaphragmatic pleura
c. Costal pleura
d. Mediastinal pleura

Ref—Gray 3rd ed, p.167; Chaurasia 4th ed, vol 1, p. 220

Explanation

- Mediastinal pleura is the answer of choice.
- Let us clear this question. We all know that parietal pleura is subdivided into 4 parts:
  - Costal
  - Diaphragmatic
  - Mediastinal
  - Cervical

Now mediastinal pleura reflected over the root of the lungs and become continuous with the pulmonary pleura around the hilum.

The root of each lung is a short tubular collection of structures that together attach the

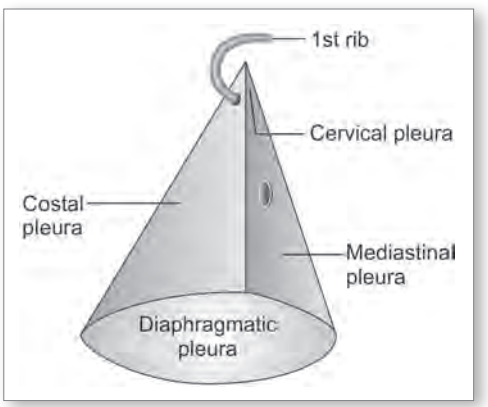

Pleura

Ans 4: d

JAYPEE BROTHERS

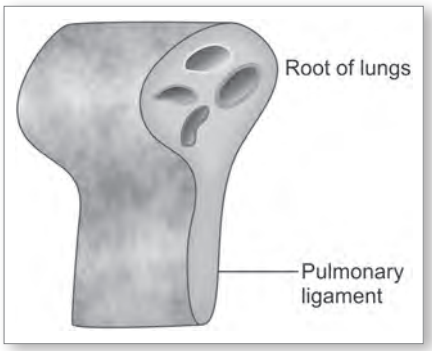

Pulmonary ligament

lung to structures in the mediastinum. It is covered by a sleeve of mediastinal pleura that reflects onto the surface of the lung as visceral pleura. The region outlined by this pleural reflection on the medial surface of the lung is the hilum, where structures enter and leave. A thin blade-like fold of pleura projects inferiorly from the root of the lung and extends from the hilum to the mediastinum. This structure is the pulmonary ligament. It may stabilize the position of the inferior lobe and may also accommodate the down-and-up translocation of structures in the root during breathing.

Costal pleura lines the thoracic wall ribs and intercostal space to which it is loosely attached by a layer of areola tissue called the endothoracic fascia.

Cervical pleura extends into the neck and covers the apex of the lungs.

Diaphragmatic pleura lines the superior aspect of the diaphragm.

Also Know

Endothoracic fascia

Costal pleura is loosely attached by a layer of areolar tissue is called endothoracic fascia.

Costomediastinal recesses

Anteriorly, a costomediastinal recess occurs on each side where costal pleura is opposed to mediastinal pleura. The largest is on the left side in the region overlying the heart.

Costodiaphragmatic recesses

The largest and clinically most important recesses are the costodiaphragmatic recesses, which occur in each pleural cavity between the costal pleura and diaphragmatic pleura.



Pleura

JAYPEE BROTHERS

Q.5. Regarding articular cartilage which is true?

a. Hyaline cartilage with perichondrium
b. Hyaline cartilage without perichondrium
c. White fibrocartilage
d. None of the above

Ref—Chaurasia 3rd ed, p. 40

Explanation

Let us discuss with each options

"The articular cartilage has no perichondrium so that its regeneration after injury is inadequate." —The Handbook of General Anatomy by BD Chaurasia 3rd ed, p. 40

"Hyaline cartilage is an example of articular cartilage." —The Handbook of General Anatomy by BD Chaurasia 3rd ed, p. 40

So the answer will be option (b), i.e. hyaline cartilage without perichondrium.

Few points about articular cartilage

- Articular cartilage devoid of perichondrium and there is no ossification
- It is devoid of nerve supply
- Act as shock absorber.

Cartilage	Example
Hyaline cartilage	Embryonic cartilage Articular cartilage Costal cartilage Tracheal cartilage Bronchial cartilage Cartilage of nose and larynx
Fibrocartilage	Intervertebral disks Intra-articular disks Menisci Labra
Elastic cartilage	External ear cartilage Auditory tube Small cartilage of inlet of larynx

Q.6. Which of following developed from left horn of sinus venosus?

a. Superior vena cava
b. Right atrium
c. Left atrium
d. Coronary sinus

Ref—Cunningham 5th ed, p. 1032; Netter 2nd ed, vol 8, p. 87; Langman 10th ed, p. 166, 167

Ans 5: b, Ans 6: d

JAYPEE BROTHERS

Explanation

"The right segment of the sinus venosus absorbed into the right atrium and the left segment forms coronary sinus." —Cunningham's Textbook of Anatomy by Daniel John Cunningham; 5th ed, p. 1032.

"The sinus venosus modifies and can be divided into three part; right and left horns and body. The right horn gets incorporated into the right atrium while the left horn and body gives rise to the coronary sinus". BD Chaurasia's Human Anatomy by BD Chaurasia vol 1, 4th ed, p. 253.

In the middle of the fourth week, the sinus venosus receives venous blood from the right and left sinus horns. Each horn receives blood from three important veins; (a) the vitelline or omphalomesenteric vein, (b) the umbilical vein and (c) the common cardinal vein. At first, communication between the sinus and the atrium is wide. However, the entrance of the sinus shifts to the right soon. This shift is caused primarily by left-to-right shunts of blood, which occur in the venous system during the fourth and fifth weeks of development.

With obliteration of the right umbilical vein and the left vitelline vein during the fifth week, the left sinus horn rapidly loses its importance. When the left common cardinal vein is obliterated in 10 weeks, all that remains of the left sinus horn is the oblique vein of the left atrium and the coronary sinus.

As a result of left-to-right shunts of blood, the right sinus horn and veins enlarge greatly. The right horn, which now forms the only communication between the original sinus venosus and the atrium, is incorporated into the right atrium to form the smooth-walled part of the right atrium. Its entrance, the sinuatrial orifice, is flanked on each side by a valvular fold, the right and left venous valves.

Dorsocranially, the valves fuse, forming a ridge known as the septum spurium. Initially the valves are large, but when the right sinus horn is incorporated into the wall of the atrium,

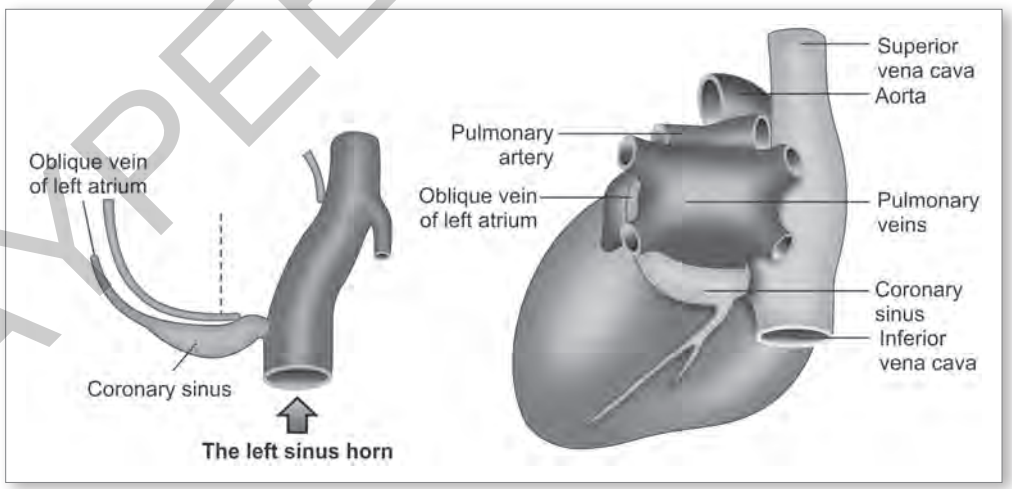

Development of coronary sinus

JAYPEE BROTHERS

the left venous valve and the septum spurium fuse with the developing atrial septum. The superior portion of the right venous valve disappears entirely. The inferior portion develops into two parts, (a) the valve of the inferior vena cava and (b) the valve of the coronary sinus. The crista terminalis forms the dividing line between the original trabeculated part of the right atrium and the smooth-walled part (sinus venarum), which originates from the right sinus horn.

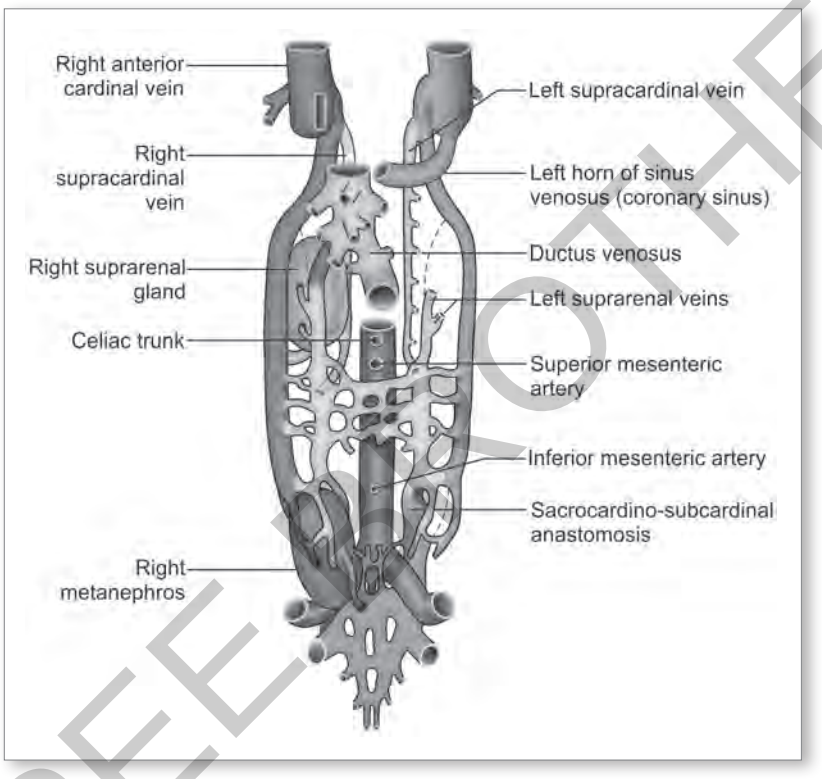

Left horn of sinus venosus

Q.7. Optic radiation passes through:

a. Sublenticular portion
b. Retrolenticular portion
c. Anterior limb of internal capsule
d. Posterior limb of internal capsule

Ref—Chaurasia 4th ed, vol 3, p. 364–365; Kulkarni p. 430; Jinkins p. 216

Ans 7: b

JAYPEE BROTHERS

Explanation

Parts of internal capsule and tracts passing through it

Part	Descending tract	Ascending tract
Anterior limb	Frontopontine	Anterior thalamic radiation
Genu	Corticonuclear (part of pyramidal tract going to motor nuclei of cranial nerves forming their supranuclear pathway)	Superior thalamic radiation (anterior part)
Posterior limb	Corticopontine, corticorubral, corticospinal (pyramidal)	Superior thalamic radiation (fibers from globus pallidus to subthalmic nucleus)
Retrolentiform part	Parieto/occipitopontine	Posterior thalamic radiation, i.e. optic radiation
Sublentiform part	Parieto/temporopontine	Auditory radiation

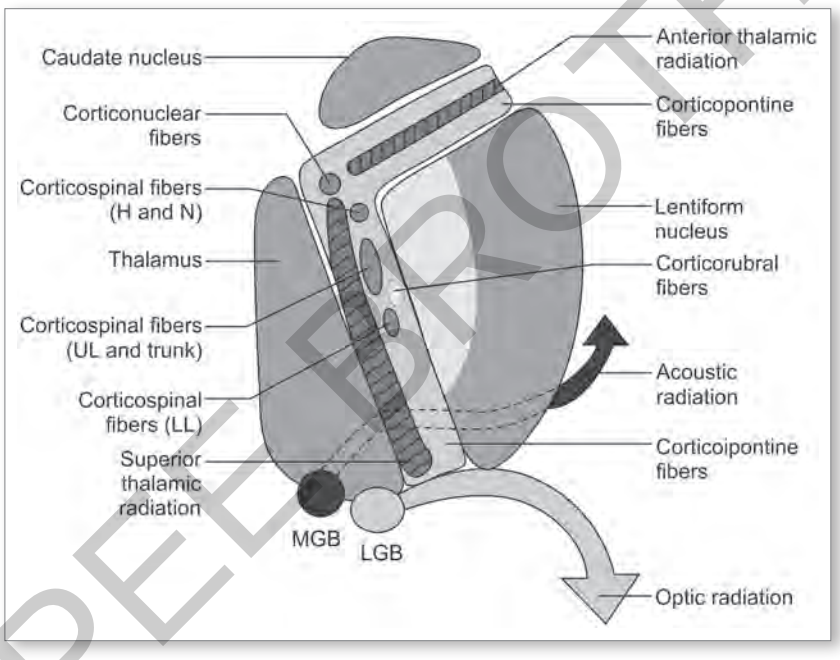

Internal capsule

PHYSIOLOGY

Q.8. Which is not true about JG apparatus?

a. Na sense at macula densa
b. Between glomerulus and afferent arteriols a dot like structure present known as macula densa
c. Macula densa acts as negative baroreceptor
d. Renin released from JG cell

Ref—Ganong 24th ed, p. 319, 372, 674, 705

Ans 8: b

JAYPEE BROTHERS

Explanation

It is a answer of exclusion.

Option a is correct, i.e.we all know that Na is sensed at macula densa.

"To perform the function of autoregulation, the kidneys have a feedback mechanism that links changes in sodium chloride concentration at the macula densa with the control of renal arteriolar resistance. This feedback helps ensure a relatively constant delivery of sodium chloride to the distal tubule and helps prevent spurious fluctuations in renal excretion that would otherwise occur."—Ganong's Review of Medical Physiology 24th ed, p. 319

About option b and option d the direct line from Ganong's Review of Medical Physiology 24th ed

"Renin is secreted from the juxtaglomerular cells that surround the renal afferent arterioles as they enter the glomeruli".

Ganong mentions the position of macula densa by the following two line.

"The thick end of the ascending limb of the loop of Henle reaches the glomerulus of the nephron from which the tubule arose and nestles between its afferent and efferent arterioles. Specialized cells at the end form the *macula densa*, which is close to the efferent and particularly the afferent arteriole. The macula, the neighboring *lacis cells* and the renin-secreting *granular cells* in the afferent arteriole form the *juxtaglomerular apparatus.*" Ganong's Review of Medical Physiology 24th ed, p. 674.

"At the point where the afferent arteriole enters the glomerulus and the efferent arteriole leaves it, the tubule of the nephron touches the arterioles of the glomerulus from which it arose. At this location, which marks the start of the distal convolution, there is a modified

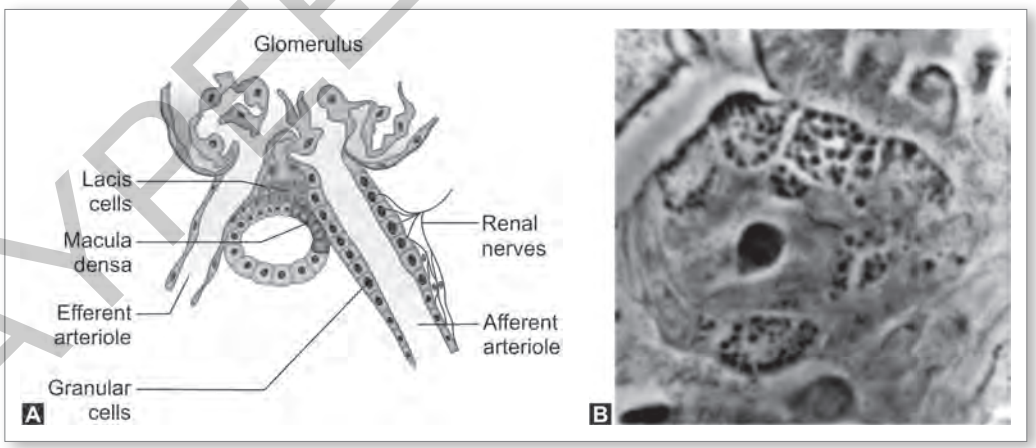

A. Diagram of glomerulus, showing the juxtaglomerular apparatus; B. Phase contrast photomicrograph of afferent arteriole in an unstained, freeze-dried preparation of the kidney of a mouse. Note the red blood cell in the lumen of the arteriole and the granular cells in the wall. (Courtesy of C Peil)

JAYPEE BROTHERS

region of tubular epithelium called the macula densa." Ganong's Review of Medical Physiology 24th ed, p. 705.

About option c

"One factor is an intrarenal baroreceptor mechanism that causes renin secretion to decrease when arteriolar pressure at the level of the JG cells increases and to increase when arteriolar pressure at this level falls. Another renin-regulating sensor is in the macula densa. Renin secretion is inversely proportional to the amount of Na^+ and Cl^- entering the distal renal tubules from the loop of Henle. Presumably, these electrolytes enter the macula densa cells via the Na-K-2Cl transporters in their apical membranes, and the increase in some fashion triggers a signal that decreases renin secretion in the juxtaglomerular cells in the adjacent aff erent arterioles. A possible mediator is NO, but the identity of the signal remains unsettled." Ganong's Review of Medical Physiology 24th ed, p. 705

From the above line we can conclude that macula densa act as a negative baroceptor to regulate renin secretion.

Few related points

Cell	Secretory function/comments
Granular cell	Renin
Renal medullary interstitial cells (RMICs)	Specialized fibroblast-like cells. They contain lipid droplets and are a major site of cyclooxygenase 2 (COX-2) and prostaglandin synthase (PGES) expression. PGE 2 is the major prostanoid synthesized in the kidney and is an important paracrine regulator of salt and water homeostasis. PGE 2 is secreted by the RMICs, macula densa cells of collecting duct
The arterioles and glomeruli	Prostacyclin (PGI 2) and other prostaglandins
Principal cells (P cells)	Relatively tall and have few organelles. They are involved in Na^+ reabsorption and vasopressin-stimulated water reabsorption. Present in CD
Intercalated cells (I cells)	Have more microvilli, cytoplasmic vesicles, and mitochondria. They are concerned with acid secretion and HCO_3^- transport. Present in CD DT

Many question in various PG exams has asked from this line.

"Signals from the renal tubule in each nephron feedback to affect filtration in its glomerulus. As the rate of flow through the ascending limb of the loop of Henle and first part of the distal tubule increases, glomerular filtration in the same nephron decreases, and, conversely, a decrease in flow increases the GFR. This process, which is called tubuloglomerular feedback, tends to maintain the constancy of the load delivered to the distal tubule. The sensor for this response is the *macula densa*". **Ganong's Review of Medical Physiology 24th ed, p. 684**

JAYPEE BROTHERS

detailed information on pgmee books, visit our website **www.jaypeebrothers.com,** for detailed information on pgmee

Sure Success in WBPGMEE 2015

Salient Features

- Authentic questions of WBPGMEE from 2015
- Fully solved MCQs with detailed explanatory answers
- Relevant text, comprising text that has been asked in questions from various other examinations
- Helps you to save your plenty of hours before WBPGMEE
- For online resources like clarification of answers, recent topics, pictures, MCQs and study materials, visit our website www.sphincterpg.com
- Direct contact with authors through www.sphincterpg.com

Amritendu Das MBBS DCH passed his MBBS from Calcutta Medical College and DCH from Dr BC Roy Post Graduate Institute of Pediatric Sciences, Kolkata, West Bengal, India. He is now working as a Medical Officer at Dr BC Roy Post Graduate Institute of Pediatric Sciences, Kolkata.



Saswata Datta MBBS PGT (Anesthesia) passed his MBBS from Bankura Sammilani Medical College and Hospital, Bankura, West Bengal, India. He has got admitted as PGT in the Department of Anesthesiology, RG Kar Medical Collage and Hospital, Kolkata, West Bengal. He is now working as a Medical Officer at Dr BC Roy Post Graduate Institute of Pediatric Sciences, Kolkata.



Available at all medical bookstores or buy online at www.jaypeebrothers.com

JAYPEE BROTHERS
Medical Publishers (P) Ltd.
www.jaypeebrothers.com

Join us on facebook.com/JaypeeMedicalPublishers

ISBN 978-93-5152-937-8

9 789351 529378