thers.com, for detailed information on anatomy books, visit our website www.jaypeebrothers.com, for detailed information on anatomy book

Online Videos
Demonstration of Dissected Specimens in Anatomy

Clinical Anatomy

(A Problem Solving Approach)

Volume 1

General Anatomy
General Embryology
Upper Limb
Lower Limb
Thorax

Neeta V Kulkarni

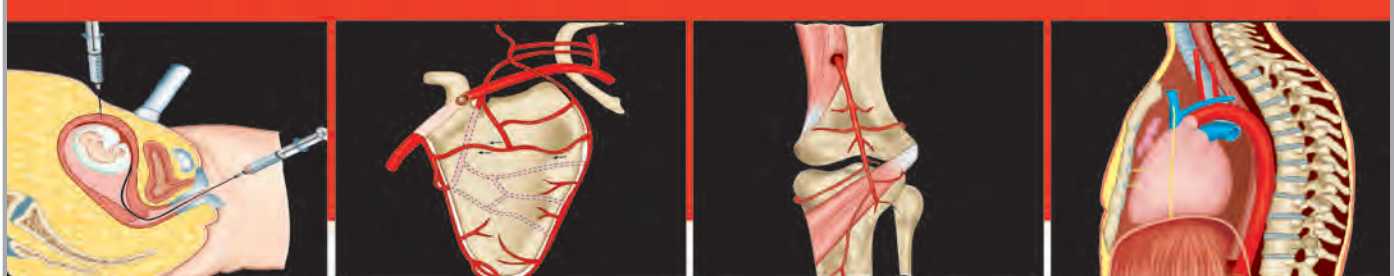

3rd Edition

Foreword
YM Fazil Marickar

JAYPEE

mation on anatomy book

Videos
Dissected
Anatomy

al
ny
ach)

me 2
Perineum
and Neck
inal Cord,
and Brain
al Nerves



3rd Edition

Foreword
YM Fazil Marickar

JAYPEE

Contents

Volume 1

Section 1: General Anatomy

1. Anatomy—Past, Present and Future 3
2. Basic Tissues of the Body 6
3. Cartilage, Bones and Joints 29
4. Vascular Tissue and Lymphatic Tissue 42
5. Skin, Hypodermis and Deep Fascia 49
6. Descriptive Anatomical Terms 54
7. Clinicoanatomical Problems and Solutions 57

Section 2: General Embryology

8. General Embryology including Basic Genetics and Genetic Causes of Birth Defects 63
9. Clinicoanatomical Problems and Solutions 94

Section 3: Upper Limb

10. Bones of Upper Extremity 101
11. Pectoral Region and Breast 119
12. Axilla and Axillary Lymph Nodes 131
13. Brachial Plexus and Axillary Vessels 136
14. Superficial Muscles of Back and Scapular Region 146
15. Pectoral Girdle and Shoulder Joint 155
16. Upper Limb (Cutaneous Nerves, Dermatomes, Superficial Veins, Lymph Vessels and Lymph Nodes) 162
17. Compartments of Arm 168
18. Cubital Fossa and Elbow Joint 176
19. Compartments of Forearm 183
20. Radioulnar Joints and Wrist Joint 198

21. Hand 207
22. Long Nerves of Upper Limb 223
23. Clinicoanatomical Problems and Solutions 231

Section 4: Lower Limb

24. Bones of Lower Limb 239
25. Surface Features, Cutaneous Nerves, Venous and Lymphatic Drainage of Lower Limb 258
26. Front of Thigh 268
27. Gluteal Region, Posterior Compartment of Thigh and Sciatic Nerve 281
28. Adductor or Medial Compartment of Thigh and Hip Joint 293
29. Popliteal Fossa and Knee Joint 305
30. Compartments of Leg and Retinacula Around Ankle 321
31. Tibiofibular Joints and the Ankle Joint 335
32. The Foot 340
33. Clinicoanatomical Problems and Solutions 355

Section 5: Thorax

34. Bones of Thoracic Cage 363
35. Thoracic Inlet and Thoracic Wall 371
36. Mediastinum, Pleural Cavities and Organs of Respiratory System 381
37. Thoracic Diaphragm and Phrenic Nerves 403
38. Development of Heart and Congenital Anomalies 411
39. Pharyngeal Arch Arteries and Fetal Circulation 418
40. Pericardium and Heart 424
41. Blood Supply of Heart 439
42. Fibrous Skeleton, Conducting Tissue and Nerve Supply of Heart 445
43. Major Blood Vessels of Thorax 449
44. Lymphatic Organs and Autonomic Nerves of Thorax 459
45. Esophagus 466
46. Clinicoanatomical Problems and Solutions 471

Volume 2

Section 6: Abdomen, Pelvis and Perineum

47. Bones of Abdomen and Pelvis 479
48. Anterior Abdominal Wall and Inguinal Canal 485
49. General Disposition of Peritoneum and Viscera in Abdominopelvic Cavity and Development of Gut 504
50. Stomach, Duodenum, Small Intestine and Large Intestine 519
51. Pancreas, Liver, Biliary Apparatus and Spleen 542
52. Blood Supply of Digestive Tract 560
53. Lumbar Fascia and Posterior Abdominal Wall or Retroperitoneum 567
54. Suprarenal Glands, Kidneys and Ureters 579
55. Extraperitoneal Structures in True Pelvis 596
56. Sigmoid Colon, Rectum and Urinary Bladder 603
57. Reproductive Organs 613
58. Perineum in Male and Female 638
59. Clinicoanatomical Problems and Solutions 662

Section 7: Head and Neck

60. Bones of Head and Neck 671
61. Scalp 697
62. Face including Eyelids and Lacrimal Apparatus 701
63. Parotid Gland 717
64. Cervical Fascia and Triangles of Neck 722
65. Submandibular Region and Submandibular Gland 736
66. Pharyngeal or Branchial Arches 744
67. Thyroid Gland and Parathyroid Glands 747
68. Major Blood Vessels, Cervical Plexus, Cervical Sympathetic Chain, Cervical Lymph Nodes and Deep Muscles of Neck 754
69. Infratemporal Fossa, Pterygopalatine Fossa, Maxillary Artery and Temporomandibular Joint 769
70. Orbit and Eyeball 783
71. Oral Cavity, Tongue and Palate 801
72. Nasal Cavity and Paranasal Air Sinuses 811
73. Pharynx 819
74. Larynx 829
75. Ear (External and Middle), Eustachian Tube, Mastoid Antrum and Internal Ear 837
76. Clinicoanatomical Problems and Solutions 850

Section 8: Vertebral Column and Spinal Cord, Cranial Cavity and Brain

77. Deep Muscles of Back, Suboccipital Triangle and Vertebral Artery 857
78. Vertebral Column 865
79. Spinal Cord 875
80. Cranial Meninges, Dural Venous Sinuses, Middle Menigeal Artery and Pituitary Gland 890
81. Development of Central Nervous System 904
82. Base of Brain and Brainstem 909
83. Cerebellum and Fourth Ventricle 925
84. Diencephalon and Third Ventricle 933
85. Cerebrum 942
86. Blood Supply of Brain 950
87. White Matter of Cerebrum 957
88. Reticular Formation, Lateral Ventricle, Basal Ganglia Limbic System and CSF Circulation 963
89. Overview of Autonomic Nervous System 973
90. Clinicoanatomical Problems and Solutions 977

Section 9: Cranial Nerves

91. Olfactory Nerve and Pathway 983
92. Optic Nerve and Visual (Optic) Pathway 985
93. Oculomotor Nerve, Trochlear Nerve and Abducent Nerve 990
94. Trigeminal Nerve and Sensory Pathway 996
95. Facial Nerve 1001
96. Vestibulocochlear Nerve, Vestibular Pathway and Auditory Pathway 1006
97. Glossopharyngeal Nerve 1010
98. Vagus Nerve 1013
99. Accessory Nerve 1017
100. Hypoglossal Nerve 1019
101. Clinicoanatomical Problems and Solutions 1022
Index *1025*

2

Basic Tissues of the Body

Chapter Contents

Structural Organization of Human Body
- Basic Tissues of the Body
- Epithelial Tissue
  - General Features of Epithelium
  - Basement Membrane
  - Nourishment of Epithelium
  - Classification of Epithelium
  - Classification of Exocrine Glands
- Connective Tissue
  - Basic Components
  - Connective Tissue Fibers
  - Classification of Connective Tissue Proper
- Muscular Tissue
  - Types of Muscle Tissue
- Neural or Nervous Tissue
  - Subdivisions of Nervous System
  - Basic Components of Nervous Tissue
  - Classification of Neurons
  - Microscopic Structure of Neuron
  - Synapse

STRUCTURAL ORGANIZATION OF HUMAN BODY

The complex human body shows five levels of structural organization (Fig. 2.1) starting from the cells and basic tissues to the organs and organ systems.

- The cells are the structural and functional units of the body, e.g. the epithelial cells, muscle cells (myocytes), neurons (nerve cells), connective tissue cells (fibroblasts), special connective tissue cells (chondrocytes, osteocytes, etc.).
- The groups of cells with similar structure and functions comprize the basic tissues, e.g. epithelial tissue, connective tissue, muscular tissue and neural tissue.
- The different types of basic tissues make up the organs, e.g. heart, kidney, lung and skin.
- A group of organs work in unison to perform a specific function form the organ system.
- Various organ systems capable of carrying out the basic life processes comprize an entire human being.

The knowledge of the histological structure of the organs helps us to understand the functions. It is also necessary to understand the pathological changes in the normal tissues in diseases. This helps in histopathological diagnosis of the disease from a bit of tissue (taken from diseased organ or lymph node) to examine under the microscope after processing and staining.

BASIC TISSUES OF THE BODY

There are four basic tissues in the body as follows:

1. Epithelial tissue
2. Connective tissue
3. Muscular tissue
4. Neural tissue

EPITHELIAL TISSUE

The epithelium is a layer or layers of cells resting on the basement membrane. It lines the external surfaces of the body and internal surface of body cavities and of hollow viscera (except the synovial cavity of a joint). The epithelia also line the secretory units and ducts of exocrine glands, kidney tubules, lung alveoli, etc. The chief functions of the epithelial tissue are protection, absorption and secretion.

General Features of Epithelium

- The epithelial tissue is rich in cells and poor in extracellular matrix. The cells are closely aggregated to form cellular sheets.
- The cell-to-cell junctions or intercellular adhesions are well developed in epithelial cells. The cell junctions maintain cell harmony and cell-to-cell communications.

JAYPEE BROTHERS

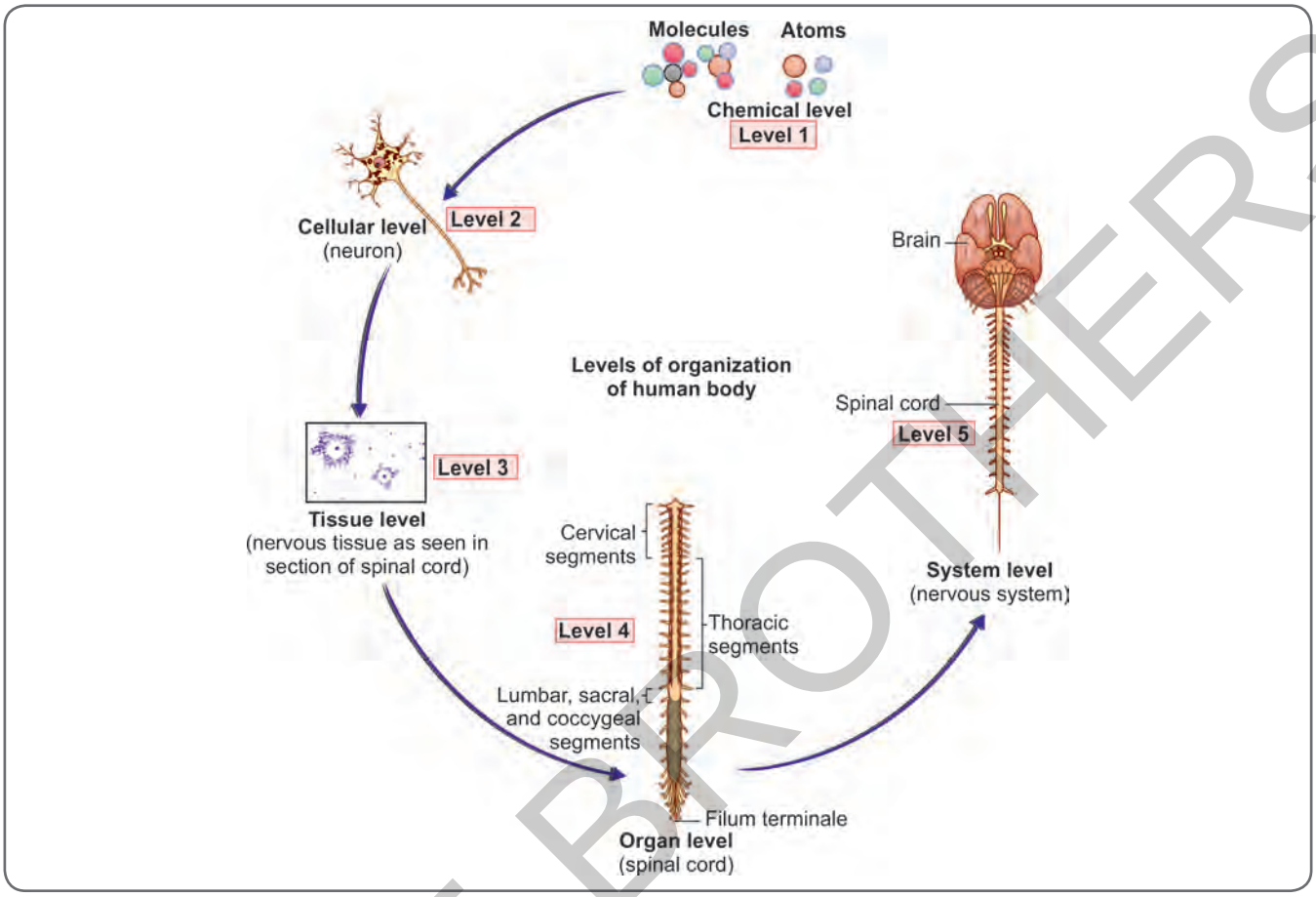

Fig. 2.1: Levels of structural organization of the human body (schematic representation)

- The basal surfaces of the epithelial cells rest on the basement membrane which separates the cells from the deeper vascular connective tissue. The luminal or apical surfaces of the cells may show structural specialization in response to the absorptive function.
- The epithelial tissue is avascular and hence receives nutrition by diffusion from blood capillaries of the connective tissue deeper to the basement membrane.
- The epithelium is capable of regeneration as exemplified by a very high rate of mitosis in intestinal epithelium and in the basal layer of the epidermis.

ADDED INFORMATION

Details of Cell Junctions (Fig. 2.2)

The intercellular junctions contain specific structural proteins with glue-like properties.

- Cell junctions on lateral surface of epithelial cells.

Contd…

Contd…

ADDED INFORMATION

- ***Tight junctions (zonula occludens)*** are located close to the luminal surface of the epithelial cells. In the tight junctions, the outer surfaces of the plasma membranes of the adjacent cells fuse thereby obliterating the intercellular space. The tight junctions occlude intercellular spaces for from the lumen of the viscus.
- ***Zonula adherens (adherens belt)*** is below the tight junction. The opposing plasma membranes show a gap of 20 nm and a dense plaque like material is present on the cytoplasmic surfaces of the plasma membranes at the junction. The microfilaments are embedded in this plaque. The zonula adherens provides rigidity to apical parts of the epithelial cells.
- ***Desmosomes (macula adherens)*** are punctate or spot-like in appearance on light microscopy. The attachment plaques contain adhesion molecules called ***cadherin***. The desmosomes provides firm adhesion to cells which are subject to friction as seen typically in stratum spinosum of the epidermis.

Contd…

JAYPEE BROTHERS

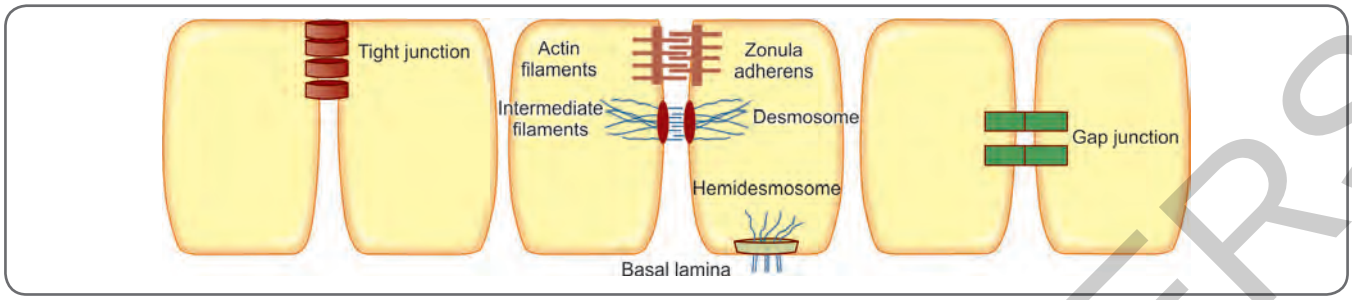

Fig. 2.2: Various types of specialized junctions

Contd…

ADDED INFORMATION

  - ***Gap junctions (nexus)*** are visible only by electron microscope. They are located close to the basal side of lateral surfaces of the cells. They contain transmembrane protein channels (connexons) that allow passage of small molecules between neighboring cells and thus allow cell-to-cell communication (including metabolic and electric coupling of cells).
- Cell junctions on the basal surface of epithelial cells:
  - ***Hemidesmosomes*** are half desmosomes that attach the basal surface of epithelial cell to the basal lamina of the basement membrane. The attachment plaque contains plenty of integrin molecules in the hemidesmosomes.

Surface Modifications of Epithelial Cells

- The ***cilia*** are long hair like projections of plasma membrane which serve the protective function in air conducting passages of respiratory system. The dust particles (inhaled from atmospheric air) and mucus (secreted by the goblet cells in the epithelium of air conducting passages) are driven upwards towards nasal cavity via nasopharynx by coordinated beating of the cilia lining the epithelium of bronchi, trachea, etc. Thus, cilia prevent the entry of dust particles into the bronchioles and the lung alveoli. Table 2.1 explains the differences between microvilli and cilia.
- ***Microvilli*** are the infoldings of apical plasma membrane (to increase the surface area). They are visible under electron microscope. Under the light microscope, microvilli appear as brush border or striated border, which is distinct when stained with special stains. They increase the surface area for absorption manifold. The microvilli are characteristic of epithelium of small intestine and of kidney tubules.
- ***Stereocilia*** represent long microvilli but are non-motile. They are found in sites where fluid secretion and resorption take place, e.g. in vas deferens and epididymis.

CLINICAL CORRELATION

Kartagener's Syndrome
This is a genetic disease, in which the person is born with immotile cilia. The patients suffer from respiratory symptoms caused by the accumulation of dust and other particulate matter (inhaled from atmospheric air), which normally are trapped by pseudostratified ciliated columnar epithelium.

TABLE 2.1: Differences between cilia and microvilli

Cilia	Microvilli
10 µm in length and 0.25 µm in diameter	1–2 mm in length and about 75–90 µm in diameter
Motile	Non-motile
Contains 9+2 pattern of microtubules	Contains numerous microfilaments (actin filaments)
Concerned with movement of ova through uterine tube and movement of secretions in trachea and bronchi towards pharynx	Concerned with absorptive functions
Seen over lining epithelium of respiratory tract and uterine tube	Seen over intestinal epithelium and proximal convulated tubule of kidney

Basement Membrane

The basement membrane is a structure that supports the epithelium. It consists of two distinct layers.

1. ***Basal lamina:*** The layer in contact with the epithelial cells. It is also produced by epithelial cells and is composed of type IV collagen fibers and laminin containing matrix.
2. ***Reticular lamina:*** It is the deeper layer and composed of reticular tissue, collagen fibers and matrix. It merges with surrounding connective tissue. It is synthesized by fibroblasts.

Functions of Basement Membrane

- It provides adhesion on one side to epithelial cells (or parenchyma); and on the other side to connective tissue (mainly collagen fibers).
- It acts as a barrier to the diffusion of molecules. The barrier function varies with location (because of variations in pore size). Large proteins are prevented from passing out of blood vessels, but (in the lung) diffusion of gases is allowed.

JAYPEE BROTHERS

- Recent work suggests that basement membranes may play a role in cell organization, as molecules within the membrane interact with receptors on cell surfaces. Substances present in the membrane may influence morphogenesis of cells to which they are attached.
- The membranes may influence the regeneration of peripheral nerves after injury, and may play a role in re-establishment of neuromuscular junctions.

Clinical Correlation

- The ***basement membrane thickens*** in pathologic conditions like ***nephropathies*** (kidney diseases) and ***vasculopathies*** (diseases of blood vessels). A thickened basement membrane is visible under the light microscope with routine hematoxylin and eosin staining.
- While examining the tissue biopsy from primary site of cancer arising from the epithelium (***epithelioma***), the pathologist looks for the basement membrane. An intact basement membrane is an indication that the cancer is localized to the primary site. This is known as ***carcinoma in situ*** stage of cancer. If the basement membrane is broken, it is an indication that cancer cells have begun to spread from the primary site.

Nourishment of Epithelium

As the epithelium is avascular it is nourished by capillaries in reticular lamina of basement membrane by a process called ***diffusion***.

Classification of Epithelium (Flowchart 2.1)

Based on the number of cell layers, the epithelium is classified as follows:

- ***Simple epithelium:*** It is composed of a single layer of cells resting on a basement membrane.
- ***Stratified (compound) epithelium:*** It is composed of more than one layer of cells stacked on each other, out of which only the basal cells rest on the basement membrane.

Based on the shape of cells in the surface layer, the simple and stratified epithelia are further classified as follows:

Simple Epithelium

Simple squamous epithelium (Pavement epithelium) (Fig. 2.3A)

Characteristics

- A single layer of flat squamous shaped cells rest on the basement membrane.

Flowchart 2.1: Classification of epithelia

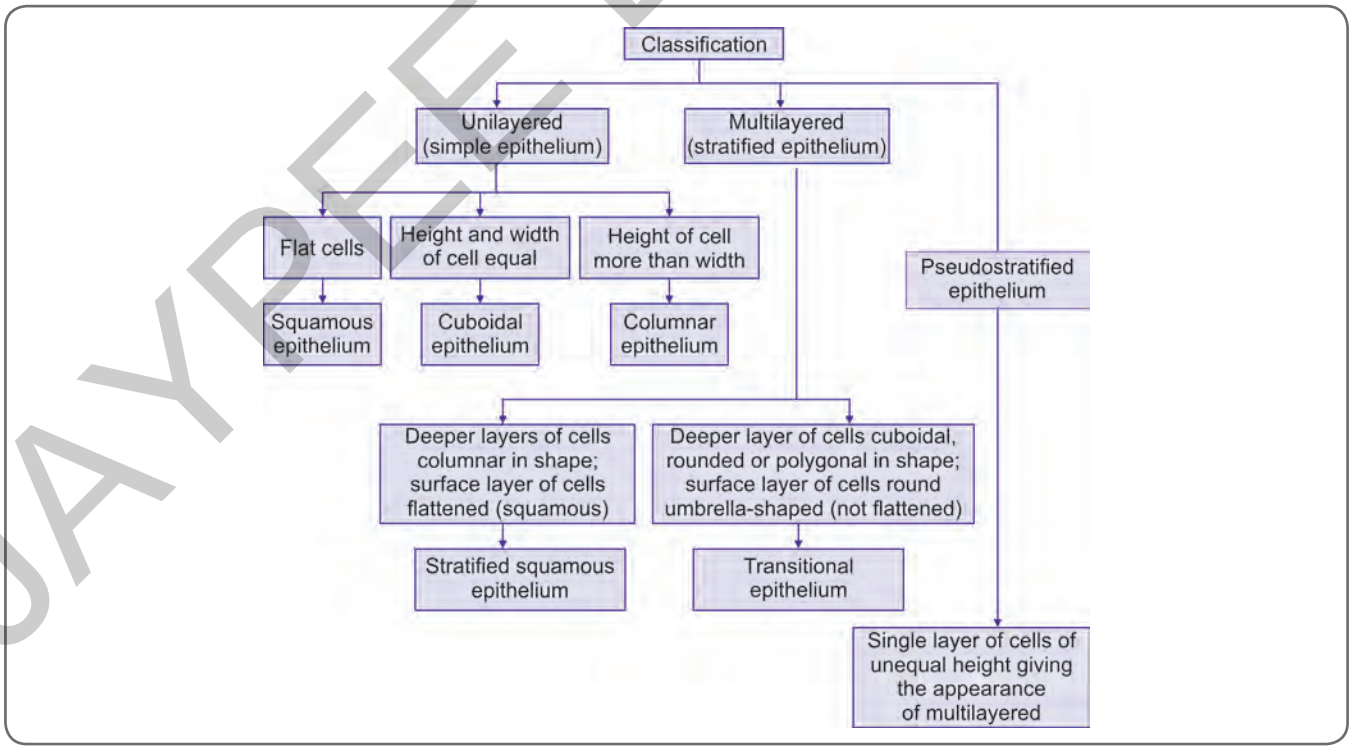

JAYPEE BROTHERS

- The cytoplasm forms a thin film and flattened nuclei are visible.

Function: Active transport of gases and nutrients through the cells.

Distribution

- Endothelium of the blood vessels.
- Endocardium of the heart chambers.
- Mesothelium of the serous membranes (pericardium, pleura and peritoneum).
- Epithelium of loops of Henle and parietal layer of Bowman's capsule in kidneys.
- Epithelium of lung alveoli.

Simple cuboidal epithelium (Fig. 2.3B)

Characteristics

- A single layer of cuboidal cells resting on basement membrane.
- The cells have equal height and breadth and their nuclei are rounded.

Distribution

- Germinal epithelium covering the surface of ovary.
- Lining of thyroid follicles (where the cells secrete thyroid hormones).
- Pigment cell layer of retina.

Simple columnar epithelium (Fig. 2.3C)

Characteristics

- A single layer of tall columnar cells resting on the basement membrane.
- Nuclei of the cells are elongated and placed closer to the base.

Subtypes of simple columnar epithelium

- Unmodified ***simple columnar*** epithelium as seen in some ducts of exocrine glands.
- ***Secretory simple columnar*** mucus secreting cells are present in gastric mucosa.
- ***Simple columnar epithelium with goblet cells*** lines small and large intestines. The goblet cells are the modified simple columnar cells at places, for the purpose of secretion of mucus.
- Simple columnar epithelium showing surface modifications for increasing absorptive surface is found in small intestine, renal tubules and gall bladder. Each columnar cell shows numerous microvilli (Fig. 2.3D) at its apical surface. Ultramicroscopically, the microvilli are minute finger-like projections of plasma membrane. Under low power they appear as striated or brush border.
- Simple columnar epithelium with cilia (Fig. 2.3E) (ciliated columnar epithelium) lining the uterine tube and uterus serves the function of transport of gametes.
- ***Pseudostratified ciliated columnar epithelium*** (Fig. 2.3F) with goblet cells (also known as respiratory epithelium) lines the respiratory tract from nasal cavity to intrapulmonary bronchi. Here, all the cells rest on the basement membrane but the nuclei of the cells

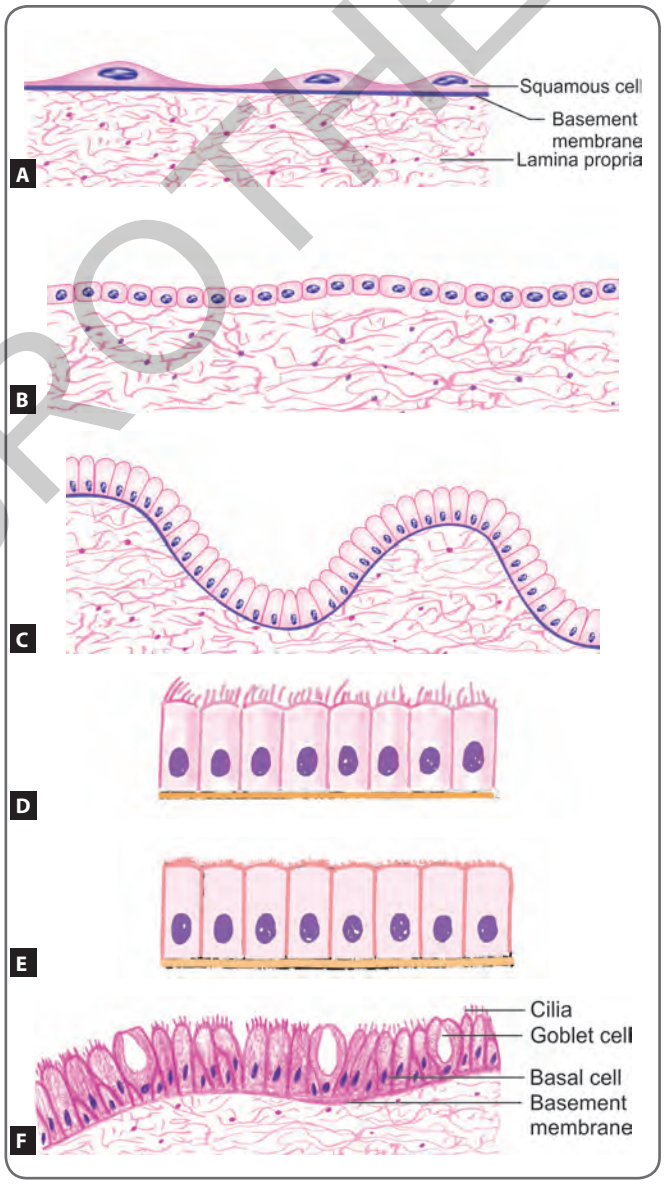

Figs 2.3A to F: Microscopic structure of **A.** Squamous epithelium; **B.** Cuboidal epithelium; **C.** Simple columnar epithelium; **D.** Columnar epithelium showing cilia; **E.** Columnar epithelium showing a striated border made up of microvilli; **F.** Pseudostratifed ciliated columnar epithelium

JAYPEE BROTHERS

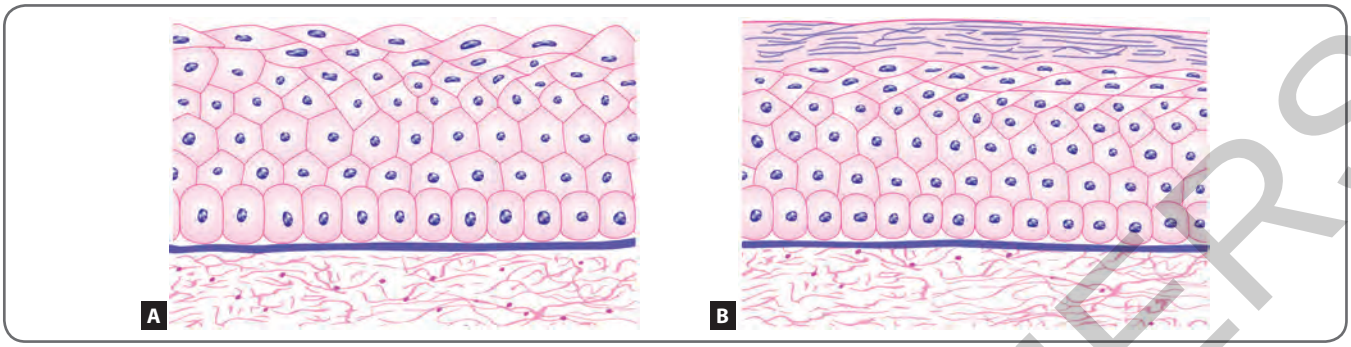

Figs 2.4A and B: Microscopic structure of stratifed squamous epithelium **A.** Non-keratinized; **B.** Keratinized

are at varying levels, thus creating false impression of stratification. This epithelium consists of shorter and taller cells. The taller cells bear cilia. The cilia dispel the foreign particles inhaled in the air towards nasal cavity and the mucus secreted by the goblet cells traps the foreign particles not dispelled by the cilia.

- ***Pseudostratified columnar epithelium*** with stereocilia (long, thick and non-motile microvilli) is found in vas deferens and epididymis, where the epithelium serves the functions of protection, absorption and secretion.

Stratified Epithelium

The stratified epithelium is multilayered where only the cells of basal layer rest on the basement membrane. It is divided into following types.

Stratified squamous non-keratinized epithelium (Fig. 2.4A)

- This epithelium is found in cornea, conjunctiva, oral mucosa, tongue, oropharynx, laryngopharynx, esophagus, ectocervix, vagina and male urethra inside the glans penis, etc.
- It forms the moist surfaces that are protective in function.
- It consists of multiple layers of cells of which superficial cells are flat (squamous) and basal cells are columnar. The intervening rows of cells are polyhedral. The basal cells are capable of mitosis to produce new cells. There is migration and gradual transformation of new cells into polyhedral cells and finally into flat cells, which are shed from the body periodically. The cells in all layers have nuclei.

Stratified squamous keratinized epithelium (Fig. 2.4B)

- This epithelium is found in epidermis of skin, lining of external auditory meatus, vestibule of nasal cavity, lining of the lowest part of anal canal, etc.
- It provides protection against abrasion, bacterial invasion and desiccation (drying).
- It is characterized by keratinization of superficial cells, which are dead and shed from the body surface. In the thick or glabrous skin of palms and soles, it is composed of five layers from basal to superficial aspect:

1. Stratum germinativum or basal layer with columnar cells having mitotic capacity.
2. Stratum spinosum of polygonal cells attached to each other by desmosomes.
3. Stratum granulosum of cells filled with keratohyalin granules.
4. Stratum lucidum, a layer with clear cells without distinct boundaries.
5. Stratum corneum having dead keratinized cells without nuclei.

Stratified cuboidal epithelium (Fig. 2.5A)

- This epithelium lines the ducts of sweat glands where it consists of two layers of cuboidal cells.
- The seminiferous epithelium in the testis is regarded as a special type of stratified cuboidal epithelium as a series of germ cells called ***spermatogonia***, ***primary spermatocytes***, ***secondary spermatocytes*** and ***spermatids*** are arranged from the basement membrane inwards.

Stratified columnar epithelium (Fig. 2.5B)

- This epithelium lines the spongy part of male urethra and the main ducts of large salivary glands and large ducts of mammary glands.
- There are several layers of columnar cells, which serve protective and secretory functions.

Transitional epithelium (Fig. 2.6)

This is a special type of epithelium lining the urinary passages. Hence it is called ***urothelium***.

JAYPEE BROTHERS

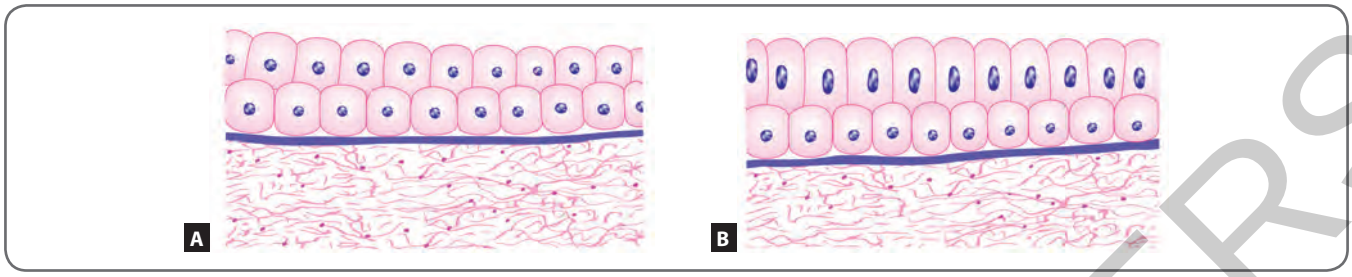

Figs 2.5A and B: Microscopic structure of **A.** Stratified cuboidal epithelium; **B.** Microscopic structure of stratified columnar epithelium

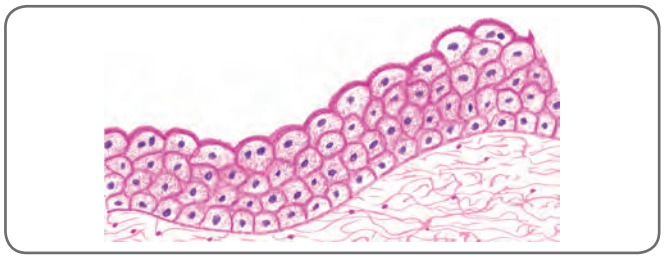

Fig. 2.6: Microscopic structure of transitional epithelium

It is found in renal calyces, renal pelvis, ureter, urinary bladder and proximal part of urethra.

It provides a permeability barrier to water and salts in urine.

When examined under light microscope it consists of:

- Cuboidal cells in basal layer, which are uninucleated and basophilic.
- Polygonal or rounded cells in middle layer.
- Large and facetted surface or umbrella cells (which are exposed to the urine).

Under electron microscope, the umbrella cells present modified plasma membrane on their luminal surface. Their apical cytoplasm contains microfilaments and fusiform membrane bound vesicles enclosing uroplakin plaques. In the distended state of the urinary bladder, the epithelium is stretched and the surface cells become flattened. The fusiform vesicles along with uroplakin plaques merge into the surface plasma membrane providing a reserve membrane during stretching.

Embryologic Insight

The epithelium is derived from endoderm, mesoderm and ectoderm as follows:

- ***Endoderm forms:*** The epithelium lining the gastrointestinal tract (with associated glands like liver and pancreas) and respiratory passages (and lung alveoli).
- ***Mesoderm forms:*** The endothelium lining blood vessels, mesothelium lining serous membranes, endocardium lining cardiac chambers, epithelium of kidney tubules and germinal epithelium of ovaries, etc.

Contd…

Contd…

Embryologic Insight

- ***Ectoderm forms:*** The epidermis of skin, oral mucosa, lining of ear canal and epithelium covering outer surface of tympanic membrane.

Student Interest

Basic tissues of the body are the foundation of ***histology and pathology***. Epithelium is a layer or layers of cells resting on the basement membrane. Epithelium lines hollow organs like digestive tract, respiratory tract, genitourinary tracts, ducts, secretory units of exocrine glands, kidney tubules and external surface of the body like epidermis of the skin (to cite a few examples). Epithelia are divided in to simple and compound (or stratified). In simple epithelium, there is a single row of similar cells in which all cells rest on the basement membrane. In compound epithelium there are multiple layers of cells but only the cells of basal layer rest on the basement membrane. The cells of epithelium work in harmony for which they are connected to adjoining cells by junctional complexes. Do not forget to brush your knowledge of the junctional complexes, surface specializations and the basement membrane.

Glandular Epithelium

The glands may consist of a single cell or aggregations of epithelial cells specialized for secretory function. The endocrine glands release secretion (hormone) directly into blood capillaries. The exocrine glands consist of secretory units (which synthesize the secretion) and ducts (by which they let out their secretion).

Classification of Exocrine Glands (Flowchart 2.2)

According to number of cells:

- Unicellular (e.g. goblet cell)
- Multicellular (e.g. salivary glands, sweat glands, mammary glands, liver, pancreas, etc.). Subdivisions are shown in Figures 2.7A to F.

JAYPEE BROTHERS

Flowchart 2.2: Classification of glands

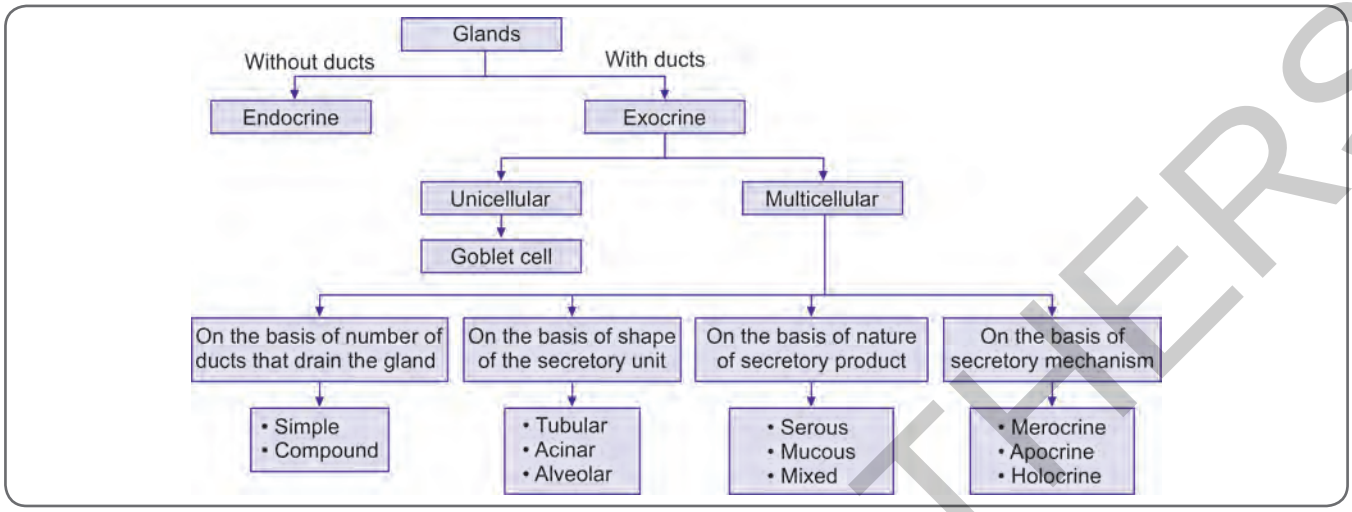

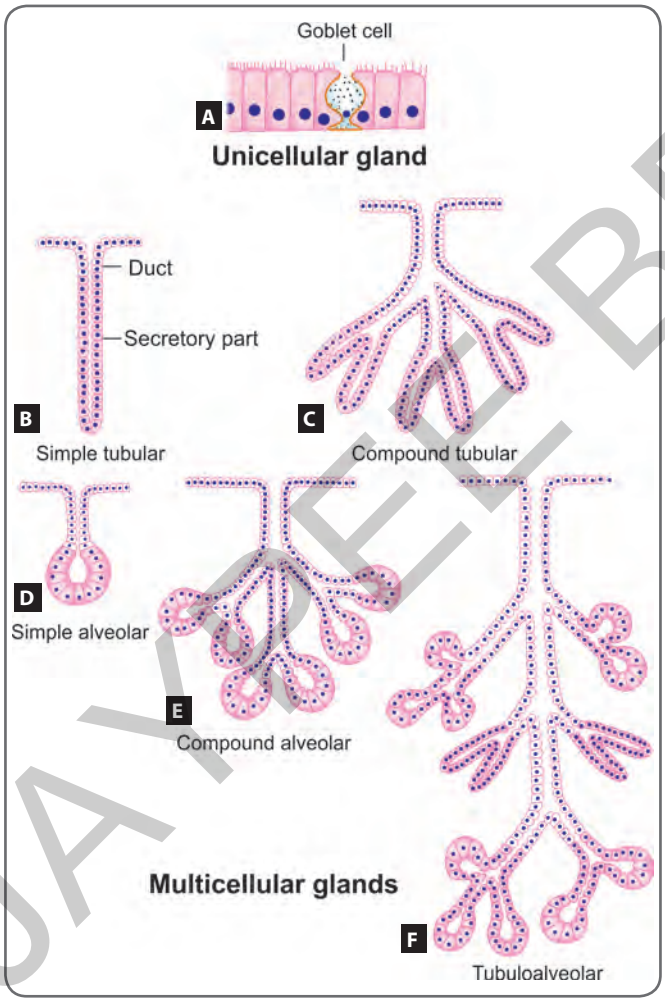

Figs 2.7A To F: Scheme to show various ways in which the secretory elements of a gland may be organized **A.** Unicellular gland; **B.** to **D.** Multicellular glands with a single duct are simple glands; **E.** and **F.** Multicellular glands with branching duct system are compound glands

Subtypes of Multicellular Exocrine Glands

Depending on duct pattern:

- Simple, if one duct drains the gland.
- Compound, if there is branching pattern of the ducts.

Depending on the shape of the secretory units:

- Simple tubular or coiled tubular (when the secretory units are shaped like small tubes).
- Alveolar or acinar (if secretory units are shaped like small bags).
- Tubuloalveolar (combination of the above two shapes).

Depending on the type of secretion (Figs 2.8A to C):

- ***Serous:*** Watery fluid containing protein (examples; parotid and lacrimal glands).
- ***Mucous:*** Viscous secretion containing mucus (examples; esophageal glands, pyloric glands, sublingual salivary glands).
- ***Mixed:*** Example—submandibular salivary glands.

Comparison of mucous and scours acini has been given in Table 2.2.

Note: Serous, mucous and mixed acini have distinctive histological features, which you have to draw in histology records.

Depending on the mode of their secretion (Figs 2.9A to C):

- ***Merocrine (eccrine)*** in which secretory product is expelled by exocytosis (e.g. sweat glands involved in thermoregulation and supplied by cholinergic sympathetic innervation) (Fig. 2.9A).
- ***Apocrine*** in which the secretory product accumulates in apical cytoplasm and is expelled by pinching of the apical plasma membrane (e.g. mammary gland and apocrine type of sweat glands that are active after puberty and are found in skin of axilla and around genital organ) (Fig. 2.9B).

JAYPEE BROTHERS

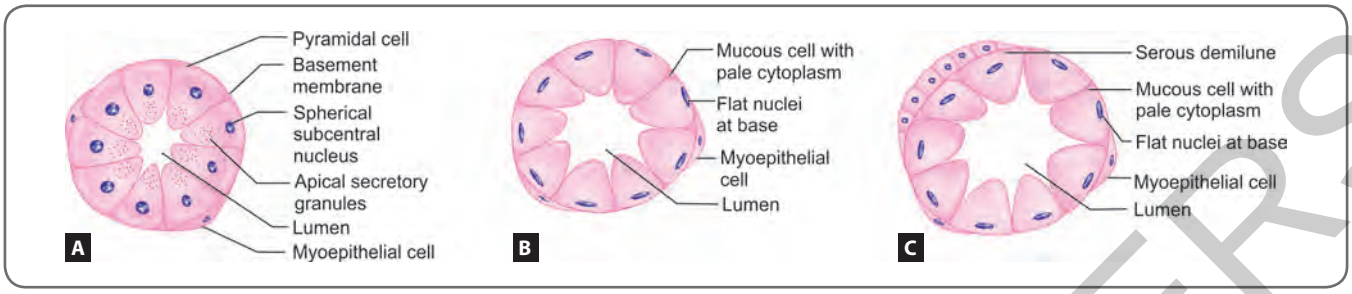

Figs 2.8A to C: Types of acini **A.** Serous; **B.** Mucous; **C.** Mixed

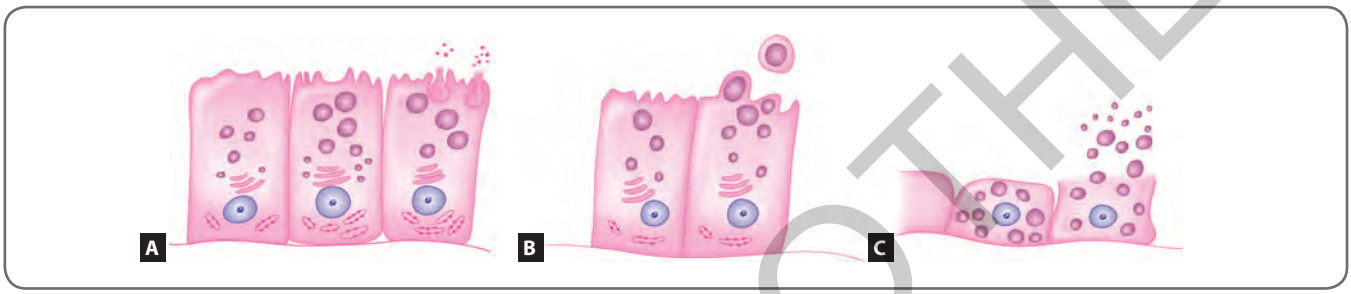

Figs 2.9A to C: Types of glands based on the manner in which their secretions are poured out of the cells **A.** Merocrine; **B.** Apocrine; **C.** Holocrine

Table 2.2: Comparison between serous and mucous acini

Serous acini	Mucous acini
Triangular cells with rounded nucleus at the base. Cell boundaries are indistinct	Tall cells with flat nucleus at the base. Cell boundaries are distinct
Contain zymogen granules	Contain mucoid material
Darkly stained with H and E (because of the presence of zymogen granules, the color varies from pink to dark purple)	Lightly stained and appear empty with H and E
Thin watery secretion	Thick mucoid secretion
Example: Parotid gland	Example: Sublingual gland

- ***Holocrine*** in which the cell (after accumulation of secretory product) dies and is expelled along with its contents (e.g. sebaceous gland) (Fig. 2.9C).

CONNECTIVE TISSUE

The connective tissue serves the function of connecting and supporting the different basic tissues and organs of the body. It is widely distributed in the body. The impaired structure and function of the connective tissue is the cause of some disorders of connective tissue. In inflammation of any organ it is the connective tissue that acts as a battle ground for the fight between the infecting agents and immune cells in the connective tissue (macrophages, plasma cells, white blood corpuscles, etc.).

Basic Components

The connective tissue consists of the following three basic components (Fig. 2.10):

1. Connective tissue cells (both resident and wandering).
2. Intercellular material (or ground substance or matrix).
3. Fibers (collagen, elastic and reticular).

Cells of Connective Tissue (Fig. 2.11)

Connective tissue contains different types of cells with a wide spectrum of functions. The cells of connective tissue are divisible into two categories:

1. ***Resident cells or fixed cells*** arise from mesenchymal stem cells. Examples of resident cells are—fibroblasts, myofibroblasts, adipocytes and persistent mesenchymal stem cells.

JAYPEE BROTHERS

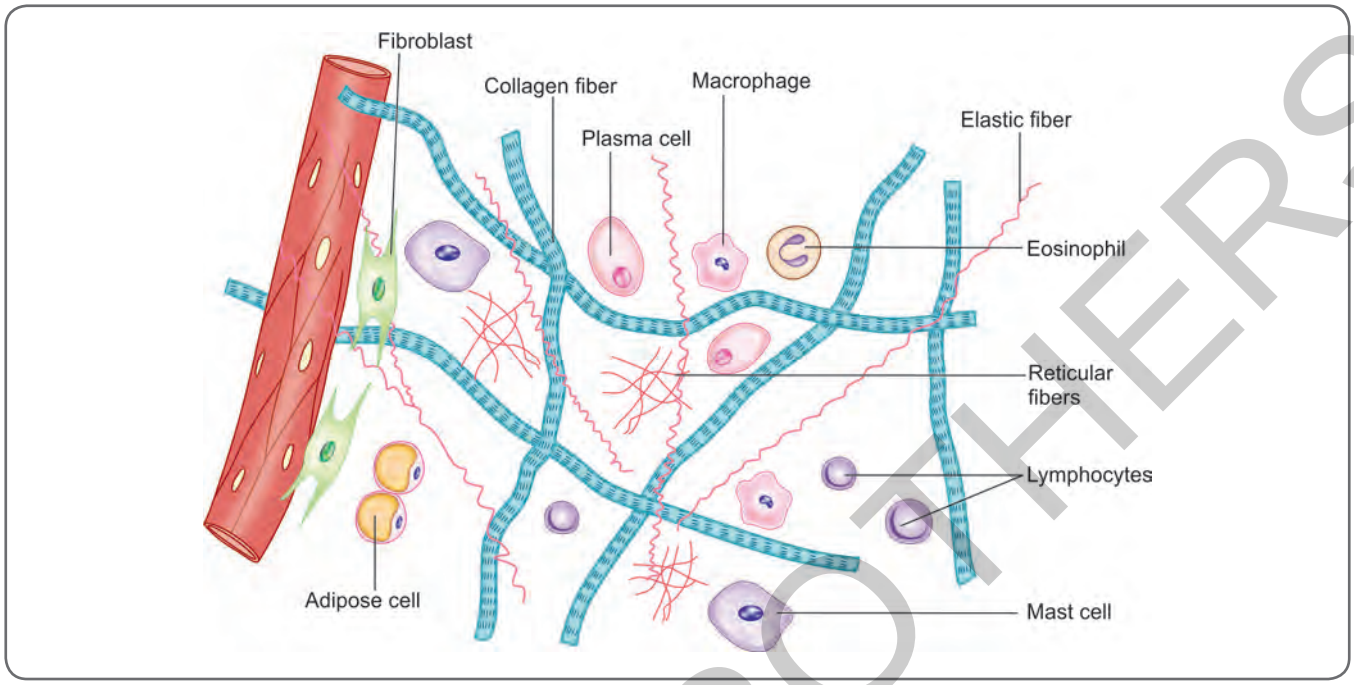

Fig. 2.10: Components of loose connective tissue

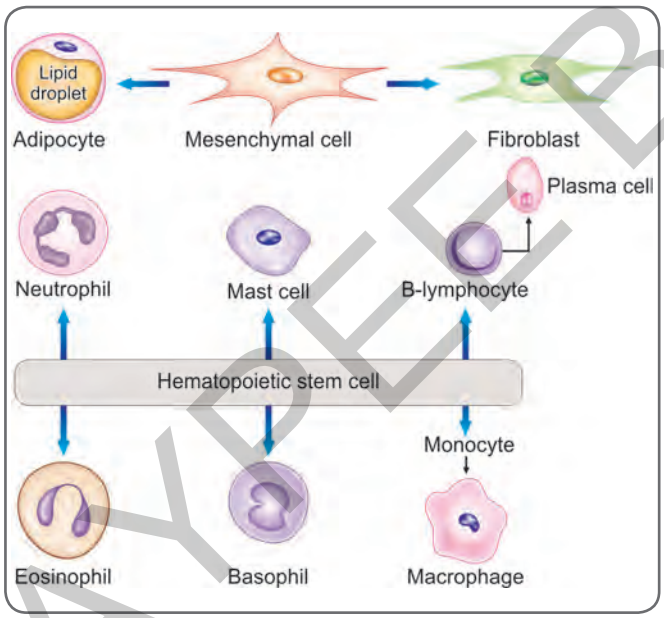

Fig. 2.11: Cells of connective tissue and their sources of origin

2. ***Transient or wandering cells*** arise from hemopoietic stem cells of bone marrow. Examples of transient cells are—macrophages, mast cells, plasma cells, monocytes, lymphocytes, eosinophils and neutrophils (from blood circulation) in addition to pigment cells or melanocytes derived from neural crest.

Resident cells

- ***Fibroblasts*** are the most common type of cells in connective tissue. They are stellate or spindle-shaped cells with little cytoplasm. They are metabolically very active as they synthesize the connective tissue fibers and the ground substance. The electron microscopic appearance of fibroblasts reveals characteristics of protein secreting cells, like well developed rough endoplasmic reticulum, one or more Golgi zones and abundant mitochondria. Most abundant protein in the body is collagen and it is produced by fibroblasts. The surfaces of active fibroblasts show characteristic scalloping (coves). It is here that collagen fibrils are polymerized to form collagen fibers in the extracellular compartment. Figure 2.9 illustrates the steps in the process of intracellular synthesis of procollagen and extracellular formation and assembly of collagen fibers from tropocollagen.
- ***Myofibroblasts*** are special type of fibroblasts that possess properties of both fibroblast and smooth muscle cell. The myofibroblasts play a significant role in wound contraction during the process of healing.

JAYPEE BROTHERS

- ***Adipocytes*** or ***lipocytes*** or ***fat cells*** are large in size (average size 50 microns). They store neutral fat (triglycerides) in the form of energy. Each cell contains a single lipid droplet in the cytoplasm. The lipid droplet is so large that it pushes the cytoplasm and the nucleus to the periphery. Thus, the cytoplasm is reduced to a rim containing cell organelles and a flattened nucleus. On routine staining the lipid droplet is dissolved. Therefore, the cell gives an empty appearance with a peripheral rim of stained cytoplasm containing a nucleus. This appearance is similar to the appearance of a signet ring.
- ***Persistent mesenchymal stem cells*** are capable of differentiating into fibroblasts, myofibroblasts and adipocytes of connective tissue.
- ***Pigment cells*** or ***melanocytes*** of connective tissue are found in dermis, choroid and iris of eyeball.

Migrant cells

- ***Mast cells*** are usually found in close relation to the blood capillaries. They are large in size. Their cytoplasm is filled with basophilic granules. The mast cell granules on staining, show metachromasia, i.e. they take up different color other than that of the color of the stain. For example, if stained with toluidine blue, the granules take up purple color. The granules contain histamine (vasoactive agent), heparin (anticoagulant) and eosinophilic chemotactic factor of anaphylaxis.
- ***Macrophages*** or ***histiocytes*** are part of the mononuclear phagocytic system (MPS) which develop from monocytes of the circulating blood. They are large cells with round nuclei and abundant acidophilic cytoplasm rich in lysosomes. They show irregular contours or ruffles of the plasma membrane. Their main function is phagocytosis by ingestion of foreign substances, cancer cells, worn out red blood cells, carbon particles in the lungs of heavy smokers, etc. Under pathological conditions several macrophages group around a large foreign body and may fuse together to form a multinuclear giant cell.
- ***Plasma cells*** or ***plasmatocytes*** are derived from B lymphocytes. They are responsible for production of antibodies (immunoglobulins) produced in response to penetration by antigens. The antibodies are generally released into the blood circulation but may be stored temporarily in the cytoplasm of the plasma cells as Russell bodies. The plasma cell is rounded with eccentrically placed nucleus which shows characteristic cart wheel or clock face appearance. This is due to radiating distribution of darkly stained heterochromatin (coiled inactive chromatin) alternating with empty spaces representing euchromatin (uncoiled active chromatin) in the periphery of the nucleus. The cytoplasm of plasma cells is highly basophilic due to abundant rough endoplasmic reticulum. The Golgi body appears pale on routine histological staining. This pale appearance is described as perinuclear halo or Golgi ghost or negative image of Golgi.
- ***White blood cells*** or ***leukocytes*** (B lymphocytes, T lymphocytes, neutrophils, basophils, eosinophils and monocytes) migrate to the connective tissue from blood capillaries by a process of diapedesis. They are found in large numbers during inflammation when they actively destroy the pathogens.

STUDENT INTEREST

Every student must know the three basic components of connective tissue (cells, fibers and matrix or ground substance). The structure and function of each cell of the connective tissue is a must know topic. Learn by drawing diagrams. Physical and chemical characters of three types of fibers (collagen, elastic and reticular) must be studied. Pay attention to the role of fibroblast in producing collagen and collagen fibers.

Intercellular material (Ground substance)

The connective tissue is composed of abundant ground substance. The connective tissue cells and fibers are embedded into it. The ground substance is amorphous and transparent. On light microscopy it is difficult to visualize the ground substance.

Chemically the ground substance is composed mainly of mucopolysaccharides or glycosaminoglycans (GAG) like hyaluronic acid, proteoglycans, etc. and structural glycoproteins or multiadhesive glycoproteins (like fibronectin, laminin, chondronectin, etc.).

The ground substance allows free exchange of nutrients and gases between the cells of the tissues and blood in the capillaries. Water or tissue fluid might accumulate in the ground substance in case of venous stasis or of lymphatic stasis causing edema.

Connective Tissue Fibers

The connective tissue fibers are of three types—collagen, elastic and reticular (Figs 2.12A to C).

Collagen Fibers

The collagen fibers are the white fibers of connective tissue. They are composed of the collagen, which is the most abundant structural protein in the body. They provide

JAYPEE BROTHERS

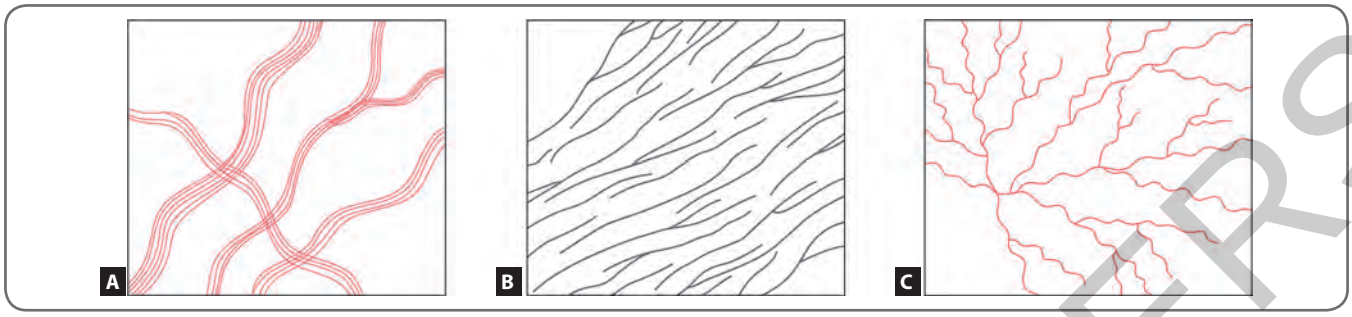

Figs 2.12A to C: Fibers of connective tissue **A.** Collagen fibers; **B.** Reticular fibers; **C.** Elastic fibers

tensile strength to the tissues. Their strength is comparable to that of steel cables. The collagen fibers aggregate into wavy bundles, which may branch. However, the individual fibers do not branch. They exhibit birefringence, which means when polarized light is thrown on the fibers the light is split into two beams that are refracted in two directions. The collagen fibers are secreted not only by fibroblasts but also by chondroblasts in cartilage, osteoblasts in bone and odontoblasts in teeth. The collagen fibers are visible on light microscopy. They appear pink on staining with eosin. However, the collagen fibrils (which make up the fibers) are visible only by electron microscopy.

ADDED INFORMATION

Biosynthesis and Secretion of Collagen (Fig. 2.13)

The collagen is secreted by fibroblasts in connective tissue, by osteoblasts in bone, by chondroblasts in cartilage and by odontoblasts in tooth. The collagen is also secreted by non connective tissue cells like smooth muscle cells, Schwann cells and epithelial cells.

Intracellular Synthesis of Procollagen

- The proline, glycine and lysine form the alpha polypeptide chains, which reach the rough endoplasmic reticulum. Here the lysine and proline are hydroxylated for which vitamin C is an essential cofactor. The deficiency of vitamin C (scurvy) with resultant defective collagen leads to widespread effects like bleeding gums, loose teeth, weak bones and poor wound healing.
- The polypeptide chains coil around each other to form a triple helix except at the terminals where the chain remains uncoiled. This forms the soluble procollagen molecules.
- The packaging of procollagen molecules takes place in Golgi apparatus for transportation out of the cells.

Extracellular Synthesis of Collagen (Fig. 2.13)

- The soluble procollagen is converted into nonsoluble tropocollagen by cutting the uncoiled terminals.
- The tropocollagen molecules aggregate to form collagen fibrils, which are polymerized into collagen fibers on the surface coves.

CLINICAL CORRELATION

Genetic Disorders of Collagen Synthesis

Defective collagen encoding genes cause autoimmune disorders in which immune responses destroy the collagen fibers. Examples of autoimmune disorders are rheumatoid arthritis and osteogenesis imperfecta.

Types of collagen fibers

There are numerous types of collagen fibers that differ from each other genetically, immunologically and chemically. They are designated by Roman numerals according to their order of discovery. Type I, type II, type III and type IV fibers are very commonly seen. Type I fibers are found in fascia, tendons, ligaments, aponeuroses, capsules of glands, sclera, fibrocartilage, bone and dentin. Type II fibers are found in hyaline and elastic cartilages and cornea. Type III fibers are the reticular fibers which occur in spleen, lymph nodes etc. Type IV fibers are seen in basement membranes.

Elastic Fibers

The elastic fibers impart elasticity to the tissues. They are composed of an amorphous core of elastin surrounded by a glycoprotein named fibrillin. Unlike collagen fibers they do not form bundles. The individual fibers branch and anastomose. They are highly refractile when unstained and are yellow in color when fresh. The elastic fibers can be stretched like a rubber band. Relaxed elastic fibers do not show birefringence but stretched fibers are highly birefringent. They stain poorly with hematoxylin and eosin stains. They are produced by fibroblasts, epithelial cells and smooth muscle cells. The elastic fibers occur in loose areolar tissue, ligaments of joints, ligamenta flava, and ligamentum nuchae, dermis, and lung, and elastic cartilage, suspensory ligament of lens and as fenestrated membranes in elastic arteries.

JAYPEE BROTHERS

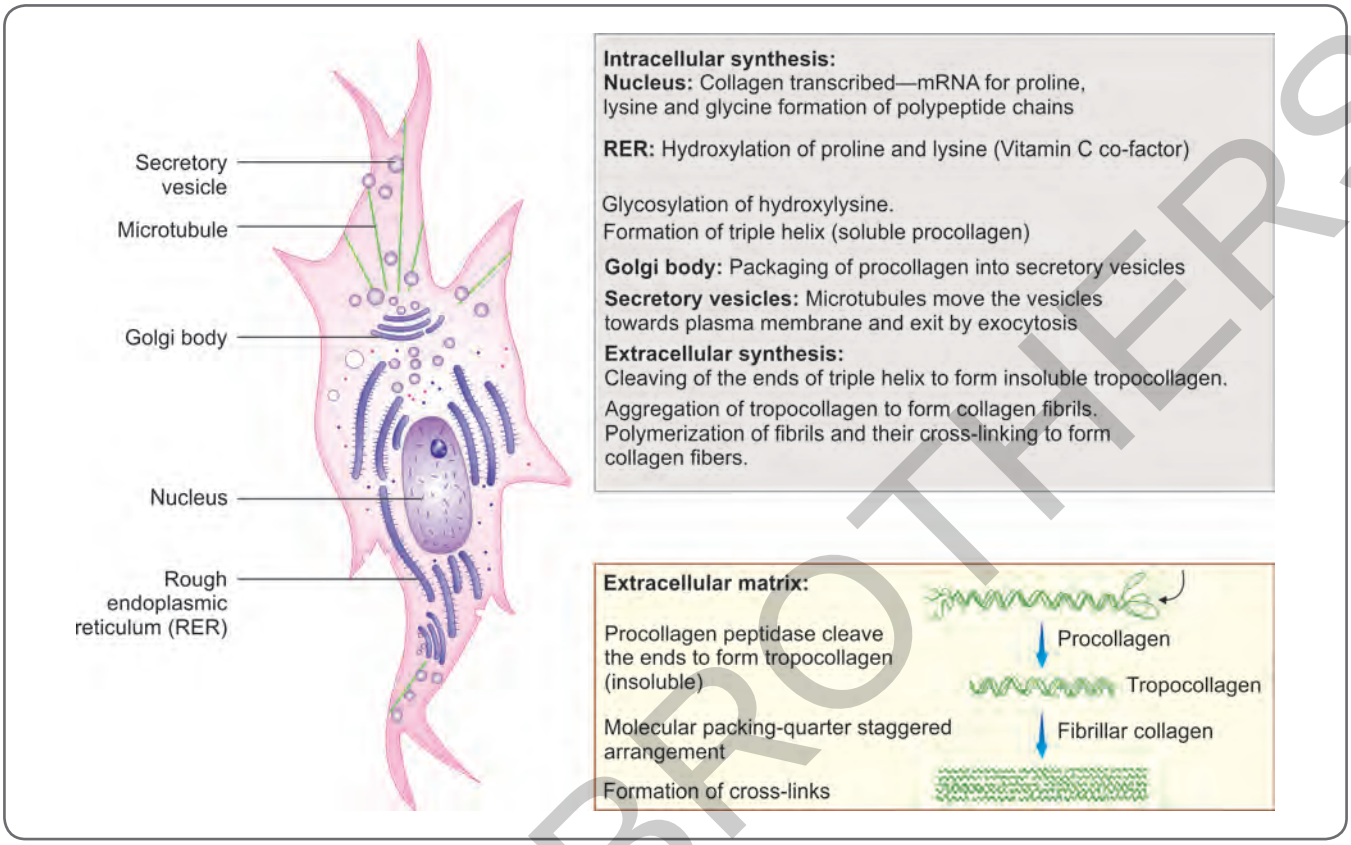

Fig. 2.13: Illustrates the steps in intracellular and extracellular synthesis of collagen by fibroblast

CLINICAL CORRELATION

Marfan's Syndrome

Marfan's syndrome results due to gene mutation causing defect in the production of elastic fibers (due to defective formation of fibrillin). The structures that are rich in elastic fibers (tunica media of aorta, suspensory ligaments of the lens in eyeball, periosteum and ligaments of the joints) are affected in Marfan's syndrome. The patients are liable to develop aortic aneurysm, lens dislocation, abnormally long limb bones and highly flexible joints.

Reticular Fibers

The reticular fibers are very thin and delicate type III collagen fibers. They are mainly produced by fibroblast but other cells like reticular cells in bone marrow and lymphoid tissues, smooth muscle cells and Schwann cells are also capable of producing them. The reticular fibers give support to the nerve fibers, muscle fibers, blood vessels and form stroma in the glands. The reticular fibers branch and anastomose to form a network or reticulum. They appear black when stained by silver stains. They are called ***argyrophilic fibers*** due to their affinity for silver stains. The reticular fibers provide supporting network in spleen, lymph nodes, thymus, bone marrow, endocrine and exocrine glands and liver. They are an integral part of the reticular lamina of basement membranes.

Classification of Connective Tissue Proper

- Loose or areolar connective tissue
- Dense connective tissue
- Yellow elastic tissue
- Reticular connective tissue
- Adipose tissue
- Myxomatous connective tissue (embryonic connective tissue).

Loose Connective Tissue

The loose connective tissue is rich in ground substance and poor in fibers and connective tissue cells. It is the most abundant connective as it forms the stroma of the organs and tunica adventitia of blood vessels. It lies underneath the epithelia forming lamina propria of mucous membranes and in submucosa of hollow organs.

JAYPEE BROTHERS

Dense Connective Tissue

This type is composed predominantly of collagen fibers hence also called ***white fibrous tissue***. It is subdivided into two types, dense irregular and dense regular.

1. The dense irregular connective tissue (Fig. 2.14A) is characterized by collagen and elastic fibers (running in irregular orientation), few cells and moderate amount of ground substance. It is found in reticular layer of dermis, periosteum and perichondrium.
2. The dense regular connective tissue (Fig. 2.14B) is characterized by densely arranged fibers, fewer cells (mostly fibroblasts) and minimum ground substance. The collagen fibers are regularly oriented and are arranged in bundles. The regular dense connective tissue is found in tendons, ligaments, capsules, fasciae and aponeuroses. The tendons attach the muscle belly to the bone or cartilage. A tendon consists of parallel collagen fibers and fibroblasts. A longitudinal section of tendon consists of bundles of collagen fibers and parallel rows of elongated nuclei of fibroblasts that are compressed between collagen fibers.

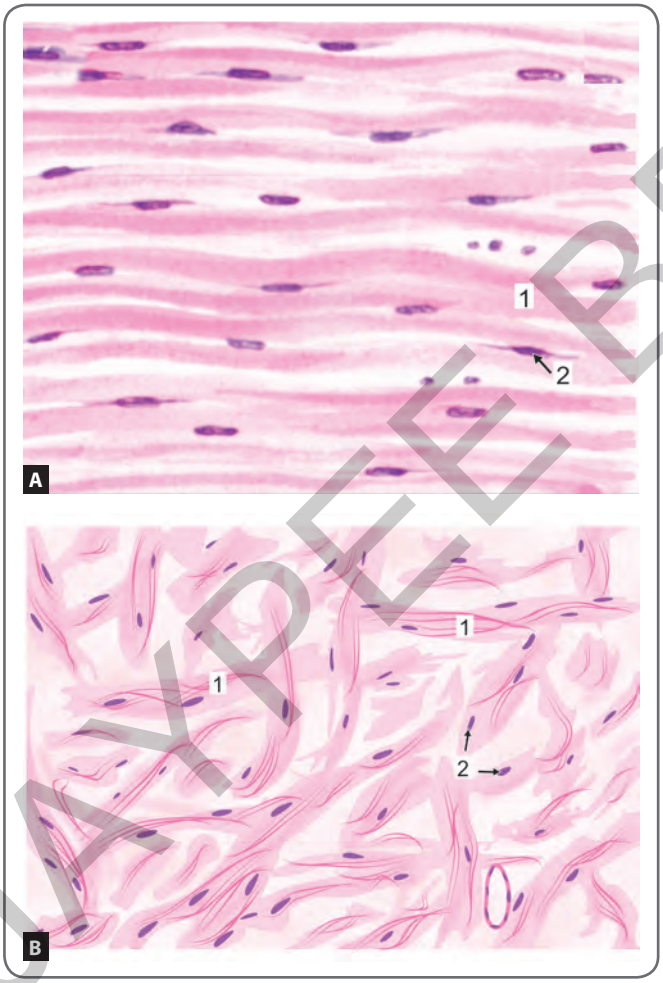

Figs 2.14A and B: Microscopic structure of **A.** Dense regular collagenous connective tissue (tendon); **B.** Dense irregular connective tissue (dermis of skin) **Key: 1.** Collagenous fibers **2.** Nuclei of fibroblast

Yellow Elastic Tissue

This type is composed predominantly of elastic fibers. The elastic tissue is found in ligamenta flava (which connect the laminae of adjacent vertebrae), cricovocal membrane of laryngeal skeleton, vocal ligaments, lung alveoli and in tunica media of the aorta.

Reticular Connective Tissue

The reticular tissue is a network of reticular fibers and reticular cells (subtype of fibroblasts). It provides a soft structural framework to support the cells of lymph nodes, spleen and bone marrow.

Adipose Tissue

The adipose or fatty tissue contains a collection of fat cells or adipocytes (Fig. 2.15). It provides warmth, cushioning effect and is also store house of energy reserve of the body. The adipose tissue is of two types. The white adipose tissue is found in adult and the brown adipose tissue is found in fetus and newborn.

1. ***White adipose cells*** (white adipocytes) are larger in size and are called ***unilocular*** because their cytoplasm is filled by a single large lipid droplet. The cell nucleus is flat and pushed by the lipid droplet to the periphery. The mitochondria are few in number and are dispersed in the peripheral rim of cytoplasm. The white fat is widely distributed in the subcutaneous tissue in the body in adults. In addition, it is found in yellow bone marrow and in abdominal cavity inside the peritoneal folds and around kidneys. It functions as store house of energy.

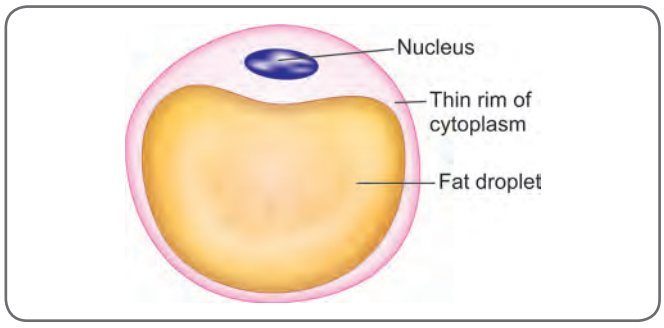

Fig. 2.15: Fat cell

JAYPEE BROTHERS

2. ***Brown adipose cells*** (brown adipocytes) are small polygonal cells and are called ***multilocular*** because their cytoplasm is filled with multiple lipid droplets. The nucleus is in the cell center and cell organelles are spread out in the cytoplasm. There are numerous mitochondria, which contain large quantity of iron-containing pigments cytochromes (which impart brown color to adipocytes). The brown adipose tissue is more widely distributed in fetuses and newborn. In adult it is seen in the interscapular region and in the lumbar region behind the kidneys.

Myxomatous (Mucoid) Connective Tissue (Fig. 2.16)

This tissue is characterized by abundant ground substance, few cells and fewer fibers. In the fetus, it occurs as Wharton's jelly in the umbilical cord. The jelly like viscous ground substance is rich in hyaluronic acid. The fibers are hardly visible and fibroblasts assume star-shape, hence called ***stellate cells***. The Wharton's jelly develops from extraembryonic mesoderm (primary mesoderm). In the adult, it is found in vitreous humor of eyeball.

MUSCULAR TISSUE

The muscular tissue is composed of elongated muscle cells called ***myocytes*** or ***muscle fibers***. The muscle fibers are the basic units of the muscle. They aggregate to form a muscle. The main function of the muscle is contraction for performing mechanical work like locomotion, movements of hand, facial expressions, pumping action of heart and peristaltic movement of intestines to name a few. The muscle fibers are equipped in their cytoplasm with contractile proteins called ***actin*** and ***myosin***. These proteins are filamentous in nature and hence are called ***myofilaments***.

Types of Muscle Tissue

There are three types of muscular tissue in the body that differ in distribution, microscopic structure and function:

1. Skeletal muscle
2. Cardiac muscle
3. Smooth muscle

ADDED INFORMATION

There are other contractile cells in the body not belonging to muscular tissue but having actin and myosin filaments. They are myoepithelial cells, myofibroblasts and pericytes. The myoepithelial cells are found around the secretory units in salivary glands, mammary glands and sweat glands. The myofibroblasts are modified fibroblasts involved in wound healing. The pericytes are small fusiform cells around the capillaries and venules. They have the potential to differentiate into myofibroblasts and fibroblasts and can give rise to new blood vessels.

Skeletal Muscle

The skeletal muscles are so called because by and large they attach to the bones and cartilages. They are also known as striated because their cells show cross striations when examined under light microscope (Fig. 2.17). They

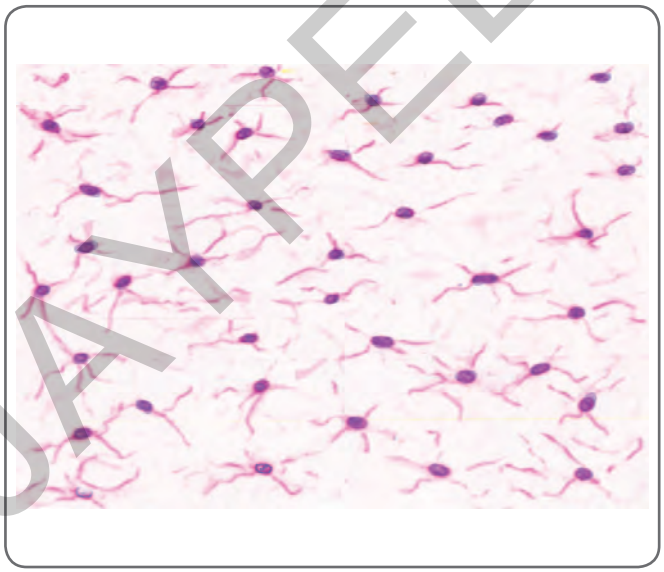

Fig. 2.16: Microscopic structure of mucoid tissue

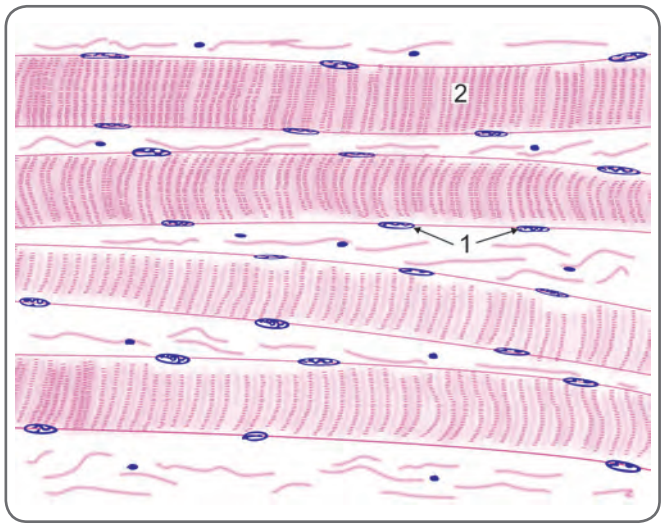

Fig. 2.17: Microscopic structure of skeletal muscle seen in longitudinal section **Key: 1.** Peripherally placed nuclei; **2.** Muscle fibers with transverse striations

JAYPEE BROTHERS

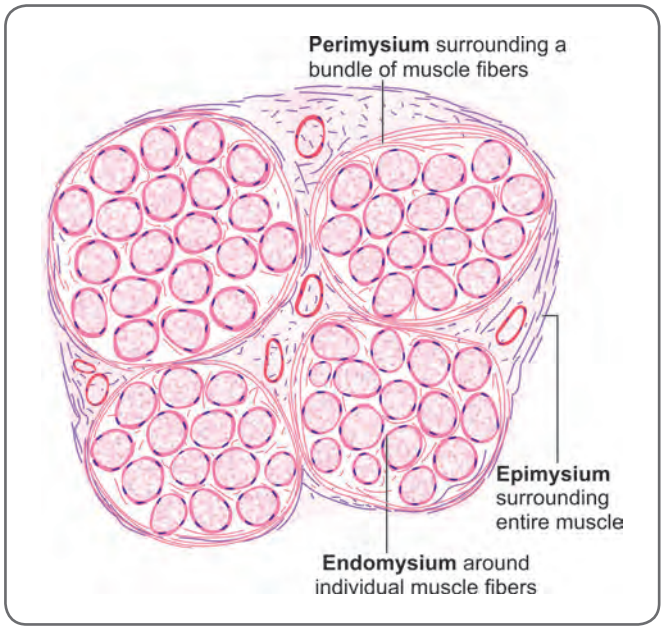

Fig. 2.18: Microscopic structure of connective tissue present in relation to skeletal muscle

are described as voluntary muscle as they contract under the influence of motor neurons of somatic nervous system and are supplied by axons of lower motor neurons (like neurons of ventral horn of spinal grey matter).

Organization of connective tissue framework in a skeletal muscle

The muscle fibers and their bundles are supported by a well defined connective tissue framework, which provides routes for the nerves and blood vessels to reach the individual muscle fiber (Fig. 2.18).

- Endomysium is a delicate connective tissue covering of each muscle fiber.
- Perimysium covers the muscle bundles or fascicles containing aggregations of muscle fibers.
- Epimysium is the common outer connective tissue covering of the all the muscle bundles.

Histology of Muscle Fiber (Fig. 2.19)

The muscle fiber is an elongated multinucleate syncytium. Its cytoplasm is called ***sarcoplasm*** and plasma membrane is called ***sarcolemma***. The flattened nuclei are placed at the periphery and in a row parallel to the sarcolemma (Fig. 2.17). The sarcoplasm is filled with structural and functional subunits of muscle fibers called ***myofibrils***, which are composed of bundles of thin actin and thick myosin filaments (the contractile proteins). The myofibrils are surrounded by special type of smooth endoplasmic reticulum (called ***sarcoplasmic reticulum***) and the sarcoplasm contains mitochondria, glycogen and myoglobin (a red colored oxygen binding protein).

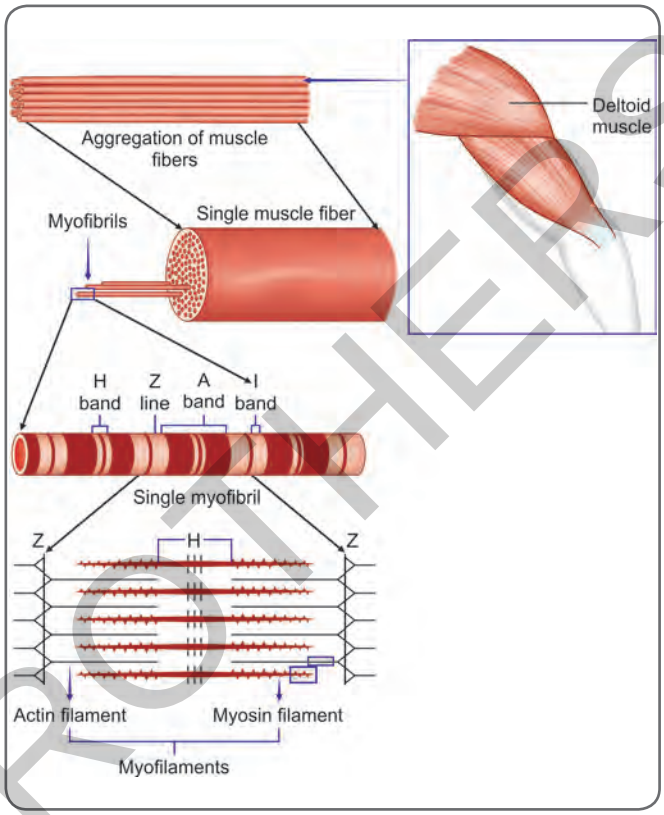

Fig. 2.19: Structure of skeletal muscle from gross to light microscopic and to ultramicroscopic levels at a glance

Cross striations

The characteristic cross striations of muscle fibers are due to presence of alternating light and dark bands (composed of above mentioned contractile proteins) arranged in regular pattern on the myofibrils. The dark bands are A (anisotropic) bands and the light bands are I (isotropic) bands. A bands show light area in the middle called ***H band***, which is bisected by a transverse dark line called ***M line***. I band is bisected by a thin dark line called ***Z line***. A sarcomere is the segment of a myofibril between consecutive Z lines. It is the basic contractile unit of the striated muscle (Fig. 2.19).

Student Interest

The skeletal muscle fiber is a single elongated multinucleate cell. It has very interesting features. It is covered by sarcolemma and its cytoplasm is called ***sarcoplasm***, which contains several flattened nuclei (lying under the sarcolemma), sarcoplasmic reticulum, mitochondria, myoglobin, glycogen, etc. The myofibrils are the thread like contractile structures that fill the sarcoplasm. The dark or A bands and light or I bands of the myofibrils are in register. This is the reason why the muscle fiber appears striated. The light band is bisected by a dark line called ***Z line*** and dark band is bisected by a lighter H-band.

Contd…

JAYPEE BROTHERS

Contd…

STUDENT INTEREST

The segment of the myofibril between two consecutive Z lines is called ***sarcomere***, which is the basic contractile unit of striated muscle. On election microscope (EM) examination each myofibril is composed of actin and myosin filaments (which are called ***myofilaments***) Actin and myosin are contractile proteins. Learn to draw a sarcomere. Easy trick to remember which band is A and which band is I: A is dark band (second letter in 'dark' is A and I is light band (second letter in 'light' is I).

Muscle triad

The electron microscope (EM) appearance of muscle fiber reveals that at A-I junctions of each myofibril there is a triad consisting of invaginated sarcolemma (T tubule) flanked on upper and lower sides by terminal cisternae of sarcoplasmic reticulum.

Functions of muscle triad

- T tubules carry the signals of depolarization from the surface sarcolemma into the deeper part of muscle fibers so that deeper and superficial myofibrils contract synchronously.
- T tubules transmit the wave of depolarization to membranes of terminal cisternae at triads. This triggers the release of calcium ions from the sarcoplasmic reticulum into the sarcoplasm. The calcium ions act on actin and myosin filaments causing contraction of muscle. When the contraction ceases, the released calcium is taken back inside the sarcoplasmic reticulum.

Nerve supply of skeletal muscle and motor unit

The nerve and the accompanying blood vessels supplying the skeletal muscle enter the muscle at a specific point called ***neurovascular hilum***. For example, thoracodorsal nerve and thoracodorsal artery enter the neurovascular hilum on the latissimus dorsi muscle. The thoracodorsal nerve contains axons of anterior horn cells of C6, C7 and C8 segments of spinal cord, which supply the muscle fibers of latissimus dorsi via their numerous branches that pass through epimysium, perimysium and endomysium to reach the respective muscle fiber. From this we understand that one axon of anterior horn cell supplies several muscle fibers. One motor neuron and the muscle fibers supplied by it constitute one motor unit. The number of muscle fibers is smaller in motor units of muscles which are involved in fine and precise movements (for example in extraocular muscles, the ratio of motor neuron to muscle fiber is 1:4 to 10). Conversely, the number of muscle fibers is very large in motor units of muscles like latissimus dorsi and gastrocnemius, where force of contraction rather than precision is necessary.

ADDED INFORMATION

Additional Features of Skeletal Muscles

- The arrangement of muscle fibers may be different according to the functional needs.
  The pennate (comb-like) muscles are characterized by muscle fascicles that are disposed at an oblique angle to the line of contraction of the muscle. There are three types of pennate muscles.
  1. In ***unipennate muscle***, the tendon (or bone) lies on one side and muscle fibers run obliquely from it (extensor digitorum longus, flexor pollicis longus, lateral two lumbricals and palmar interossei).
  2. In ***bipennate muscle***, the tendon (or bone) lies in the center and muscle fibers reach it from either side obliquely (rectus femoris, soleus, medial two lumbricals and dorsal interossei).
  3. In ***multipennate muscle***, there are numerous tendinous septa that receive fibers from various directions as in acromial fibers of deltoid and in subscapularis.
- Two types of muscle contraction (depending on movement of joint):
  1. In ***isometric contraction*** there is no movement of a joint but there is increase in the tone of muscle. On lifting a heavy suitcase the flexor muscles contract without moving the elbow joint.
  2. In ***isotonic contraction*** the same muscles shorten to hold a baby.
- Depending on the actions of the muscles they are divided into following types:
  - Prime mover is the main muscle that performs a particular action, for example, in flexed forearm the biceps brachii is the main supinator and in extended forearm the supinator muscle is the main supinator.
  - Fixator is the muscle that contracts isometrically to stabilize the prime mover. The examples of fixator muscles are quadratus lumborum (which fixes the 12th rib during inspiration facilitating contraction of diaphragm) and rhomboid muscles fixing the scapula during overhead abduction of arm.
  - Antagonist is the term used for a muscle that opposes the action of a prime mover as exemplified by contraction of triceps brachii (the extensor of elbow) during flexion movement of that joint.
  - Synergist is the term used for a muscle, which helps other muscle (prime mover) in performing its stipulated action. The flexors and extensors of carpus (flexor carpi radialis and extensor carpi radialis) and extensor carpi radialis longus and brevis and extensor carpi ulnaris) contract simultaneously to stabilize the wrist joint when long flexor or extensor muscles of the digits contract.

JAYPEE BROTHERS

r detailed information on anatomy books, visit our website www.jaypeebrothers.com, for detailed information on anatomy books, visit our webs

Clinical Anatomy

(A Problem Solving Approach)

Key Features

- Volume 2 consists of three sections Abdomen, Pelvis & Perineum, Head & Neck, Vertebral Column & Spinal Cord, Cranial Cavity & Brain and Cranial Nerves.
- Content is designed to provide exposure on day-to-day applications of anatomy in clinical settings and analyses.
- Clinical correlations, embryologic insights, added information and student interest displayed in boxes.
- Profusely expressed clinical diagrams, line diagrams, photographs have been incorporated to boost the quality of learning and understanding.
- The information is maintained upto recent clinical advances, and language is kept simple and enjoyable.
- Sections are accompanied with clinicoanatomical problems and solutions consist of case histories followed by multiple-choice questions and answers with rationales.
- Beneficial to one and all involved in providing health care.



Neeta V Kulkarni graduated from Government Medical College, Nagpur and has completed her post-graduation in Anatomy from Government Medical College, Thiruvananthapuram, Kerala, India. She began her career in Anatomy under the Government of Kerala and worked in various Medical Colleges in the State of Kerala until her retirement from Medical College, Thiruvananthapuram. Post-retirement, she was actively involved in setting up the Anatomy department including Anatomy museum at Dr SMCSI Medical College, Karakonam, Thiruvananthapuram, Kerala, India. She has worked in the capacity of Professor and Head of Anatomy and as Vice Principal in the same college until 2007 and continued to be the senior Professor of Anatomy until May 2012. She is the lifetime member of ASI and ISHG and was the member of National Advisory Board of Journal of Anatomical Society of India. The first edition of her book, *Clinical Anatomy for Students—Problem Solving Approach* was published by Jaypee Brothers Medical Publishers in 2006. The second edition of *Clinical Anatomy—A Problem Solving Approach* was also published by the same publishers in 2011. Currently the author is residing at Pune, Maharashtra.

Printed in India

Available at all medical bookstores or buy online at www.ejaypee.com

JAYPEE BROTHERS
Medical Publishers (P) Ltd.
EMCA House, 23/23-B, Ansari Road,
Daryaganj, New Delhi - 110 002, INDIA
www.jaypeebrothers.com

Join us on facebook.com/JaypeeMedicalPublishers
Follow us on instagram.com/JaypeeMedicalPublishers

ISBN 978-93-5152-966-8
9 789351 529668