ebrothers.com, for detailed information on surgery books, visit our website www.jaypeebrothers.com, for detailed information on surgery book

A Practical Approach to Vascular & Endovascular Surgery

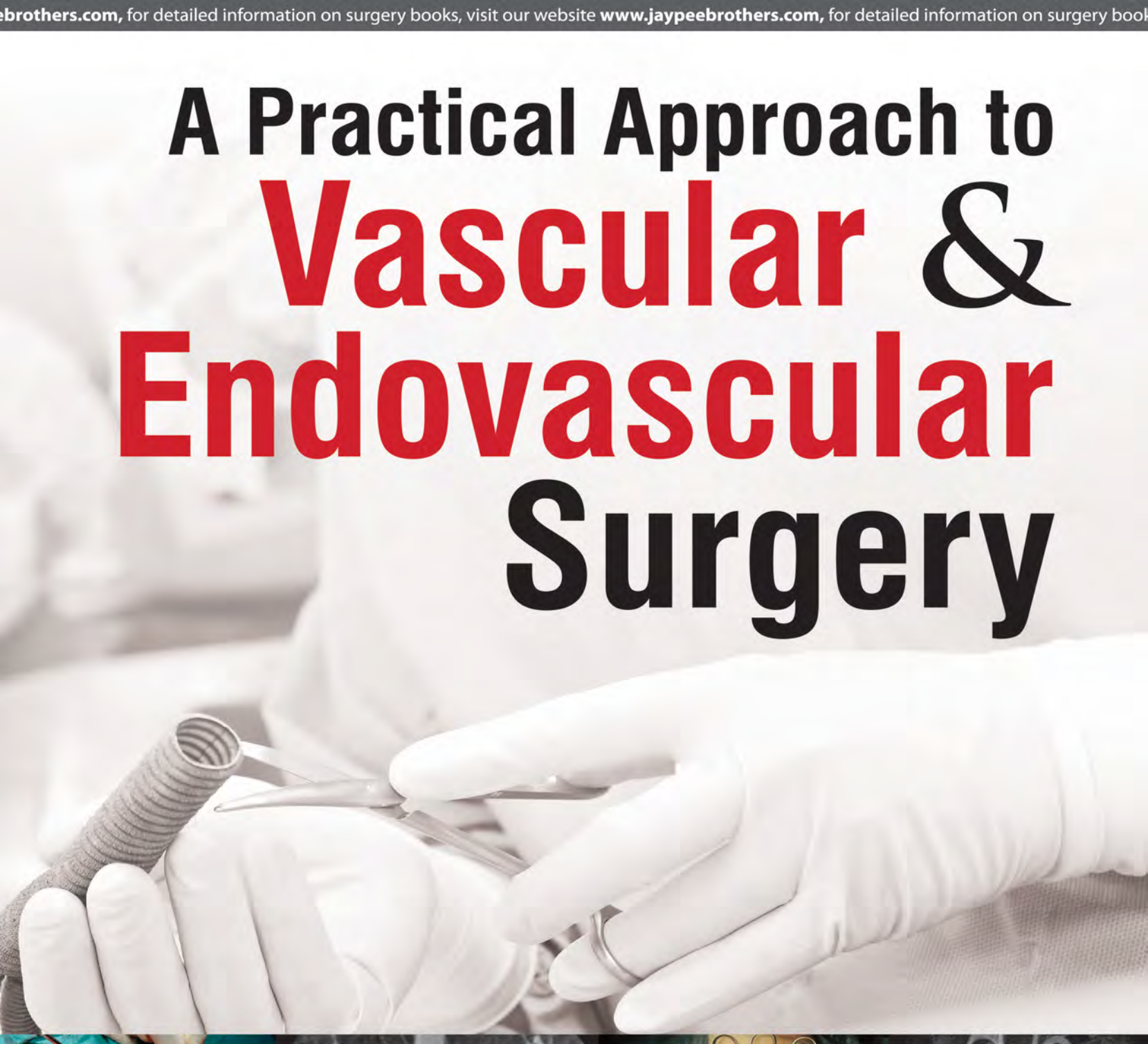

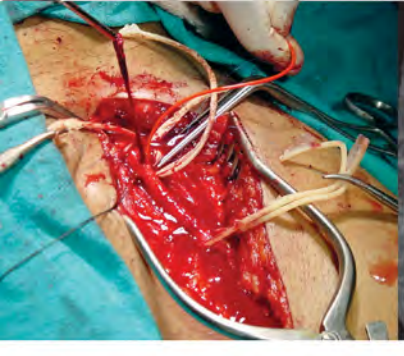
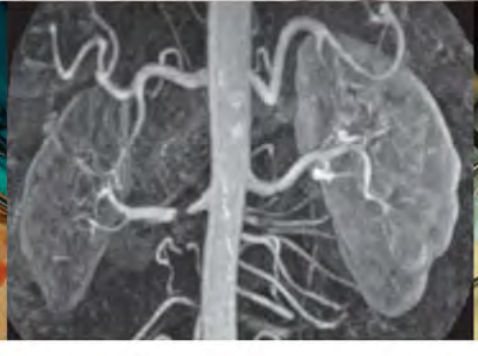

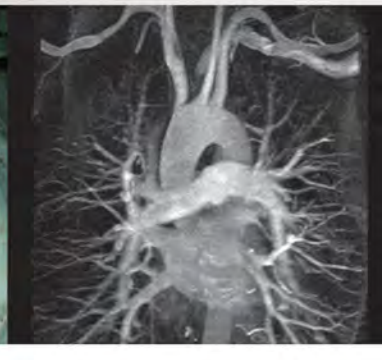

Jaisom Chopra
VS Bedi

Foreword
John HN Wolfe

JAYPEE

Contents

1. History and Examination of the Arterial System 1
Jaisom Chopra

Vascular History 1 • Presenting Complaints 1 • Mode of Onset of Illness 3 • Physical Examination of the Arterial System 4 • Assessing the Outcomes and Improvements in Arterial Disease 8

2. Noninvasive Vascular Imaging for Vascular Disease 10
Jaisom Chopra

Basis of Vascular Ultrasound 10 • Common Uses of the Procedure 10 • Diagnostic Evaluation of Lower Extremity Arterial Disease 12 • Ankle-Brachial Index 13 • Exercise Ankle-Brachial Index 14 • Segmental Leg Pressures 14 • Pulse Volume Recording 14 • Doppler Velocity Waveform Analysis 15 • Duplex Arterial Ultrasound 15 • Computed Tomographic Angiography 17 • Magnetic Resonance Angiography 19 • Noninvasive Evaluation of Extracranial Carotid Artery Disease 20 • Noninvasive Evaluation of Renal Artery Stenosis 21 • Evaluation of Aortic Aneurysmal Disease 21

3. Diagnostic Catheter-based Vascular Angiography 25
Jaisom Chopra

Anatomic Considerations 25 • Fundamentals 27 • Clinical Aspects of Angiography 27 • Limitations/Risks 30 • Special Issues/Consideration 33

4. Magnetic Resonance Angiography in the Diagnosis of Vascular Disease 35
Jaisom Chopra

Clinical Applications 35 • Limitations 38 • Special Issues 38

5. Approach to Management of Intermittent Claudication 40
Jaisom Chopra

Clinical Features 40 • Diagnosis 41 • Management 43 • Surgical Treatment of Infra-inguinal Disease 51

6. Management of Acute Limb Ischemia 53
Jaisom Chopra

Pathophysiology 53 • Diagnosis 54 • Management 54 • Occluded Graft 57 • Reperfusion Injury 58

7. Management of Chronic Critical Limb Ischemia 62
Jaisom Chopra

Clinical Features 62 • Diagnostic Evaluation 63 • Management 65

8. Buerger's Disease (Thromboangiitis Obliterans) 73
Jaisom Chopra

Epidemiology 73 • Etiology 73 • Clinical Presentation 74 • Clinical Course 74 • Diagnosis 74 • General Treatment 74 • Prevention 75 • Medical Therapy 75 • Surgical Therapy 76

9. Aortic Dissections 77
VS Bedi, Anand Chandrasekar, Ajay Yadav, Ambarish Satwik, Kamran Ali Khan

Classification 77 • Incidence and Risk Factors for Developing Aortic Dissection 78 • Pathogenesis 78 • Malperfusion Syndrome 78 • Clinical Features 78 • Differential Diagnosis 79 • Diagnostic Evaluation 80 • Treatment 81 • Thoracic Endovascular Aortic Repair 84

10. Renovascular Hypertension 89
VS Bedi, Ajay Yadav, Ambarish Satwik, Kamran Ali Khan

Background 89 • Epidemiology 89 • Etiology 89 • Pathophysiology 90 • Complications 90 • Clinical Features 90 • Diagnostic Tests 91 • Management 92 • Prognosis 94

11. Management of Abdominal Aortic Aneurysms 96
Jaisom Chopra

Risk Factors 96 • Pathogenesis 97 • Etiology 97 • Clinical Features 97 • Diagnosis 99 • Management 101 • Prognosis and Follow-up 104

12. Thoracic Aortic Aneurysm 106
VS Bedi, Anand Chandrasekar, Ajay Yadav, Ambarish Satwik, Kamran Ali Khan

Mean Aortic Diameters in Male and Female 106 • Pathology 107 • Incidence and Prevalence 107 • Etiology 107 • Anatomical Classification 109 • Clinical Features and Synchronous Aneurysmal Risk 109 • Diagnostic Evaluation 110 • Management 111 • Complications 115 • Endovascular and Its Results 116

13. Approach to the Management of Mesenteric Vascular Disease 124
Jaisom Chopra

Clinical Anatomy 124 • Clinical Features and Diagnosis 125 • Management 128 • Special Issues 129

14. Approach to the Patient with Upper Extremity Arterial Disease 132
Jaisom Chopra

Problems 132 • Anatomy and Physiology of Upper Extremity Circulation 132 • History and Physical Examination 134 • Diagnostic Testing 135 • Implications of Testing for Upper Extremity Disease 137

15. Large Arteries of Upper Limb: Innominate, Subclavian and Axillary 138
Jaisom Chopra

Clinical Features 138 • Diagnosis 140 • Management 141

16. Vasospastic Disorders and Miscellaneous Disorders of the Extremities 144
Jaisom Chopra

Raynaud's Phenomenon 144 • Complex Regional Pain Syndrome 148 • Erythermalgia 149 • Acrocyanosis 150 • Pernio (Chilblains) 150

17. History, Physical Examination and Diagnostic Approach to Venous Disorders 151
Jaisom Chopra

Clinical Features 152 • Differential Diagnosis 156 • Diagnostic Evaluation and Approach 156

18. Approach to the Management of Varicose Veins 161
Jaisom Chopra

Clinical Features 162 • Diagnosis 163 • Treatment 164

19. Venous Thromboembolism 170
Jaisom Chopra

Clinical Features 171 • Diagnosis 172 • Management of Patients with Acute Venous Thrombosis 174 • Special Issues 179

20. Approach to the Management of Chronic Venous Insufficiency 181
Jaisom Chopra

Clinical Features 181 • Diagnosis 183 • Management 185

21. Upper Extremity Deep Vein Thrombosis and Superior Vena Cava Thrombosis 192
Jaisom Chopra

Classification of Upper Extremity Deep Vein Thrombosis 192 • Clinical Features 193 • Management of Patient 194 • Special Issues 195 • Superior Vena Cava Thrombosis 195

22. Management of Vasculogenic Impotence 199
Jaisom Chopra

Clinical Features 199 • Diagnosis 202 • Management 203 • Special Issues 205

23. Approach to and Management of Inflammatory Vasculitis 207
Jaisom Chopra

Classification of Primary Vasculitides 207 • Large Vessel Vasculitis 207 • Medium Vessel Vasculitis 210 • Small to Medium Vessel Vasculitis 211 • Special Issues 216

24. Lymphedema 217
Jaisom Chopra

Clinical Features 217 • Diagnosis 220 • Management of Patients 220

25. Hemodialysis Access 223
Jaisom Chopra

Anatomic Considerations 223 • Clinical Aspects of Fistula/Graft Placement 223 • Hemodialysis Catheters and Ports 226 • Limitations/Complications of Hemodialysis Access 227 • Special Issues 228

26. Perioperative Management of Patients with Peripheral Vascular Disease 230
Jaisom Chopra

Preoperative Cardiac Risk Assessment 230 • Preoperative Testing 231 • Perioperative Cardiac Risk Reduction 231 • Percutaneous Coronary Interventions 232

27. Bypass Grafts: Surgical Aspects and Complications 236
Jaisom Chopra

Vascular Conduits 236 • Surgical Considerations 241 • Limitations and Complications 245 • Special Issues 247

28. Computed Tomographic Angiography 248
Jaisom Chopra

Uses of Computed Tomographic Angiography 248 • Magnetic Resonance Angiography 249 • Noninvasive Evaluation of Extracranial Carotid Artery Disease 250 • Noninvasive Evaluation of Renal Artery Stenosis 250 • Evaluation of Aortic Aneurysmal Disease 252

Index 255

4

Magnetic Resonance Angiography in the Diagnosis of Vascular Disease

Jaisom Chopra

INTRODUCTION

- Catheter-based digital subtraction angiography (DSA) is still the gold standard for evaluating vascular disease.
- Magnetic resonance angiography (MRA) is fast becoming the noninvasive procedure of choice for certain vascular beds. It gives us information about the anatomy of the vascular tree, the blood flow, and the vascular wall.

CLINICAL APPLICATIONS

Cerebrovascular MRA (Fig. 1)

- It evaluates the cerebral circulation in a single sitting and gives additional parenchymal information making it the modality of choice.
- As the arteriovenous transit time is fast in the brain and because gadolinium contrast is not extracted by the brain capillaries, contrast imaging must be done very rapidly.

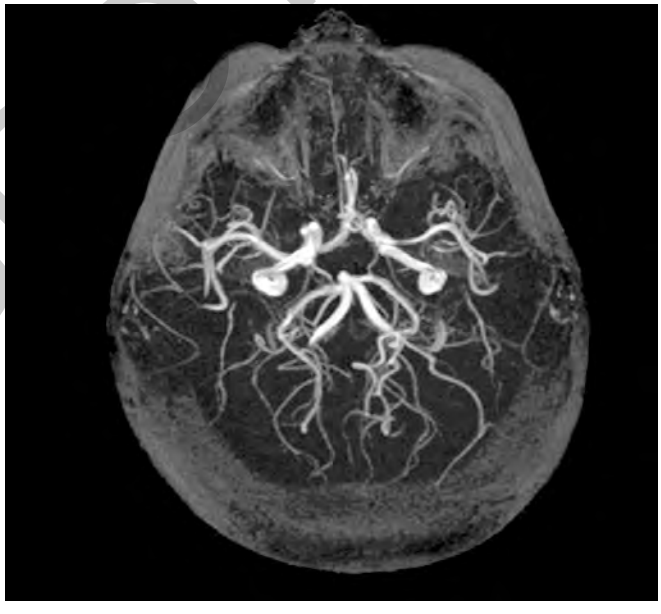

Fig. 1 Cerebrovascular MRA

Extracranial Vessels (Fig. 2)

Three-dimensional (3D) contrast MRA of carotids and thoracic aortic arch vessels is the investigation of choice to establish the presence and the absence of disease. Although DSA has a sensitivity and specificity of 95%, the reported advantages of MRA are:

- Ability to image plaque ulcerations
- No flow-related artifacts so that tortuous vessels are not degraded
- Short imaging times—coverage of aortic arch to circle of Willis takes on 30–40 s.

Techniques

Three-dimensional gadolinium-enhanced MRA of the carotids is obtained in the coronal plane without breath holding. This improves the sharpness of the image of the aortic great vessels and their origin. This runs the risk of moving out of the coronal plane with any movement of the neck. This also involves the digital subtraction wherein background images are deleted to improve the quality of the vessels especially in the area of stenosis.

Intracranial Vessels (Fig. 3)

Techniques

In acquired disease where there is narrowing—the sting sign—the lumen is very narrow and just short of total occlusion.

JAYPEE BROTHERS

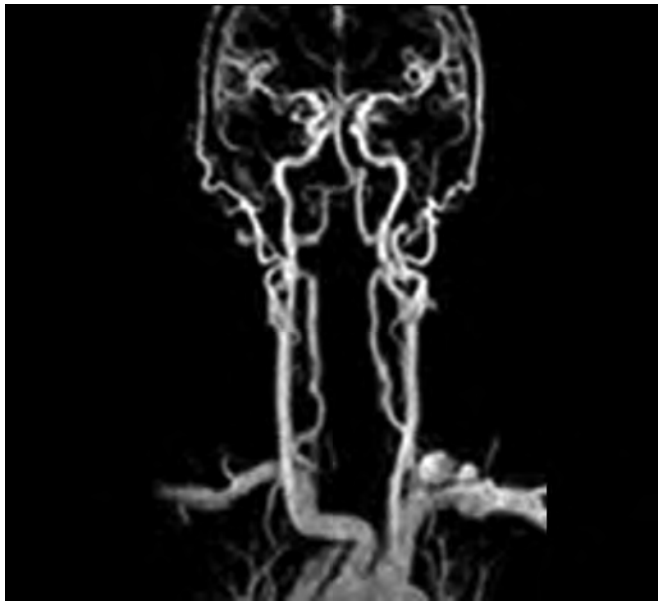

Fig. 2 MRA extracranial vessels



Fig. 3 MRA intracranial vessels

The 3D sequence is sensitive to a wide range of flow velocities and shows better flow morphology. It is sensitive to any movement by the patient and so the patient has to remain still during this procedure which may pose a problem at times. That is why a fidgety head injury patient may take time because he cannot lie still.

Indications

- MRA has sensitivity and specificity comparable to invasive angiography.
- Intracranially, it shows arterial stenosis and occlusion, aneurysms, arteriovenous malformations (AVMs), tumors, vascular compressions, and venous pathology.
- Extracranially, it shows carotid bifurcation disease, aortic arch branch vessel disease, stenosis and occlusion, atherosclerotic disease, and carotid and vertebral artery dissection.

Thoracic MRA (Fig. 4)

Computed tomography (CT), angiography and MRA have replaced conventional angiography. The multiplanar reformations of magnetic resonance imaging (MRI) eliminate the problem of overlap seen in catheter angiography and provide a complete picture of the anatomy of the vessels and complex congenital disease in the chest. Phase-contrast MRA can measure flow and provide physiological information across stenosis and shunts.

Indications

- Pathology of the great vessels in the chest—thoracic aorta and its branches, pulmonary artery and its branches, and large veins of the chest. Imaging of the coronary arteries and veins is possible but in experimental stages.
- Aortic disease—congenital and acquired disease of the thoracic aorta. In congenital disease—coarctation, right-sided aorta, vascular rings, and double arch. In acquired

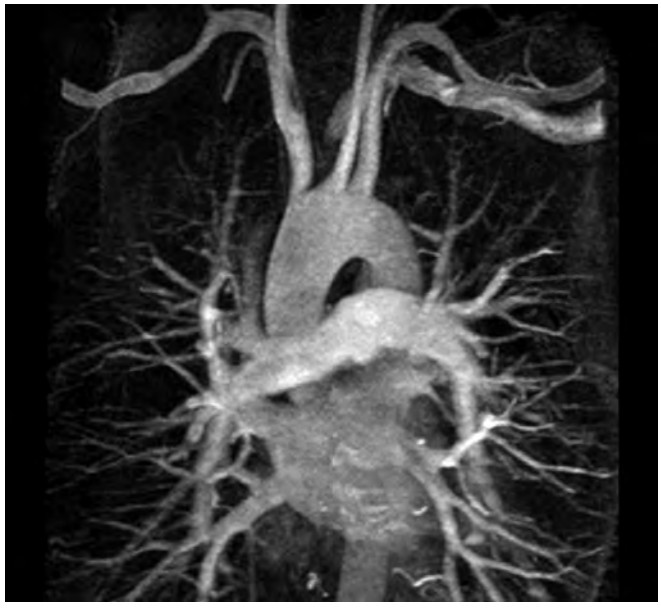

Fig. 4 MRA thorax

JAYPEE BROTHERS

disease—aneurysms, dissection, trauma, inflammatory disease (giant cell arteritis).
- Pulmonary disease—congenital and acquired disease. In congenital disease of the pulmonary artery, we see pulmonary atresia, pulmonary slings, and arteriovenous (AV) malformations. In acquired disease, we have pulmonary hypertension. There is high sensitivity and specificity to pulmonary embolism. Compression and invasion of the pulmonary vessels by tumor is seen well by MRA.
- Venous disease—magnetic resonance venography (MRV) of large veins of the chest has proved to be very useful to assess thoracic inlet syndrome, superior vena cava (SVC) syndrome, and thrombus in SVC and branches. Pulmonary vein anatomy is assessed before and after radiofrequency ablation therapy for refractory atrial fibrillation.

Abdominal and Pelvic MRA (Fig. 5)

- Although CT angiography is still the preferred modality for abdominal aorta, but MRA has started to bypass it in various aspects of abdominal and pelvic vascular disease imaging.
- MRA images are rapid, efficient, offer high spatial and contrast resolution apart from avoiding high doses of IV contrast and ionizing radiations as seen in CTA.
- MRA also provides assessment of flow and functional stenosis severity. This is useful in renal arteries and mesenteric arteries and portal venous systems.
- Multiplanar reformations provide good images of complex anatomy.

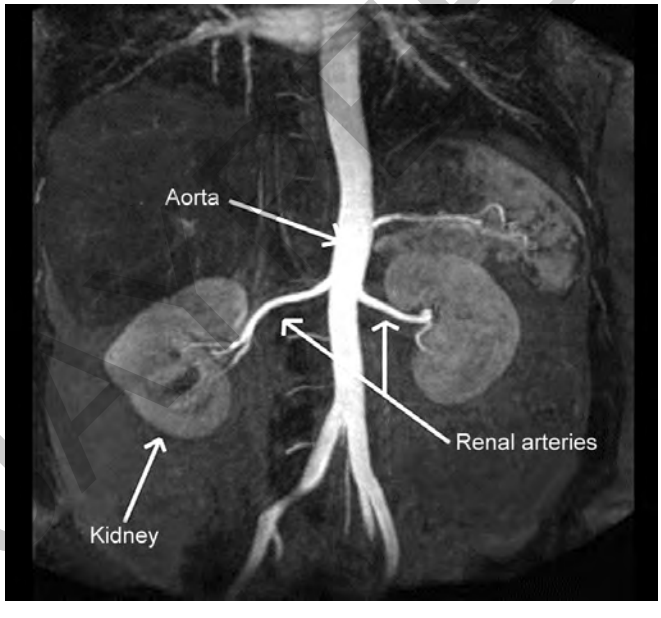

Fig. 5 MRA abdomen

- It provides images of the lumen and wall of the vessels along with dynamic imaging of the flow through different abdominal viscera.
- Up to 50 high-quality images can be obtained in one breath that will cover the entire abdominal aorta from diaphragm to aortic bifurcation.

Indications

- Evaluating renal artery stenosis, aneurysms, dissection, and fibromuscular disease. Not only the renal anatomy but also the function can be evaluated by MRA, which is not possible with catheter angiograms.
- Renal failure patients cannot tolerate high bolus of IV contrast, and so, MRA has a distinct advantage over catheter angiogram or CT angiogram.
- MRA is excellent for evaluating renal donor kidneys for vasculature and structure.
- MRA is excellent for evaluating renal allograft after transplantation to assess patency of anastomosis and function of allograft.
- Mesenteric MRA is used to define mesenteric ischemia, aneurysms, dissection, anatomic variations, collateral circulation, and encasement by tumor.
- MRA can evaluate the venous circulation—systemic and portal.
- Inferior vena cava (IVC) and branches are evaluated for occlusion by thrombus and tumor encasement.
- MRI evaluates liver parenchymal disease, as well as vascular supply in portal hypertension, portosystemic shunts, portal vein thrombosis, cavernous transformation, and tumor encasement.
- MRI helps assess hepatic veins in Budd-Chiari syndrome and liver tumor encasement.
- MRI is helpful in evaluating arterial and dual venous connections to the liver after liver transplant.
- MRV helps assess renal veins and extent of renal cell carcinoma.
- MRV is helpful in mesenteric vein thrombosis and acute thrombosis of ovarian veins.

Peripheral Vascular MRA (Fig. 6)

- It helps screen at-risk persons and provides a roadmap for planning further therapy. It helps evaluate in-flow disease.
- A 3-D MRA can evaluate the pathology to the foot by a single-dose bolus-chase method. The foot vessels remain a challenge and are not well visualized.

Indications

- MRA evaluates arteries of upper and lower limbs involved in atherosclerosis, aneurysms, inflammatory vasculitis, and embolic disease.

JAYPEE BROTHERS



Fig. 6 MRA peripheral vascular

- MRA helps investigate AV malformations and assess dialysis fistulas.
- MRV assesses deep vein thrombosis, vascular malformations, and post-thrombotic venous disease.

LIMITATIONS

Susceptibility Artifacts

These are the T2 effects—dephasing due to the magnetic properties of the local environment. These include:

- Surgical clips, shrapnel, and stents
- High concentration of IV contrast
- Air-tissue interfaces such as lung vessels and bowel vessels.

They produce focal signal fall-outs—dark areas in images obscuring surrounding vessels and make them look like stenosis or occlusion. These artifacts can be minimized but not eliminated. Plane X-rays can detect location of metals.

Motion Artifacts

In uncooperative patients or during breathing. This makes images blurred and reduces sensitivity to detect subtle findings. These are minimized by breath holding and shorter duration of examination. The involuntary motion like peristalsis and arterial pulsations cause ghosting and reduced by echocardiography (ECG) gating. Intraluminal turbulence causes spin dephasing leading to overestimation of stenosis.

Coverage Artifacts

If parts of the vessels are not included, they appear as occluded vessels. This may happen in markedly tortuous aorta and other vessels. Vessels toward the edges of the field show drop off signals and blurring.

Timing Artifacts

This is of prime importance. If performed too early, then the signal is weak and vessel may look diseased especially distal to a stenosis or occlusion. Delayed phase shows collateral and reformation distal to the occlusion. The delayed timing is based on the part of the body slowest to fill.

Resolution Artifacts

This limits sensitivity to detect subtle lesions. It may give the appearance of stenosis or fail to detect intraluminal lesions partially obstructing flow.

Non-contrast-Enhanced Artifacts

The blood flow within the plane of the image causes false occlusions and stenosis due to in-plane saturation effects. Blood turbulence in stenosis, aneurysms, and bifurcations gives a similar effect. This is also seen in tortuous vessels or with temporary retrograde flow seen during cardiac diastole. This effect is minimized by increasing the distance between the tracking saturation and the imaging plane.

Mural and Extramural Pathology

Many extramural tissues such as fat, hemorrahage, and bowel content can mimic normal flow or masses. Lung atelectasis can mimic a mass or even inflammatory aneurysm due to abnormal periaortic enhancement. A high signal from perivascular fat due to incomplete fat suppression can mimic intraluminal flow. A high signal from a thrombus within an aneurysm can mimic normal blood flow. Vascular stenosis and perfusion defects are seen in extramural pathologies such as lung disease.

SPECIAL ISSUES

Contraindication to MRI include:

- Pacemaker
- Epicardial pacer wires
- Aneurysm clips
- Metal fragments in the eye
- Some metallic implants:
  - Many metallic implants are compatible with MRI.
  - Endovascular stents (Nitinol) are MRI compatible.
  - Pregnant patients can be scanned but without contrast.

JAYPEE BROTHERS

CONCLUSION

- MRA is becoming the technique of choice for many vascular beds.
- MRA is popular because it is associated with minimal risks and gives high resolution anatomical and functional details.
- Three-dimensional contrast-enhanced MRA can be done with a single breath hold.
- By MRA, the hemodynamic significance of a stenosis can be assessed.

PRACTICAL POINTS

- If possible, MRI should be performed holding the breath.
- Consider the possibility of an artifact to explain an unusual finding and always correlate the finding with other imaging modalities.
- Consider the possibility of slow flow if no images are seen.

JAYPEE BROTHERS

for detailed information on surgery books, visit our website **www.jaypeebrothers.com,** for detailed information on surgery books, visit our webs

A Practical Approach to
Vascular & Endovascular Surgery

A Practical Approach to Vascular and Endovascular Surgery is a result of many years of experience put together by the authors. It is a practice-oriented book that is mainly targeted to benefit surgical postgraduates, vascular surgery trainees and young vascular consultants.

The speciality of Vascular and Endovascular Surgery has evolved rapidly over the years and treatment protocols and guidelines have changed with time. This book outlines the latest trends in management of vascular diseases and lays down special emphasis on the endovascular methods to treat such conditions.

There are chapters which highlight the various approaches to the management of aortic aneurysms and aortic dissections. These chapters have been simplified in a manner to make it easy for the reader to understand.



Jaisom Chopra completed his Masters in General Surgery (1981) from Jawaharlal Nehru Medical College, Aligarh Muslim University, Aligarh, Uttar Pradesh, India. He then became a Fellow of Royal College of Surgeons (Edinburgh) (1989). He spent several years in the UK visiting many hospitals where he underwent rigorous vascular training and enhanced his skills. This was followed by a two-year stint at Port Elizabeth, South Africa, as Consultant Vascular and General Surgeon. He returned to India in 1997 and joined Batra Hospital, New Delhi as Consultant Vascular Surgeon. From 2011 onwards, he has been attached to Indraprastha Apollo Hospitals, New Delhi.

He has many national as well as international papers and publications under his belt. He has been actively involved in research activities and has also contributed as a Teacher for more than 15 years. He has participated in several national as well as international conferences.

He has special interest in the 'scarless' management of varicose veins. He has vast experience in performing a wide variety of vascular procedures such as endarterectomies, embolectomies and bypasses. His dedication towards patient care is exemplary and his commitment towards teaching has propelled the specialty of vascular surgery to glorious heights.



VS Bedi completed his Masters in Surgery (1988) from University of Mumbai, Mumbai, Maharashtra, India. He underwent specialization training in Vascular Surgery from Bombay Hospital, and further enhanced his skills in three Vascular Surgery centers across Germany (Katharinen Hospital, Stuttgart; Porz am Rhein, University of Cologne and Evangelical Krankenhaus, Mülheim). He was instrumental in establishing the Vascular Centre (1995), Army Hospital, Referral and Research, New Delhi, and served the Indian Navy from 1983 till 2012. Thereafter, he joined, as Chairman and Senior Consultant, Department of Vascular and Endovascular Surgery, Sir Ganga Ram Hospital, New Delhi.

He is an international figure and a key opinion leader in the world of Vascular Surgery with numerous paper publications, paper presentations and national as well as international trophies under his belt. He is the President, Vascular Society of India and the first member from India for the Trans-Atlantic Society Consensus (TASC). He has been bestowed with honorary corresponding membership of the German Vascular Society. He was decorated with the Nao Sena Medal in 2003 by the Government of India for active role played during the Gujarat Earthquake. He has recently taken over as the President of the World Federation of Vascular Societies.

He has special academic interest in the Management of Aortic Aneurysms and has one of the largest experiences in the country on endovascular management of aortic aneurysms. He also has the largest series of eversion endarterectomies for management of carotid stenosis. He is the first to perform Modified Eversion Endarterectomy in India.

He seeks to establish a comprehensive training program for vascular specialists, which can be implemented across the country to enhance patient care.

Available at all medical bookstores
or buy online at www.jaypeebrothers.com

JAYPEE BROTHERS
Medical Publishers (P) Ltd.
www.jaypeebrothers.com

Join us on facebook.com/JaypeeMedicalPublishers

Shelving
Recommendation
SURGERY

ISBN 978-93-5152-995-8
9 789351 529958