ers.com, for detailed information on radiology books, visit our website www.jaypeebrothers.com, for detailed information on radiology books

MRI Brain

Atlas and Text

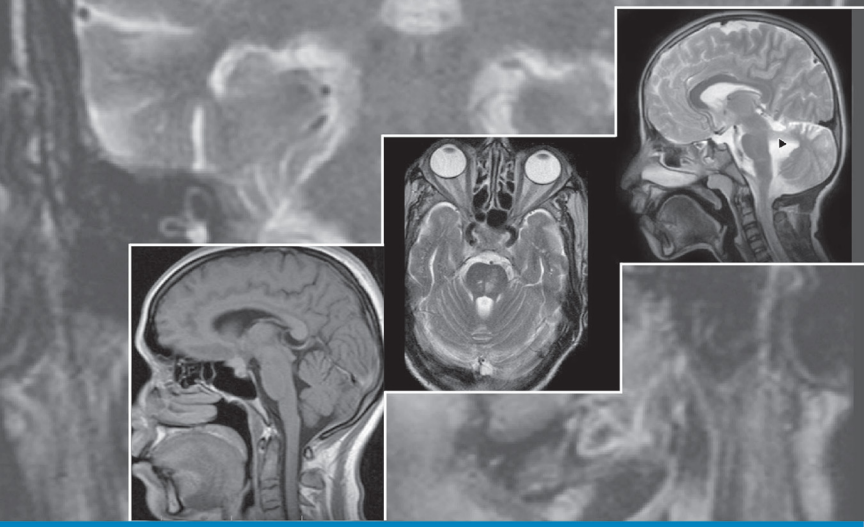

G Balachandran

Foreword
PC Rajaram

JAYPEE

Contents

1. MRI Basics: Physics **1**

- MR Working in a Nutshell *3*
- Advantages of MRI *5*
- Disadvantages of MRI (Compared to CT Scan) *5*
- Multiplanar Capability in MR *6*

2. Normal Cross-sectional MR Anatomy of Brain **8**

- *Axial Image Planes:* Parallel to Skull Base *9*
- Axial Image Level A1 *10*
- Axial Image Level A2 *11*
- Axial Image Level A3 *12*
- Axial Image Level A4 *13*
- Axial Image Level A5 *14*
- Axial Image Level A6 *15*
- Axial Image Level A7 *16*
- *Coronal Section:* Parallel to Coronal Suture *17*
- Coronal Image Level C1 *18*
- Coronal Image Level C2 *19*
- Coronal Image Level C3 *20*
- Coronal Image Level C4 *21*
- *Midline Sagittal Image:* Parallel to Sagittal Suture *22*
- Gross Brain Anatomy as seen in MR Images *23*

3. MRI of Signals and Sequences **26**

- Glossary of Terms *26*
- Examples for Basic MR Signal Intensity Nomenclature *28*

- Note on Sequences *28*
- Examples of Common MR Sequences and their Use *30*
- Fluid Attenuation Inversion Recovery (FLAIR) *34*
- Role of MRI Contrast Agent *36*
- *Diffusion Weighted Imaging:* An Important Tool for Diagnosing Stroke *37*

4. Principles of Intracranial Space Occupying Lesions (ICSOL)/Tumor Diagnosis by MRI 39

- Look for Classic Location/Morpholgy/Sign *39*
- Determine Whether the Lesion is Intra-axial versus Extra-axial *40*
- Patient's Age and Sex *41*
- MRI Signal Intensity *41*
- T1W Bright Lesions *41*
- Classic Location *42*
- Type and Degree of Contrast Enhancement *43*
- The Extension and/or Spread of the Tumor *43*

5. MRI Atlas of Cases 45

***Cases (1–30):* Tumors 45**

- *Case 1: Cerebral Pilocytic Astrocytoma 45*
- *Case 2: Left Falx Meningioma 49*
- *Case 3: Cerebellopontine Angle Meningioma 52*
- *Case 4: Recurrent Central Neurocytoma 57*
- *Case 5: Brainstem Glioma 59*
- *Case 6: Cerebellar Pilocytic Astrocytoma 61*
- *Case 7: Right Falx Meningioma 64*
- *Case 8: Atypical Meningioma 66*
- *Case 9: Multiple Meningiomas 69*

- *Case 10: Hemangiopericytoma 72*
- *Case 11: Craniopharyngioma 75*
- *Case 12: Left Glioblastoma Multiforme 78*
- *Case 13: Right Glioblastoma Multiforme 81*
- *Case 14: Optic Groove Meningioma 83*
- *Case 15: CP Angle Epidermoid 85*
- *Case 16: Dysembryoplastic Neuroepithelial Tumor 88*
- *Case 17: Planum Sphenoidale Meningioma 90*
- *Case 18: Posterior Cranial Fossa Meningioma 93*
- *Case 19: Low Grade Glioma 96*
- *Case 20: Pituitary Secreting Macroadenoma 99*
- *Case 21: Jugular Foramen Schwannoma 103*
- *Case 22: Cerebellar Hemangioblastoma 105*
- *Case 23: Central Nervous System Lymphoma 108*
- *Case 24: Pituitary Microadenoma 111*
- *Case 25: Infratentorial Ependymoma in Adult 114*
- *Case 26: Classical Acoustic Schawannoma 116*
- *Case 27: Juxtatentorial Meningioma 119*
- *Case 28: Convexity Meningioma 121*
- *Case 29: Benign Glioma 123*
- *Case 30: Craniopharyngioma in Adult 125*

***Cases (31–49):* Congenital Lesions 128**

- *Case 31: Schizencephaly: Closed Lip Type 128*
- *Case 32: Schizencephaly: Open Lip Type 130*
- *Case 33: Dysgenesis of Corpus Callosum and Associated Lipoma 132*
- *Case 34: Lipoma of Corpus Callosum 135*
- *Case 35: Type 1 Chiari Malformation 137*
- *Case 36: Type 1 Chiari Malformation with Syrinx 1 139*

- *Case 36A: Type 1 Chiari Malformation with Syrinx 2 141*
- *Case 37: Classic Arachnoid Cyst 143*
- *Case 38: Arachnoid Cyst: Posterior Cranial Fossa 146*
- *Case 39: Craniovertebral Junction Anomaly: Basilar Invagination Fossa 149*
- *Case 40: Classic Colloid Cyst 152*
- *Case 41: Rathke's Cyst 154*
- *Case 42: Cerebellopontine Angle: Epidermoid 156*
- *Case 43: Intraventricular Epidermoid 159*
- *Case 44: Partial Dysgenesis of Corpus Callosum with Interhemispheric Cyst 162*
- *Case 45: Joubert Syndrome 164*
- *Case 46: Quadrigeminal Plate Arachnoid Cyst with Obstructive Hydrocephalus 167*
- *Case 47: Dandy-Walker Variant 169*
- *Case 48: Posterior Cranial Fossa Giant Cyst 171*
- *Case 49: Quadrigeminal Plate Large Arachnoid Cyst 173*

***Cases (50–67):* Vascular 176**

- *Case 50: Cavernoma Left Frontal Lobe 176*
- *Case 51: Acute Right Middle Cerebral Artery Territory Ischemic Infarct 179*
- *Case 52: Giant Aneurysm of Basilar Artery Trunk 182*
- *Case 53: Right Subacute Subdural Hematoma 184*
- *Case 54: Lateral Medullary Syndrome (Wallenberg's Syndrome) 187*
- *Case 55: Venous Infarct: Left Temporal Lobe 189*
- *Case 56: Acute Right Thalamic Ischemic Infarct 191*
- *Case 57: Giant Aneurysm Supraclinoid Segment of Internal Carotid Artery 194*

- *Case 58: Left Transverse Sinus Thrombosis 196*
- *Case 59: Right Cerebellar Ischemic Infarct 198*
- *Case 60: Anterior Cerebral Artery Aneurysm with Subarachnoid Hemorrhage 201*
- *Case 61: Vein of Galen Malformation 203*
- *Case 62: Cavernoma with Recent Bleed 205*
- *Case 63: Right Posterior Watershed Infarct 207*
- *Case 64: Vertebrobasilar Insufficiency 209*
- *Case 65: Cerebral Venous Thrombosis 211*
- *Case 66: Posterior Reversible Ischemic Encephalopathy 213*
- *Case 67: Intraventricular Hemorrhage 216*

***Cases (68–78):* Infectons/Infestations 219**

- *Case 68: Solitary Tuberculoma 219*
- *Case 69: Multiple Tuberculomata 222*
- *Case 70: Tuberculous Cerebral Abscess 224*
- *Case 71: Tuberculosis of the Optic Nerve Sheath 227*
- *Case 72: Bacterial Meningoencephalitis 229*
- *Case 73: Toxoplasmosis 232*
- *Case 74: Opportunistic Brain Infection in Immunocompromised Patient 234*
- *Case 75: Neurocysticercosis 237*
- *Case 76: Acute Disseminated Encephalomyelitis 239*
- *Case 77: Viral Encephalitis 242*
- *Case 78: Rhino-Orbito-Cerebral Zygomycosis 245*

***Cases (79–100):* Miscellaneous 248**

- *Case 79: Wilson's Disease 248*
- *Case 80: Tuberous Sclerosis 250*

- *Case 81: Central Pontine Myelinolysis 253*
- *Case 82: Neurosarcoidosis 256*
- *Case 83: Idiopathic Intracranial Hypertension (IICHT)/Pseudotumor Cerebri 259*
- *Case 84: Obstructive Hydrocephalus: Aqueductal Stenosis 261*
- *Case 85: Traumatic Atlantoaxial Joint Subluxation 263*
- *Case 86: Central Pontine Myelinolysis 2 265*
- *Case 87: Mesial Temporal Sclerosis 267*
- *Case 88: Tolosa-Hunt Syndrome 270*
- *Case 89: Fahr's Disease 272*
- *Case 90: Normal Pressure Hydrocephalus 274*
- *Case 91: Adrenoleukodystrophy 277*
- *Case 92: Ectopic Neurohypophysis 279*
- *Case 93: Diffuse Axonal Injury 282*
- *Case 94: Devic Disease 284*
- *Case 95: Leigh's Disease 287*
- *Case 96: Huntington's Chorea 289*
- *Case 97: Empty Sella Syndrome and Aqueductal Stenosis 292*
- *Case 98: Neuroglial Cyst 295*
- *Case 99: Neurofibromatosis Type 1 297*
- *Case 100: Neurofibromatosis Type 2 300*

Index *303*

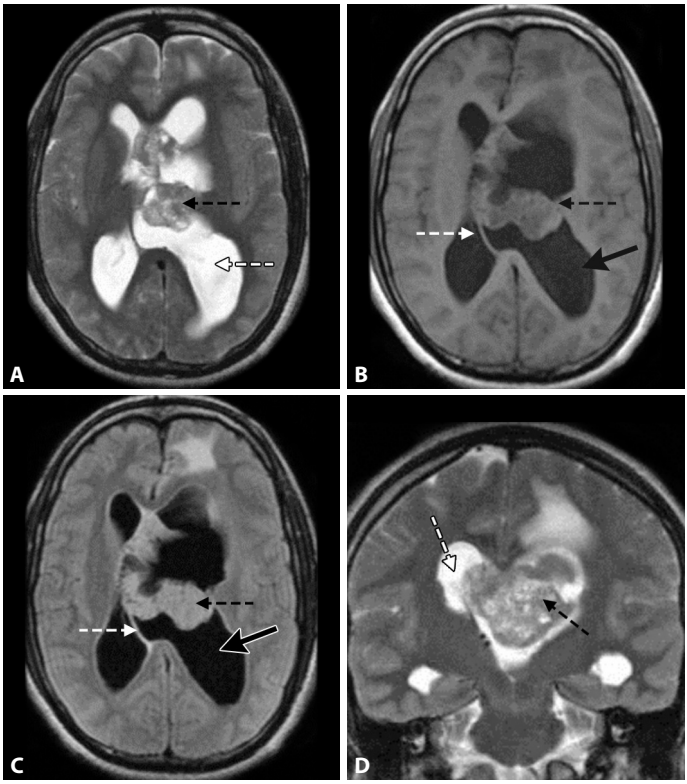

Figures 1A to D: (A) *T2W axial:* A well-defined heterogenous intraventricular mass with small cysts within the mass, with obstruction at foramen of Monro (dotted black arrow); (B) *T1W axial:* The septum pellucidum (white dotted arrow) is displaced and the mass is seen arising from the left side. The left lateral ventricle is more dilated than the right side (thick black arrow); (C) *FLAIR axial:* The septum pellucidum is displaced and the mass is seen arising from the left side; (D) *T2W coronal:* Better the intraventricular location of the tumor

DISCUSSION

Central neurocytomas are rare intraventricular neoplasms of the central nervous system, compromising 0.25–0.5% of brain tumors. The diagnosis and management of these tumors remains controversial since most clinical series are small. Typically, patients with central neurocytomas have a favorable prognosis, but in some cases the clinical course is more aggressive. Although histological features of anaplasia do not predict biologic behavior, proliferation markers including MIB-1 might be more useful in predicting relapse.

Radiologically, the typical appearance of a central neurocytoma as reported in the literature is that of a well-circumscribed mass confined to the anterior portion of the lateral ventricles. Punctate or coarse calcifications and multiple small cysts within the tumor are often observed. Mild-to-moderate contrast enhancement is common. Intraventricular oligodendroglioma or ependymoma may be indistinguishable from central neurocytoma without ultrastructural and immunohistochemical studies. Imaging of central neurocytoma is usually characteristic. Most of them occur as an exophytic, well circumscribed, globular mass that protrudes into the ventricles. Radiological differential diagnosis includes the intraventricular tumors of the lateral ventricles, such as ependymoma, giant cell astrocytoma, pilocytic astrocytoma and neurocytoma.

BIBLIOGRAPHY

1. Goergen SK, Gonzales MF, McLean CA. Intraventricular neurocytoma: radiologic features and review of the literature. Radiology. 1992;182:787-92.
2. Smoker WRK, Townsend JJ, Reichman MV. Neurocytoma accompanied by intraventricular hemorrhage: case report and literature review. AJNR. 1991;12:765-70.

for detailed information on radiology books, visit our website **www.jaypeebrothers.com,** for detailed information on radiology books, visit our w

MRI Brain
Atlas and Text

Salient Features

- A collection of over 100 neuroradiology cases, and all the cases have been completely worked up till the final diagnosis
- All the cases have either surgical or histopathological proof of the final diagnosis, and are categorized for easy reading into congenital, vascular, tumors, infections and miscellaneous lesions such as metabolic and degenerative diseases
- The initial chapters are devoted to principles of MRI technique in such a simple language so that even a novice can understand MRI principles and are followed by chapters on normal brain appearance on MRI, basic interpretation, glossary of common MR terms, etc.
- In each case study, images are followed by their interpretation and brief description of the disease
- The language chosen is simple and easy to follow so that even a budding medical doctor can understand and interpret
- The purpose of the book is to make the General Practitioners to get them acquainted with common brain diseases in their MRI study, to get an idea of various manifestations, to feel ease when ordering MRI brain and interpreting those images, to cross-check their findings with the official report.



G Balachandran is a highly qualified Consultant Radiologist with over 30 years of experience in teaching radiology. Presently, he is working as an Associate Professor, Department of Radiology, Sri Manakula Vinayagar Medical College and Hospital, Puducherry, India. He has already published three books, which were well accepted by medical students. He is a postgraduate Teacher and has guided several postgraduate thesis. He was an Academic Registrar, Indira Gandhi Government General Hospital and Postgraduate Medical Institute, Puducherry, India. He has presented papers in reputed international radiology journals and has published over 500 cases in international radiology forum such as EURORAD, MyPACS.net, Radiopaedia.org, Radiolopolis, AuntMinnie, RTi, etc.

Available at all medical bookstores
or buy online at www.jaypeebrothers.com

JAYPEE BROTHERS
Medical Publishers (P) Ltd.
www.jaypeebrothers.com

Join us on facebook.com/JaypeeMedicalPublishers

Shelving Recommendation
RADIOLOGY

ISBN 978-93-5250-022-2