2nd Edition

Volume 1

HAIR TRANSPLANT 360

for Physicians



SAMUEL M LAM

Get Full Access with added features at

emedicine360.com

JAYPEE

Contents

SECTION I: CORE 360 1

1. **Hair Transplant Preoperative 360** **5**
   - History and Where We are Today 5
   - Preoperative Considerations 8
     - Male-Pattern Baldness 8
     - Women and Hair Loss 12
     - Medical Management for Hair Loss 17
     - Other Medical Therapies for Hair Loss 28
     - Low-Level Laser Therapy 30
     - Platelet-Rich Plasma and ACell Matristem Micromatrix 32
     - Hair-Loss Diseases and Hair Restoration 32
     - The Hair Cycle 36
     - Types of Hair Loss: A Glossary 36
     - Hair Replacements, Hairpieces, and Wigs 39
     - Camouflaging Products 42
     - Scalp Micropigmentation 44
     - Consultation and Preoperative Planning 45
     - Preoperative Session 53
   - Other Topics 56
     - Standardized Photography 56
     - Office Management and Leadership 60
     - Marketing 63
   - Concluding Thoughts 64
2. **Hair Transplant Operative 360** **67**
   - New thoughts about the Second Edition 67
   - Operative Considerations: The Surgeon's Role 71
     - Overview 71
     - Key Instrumentation and Materials 72
   - Hairline Design 73
   - Graft-Calculation Planning 84
   - Preparation of PRP 89
   - Platelet-Rich Plasma/ACell Matristem Micromatrix Injection in Balding Scalp without Surgery 92
   - Patient Preparation and Anesthesia Considerations 93
   - Donor Harvesting and Closure 95

Graft-Storage Solutions 120
Recipient-Site Creation 122
Operative Set-up 123
Basic Principles for Recipient-Site Creation 127
Male Hairline Recipient-Site Creation 133
Male Hairline Recipient-Site Creation 139
Female Hairline Recipient-Site Creation 142
Temporal Point Recipient-Site Creation 146
Lateral (Parietal) Hump Recipient-Site Creation 149
Midscalp Recipient-Site Creation 150
Crown/Vertex Recipient-Site Creation 156
Immediately Following Recipient-Site Creation 164
3. Hair Transplant Postoperative 360 167
Postoperative Instructions and Advice 167
Identifying and Managing Complications 170
Donor Harvesting 171
Recipient-Site Creation 173
Managing the Postoperative Patient Relationship 177

SECTION II: MORE 360 181

4. Case Studies 185
Overview 185
Case One: Male Hairline and Central Density 186
Clinical Scenario 186
Planning 186
Execution 186
Rationale for Selection of This Case 189
Results 190
Case Two: Female Hairline Lowering 190
Clinical Scenario 190
Planning 190
Execution 190
Rationale for Selection of This Case 191
Results 195
Case Three: Multiple Stage Male Hair Transplant Front and Back 195
Clinical Scenario 195
Planning 196
Execution 196
Rationale for Selection of This Case 202
Results 203

Case Four: Recipient-Site Planning and Execution 1 203
Case Five: Recipient-Site Planning and Execution 2 206
5. Physician Training **221**
Overview 221
Hairline Design 222
Recipient-Site Creation 235
Addendum: Patient Forms **251**

Index *259*

II

MORE 360

JAYPEE BROTHERS

4. Case Studies 360 185
5. Physician Training 360 221
Addendum: Patient Forms 251

JAYPEE BROTHERS

Chapter 4 presents five case studies to help a surgeon entering the field of hair restoration to think more creatively and strategically that include male hairline and midscalp, female hairline, two-stage male hairline/midscalp and then crown, followed by two mega session cases focused on recipient-site planning. Chapter 5 is a new chapter that explores training physicians on hairline design using eye-brow pencils and recipient-site planning using a honeydew melon model. The common errors for both hairline design and recipient-site creation are presented to help the starting surgeon engage in critical self-study and thereby improve results without risking patient injury. The addendum at the end of this section includes patient clinical forms that may be used and adapted for one's own practice.

JAYPEE BROTHERS

Develop a passion for learning. If you do, you will never cease to grow.

Anthony J D'Angelo

JAYPEE BROTHERS

4 Case Studies

JAYPEE BROTHERS

OVERVIEW

The mission of this book is to emphasize the creative (artistic) component to hair restoration as much as the technical aspects of the procedure. Most textbooks to date have only laid the groundwork for the technical side of surgery without much study of the artistry required to achieve outstanding results.

Hair-transplant surgery can be thought of as painting a canvas (the naked scalp) with many-sized brushes (grafts) but only afforded a limited amount of paint to complete the job. In addition, the artist must project forward in time to predict an ever-enlarging canvas with ever-dwindling paint. In short, an excellent result today may become less than desirable (less dense or worse unnatural) over time if lacking good planning or follow-up.

Although this chapter focuses on the creative-thinking process that separates an average from an excellent hair-restoration surgeon, it is also a much-needed exercise for a surgeon who has read the previous chapters and now must strategize on how to perform a procedure on a real patient. What is technically understood from reading a book can fall apart when actually confronting a real-world scenario. Hence, I have chosen representative cases of real patients who can help mature the thinking of both a novice and advanced surgeon. Obviously, this chapter should only be the start of a lifelong educational process that involves regularly attending major meetings on hair restoration, visiting respected colleagues, and simply ongoing mastery of the discipline by rigorous technique and review of one's results. The new Chapter 5 to this edition reinforces the skills to practice one's art by performing repeated drills. Through studying the "artwork" in this chapter and then practicing it through the exercises in the following chapter, the reader can create a solid foundation for successful hair restoration.

I have meditated on how hair transplantation is very akin to what Apple, Inc, delivers every year with a new iPhone model. Steve Jobs contended that the work

at Apple, Inc, represents an intersection of Liberal Arts and Technology, and I would say that is a good way to describe superior hair-transplant work. There is a mixture of advancing technology and artistry. This new edition highlights how many changes have been developed since the publication of the first edition. In tandem with technological developments, every artist evolves and so this book represents the current "artwork" that I practice. By the time that this book is published, there may be subtle and profound changes to my work but that is and should be the nature of all practicing artists and technicians. With critical self-study of your work, you can strive to achieve better results, which I believe is an inherent ingredient to enhancing one's joy in this lifelong pursuit.

CASE ONE: MALE HAIRLINE AND CENTRAL DENSITY

Clinical Scenario

A 40-year-old white man (Figs. 4.1A to F) has been losing hair over the past decade or more. He started using finasteride and minoxidil about 3 years prior to his clinical visit. He shows extensive miniaturization of his hairline, central forelock, midscalp, and upper crown/vertex transition zone. He has lost the strength of his hairline and would like that restored.

Planning

The plan was to recreate a strong frontal hairline to restore the aesthetic frame to his face including the upper temporal recess. The secondary goal was to support the hairline by focusing on the central forelock and the central midscalp where there was a see-through effect back to the crown. Given the extensive degree of miniaturization, the hair was also evaluated wet, which revealed a much thinner midscalp than visible with his hair dry. On donor evaluation, the donor density was medium-high and the donor laxity was below average. I did not believe the scalp laxity would be sufficient to afford me enough grafts to cover both the frontal scalp and the crown in a single session and look natural with both dry and with wet hair. Accordingly, I believed that maximizing donor harvest would yield a sufficient number of grafts ideal to provide him a natural result for the frontal half of his head and leave his vertex for a later time and perform a similar-sized session. However, I would also inject activated platelet-rich plasma (PRP)/ACell Matristem Micromatrix (AMM) into the crown to determine if there would be any additional benefit.

Execution

Looking at his donor density that was about 70–80 follicular units (FUs) per square centimeter, I evaluated that we would need a 26 cm long by 11 mm donor strip in order to yield approximately 2,000–2,200 follicular-unit grafts (FUGs) containing

JAYPEE BROTHERS



Figures 4.1A to F

A 40-year-old man is shown before (A, C, and E) and after (B, D, and F) a single hair-transplant session as detailed in Figure 4.2 with the transplant restoring the hairline, central forelock, and midscalp

JAYPEE BROTHERS

1–4 hairs. I harvested the donor strip using the two-blade technique to ensure consistent width and desired yield. The wound was closed using 3-0 polypropylene, and a trichophytic closure was not used because the donor laxity was slightly tighter than desirable. After the initial 2 cm of tissue was dissected into grafts, we projected rounded numbers for graft yield as evident in the electronic medical record diagram (Fig. 4.2), demonstrating projected 200 one-hair grafts, 800 two-hair grafts, 700 three-hair grafts, and 480 four-hair grafts for the total of 2,180 grafts. (As a reminder, the reader is encouraged to read how to project numbers from a dissected donor segment, which is covered in Chapter 2.) These numbers were used to create the majority of recipient sites with final design/plan adjustments made when finalized graft numbers were obtained, as explained in Chapter 2 of this book. The recipient sites were made as shown in Figure 4.2 with a 21G needle for 1-hair sites, 20G for 2-hair sites, 19G for 3-hair sites, and 18G for 4-hair sites. The actual numbers differed slightly with the projected numbers being 232 one-hair grafts, 850 two-hair grafts, 750 three-hair-grafts, and 295 four-hair grafts for a total of 2,127 FUs. The difference between the projected and the final graft output was accommodated for by shifting grafts around as follows: pairing 30 extra 1-hair grafts and placing them into 2-hair sites (for a total of 15 grafts), placing extra 2-hair grafts (50 + 15) into 19G sites, consequently shifting extra 3-hair grafts (50 + 65) into 18G sites and thereby filling all sites with grafts. In this case, the sites versus graft numbers matched, and no additional sites were made or any sites left empty.

Looking at the pattern design in Figure 4.2, the goal is to build a natural hairline using 1-hair grafts along with multiple supporting rows of 2-hair grafts, all executed with sagittal sites. The 3-hair grafts were used to frame the hairline uniformly

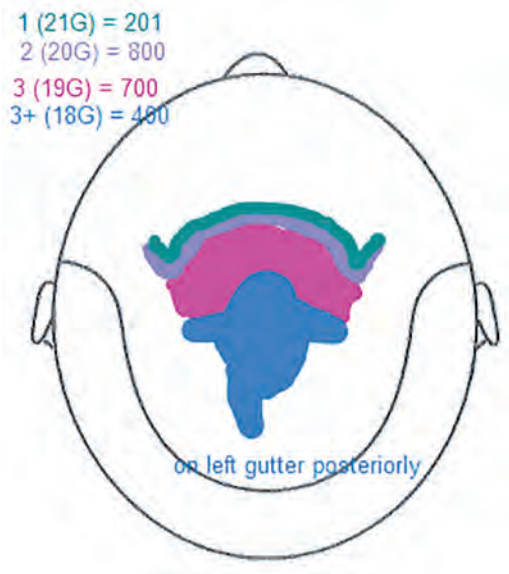

Figure 4.2

Electronic medical record schematic for Case One shows the recipient-site allocation used for the procedure

JAYPEE BROTHERS

across, which were created using coronal sites to aid in graft placement as well as for improved visual density, for the reasons enumerated in Chapter 2. The 4-hair grafts were used to support the midscalp density with a small encroachment into the central forelock to build further density in that critical area. The 4-hair sites were designed using sagittal incisions to aid in graft placement since there would be alternating sagittal and coronal sites that the graft-placement team could readily identify. There were more sites created along the left hair part to improve visual density in this area of aesthetic weakness. Further, hairs placed into the hair part would cascade over from the part all the way across the midscalp region creating more scalp coverage and visual density. In many cases, I use stronger and larger grafts a bit closer to the hairline to provide increased visual density in the central forelock. Given the coarseness of his hair, I was concerned with the fact that these grafts would look too strong and I elected to use them farther back. In general, I prefer to progress from fine hairs placed densely (1- and 2-hair grafts) along the hairline to slightly larger grafts (3-hair grafts) placed more densely in the central forelock then return to smaller grafts (like 2-hair grafts) farther back in areas of less concern. In this case, I progressed to and finished with stronger grafts because he already had hairs in the posterior midscalp and I knew that this gentleman would return for an additional session to restore his crown.

As in all procedures, I go back and think what could I have done better and with the lens of time, I would say that I would have used closer to 500 one-hair grafts, which is now more of the norm for me to further soften his hairline and possibly I would have built a little bit more of his upper to middle temple to support his hairline better. I believe we can always go back and look at our results to determine what we could do better.

Rationale for Selection of This Case

This case was selected for a few reasons. First, I believe it shows a standard hairline and central density that a beginning to advanced surgeon would elect to undertake, especially considering that no temple or crown was undertaken simultaneously. This approach would be a more straightforward undertaking for any surgeon starting out in this field. The darker hair makes dissection easier for the assistant team compared with white hair, which should be a consideration for a beginning surgeon since the proficiency of the team is as important as the surgeon's work. In addition, dissecting white hairs by an inexperienced team has a greater risk of transection and consequently more likelihood of poor results. As stated in Chapter 2, it is inadvisable to the starting surgeon and team to attempt to reconstruct the entire frontal area and crown in a single session because the scattered grafts will fail to achieve adequate visual density and the sparse spacing may also appear unnatural.

JAYPEE BROTHERS

RESULTS

The patient is shown before and 1 year (*see* Figs. 4.1A to F) after a single session of hair transplantation with a natural-appearing hairline and adequate central density blending naturally into his existing crown and temple hair. At this point we planned the second procedure and the patient underwent crown reconstruction during which further hairline refinement was performed.

CASE TWO: FEMALE HAIRLINE LOWERING

Clinical Scenario

A 26-year-old woman was bothered since her adolescence by her high hairline and wanted to have a more feminine hairline frame. She denied any history of hair loss, hair shedding, or use of any medications to treat hair loss.

Planning

The plan would be to restore both her frontal hairline frame and the temporal hairline, both of which needed to be completed to achieve a natural female hairline (*see* Figs. 4.3A to K). When performing female hairline lowering, there are two options: surgical female hairline advancement using a coronal-type incision (as discussed in Volume 3 of this book series) and hair transplantation. The benefit of the former is that the patient can achieve an immediate benefit without needing to wait for hair grafts to grow based on the degree of scalp laxity. However, the temporal hair would have to be addressed through a delayed hair-transplantation session since the advancement would only address the frontal hairline and not the temporal hairline.

The decision for the patient was to undergo a standard hair-transplant procedure to reframe her entire hairline. The plan for her surgery involved creating a strong frame and visual hair density. The donor density was medium throughout and the hair was moderate in thickness and relatively straight. Her scalp laxity was moderate. Every patient undergoes counseling that a single hair-transplant procedure may be inadequate to achieve full density, and this patient underwent two procedures to attain the result that she desired. The initial planning did not include a second procedure. However, the second procedure was performed focusing on hairline refinement.

Execution

In planning the donor harvest, the patient exhibits a donor density of approximately 75 FUs/cm^2. Accordingly, a donor harvest of 9.75 mm × 25 cm was planned to yield approximately 5,000 hairs or approximately 2,000 FUGs. She underwent

JAYPEE BROTHERS

her first procedure using primarily 2-hair grafts to achieve a strong frame to the hairline supported posteriorly with 3-hair and difollicular unit (DFU) grafts (Fig. 4.4A). The anterior hairline was framed with 1-hair grafts. The 2-hair sites were created anteriorly with 19G needles and posteriorly with a 0.65 mm punch (an older method that I no longer employ). Difollicular unit sites were made with a 1 mm punch (again I no longer use punches but believe needles and slits better in achieving consistent results). One-hair sites anteriorly were made with a 20G needle. Recipient sites along the hairline were fashioned to create a natural, female cowlick appearance. A review of Chapter 2 will provide details as to the nature of a female hairline, which is difficult to design easily for a beginner. Unlike a male hairline in which all of the anterior hairline recipient sites are directed uniformly anteriorly, the female hairline typically has a central whorl that blends seamlessly into the temples. The projected numbers from a 2-cm segment of tissue were as follows: 160 one-hair grafts, 400 two-hair grafts, 150 three-hair grafts, and 382 DFU grafts. The actual number of grafts that were yielded when number counts were completed were as follows: 160 one-hair, 361 two-hair, 236 three-hairs, and 483 DFUs. To fit the actual number count, additional DFU and 3-hair sites were made to accommodate the actual numbers yielded.

The patient returned over a year later with a suboptimal result. The density was insufficient and the hairline did not look sufficiently fine and natural in appearance. I have found that the use of punches at times can lead to more inconsistent growth due to partial vascular compromise. The decision was to remove part of the old scar (which measured 25 cm × 9.75 mm as mentioned above) within the shorter new scar measuring 10 cm × 10 mm. The goal was to achieve a denser and more natural hairline using a much larger number of 1-hair grafts (almost 4 times the number) and additional 2-hair grafts to achieve an improved outcome, as shown in Figure 4.4B. Figures 4.4C-E show close-up views of recipient-site patterns for female hairline design. To ensure that the number of recipient sites were precisely matched to the grafts dissected, no projected number was calculated but instead the yielded grafts were placed in a stick-and-place manner after all grafts were dissected. There were 503 one-hair grafts and 586 two-hair grafts, and the recipient sites were made to match those numbers precisely.

Rationale for Selection of This Case

This case was selected for a number of reasons. First, a female hairline is a unique entity that is completely different from a male hairline in design. Second, I believe that this case demonstrates the evolution of technique through a careful review of one's methods and how to improve on the results after an initial session that was less than satisfying. The reader is always encouraged to carefully review one's own

JAYPEE BROTHERS



Figures 4.3A to F

JAYPEE BROTHERS











Figures 4.3A to K

A 26-year-old woman is shown before surgery without a hairline drawn (A and E), before surgery with a drawn hairline (B, H, and J), after a single hair-transplant procedure (C and F), and after a second hair transplant (D, G, I, and K)

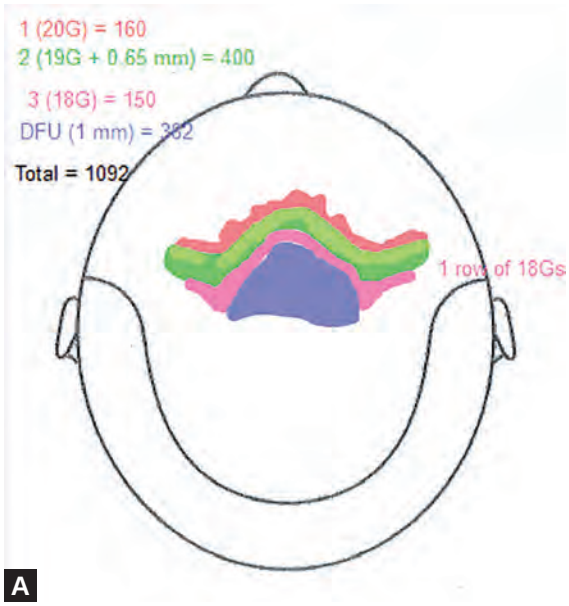

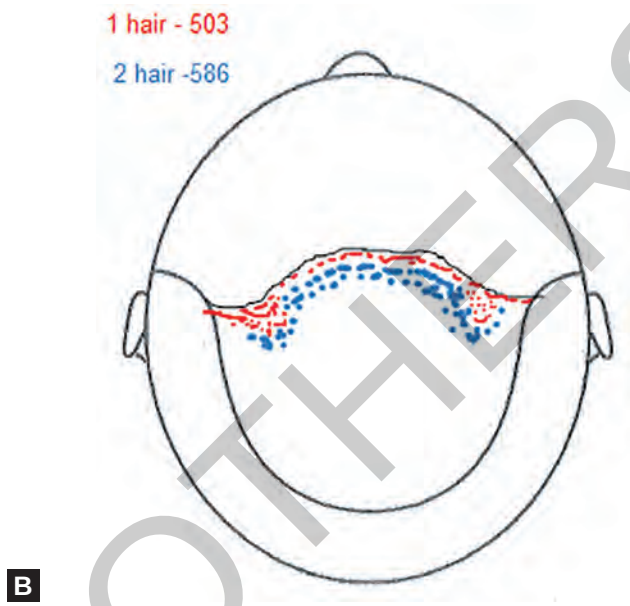

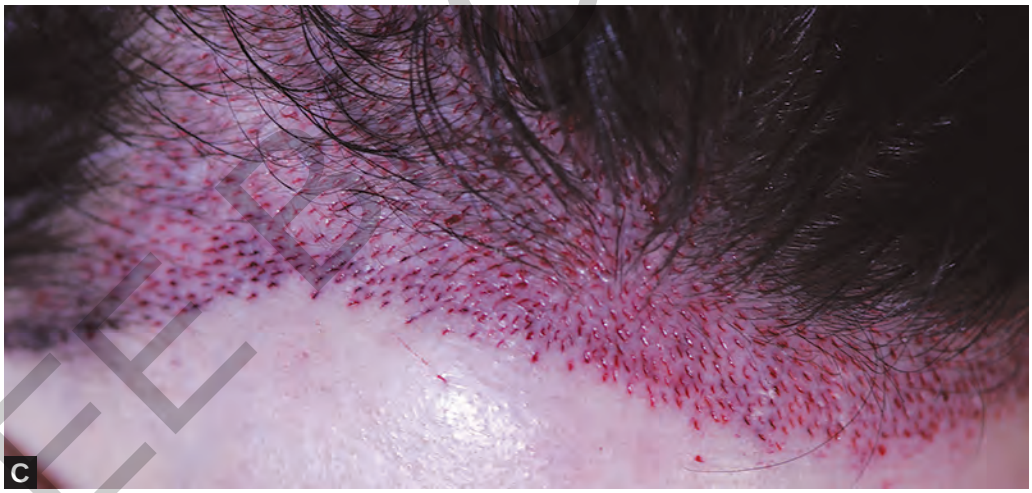

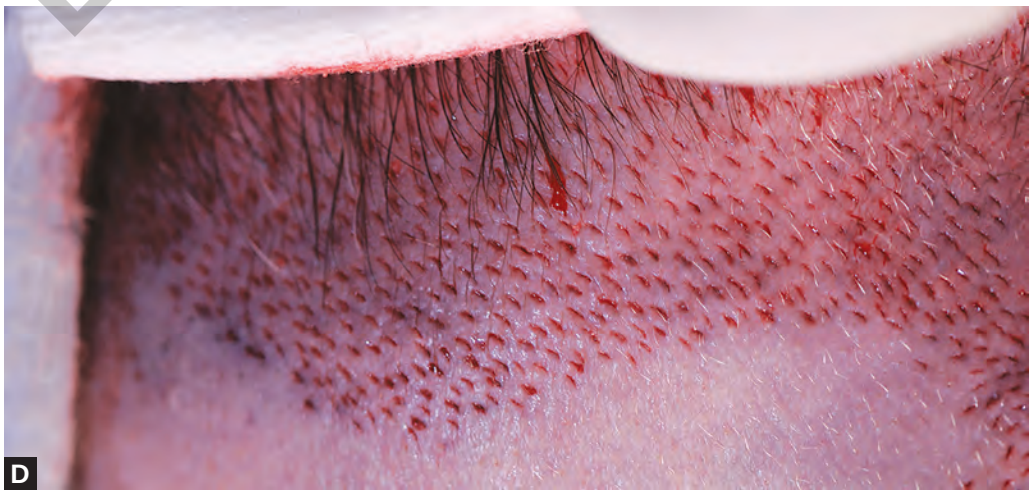

Figures 4.4A to D

JAYPEE BROTHERS

HAIR TRANSPLANT 360
for Physicians

This second edition of *Hair Transplant 360 (Vol. 1)* is completely revised and expanded, featuring extensive discussion on bioenhancement technology, including, Platelet-Rich Plasma (PRP), ACell Matristem Micromatrix, Liposomal ATP, etc. In addition, entirely new information on medical therapy is discussed in Chapter 1, including updates on finasteride, prostaglandins, female therapies, Low-Level Laser Therapy, etc. Operative techniques in Chapter 2 as well as Postoperative techniques in Chapter 3 have been further expanded and completely revised, and new case studies are presented in Chapter 4. Chapter 5 is a new chapter that teaches students the stepwise procedure of performing hairline design on human models and recipient-site creation on a melon. Videos have also been thoroughly revised and expanded.

Salient Features

- Understanding when it is safe and beneficial to operate and when to forgo the procedure (medical hair loss conditions, the dilemma of the young patient, scarring alopecia, etc.)
- Understanding Male and Female Pattern Baldness
- Medical Management of Hair Loss
- Hairline Design (principles, artistic, ethnic, and gender variations; step-by-step technique)
- Donor Harvesting (graft calculation, determining area for harvest, understanding and using different harvest techniques, when to perform a trichophytic closure; step-by-step technique)
- Recipient-site creation (basic principles: angles and distribution; regional considerations: male and female hairline, central forelock, midscalp, temple, lateral hump, and crown; step-by-step technique)
- Postoperative Care, Identifying and Managing Complications
- Creating Standardized Hair-Transplant Photography
- Leadership, Office Management, and Marketing
- Quality Control Algorithm for the Physician
- Case Studies, emphasizing creative approach to hair restoration
- 7 full-length videos covering every major aspect of hair surgery including hairline design, regenerative medicine preparation and execution, donor harvesting and closure, recipient-site creation (both sagittal and coronal methods), crown design, graft calculation and planning, and recipient-site practice on a melon model.

Samuel M Lam MD is author of seven prominent medical textbooks and over 250 scientific articles and book chapters. He lectures both nationally and internationally and runs a national course on hair restoration. He is triple board-certified and is a diplomate of the American Board of Hair Restoration Surgery, which he actively serves. He is a fellow member of and has chaired committees for the International Society of Hair Restoration Surgery (ISHRS). His clinical practice in Plano, Texas, USA is limited to facial plastic surgery and hair restoration.



Available at all medical bookstores
or buy online at www.jaypeebrothers.com

JAYPEE BROTHERS
Medical Publishers (P) Ltd.
www.jaypeebrothers.com

Join us on facebook.com/JaypeeMedicalPublishers

Shelving Recommendations
DERMATOLOGY, PLASTIC SURGERY & HAIR TRANSPLANTATION

ISBN 978-93-5250-038-3