ur website **www.jaypeebrothers.com,** for detailed information on cardiology books, visit our website **www.jaypeebrothers.com**



Essentials of Cardiovascular Examination

Sumesh Raj
Rajan GV

JAYPEE

Contents

Section–A Approach to the Patient 1–17

Chapter 1 The cardiac history 3

- Chief complaints 3
- Dyspnea 3
- Orthopnea 4
- Paroxysmal nocturnal dyspnea (PND) 4
- Angina pectoris 5
- Palpitation 6
- Syncope 7
- Hemoptysis 8

Chapter 2 General examination in relation to cardiovascular system (CVS) 9

- Head to foot examination 9

Chapter 3 Examination proforma 11

- General examination 11
- Examination of the cardiovascular system 11

Chapter 4 Anatomy of heart and coronary circulation 14

- Embryology of the heart 14
- Anatomy of the heart 14
- Coronary circulation 15
- Venous drainage of the heart 16
- Lymphatic drainage of the heart 16
- Nerve supply of the heart 16

Section–B Cardiovascular System 19–63

Chapter 5 Arterial pulse 21

- Importance 21
- Method of palpation of the right radial artery 21
- Assessment of arterial pulse 21
- Rhythm 23
- Pulse volume 24

- Pulse character 24
- Pulsus bisferiens 26
- Pulsus alternans 26
- Pulsus bigemini 27
- Pulsus trigemini 27
- Pulsus paradoxus 27
- Reverse pulsus paradoxus 28
- Condition of vessel wall 28
- Examination of peripheral pulses 29
- Radiofemoral delay 29
- Grading of the arterial pulsation 29

Chapter 6 Blood pressure 30

- Examination of blood pressure 30

Chapter 7 Jugular venous pulse and jugular venous pressure 32

- Jugular venous pressure 32
- Prerequisites in examination of JVP 32
- JVP as indicator of mean right atrial pressure 32
- Causes of elevated JVP 33
- Causes of fall in JVP 33
- Jugular venous pulse 34

Chapter 8 Inspection of precordium 37

Chapter 9 Palpation 39

- Apical impulse 39
- Causes of right ventricular enlargement 41

Chapter 10 Percussion of the heart 43

Chapter 11 Auscultation 44

Chapter 12 First heart sound (S_1) 46

Chapter 13 Second heart sound (S_2) 48

- Loud S_2 48
- Soft S_2 may be due to soft A_2 or soft P_2 48
- Single S_2 49

- Splitting of S_2 49
- Types of split S_2 50

Chapter 14 Third heart sound (S_3) 51

Chapter 15 Fourth heart sound (S_4) 52

- S_4—atrial contraction sound 52

Chapter 16 Ejection clicks 54

Chapter 17 Heart murmurs 56

- Systolic murmurs 57
- Diastolic murmurs 58
- Continuous murmur 59
- To and fro murmur (biphasic murmur) 61
- Systolic–diastolic murmur 62
- Innocent murmurs 62
- Functional murmurs 62
- Pansystolic murmur (PSM) 63

Section–C Cardiovascular system and related diseases 65–212

Chapter 18 Acute rheumatic fever (ARF) 67

Chapter 19 Infective endocarditis 72

- Acute endocarditis 72
- Prosthetic valve endocarditis (PVE) 73
- Endocarditis occurring among injection drug users 73

Chapter 20 Mitral stenosis (MS) 77

- Juvenile mitral stenosis 78
- Pulmonary edema 79
- Auscultation 79
- Atrial myxoma 82

Chapter 21 Mitral regurgitation (MR) 84

- Mitral regurgitation 84

Chapter 22 Aortic stenosis (AS) 88
- Bicuspid aortic valve disease 88
- Silent AS 90

Chapter 23 Aortic regurgitation (AR) 93
- Aortic valve involvement 93
- Murmur 95

Chapter 24 Tricuspid stenosis (TS) and tricuspid regurgitation (TR) 98
- Tricuspid stenosis (TS) 98
- When to entertain the diagnosis of TS 98
- Tricuspid regurgitation (TR) 99

Chapter 25 Pulmonary stenosis (PS) and pulmonary regurgitation (PR) 101
- Pulmonary stenosis (PS) 101
- Pulmonary regurgitation (PR) 102

Chapter 26 Pulmonary hypertension 104

Chapter 27 Mitral valve prolapse (MVP) 107
- Synonyms 107

Chapter 28 Atrial septal defect (ASD) 109

Chapter 29 Ventricular septal defect (VSD) 112
- Ventricular septal defect (VSD) 112

Chapter 30 Patent ductus arteriosus (PDA) 115

Chapter 31 Tetralogy of Fallot (TOF) 117

Chapter 32 Eisenmenger's syndrome 121

Chapter 33 Coarctation of the aorta 123
- Investigations 124
- Chest radiograph 125
- Doppler echocardiography 125

Chapter 34 Other congenital heart diseases 127
- Malpositions of the heart 127

- Total anomalous pulmonary venous connection (TAPVC) 128
- Partial anomalous pulmonary venous connection (PAPVC) 128

Chapter 35 Heart failure (HF) 132

- Classification of cardiac failure 132
- Right and left-sided heart failure and congestive cardiac failure 133
- Forward and backward heart failure 133
- Systolic and diastolic failure 133
- Left ventricular remodeling 134
- Paroxysmal nocturnal dyspnea (PND) 134
- Cheyne-stokes respiration 134
- Drugs for heart failure 138

Chapter 36 Pulmonary thromboembolism (acute cor pulmonale) 140

- Risk factors for deep vein thrombosis 140

Chapter 37 Cor pulmonale (pulmonary heart disease) 144

Chapter 38 Systemic hypertension 148

- Hypertensive crises 148
- Clinical presentation 150

Chapter 39 Ischemic heart disease 154

- Stable angina pectoris 154
- Asymptomatic (silent) ischemia 158

Chapter 40 ST-segment elevation myocardial infarction (STEMI) 159

- Serum cardiac biomarkers 161

Chapter 41 Unstable angina and non-ST-segment elevation myocardial infarction 168

- NSTEMI 168
- Prinzmetal's variant angina 171

Chapter 42 Arrhythmias 172
- Tachyarrhythmias 172
- Bradyarrhythmias 181

Chapter 43 Conduction disorders of the heart 185
- Right bundle branch block (RBBB) 185
- Left bundle branch block (LBBB) 186
- Hemiblocks (fascicular blocks) 187

Chapter 44 Pericardial diseases 189
- Pericarditis 189
- Cardiac tamponade 192
- Chronic constrictive pericarditis 193

Chapter 45 Myocarditis 195

Chapter 46 Cardiomyopathy 198
- Types of cardiomyopathy 198
- Dilated cardiomyopathy 198
- Restrictive (obliterative) cardiomyopathy 200
- Hypertrophic obstructive cardiomyopathy (HCM) 201

Chapter 47 Diseases of the aorta 203
- Aortic aneurysm 203
- Classification aneurysms 203
- Thoracic aortic aneurysms 204
- Abdominal aortic aneurysms 205
- Aortic dissection 206
- Aortitis 206

Chapter 48 Cardiac manifestations of systemic disease 209

Chapter 49 Neoplastic diseases of the heart 211
- Primary tumors 211
- Other benign tumors 212

Section–D Investigations in Cardiovascular System (CVS) 213–229

Chapter 50 The electrocardiogram 215
- ECG waveforms and intervals 215

Chapter 51 Noninvasive cardiac imaging 221

- Echocardiography 221
- Radionuclide imaging 222
- MRI/CT imaging 222

Chapter 52 Stress tests 224

Chapter 53 Cardiac catheterization 226

- Cardiac catheterization 226

Index 231

SECTION D

Investigations in Cardiovascular System (CVS)

50. The electrocardiogram
51. Noninvasive cardiac imaging
52. Stress tests
53. Cardiac catheterization

JAYPEE BROTHERS

Chapter

50 The Electrocardiogram

An electrocardiogram (ECG or EKG) is a graphic recording of electric potentials generated by the heart.

ECG Waveforms and Intervals (Fig. 50.1)

- 'P' wave represents atrial depolarization.
- The QRS complex represents ventricular depolarization.
- ST-T-U complex (ST-segment, 'T' wave and 'U' wave) represents ventricular repolarization.
- The J point is the junction between the end of the QRS complex and the beginning of the ST-segment.

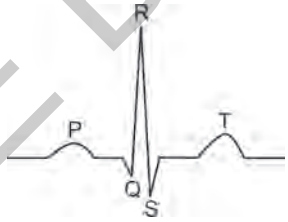

Fig. 50.1: Normal ECG

- ECG is recorded on graph paper that is divided into 1 mm^2 grid-like boxes.
- ECG paper speed is generally 25 mm/second.
- The smallest (1 mm) horizontal divisions correspond to 0.04 second (40 ms).
- With heavier lines at intervals of 0.20 second (200 ms).
- Vertically, the ECG graph measures the amplitude of a specific wave (1 mV =10 mm).
- There are four major ECG intervals: R-R, P-R, QRS and Q-T.
- The heart rate—1500/R-R interval in seconds.

JAYPEE BROTHERS

- P-R interval—The time (normally 120–200 ms) between atrial and ventricular depolarization.
- QRS interval (normally 100–110 ms) reflects the duration of ventricular depolarization.
- The Q-T interval includes both ventricular depolarization and repolarization times and varies inversely with the heart rate.
- Corrected Q-T interval, QTc, can be calculated as QT/R-R and normally is 0.44 second.
- If the initial QRS deflection in a particular lead is negative, it is termed a 'Q' wave;
- The first positive deflection is termed as 'R' wave.
- A negative deflection after an 'R' wave is an 'S' wave.
- An entirely negative QRS complex is termed a QS wave.

ECG Leads

- The 12 conventional ECG
- Six limb (extremity) leads
- Six chest (precordial) leads
- The limb leads record potentials transmitted onto the frontal plane
- The chest leads record potentials transmitted onto the horizontal plane

1. Lead V_1, fourth intercostal space, just to the right of the sternum.
2. Lead V_2, fourth intercostal space, just to the left of the sternum.
3. Lead V_3, midway between V_2 and V_4.
4. Lead V_4, midclavicular line, fifth left intercostal space.
5. Lead V_5, left anterior axillary line, same level as V_4.
6. Lead V_6, left midaxillary line, same level as V_4 and V_5.
7. Right precordial leads V_3R, V_4R, etc. detects evidence of acute right ventricular ischemia.

Electrical Axis

- It is determined from the frontal plane leads—I, II, III, aVR, aVL and aVF.
- It is quantified by using the hexaxial reference system (Fig. 50.2).
- The normal QRS axis shows a wide range of normality from –30° to +90°.
- Paired leads which are perpendicular to each other (lead I to aVF, lead II to aVL, lead III to aVR).
- Lead I and II show predominantly positive QRS complex—Normal axis.
- QRS complex predominantly positive in lead I and negative in lead III —Left axis.
- QRS complex predominantly positive in lead III and negative in lead I—Right axis.

JAYPEE BROTHERS

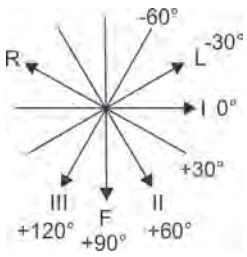

Fig. 50.2: Hexaxial reference system

- Left axis deviation is more negative than –30°.
- Right axis deviation is more positive than +90°.

Abnormalities

- Right atrial overload may lead to an increase in 'P' wave amplitude (2.5 mm).
- Left atrial overload produces a biphasic 'P' wave in V_1 with a broad negative component.
- Right ventricular hypertrophy—Tall 'R' wave in lead V_1, usually with right axis deviation.
- Left ventricular hypertrophy (LVH) by voltage criteria—SV_1 + (RV_5 or RV_6) >35 mm.
- Left ventricular "strain" pattern— ST depression + T inversion in lateral leads.

Acute Cor Pulmonale Due to Pulmonary Embolism

- Sinus tachycardia is the most common arrhythmia.
- Other tachyarrhythmias, such as atrial fibrillation or flutter, may occur.
- Right axis deviation.
- $S_1Q_3T_3$ pattern (prominence of the 'S' wave in lead I and the 'Q' wave in lead III, with 'T' wave inversion in lead III).

Bundle Branch Blocks

Wolff-Parkinson-White (WPW) syndrome

The diagnostic triad consists of

- Wide QRS complex associated
- Short P-R interval
- Slurring of the initial part of the QRS (delta wave).

Myocardial Ischemia and Infarction

- Acute infarction—ST elevations.
- Hyperacute infarction—Tall peaked 'T' waves.

JAYPEE BROTHERS

- Acute subendocardial ischemia—ST-segment depression.
- Acute transmural anterior wall infarction is reflected by ST elevations in one or more of the precordial leads (V_1–V_6) and leads I and aVL.
- Inferior wall ischemia produces changes in leads II, III and aVF.
- True posterior wall MI – R/S ratio more than 1 in V_1, upright T and ST depressions in leads V_1 – V_3.
- Right ventricular ischemia usually produces ST elevations in right-sided chest leads—V_3R and V_4R.
- ST elevations are the earliest sign of acute infarction, followed by evolving 'T' wave inversions and often by 'Q' waves.
- Reversible transmural ischemia due to coronary vasospasm—Prinzmetal's variant angina may cause transient ST-segment elevations without development of 'Q' waves.
- Pseudonormalization—Patients whose baseline ECG already shows abnormal 'T' wave inversions may develop 'T' wave normalization during episodes of acute transmural ischemia.
- Wellens 'T' waves—Prominent 'T' wave inversions in the precordial leads in severe anterior wall ischemia.
- 'Q' wave infarction—Transmural infarction.
- Non-'Q' wave—Subendocardial (nontransmural) infarction.

Brugada Pattern (Fig. 50.3)

- Right bundle branch block-like pattern
- ST elevations in right precordial leads.

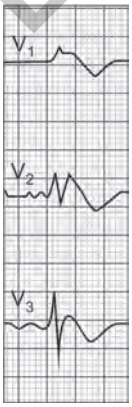

Fig. 50.3: Brugada pattern in ECG

Hyperkalemia (Fig. 50.4)

- Tall, narrow peaked (tenting) of the 'T' waves.
- Widening of the QRS interval.
- Severe hyperkalemia eventually causes cardiac arrest with a 'sine wave' pattern followed by asystole.

JAYPEE BROTHERS

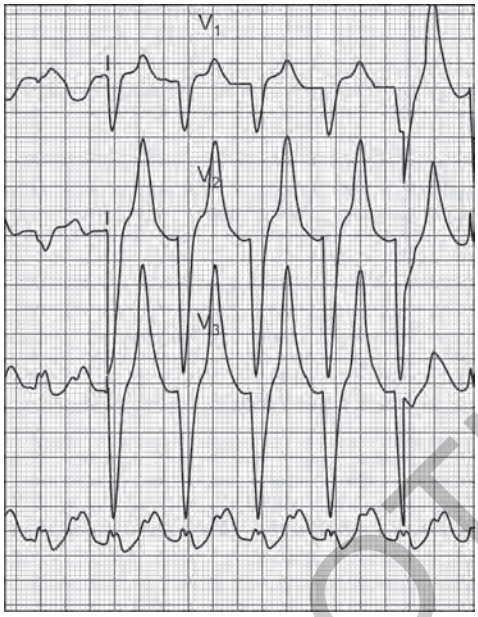

Fig. 50.4: ECG in hyperkalemia

Hypokalemia (Fig. 50.5)

- Prominent 'U' waves.
- Prolongation of the Q-T interval.

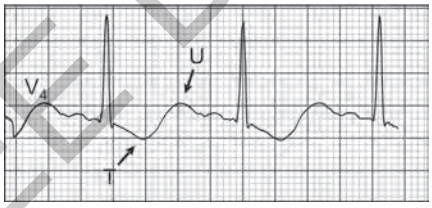

Fig. 50.5: ECG in hypokalemia

- **Systemic hypothermia**—Convex elevation of the J point (Osborn wave) (Fig. 50.6).
- Hypocalcemia—Prolongs the Q-T interval

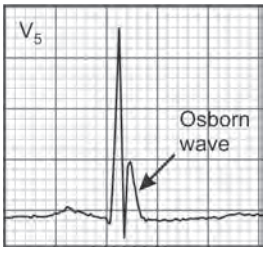

Fig. 50.6: Osborn wave in ECG

JAYPEE BROTHERS

- Hypercalcemia—Shortens the Q-T interval
- Digitalis effect—Digitalis shorten the Q-T interval with "scooping"of ST–T wave complex.

Electrical Alternans (Fig. 50.7)

- A beat-to-beat alternation in one or more components of the ECG signal.
- Seen in pericardial effusion, usually with cardiac tamponade.

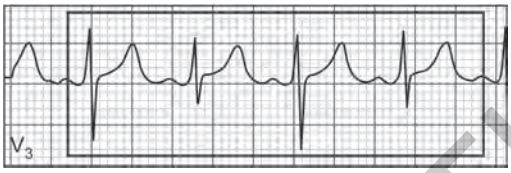

Fig. 50.7: ECG in electrical alternans

JAYPEE BROTHERS

Chapter

51 Noninvasive Cardiac Imaging

Echocardiography

- Two-dimensional (2D) echocardiography is able to visualize the heart directly in real time using ultrasound, providing instantaneous assessment of the myocardium, cardiac chambers, valves, pericardium and great vessels.
- Doppler echocardiography measures the velocity of moving red blood cells and has become a noninvasive alternative to cardiac catheterization for assessment of hemodynamics.
- Transesophageal echocardiography (TEE) provides a unique window for high-resolution imaging of posterior structures of the heart, particularly the left atrium, mitral valve and aorta.

2D Echocardiography

- It is the "gold standard" for imaging valve morphology and motion.
- The imaging modality of choice for the detection of pericardial effusion.
- Intracardiac masses can be visualized on 2D echocardiography.
- It can provide extremely useful information on diseases of the aorta.

Doppler Echocardiography

- Doppler can be used to determine the pressure gradient across the valve.
- Valvular regurgitation is diagnosed by Doppler echocardiography when there is abnormal retrograde flow across the valve. Color-flow imaging is the Doppler method used.
- Intracardiac pressures can be calculated.
- Stroke volume and cardiac output can be reliably measured.
- Noninvasive evaluation of ventricular diastolic filling.

2D and Doppler echocardiography have been useful in the evaluation of patients with congenital heart disease.

JAYPEE BROTHERS

Ejection fraction (EF)

- Represents the volume of blood pumped out of the left ventricle with each cardiac cycle.
- EF = Stroke volume/end diastolic volume × 100.
- Normal EF= 55–75%.

Stress Echocardiography

- 2D and Doppler echocardiography are usually performed with the patient in the resting state. Further information can be obtained by reimaging during either exercise or pharmacologic stress.
- The primary indications for stress echocardiography are to confirm the suspicion of ischemic heart disease and determine the extent of ischemia.
- Dobutamine echocardiography has also been used to assess myocardial viability in patients with poor systolic function.

Transesophageal Echocardiography

- Diseases of the aorta, such as aortic dissection, can be readily diagnosed by TEE.
- Defining the source of embolism is a common indication for TEE.
- The presence of vegetations for the diagnosis of infective endocarditis can be assessed by TEE.

Radionuclide Imaging

- This is uses of radioactive tracers to provide assessment of myocardial perfusion and metabolism, along with ventricular function.
- This is applied primarily to the evaluation of patients with ischemic heart disease.
- The two most commonly used technologies are single-photon emission computed tomography (SPECT) and positron emission tomography (PET).
- Assessment of myocardial perfusion and coronary artery disease—The most commonly used SPECT perfusion tracers are thallium-201 and technetium-99 labeled isonitriles.
- Assessment of myocardial metabolism and viability by PET scans.
- Assessment of ventricular function.

MRI/CT Imaging

- Cardiac MRI and CT scan can delineate cardiac structure and function with high resolution.

JAYPEE BROTHERS

- They are useful in the examination of cardiac masses, the pericardium, the great vessels and ventricular function and perfusion.
- Gadolinium enhancement during cardiac MRI adds information on myocardial perfusion.
- Detection of coronary calcification by CT as well as direct visualization of coronary arteries by CT angiography (CTA) may be useful in selected patients with suspected coronary artery disease (CAD).

JAYPEE BROTHERS

Chapter

52

Stress Tests

Definition

- Exercise testing is a cardiovascular stress test that uses treadmill bicycle exercise with electrocardiography (ECG) and blood pressure monitoring.
- Pharmacologic stress testing is a diagnostic procedure in which cardiovascular stress induced by pharmacologic agents like dobutamine
- Pharmacologic stress testing is used patients with decreased functional capacity or in patients who cannot exercise.
- Pharmacologic stress testing is used in combination with imaging modalities such as radionuclide imaging and echocardiography.
- Treadmill stress testing is indicated for diagnosis and prognosis of cardiovascular disease, specifically CAD.

Contraindications for Stress Testing

- Acute myocardial infarction within 2 days
- Unstable angina not previously stabilized by medical therapy
- Uncontrolled cardiac arrhythmias causing hemodynamic compromise
- Symptomatic severe aortic stenosis
- Symptomatic heart failure
- Acute pulmonary embolus or pulmonary infarction
- Acute myocarditis or pericarditis
- Acute aortic dissection.

Treadmill Protocol

- The standard Bruce protocol, includes 3 minute periods to allow achievement of a steady state before workload is increased.

JAYPEE BROTHERS

- The modified Bruce protocol is most often used in older individuals or those whose exercise capacity is limited by cardiac disease.

Interpretation of Test Findings

- Interpretation should include exercise capacity and clinical, hemodynamic and ECG response.
- The occurrence of ischemic chest pain consistent with angina is important, particularly if it forces termination of the test.
- Positive stress test means an ST depression more than 1 mm.

JAYPEE BROTHERS

for detailed information on cardiology books, visit our website **www.jaypeebrothers.com,** for detailed information on cardiolog

Essentials of
Cardiovascular Examination

The purpose of this *Essentials of Cardiovascular Examination* is to provide both undergraduate and postgraduate students, interns and practising physicians a solid background in cardiac physical examination. The physical diagnosis is extensively dealt with so as to enable a student for in-depth study and to approach the examination with ease. Basic cardiovascular anatomy and physiology are also dealt with. All the common cardiovascular diseases and their investigation and treatment updates are also included to enable the use of this book as a ready-reckoner reference for practising physicians.



Sumesh Raj MD is presently Associate Professor in Internal Medicine in Sree Gokulam Medical College, Thiruvananthapuram, India. He completed both MBBS and MD in Internal Medicine from Government Medical College, Thiruvananthapuram. He did his postgraduation in Diabetology from Vinayaka Missions University. He has more than a decade of teaching experience. He is an examiner for both undergraduate and postgraduate students in University of Kerala and Kerala University of Health Sciences. He is a research guide for postgraduate students in Kerala University of Health Sciences. He is a Life Member of Association of Physicians of India (API), Research Society for Study of Diabetes in India (RSSDI) and Indian Medical Association (IMA). He has several research publications in national and international journals. He is American Diabetes Association certified Diabetologist.



Rajan GV BSc MD has three decades of teaching experience in Government Medical College, Thiruvananthapuram, India, from where he retired as Professor and Head of the Department of Internal Medicine. He completed his MBBS from Government Medical College, Thiruvananthapuram and MD in Internal Medicine from Maulana Azad Medical College, New Delhi. He has been examiner for both undergraduate and postgraduate students in University of Kerala and other universities. He has been a research guide for postgraduate students. He has been examiner and teacher in Internal Medicine for dental students. He has several research publications to his credit. He is presently Senior Consultant in Cosmopolitan Hospital, Thiruvananthapuram.

Available at all medical bookstores
or buy online at www.jaypeebrothers.com

JAYPEE BROTHERS
Medical Publishers (P) Ltd.
www.jaypeebrothers.com

Join us on facebook.com/JaypeeMedicalPublishers

Shelving Recommendation
CARDIOLOGY

ISBN 978-93-5250-042-0