rothers.com, for detailed information on dental books, visit our website www.jaypeebrothers.com, for detailed information on de



Exam Preparatory Manual for Undergraduates

Pathology *for* Dental Students

Ramadas Nayak

Foreword
Yenepoya Abdulla Kunhi

Contents

SECTION 1: THEORY

1. Introduction **3**
Normal Cell Structure and Functions 3
Introduction to Pathology 6

2. Cell Injury **9**
Types of Cellular Responses to Injury 9
Cellular Adaptations 9
Cell Injury 15
Necrosis 24
Apoptosis 30
Pathologic Calcification 35
Hyaline Change 37
Pigments 38

3. Inflammation **41**
Acute Inflammation 41
Causes of (Stimuli for) Acute Inflammation 42
Sequence of Events in Acute Inflammation 43
Reactions of Blood Vessels (Vascular Changes) 43
Leukocytic/Cellular Events 46
Chemical Mediators of Inflammation 50
Cell-derived Mediators 51
Plasma-derived Mediators 55
Outcomes of Acute Inflammation 58
Morphological Types/Patterns of Acute Inflammation 59
Systemic Effects of Inflammation 61
Chronic Inflammation 62
Granulomatous Inflammation 64
Giant Cell 66

4. Repair **67**
Healing 67
Cell Cycle and Cell Proliferation 68
Healing by Repair, Scar Formation and Fibrosis 69
Cutaneous Wound Healing 71
Factors that Influence Wound Healing 74
Complications of Wound Healing 75
Healing of a Fracture 76

5. Immunity **80**
Immunity 80
Cells of the Immune System 82
Cytokines 84
Hypersensitivity: Immunologically Mediated Tissue Injury 85
Type I (Immediate) Hypersensitivity 86
Antibody-mediated (Type II) Hypersensitivity 89
Immune Complex–mediated (Type III) Hypersensitivity 93
T Cell-mediated (Type IV) Hypersensitivity 96
Autoimmune Diseases 98
Systemic Lupus Erythematosus (SLE) 99
Major Histocompatibility Complex (MHC) Molecules 103
Acquired Immunodeficiency Syndrome (AIDS) 105
Amyloidosis 111

6. Infections **120**
Granulomatous Diseases 120
Tuberculosis 120
Leprosy 129
Syphilis 134
Typhoid Fever 139
Viral Hepatitis 142
Chronic Hepatitis 148
Actinomycosis 149

7. Hemodynamic Disorders **151**
Hyperemia and Congestion 151
Edema 155
Thrombosis 160
Embolism 166
Infarction 173
Shock 175

8. Nutritional Disorders **183**
Common Vitamin Deficiencies 183
Fat-soluble Vitamins 184
Water-soluble Vitamins—Vitamin B Complex 193

9. Hypertension **198**
Hypertension 198

10. Diabetes Mellitus **203**
Diabetes Mellitus 203
Type 1 Diabetes (T1D) 204
Type 2 Diabetes (T2D) 206
Pathogenesis of the Complications of Diabetes 207

11. Neoplasia **216**
Classification 217
Nomenclature of Neoplasms 218
Characteristics of Benign and Malignant Neoplasms 221
Carcinoma In Situ 226
Metastasis 227
Precancerous Conditions/Lesions 229
Molecular Basis of Cancer 230
Steps in Normal Cell Proliferation 231
Hallmarks of Cancer 232
Etiology of Cancer (Carcinogenic Agents) 238
Laboratory Diagnosis of Cancer 245
Clinical Aspects of Neoplasia 249
Paraneoplastic Syndromes 250
Prognosis 250
Common Specific Epithelial Tumors 252
Mesenchymal Tumors 260

12. Hematology **264**
Disorders of Red Cells 264
Anemia 264
Iron Deficiency Anemia 267
Megaloblastic Anemia 270
Pernicious Anemia 273
Aplastic Anemia 275
Hereditary Defects in Hemoglobin 276
β-Thalassemia Major 277
Sickle Cell Anemia 280
Disorders of White Cells 283
Normal Differential Leukocyte Count (DLC) 283
Quantitative Disorders of Leukocytes 283
Acute Leukemia 286
Acute Lymphoblastic Leukemia/Lymphoma 288
Acute Myelogenous Leukemia 291
Chronic Myelogenous Leukemia 293
Chronic Lymphocytic Leukemia 296
Disorders of Hemostasis 298
Normal Hemostasis 298
Classification of Hemostatic Disorders 298
Immune Thrombocytopenic Purpura 300
Coagulation Disorders 302
Hereditary Coagulation Disorders 303
Hemophilia 303
Acquired Coagulation Disorders 306

13. Lymph Nodes **308**
Lymphoid Neoplasms 308
Non-Hodgkin Lymphoma 309
Hodgkin Lymphoma 313
Metastatic Carcinoma 320

14. Oral Cavity **321**
Lichen Planus 321
Stomatitis 322
Precancerous Lesions of Oral Cavity 322
Squamous Cell Carcinoma 323
Odontogenic Cysts 326
Odontogenic Tumors 326

15. Salivary Glands **328**
Salivary Glands 328
Salivary Gland Neoplasms 330
Pleomorphic Adenoma 331
Warthin Tumor 333
Mucoepidermoid Carcinoma 333

16. Bone **335**
Infections—Osteomyelitis 335
Osteoporosis 339
Bone Tumors 340

17. Cardiovascular System **351**
Congenital Heart Disease 351
Left-to-Right Shunts 353
Right-to-Left Shunts 356
Heart Failure 357
Infective Endocarditis 358
Atherosclerosis 364
Ischemic Heart Disease 370
Angina Pectoris 372
Myocardial Infarction (MI) 372

SECTION 2: PRACTICALS

18. Urine Analysis **383**
Physical Examination 383
Chemical Examination 385

19. Hematology **394**
Hemoglobin Estimation 394
Cell Count 398
Hematocrit 403
Erythrocyte Sedimentation Rate 405

Blood Grouping 407
Peripheral Smear Staining 412

20. Tests for Bleeding Disorders **419**
Tests for Bleeding Disorders 420

21. Histopathology **423**
Tissue Processing and Staining 423
Frozen Section Techniques 424
Histopathology Slides 425

22. Blood Transfusion **432**
Blood Transfusion 432
Blood Components 433
Transfusion Reactions 434

Appendices **437**
Appendix 1. Terminologies 437
Appendix 2. Stages of Erythropoiesis 444
Appendix 3. Stages of Myelopoiesis 445
Appendix 4. Stages of Megakaryopoiesis 446

Index 447

Chapter 4

Repair

Chapter Outline

- Introduction
- Healing
- Cell cycle and cell proliferation
- Healing by repair, scar formation and fibrosis
- Cutaneous wound healing
- Factors that influence wound healing
- Complications of wound healing
- Healing of a fracture

INTRODUCTION

Q. Define the term healing, regeneration and repair.

Injury to cells and tissues **results in loss of cells and tissues.** It sets in inflammation (restrict the tissue damage) and initiate replacement of lost tissue by living tissue.

HEALING

Definition: Healing is a process of replacement of dead tissue by living tissue.
It can be broadly divided into regeneration and repair.

1. **Regeneration**:

Definition: Regeneration is a process in which **lost tissue is replaced by tissue of similar type**. It results in the complete restoration of lost or damaged tissue by proliferation of residual uninjured cells and replacement from stem cells.

2. **Repair**:

Definition: Repair is defined as a process in which **lost/damaged tissue is replaced by fibrous tissue or scar.**

Repair is often used for parenchymal and connective tissues and *healing* for surface epithelia. However, these terms are used interchangeably.

Factors Deciding the Pattern of Healing

The proportion of regeneration and repair process in healing depends on:

Proliferative Capacity of the Tissue

According to proliferative capacity of the cells, the tissues of the body can be divided into three groups:

JAYPEE BROTHERS

1. **Labile (continuously dividing) tissues**: The cells of labile tissues proliferate throughout life, replacing the lost cells from stem cells. Examples:
   - Hematopoietic cells of the bone marrow
   - Surface epithelia of the skin, oral cavity, vagina, and cervix
   - Columnar epithelium of the GI tract and uterus.
2. **Stable (quiescent) tissues**: Cells of stable tissue normally do not proliferate; but can **proliferate in response to injury or loss of tissue.** Examples:
   - **Parenchymal cells** of **liver**, kidneys, and pancreas
   - **Mesenchymal cells:** Fibroblasts, vascular endothelial cells, smooth muscle cells, chondrocytes, and osteocytes.
3. **Permanent (nondividing) tissues**: Cells of these tissues **cannot proliferate after birth**. In these tissues, repair is by scar formation. Example:
   - **Neurons: Damaged neurons** are **replaced by** the proliferation of the **glial cells**
   - **Skeletal muscle** cells
   - **Cardiac muscle** cells.

Extent of Tissue Injury

- **Mild and short duration**: The damaged tissue is healed by regeneration without significant scarring.
- **Severe and chronic**: Healing occurs by fibrous tissue forming scar.
  - Severe tissue injury damages both parenchymal cells and the extracellular matrix (ECM) framework
  - Chronic inflammation.

CELL CYCLE AND CELL PROLIFERATION

- Inflammation is the primary response of living tissue to injury.
- With inflammation, there will be damage or loss of tissue, which has to be replaced by living tissue. This replacement is done by transient increase in cellularity due to proliferation of cells by either regeneration and/or by repair.
- Proliferation of cells is characterized by DNA replication and mitosis. The sequence of events that control DNA replication and mitosis is known as the **cell cycle**.

Definition of cell cycle: Cell proliferation is a regulated process, which involves activators and inhibitors, as well as checkpoints.

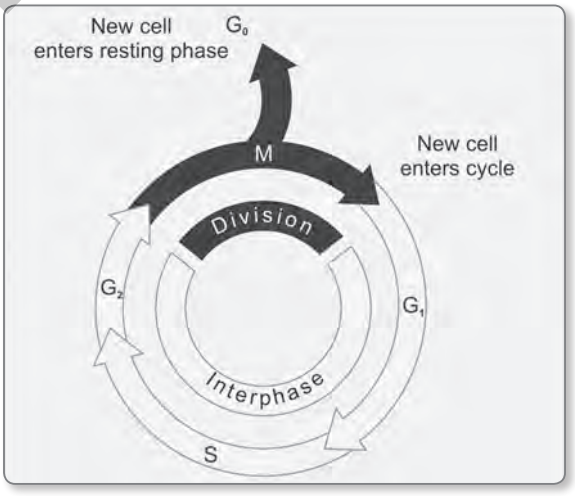

Fig. 4.1: Cell cycle showing different phases (G_0, G_1, G_2, S, and M). Cells from labile tissues (e.g. epidermis) may remain in cycle continuously; stable cells (e.g. liver cells) are quiescent but can enter the cell cycle; permanent cells (e.g. neurons) have lost the capacity to proliferate and cell cycle arrests in the G_1 phase or exit the cycle and are in G_0 phase

Phases of Cell Cycle (Fig. 4.1)

- G_1 (presynthetic)
- S (DNA synthesis)
- G_2 (premitotic)
- M (mitotic) phase.

JAYPEE BROTHERS

Checkpoints: They checks whether there is any damage to DNA and chromosomes in the replicating cells. These checkpoints make sure that only normal cells complete replication. There are two checkpoints:

1. G_1/S checkpoint monitors the integrity of DNA before replication.
2. G_2/M checkpoint checks DNA after replication and monitors whether the cell can safely enter mitosis.

HEALING BY REPAIR, SCAR FORMATION AND FIBROSIS

Healing may be either by **regeneration or repair or combination of both.** With mild and transient injury, there is regeneration. If the tissue injury or damage persists, inflammation becomes chronic, resulting in excessive deposition of connective tissue known as **fibrosis** (repair).

Steps in Healing by Repair (Scar Formation)

Inflammation

Whenever there is tissue injury, inflammatory reaction begins, which tries to limit the damage and remove the injured tissue. At the same time, it also promotes the deposition of ECM components at the site of injury and stimulates angiogenesis.

Angiogenesis

Definition: Angiogenesis is the process of formation of new blood vessels from existing vessels. It supplies nutrients and oxygen needed to support the repair process. These vessels are leaky because of incomplete interendothelial junctions and VEGF (the growth factor responsible for angiogensesis).

Steps in angiogenesis (Figs 4.2A to D):

- **Vasodilatation** in response to nitric oxide and **increased permeability of the pre-existing vessel due** to VEGF.

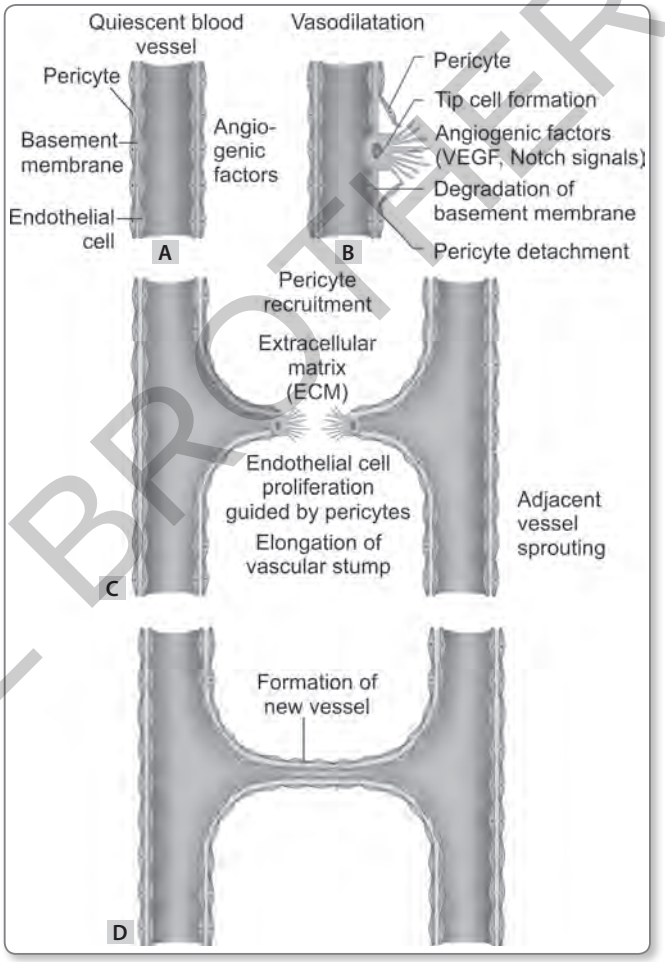

Figs 4.2A to D: Mechanism of angiogenesis. A. Normal blood vessel; B. **Vasodilatation**: First, pericytes separate followed by mobilization and proliferation of endothelial cells from the existing vessel to form capillary sprouts towards the site of injury (angiogenic stimuli); C. Endothelial cells proliferate, loosely following each other, and are presumably guided by pericytes. Maturation of vessel (stabilization) involves the recruitment of pericytes and smooth muscle cells to form the periendothelial layer; D. Finally, blood-vessel sprouts will fuse with other sprouts to build new circulatory systems

JAYPEE BROTHERS

- **Separation of pericytes** from the outer surface of blood vessel and breakdown of the basement membrane. This allows formation of a vessel sprout.
- **Migration and proliferation of endothelial cells** toward the site of injury.
- **Maturation of endothelial cells** into capillary sprouts/tubes.
- **Formation of mature vessel:** It involves recruitment of pericytes and smooth muscle cells to form the periendothelial layer.
- **Suppression of endothelial proliferation** and migration, and deposition of basement membrane.

Formation of Granulation Tissue

Q. Write short note on granulation tissue.

The first 24 to 72 hours of the repair process begins with proliferation of fibroblasts and vascular endothelial cells. It forms a **specialized type of tissue** known as **granulation tissue**, which is a **hallmark/characteristic of tissue repair**. The term granulation tissue is derived from its pink, soft, granular appearance on the surface of healing wounds.

- **Microscopy** (Figs 4.3A and B): Its characteristic features are:
  - Presence of **new small blood vessels** (angiogenesis): The new blood vessels are **leaky**, which allow the passage of plasma proteins and fluid into the extravascular space, which is responsible for edema often seen in granulation tissue.
  - **Proliferation of fibroblasts.**
- **Amount** of granulation tissue formed depends on the:
  - **Size of the tissue deficit** created by the wound
  - **Intensity of inflammation**.

Scar Formation

- The leukocytes, edema, and angiogenesis disappear, accomplished by the **increased accumulation of collagen.** The **granulation tissue scaffolding is converted into a pale, avascular scar.**
- **Components of scar:** It is composed of spindle-shaped fibroblasts, dense collagen, fragments of elastic tissue, and other ECM components.
- **By the end of the first month,** the scar consists of acellular connective tissue without inflammatory infiltrate.

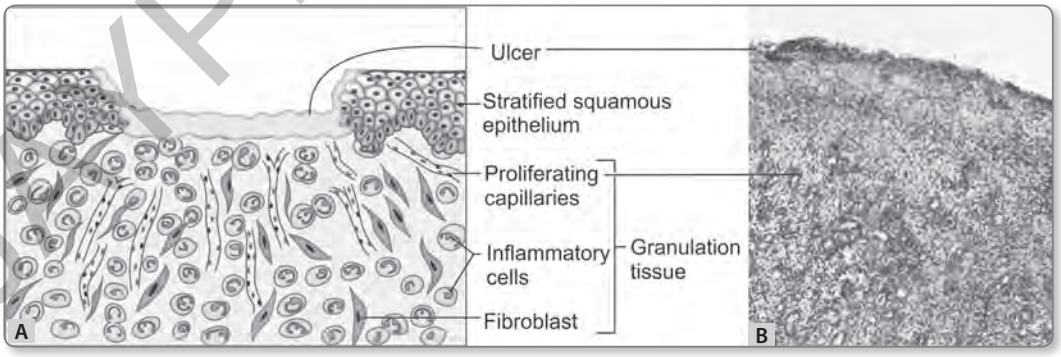

Figs 4.3A and B: Granulation tissue consisting of numerous blood vessels, fibroblasts and edema. A. Diagrammatic; B. Hematoxylin and eosin

(For color version, see Plate 2)

JAYPEE BROTHERS

Connective Tissue Remodeling

- Remodeling of the connective tissue framework is an important feature. It is the long-lasting phase of tissue repair.
- Remodeling indicates that the equilibrium/balance between ECM synthesis (collagen deposition) and degradation has been restored.

CUTANEOUS WOUND HEALING

Q. Describe the healing of a clean surgical wound/ healing by first intention.

Healing by Primary Union or by First Intention

Definition: Healing of a **clean, uninfected surgical incision** in the skin joined with surgical sutures is known as healing by **primary union or by first intention**.

Surgical incision causes **death of a minimum number** of epithelial and connective tissue **cells.** The **disruption of epithelial basement membrane** continuity is also **minimal**. Re-epithelialization occurs by regeneration and there is a **relatively thin scar**. This is simplest type of cutaneous wound healing.

Stages in the Healing by First Intention (Figs 4.4A to D)

- **First 24 hours:**
  - **Formation of blood clot**: It is formed in the space between sutured margins. Blood clot contains not only trapped red cells but also fibrin, fibronectin and complement components. Clot stops bleeding and acts as a scaffold for migrating and proliferating cells. **Dehydration at the external surface of the clot** leads to formation of a **scab** over the wound.
  - **Neutrophil infiltration**: Within 24 hours of wound, **neutrophils** appear at the margins of the incision. Neutrophils use the scaffold produced by the fibrin clot for its migration. They **release proteolytic enzymes which clean out debris**.
  - **Epithelial changes:** At the cut edges of the wound, the **basal cells of the epidermis** begin to show **mitotic activity**. Epithelial cells from both the edges of wound proliferate and migration across the wound along the dermis.
- **Two days:**
  - **Neutrophils are replaced by macrophages**.
  - The **epithelial cells fuse in the midline below the surface scab** and epithelial continuity is re-established in the form of a thin continuous surface layer.
- **Three to seven days**:
  - **Granulation tissue** begins to invade incision space. It progressively grows into the **incision space/wound and fills the wound area** by 5 to 7 days. Collagen is progressively laid down.
  - **Surface epidermis** achieves its **normal thickness** and differentiation. It matures with surface keratinization.
  - Acute **inflammatory response** begins to **subside**.
- **Ten to fourteen days**:
  - Leukocytic infiltration, edema, and angiogenesis disappear during the second week.
  - **Increased accumulation of collagen** and **regression of vascular channels**. The **granulation tissue scaffolding is converted into a pale, avascular scar.** Wound normally gains about 10% strength of normal skin. Further fibroblast proliferation occurs with collagen deposition.

JAYPEE BROTHERS

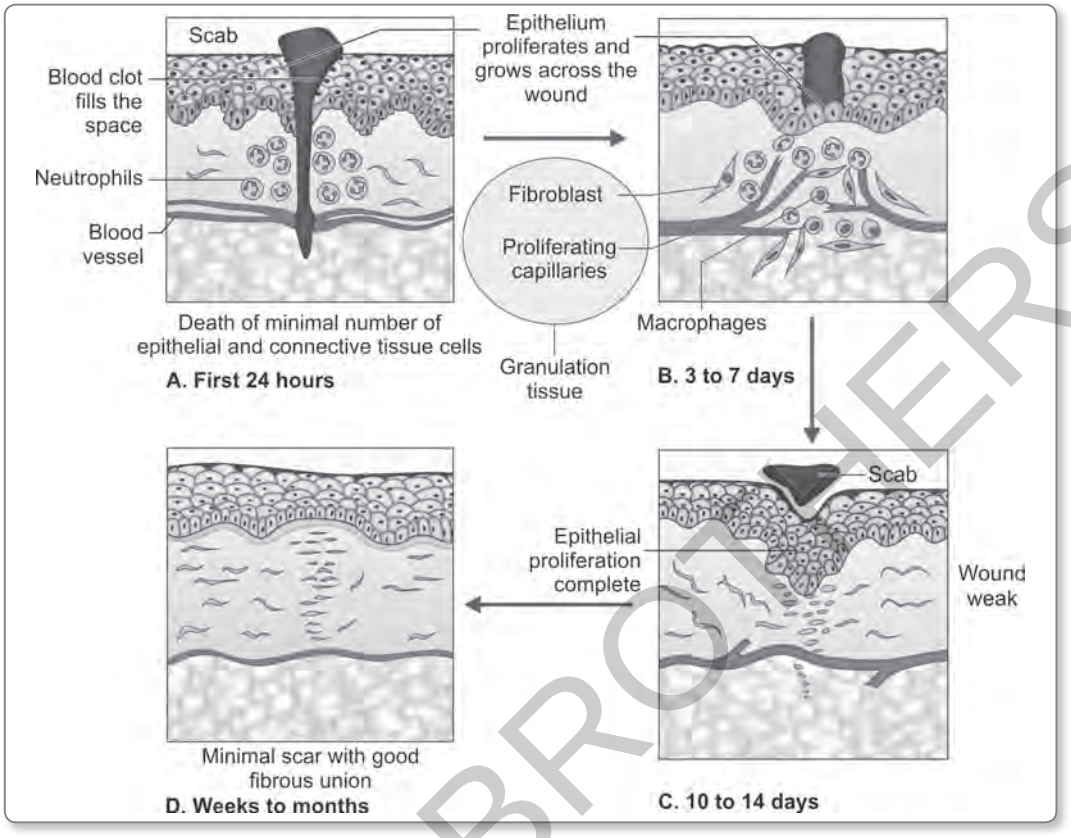

Figs 4.4A to D: Healing by primary intention. A. A wound with closely apposed edges and minimal tissue loss. The blood clots and fills the gap between the edges of the wound; B. Epithelium at the edges proliferates. Minimal amount of granulation tissue is formed; C. The epithelial proliferation is complete and the wound is weak; D. Fibrosis with a small scar

- **Weeks to months:**
  - The **scar** appears as **acellular** connective tissue covered by intact epidermis and without inflammatory infiltrate.
  - Collagen deposition along the line of stress and **wound gradually achieves maximal 80% of tensile strength** of normal skin.

Healing by Secondary Union or by Second Intention

Q. Describe the mode of healing of wound by second intention.

Definition: When injury produces **large defects** on the skin surface with **extensive loss of cells and tissue**, the healing process is more complicated. Healing in such cutaneous wound is referred to as healing by **secondary union or by second intention.**

Features of Healing by Secondary Intention (Figs 4.5A to D)

Q. Mention the differences between healing by first intention and second intention.

- Larger wounds show **more exudate and necrotic tissue**. The **clot or scab** formed at the surface of wound is **large**. Full epithelialization of the wound surface is slow because of the larger gap.

JAYPEE BROTHERS

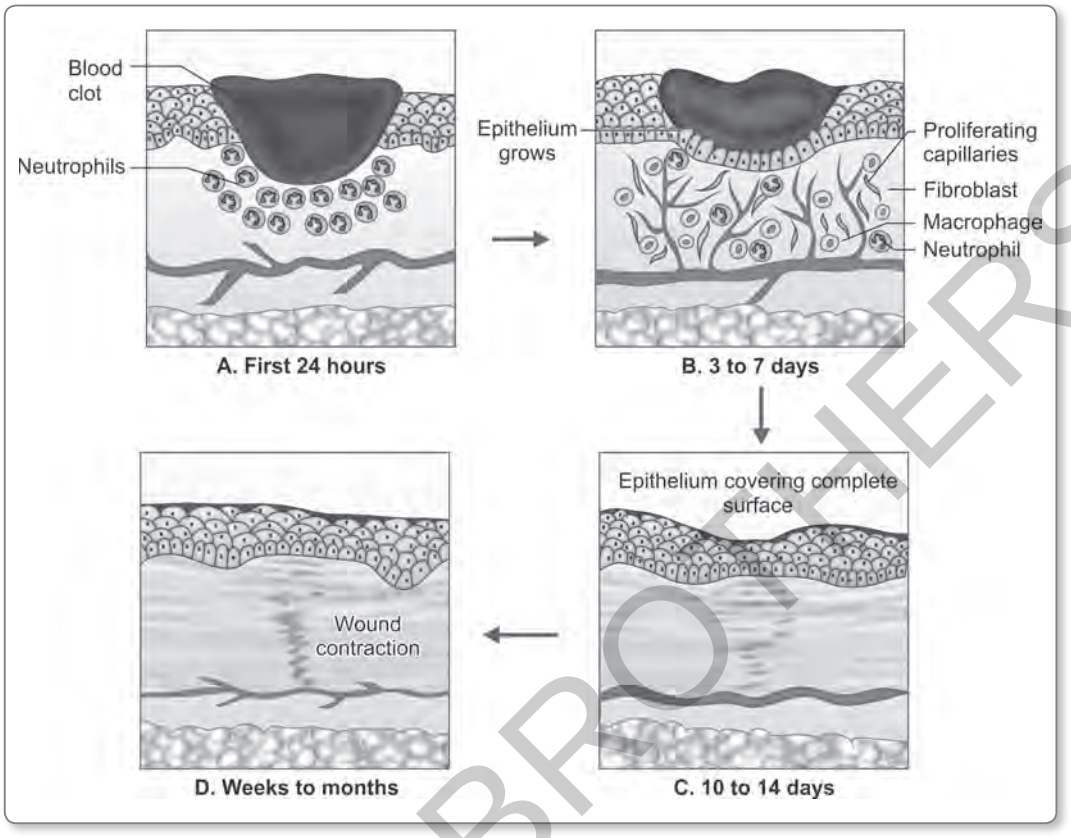

Figs 4.5A to D: Healing by secondary intention. A. There is significant loss of tissue and the edges are far apart. Acute inflammation develops both at the edges and base; B. The cell proliferation starts from the edges and large amount of granulation tissue is formed; C. The wound is covered on the entire surface by the epithelium. The collagen fibers are deposited; D. Granulation tissue is replaced by a large scar. There is significant wound contraction

- **Severe inflammatory reaction** because of larger defect and greater necrotic tissue.
- The **larger defect requires more** amount of (abundant) **granulation tissue**.
- Extensive deposition of collagen with substantial scar formation.
- **Wound contraction:** Wound contraction generally occurs in large surface wounds and is an important feature in healing by secondary union.

Myofibroblasts of granulation tissue **have ultrastructural features of smooth muscle cells**. They contract in the wound tissue and are responsible for wound contraction.

Wound Strength

Major portion of the connective tissue in repair is fibrillar collagens (mostly type I collagen) and are responsible for the development of strength in healing wounds.

Time for a skin wound to achieve its maximal strength

- **At the end of the first week:** When sutures are removed from an incisional surgical wound, **wound strength** is about **10%** that of normal unwounded skin.
- **Four weeks**: Wound strength quickly increases over the next 4 weeks, and then slows down.
- **Three months:** Wound strength **reaches a 70% to 80% of the tensile strength** of unwounded skin.

JAYPEE BROTHERS

FACTORS THAT INFLUENCE WOUND HEALING

Q. List the factors that influence wound healing.

Q. List factors which delay healing.

Local Factors

1. **Infection:** It is the single most important cause for delay in healing. Infection causes persistent tissue injury and inflammation.
2. **Mechanical factors: Movement of wounded area** may compress the blood vessels and separate the edges of the wound and can result in delayed healing.
3. **Foreign bodies:** Unnecessary sutures or foreign bodies (fragments of steel, glass), or even bone can delay healing.
4. **Size and type of wound**: Small surgical incisional or other injuries heal quickly with less scar formation than large excisional wounds or wounds caused by blunt trauma.
5. **Location of injury:** Wound over the skin covering bone with little intervening tissue prevents wound contraction (e.g. skin over the anterior tibia). The edges of skin lesions (e.g. burns) in such locations cannot be apposed.

Q. List factors which promote healing.

6. **Blood supply:**
   - Wounds in areas with **good blood supply,** such as the face, heal **faster** than those with **poor blood supply**, such as the foot.
   - **Varicose veins** of the legs decrease the venous drainage and **can cause nonhealing ulceration**.
   - **Bed sores (decubitus ulcers**) result due to prolonged, localized pressure, which diminishes both arterial and venous blood flow.
7. Ionizing radiation decreases repair process.
8. Complications may delay wound healing.

Systemic Factors

1. **Nutritional deficiencies:** Delays wound healing and these include:
   - Protein deficiency (e.g. malnutrition)
   - Vitamin C deficiency: Inhibits collagen synthesis and retard healing
   - Trace elements: Copper and zinc deficiency.
2. **Age:** Wound healing is rapid in young compared to aged individuals.
3. **Metabolic status**: **Diabetes mellitus** is associated with delayed healing due to micro-angiopathy.
4. **Circulatory status**: **Inadequate blood supply** *(*due to arteriosclerosis) or venous abnormalities (e.g. varicose veins) that retard venous drainage, delay healing.
5. **Hormones: Glucocorticoids have anti-inflammatory effects** and also inhibit collagen synthesis, thereby **impair wound healing**.
6. **Hematological abnormalities:** Quantitative or qualitative defects in neutrophils and bleeding disorders may slow the healing process.

JAYPEE BROTHERS

COMPLICATIONS OF WOUND HEALING

Q. Mention the complications of wound healing.

Inadequate Granulation Tissue Formation

Inadequate formation of granulation tissue or a deficient scar formation can cause **wound dehiscence** and **ulceration**.

1. **Dehiscence** (the wound splitting) or rupture of a wound is most common life-threatening complication after abdominal surgery. It is due to increased abdominal pressure/ mechanical stress on the abdominal wound from vomiting, coughing, or ileus.
2. **Ulceration:**
   - Wounds can ulcerate due to inadequate angiogenesis during healing. For example, wounds in the leg of patients with atherosclerotic peripheral vascular disease or varicose veins usually ulcerate.
   - Nonhealing wounds also develop in regions devoid of sensation. These **neuropathic or trophic ulcers** may be seen in diabetic peripheral neuropathy, nerve damage from leprosy.
3. **Incisional hernia** resulting from weak scars of the abdominal wall due to a defect caused by prior surgery. They are due to insufficient deposition of extracellular matrix or inadequate cross-linking in the collagen matrix.

Excessive Scar Formation

Excessive formation of the components of the repair process can result in:

1. **Hypertrophic scar:** The accumulation of excessive amounts of extracellular matrix, mostly collagen may give rise to a raised scar at the site of wound known as a hypertrophic scar. They usually develop after thermal or traumatic injury, which involves the deep layers of the dermis.
2. **Keloid:** If the scar tissue grows/progress beyond the boundaries of the original wound and does not regress, it is called a keloid. Thus, keloid is an exuberant scar that recurs with still larger keloid after surgical excision.
3. **Exuberant granulation:**
   a. **Pyogenic granuloma or granuloma pyogenicum (Fig. 4.6)**:
      i. This consists of the localized formation of excessive amounts of granulation tissue.
      ii. Such exuberant granulation tissue projects above the level of the surrounding skin and prevents re-epithelialization. This mass formed is often named as **proud flesh.**
   b. **Desmoids or aggressive fibromatoses**:
      i. Incisional scars or traumatic injuries may be followed by excessive proliferation of fibroblasts and other connective tissue elements.
      ii. They are known as desmoids, or aggressive fibromatoses, which may recur after excision.

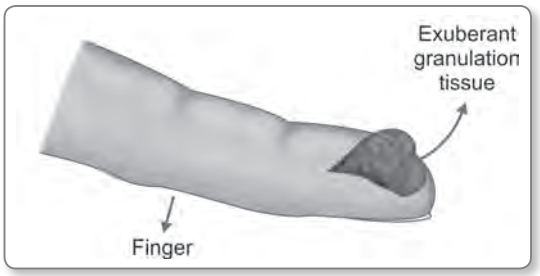

Fig. 4.6: Exuberant granulation tissue at the tip of the finger

JAYPEE BROTHERS

Excessive Contraction

- A decrease in the size of a wound due to myofibroblasts is known as **contraction**.
- An exaggeration of this contraction is termed **contracture** and results in deformities of the wound and the surrounding tissues.
- Consequences of contractures:
  - **Compromise movements:** for example, contractures that follow severe burns can compromise the movement of the involved region (Fig. 4.7) and joint movements.
  - **Obstruction:** for example, in GI tract contracture (stricture) can cause intestinal obstruction.



Fig. 4.7: Wound contracture—Severe contracture of a wound on the right side of neck, following burns

Others

1. **Infection** of wound by microbes.
2. **Epidermal cysts** can develop due to persistence of epithelial cells at the site of wound healing.
3. **Pigmentation** may develop due to either colored particle left in the wound or due to hemosiderin pigment.
4. **Neoplasia:** For example squamous cell carcinoma may develop in Marjolin's ulcer, which is the scar that follows burns in skin.

Fibrosis

- Normal wound healing is associated with deposition of collagen.
- The excessive deposition of collagen and other ECM components in a tissue is termed as fibrosis. It is usually observed in chronic inflammation.
- **TGF-β is an important fibrogenic agent**.
- Examples of **disorders with fibrosis**: Cirrhosis of liver, pneumoconioses, chronic pancreatitis and glomerulonephritis.

HEALING OF A FRACTURE

Q. Describe the healing of fractures in long bones.

Phases of Fracture Healing (Figs 4.8A to E)

Bone can repair by reactivating processes that normally takes place during embryogenesis. There are three major phases of fracture healing.

Inflammatory Phase

- **Fracture and hemorrhage:**
  - Soon **after fracture**, **blood vessels** (in the periosteum, cortex and medullary cavity) **rupture** leads to extensive hemorrhage (hematoma), at the fracture site and surrounding tissue.
  - **Necrosis of bone** also occurs at the fracture site.

JAYPEE BROTHERS

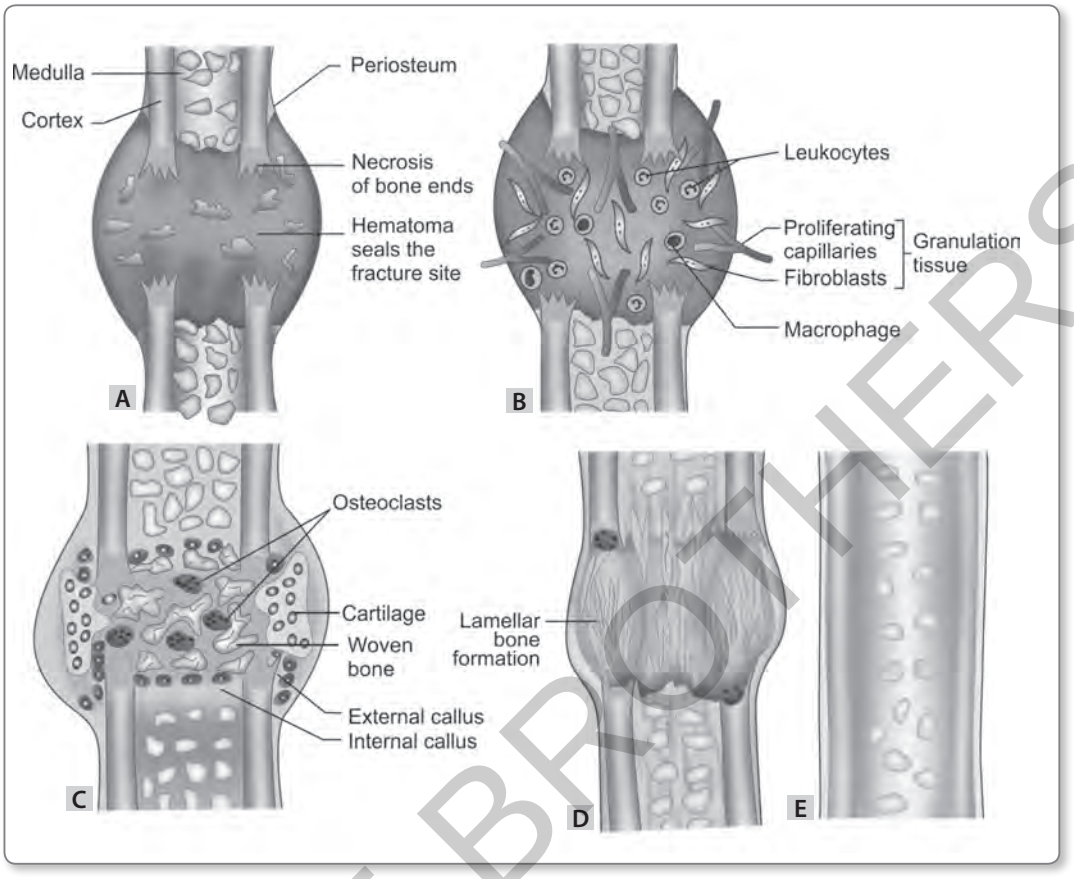

Figs 4.8A to E: Healing of a fracture. A. Immediately after a fracture, blood clot/hematoma forms at the site of fracture; B. During the inflammatory phase of fracture healing, the inflammatory cells (neutrophils and macrophages) migrate to the area of fracture and neovascularization develops; C. The reparative phase of fracture healing is characterized by the formation of a callus near the fracture site; D. In the remodeling phase, the reactive bone (lamellar or woven) develops; E. Healing is complete and bone attains its original contour

- **Inflammatory cells:**
  - **Fibrin mesh work** in the clotted blood **helps**
    - **To seal the fracture site**
    - **Influx of inflammatory cells (neutrophils and macrophages) to the area**
    - **Ingrowth of fibroblasts and new capillary vessels (neovascularization) to the site, producing granulation tissue between the fracture fragments.**
  - **Activation of osteoprogenitor cells**: The **inflammatory cells and platelets release cytokines** (PDGF, TGF-β, FGF and interleukins) → **activate the osteoprogenitor cells** in:
    - **Periosteum**
    - **Medullary cavity**
    - **Surrounding soft tissues.**
- **Formation of granulation tissue:** It consists of proliferating capillaries and fibroblasts and are formed at the site of fractures

JAYPEE BROTHERS

- **Soft-tissue callus or procallus formation:**
  - **Osteoprogenitor cells → activate both osteoblastic and osteoclastic activities** at the fracture site.
  - **Osteoblasts** derived from activated osteoprogenitor cells **migrate into the granulation tissue** and **differentiate into osteoid synthesizing units**. They **deposit** large quantities of **osteoid collagen in a haphazard pattern** producing **woven bone** (unmineralized bone is called osteoid).
  - **Granulation tissue containing** (mineralized or unmineralized) **bone or cartilage** is termed a **callus.**
  - At this stage, **callus** is predominantly **uncalcified** and is called **soft-tissue callus or procallus**, which **provides a type of temporary connection between the ends of the fractured bones**. However, procallus does not have any structural rigidity for any weight bearing. The callus depending on its site and appearance can be divided into external and internal callus.
    - **External callus:** It is formed from the osteoprogenitor cells of periosteum and surrounding soft tissue and is found on the surface of the bone. It bridges the fracture site outside the bone and continues to grow inwards toward the fracture site. In this region, the osteoprogenitor cells may also differentiate into chondroblasts, which form fibrocartilage and hyaline cartilage around the fracture site.
    - **Internal callus:** It is derived from osteoprogenitor cells of medullary cavity and grows outward toward the fracture site. This bridges the fracture in the region of medullary cavity but in contrast to external callus does not contain cartilage.
  - The **repair tissue** attains **maximal thickness at the end of the second or third week** and consists of hyaline cartilage and woven bone.

Reparative Phase

- **Lamellar bone formation:** As the healing advances, the hyaline cartilage and woven bone of the original fracture **callus are replaced by lamellar bone.** This is stronger and consists of **parallel collagen fibers**.
- **Endochondral ossification:** The replacement process is known as **endochondral ossification** with respect to the hyaline cartilage and **bony substitution** with respect to the woven bone.
- **Bony callus:** At this stage, the **callus is mineralized** (calcified) and is known as **bony (osseous) callus**. As the mineralization proceeds, the stiffness and strength of the callus increases. By the second or third week, controlled weight bearing can be tolerated.

Remodeling Phase

- Several weeks after a callus has sealed the bone ends, the remodeling phase begins.
- **Resorption of excess portions of bony callus**: During healing, **excess of bony callus is formed around the fracture site**. As the callus is subjected to weight-bearing forces, the portions of bony callus that are not physically stressed by this weight are **slowly resorbed by osteoclasts**. Thus, the osteoclasts act to remodel bone and decrease the size of callus.
- The remodeling phase **substitutes the trabecular bone with compact bone**.
- Remodeling phase continues till the original bone shape (contour), outline and strength of the fractured bone is re-established.

The **whole process of healing** of a bone fracture usually takes **about 6 to 8 weeks**.

JAYPEE BROTHERS

Major Causes of Delayed Fracture Healing (Table 4.1)

Table 4.1: Major causes of delayed fracture healing

Local factors	General factors
• Excessive movement of fractured bone during healing process • Infection of the fractured site • Severe local soft tissue injury • Wide separation of fracture ends • Extensive necrosis of the fractured bone • Poor or impaired blood supply (e.g. tibia, head of femur)	• Old age • Poor general health • Drugs, e.g. corticosteroids

Complications of Healing

Q. Mention the complications of healing of fracture bone.

- **Delayed union and nonunion** of fracture.
- **Pseudoarthrosis:** In case of nonunion, too much movement along the fracture gap can cause cystic degeneration in the callus, creating a false joint or pseudoarthrosis.
- **Large callus with deformity**.

JAYPEE BROTHERS

for detailed information on dental books, visit our website www.jaypeebrothers.com, for detailed information on dental books, visit our web

Exam Preparatory Manual for Undergraduates

Pathology for Dental Students

Salient Features

- Provides basic concepts of diseases required to be known by undergraduate dental students
- Provides knowledge in a simple, lucid and easily understandable and reproducible format
- Richly illustrated
- The book is divided into two sections: theory and practicals
- Concise text in bullet form for easy review and recollection
- Key points are provided in bold words so that it will help the students to just brush through the entire book within few hours before the examination or viva voce
- Provides usual questions asked in the examination
- Texts are enhanced by many illustrations, gross photographs, photomicrographs, tables, flowcharts and X-rays
- Color plates have been provided to facilitate the visual impression of gross and microscopic features of important lesions.



Ramadas Nayak MBBS MD graduated from Mysore Medical College, Mysuru, Karnataka, India, in the year 1979 and completed his postgraduation in Pathology from Kasturba Medical College, Mangaluru, Karnataka, India. Presently, he is working as Professor and Head, Department of Pathology, Yenepoya Medical College, Yenepoya University, Mangaluru. In his illustrious teaching career of 32 years, Dr Nayak was Head, Department of Pathology at Kasturba Medical College, Mangaluru for a span of 5 years. Apart from publishing over 82 scientific papers in both national and international journals, he is reviewer of the article for Journal of Oral and Maxillofacial Pathology. He serves as an examiner for both undergraduate and postgraduate examinations in several universities. He has worked as Project Officer for Development of Cancer Atlas in India—a project conducted by Indian Council of Medical Research (ICMR) sponsored by WHO. He was the editorial Committee Member of South Asia Edition of British Medical Journal. He is also the author of four books entitled *Essentials in Hematology and Clinical Pathology, Textbook of Pathology and Genetics for Nurses, Rapid Review of Hematology* and *Exam Preparatory Manual for Undergraduates in General and Systemic Pathology*. Twice he secured "Good teacher award" and eight times "Best audiovisual" award in Kasturba Medical College, Mangaluru. Above all, he is loved and admired by his students.

Available at all medical bookstores or buy online at www.jaypeebrothers.com

JAYPEE BROTHERS
Medical Publishers (P) Ltd.
www.jaypeebrothers.com

Join us on facebook.com/JaypeeMedicalPublishers

Shelving Recommendations
PATHOLOGY, DENTISTRY

ISBN 978-93-5250-118-2