ur website www.jaypeebrothers.com, for detailed information on radiology books, visit our website www.jaypeebrothers.com

Manual of ULTRASOUND



GS Garkal

3rd Edition

JAYPEE

Contents

1. Basic Principles of Ultrasound 1

2. Ultrasound Instruments 3

Components of an Echograph *3*

3. Real-time Ultrasound 6

Survey and Detail *6*

4. Introduction to Abdominal Scanning 10

Examination Protocol *12*

5. Sonography of Soft Tissues 14

Soft Tissue Abnormalities *14*

6. Hepatic Sonography 17

Hepatic Ultrasound *17*

Examination of Liver *20*

Liver Cysts *23*

Tumors *27*

Ultrasonic Anatomy of the Liver *32*

Ultrasound Appearances of Liver *39*

7. Gallbladder and Biliary Tract 54

Indications *54*

Anatomy *54*

Physiology of the Gallbladder *54*

Tests for Biliary Functions *56*

Radiographic Ways to Study Gallbladder *56*

Disease of Gallbladder *56*

Ultrasound Appearances of Gallbladder *58*

8. Pancreas **75**
Anatomy *75*
Fact and Fallacies in Evaluation of Pancreas *80*
Ultrasonography of Pancreas *84*
Ultrasound Appearances *86*
Pancreas *86*

9. Abdominal Aorta **95**
Vascular Pathology *97*
Aneurysm *97*

10. Spleen **100**
Physiology *100*
Ultrasound Appearances *101*
Splenomegaly *104*
Hematological *105*

11. Urinary System **113**
Kidneys *113*
Kidneys Ultrasonography *118*
Diseases of the Kidney *120*

12. Adrenal Ultrasonography **142**
Adrenal Glands *142*

13. Ultrasound: Prostate **150**
Male Pelvis *150*
Prostate *150*

14. Abdominal Sonography **155**
Gastrointestinal Ultrasound *157*
General Sonographic Findings *157*
Intestine *160*
Mesenteric Infarction *160*
Inflammatory Diseases *161*

Appendix *165*
Fluid Collections *168*
Retroperitoneum *174*

15. Ultrasonography of the Scrotum **177**
Ultrasound Appearances of Scrotum *177*
Acute Scrotum *182*

16. Ultrasonography of the Thyroid **186**
Thyroid Gland *186*

17. Breast **197**
Anatomy *197*
Benign Tumors *200*

18. Pelvic Ultrasonography **204**
Female Pelvis: Technique *204*
Uterus *205*
Non-neoplastic Disorders *216*
Intrauterine Devices *223*
Gestational Trophoblastic Disease *223*
Ovaries *226*
Follicular Maturation *229*
Ovarian Mass *230*
Pelvic Inflammatory Diseases *237*
Sonographic Evaluation of Pelvic Infections *237*

19. Infertility **242**
Uterine Factors *242*
Fallopian Tubes Obstruction *243*
Ovarian Factor *244*
Follicular Monitoring *246*
Spontaneous Ovulation *246*
Induced Ovulation *247*
New Advent *251*

20. Obstetrics **253**

Introduction to Obstetrical Ultrasound *253*
First Trimester Abnormalities *259*
Ectopic Pregnancy *264*
Fetal Development *267*
Cephalopelvic Disproportion *275*
Multiple Pregnancy *276*
Fetal Malformation *278*
Abnormal Cranial Anatomy *278*
Abnormal Spine Anatomy *281*
Abnormal Abdominal Anatomy *282*
Abnormal Renal Anatomy *284*

21. Placenta **287**

Placental Grading *287*

22. Amniotic Fluid **295**

Oligohydramnios *295*
Polyhydramnios *295*
Ultrasound Findings *296*
Assessment of Amniotic Fluid Volume *296*

23. Assessment of Fetal Wellbeing **298**

Biophysical Profile *298*

Appendix (Fetal Growth) *305*

Index *323*

CHAPTER 4

Introduction to Abdominal Scanning

JAYPEE BROTHERS

Diagnostic ultrasound provides a unique method of examining structures beneath the skin surface. The image produced is cross-sectional, and sonography has a primary advantage over radiography by nature of its capacity to distinguish interfaces between soft tissue structures of the body. This ability plus the noninvasive and nontraumatic qualities of ultrasonography have resulted in ever increasing interest and use during recent years.

The next important step is to recognize an adequate scan, and how to achieve the same. In B-scanning the strongest echoes are produced when the sound beam is at right angles to an interface. For this reason it is often necessary to employ a compound sector scanning motion to record a maximum number of interfaces at perpendicularity.

Because the transducer spends approximately 99% of its time listening and less than 1% of its time sending the signal, it is important to develop a proper scanning speed so that every echo will be recorded. Scanning too fast results in many echoes being unrecorded. Scanning too slow allows the beam to concentrate too long on one particular area causing artifactual echoes to appear (Fig. 4.1).

The skin over the area of interest should be liberally coated with mineral oil or other suitable couplet to eliminate any air molecules between the transducer and the skin, thus providing maximum contact.

It is advisable to carry out scanning in an orderly fashion and to identify the anatomical position where transverse and longitudinal cross sections are taken by recording a preselected landmark. Most commonly used landmarks are:

- Umbilicus
- Xiphoid process
- Iliac crest
- Symphysis pubis.

Osseous structures are preferable because they do not change position.

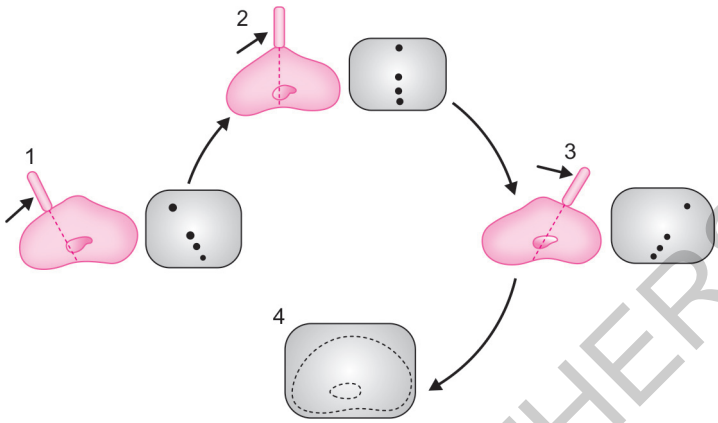

Fig. 4.1 As the transducer is moved across the body, an image of the body section transversed is built up on the storage screen

All recorded scans should be labeled for future reference with the following information:

- Patient's name
- Date
- Anatomical position
- Gain setting (whenever applicable).

The criteria for an adequate scan as described by Filly and Freimanis is helpful to the novice in evaluating a scan (Figs 4.2 and 4.3):

- Longitudinal scans
  - Well-defined anterior/posterior aortic walls on left side
  - Well-defined liver-diaphragm interface on right side.
- Transverse scans
  - Posterior liver surface well outlined
  - Anterior surface of spine seen
  - Adequate delineation of aorta and whenever possible the inferior vena cava
  - Adequate delineation of the left side of the spine on transverse scans.

JAYPEE BROTHERS

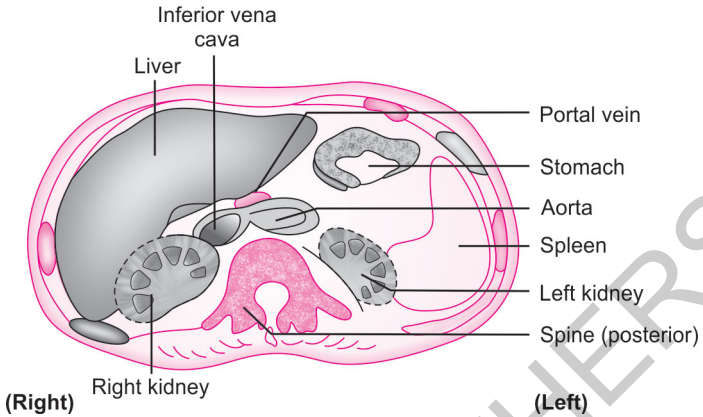

Fig. 4.2 Transverse, supine

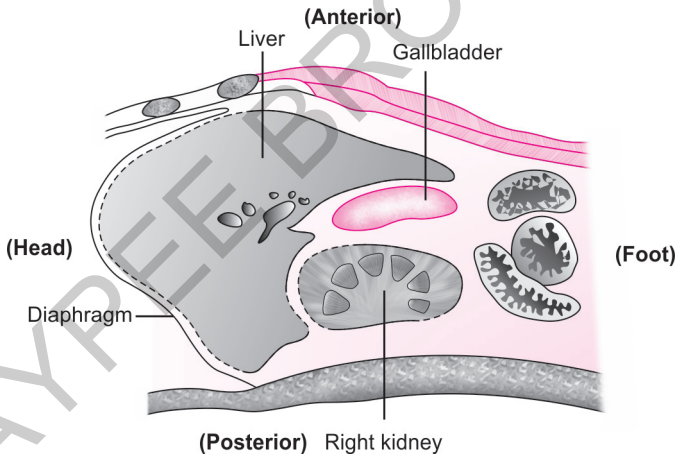

Fig. 4.3 Longitudinal, supine, 6 cm right

JAYPEE BROTHERS

Examination Protocol

- Greet the patient
- Take the patients history (in a private place)
- Explain the procedure to the patient
- Instruct the patient on how to gown

- Complete 'paper work' while patient changes
- Review available clinical information
- Position patient on exam table:
  - As far to the edge of the table (near you) as possible
  - Elevate patients head as needed
  - Instruct patient to elevate arms if abdominal/kidney scans are being performed
  - Drape the patient
  - Apply appropriate contact-media.
- Set instrumentation/film devices, etc.
- Perform scans and record
  - Longitudinal, transverse and oblique if necessary
- Prepare and process films at completion of examination
- Release patient.

JAYPEE BROTHERS

for detailed information on radiology books, visit our website www.jaypeebrothers.com, for detailed information on radiology

Manual of ULTRASOUND

Salient Features

- A thoroughly revised and updated book
- Includes a new chapter on Basic Sonography of Soft Tissue
- A compact book of great utility to ultrasonographers/ultrasonologists, medical graduates and medical practitioners.



GS Garkal did MBBS from Lucknow University, Uttar Pradesh, India; DMRD and MD (Radiodiagnosis) from Delhi University, New Delhi, India. He did senior residency from Wellington Hospital (Ram Manohar Lohia Hospital), New Delhi. Since 1979, he is in private practice as Consultant Radiologist, Janta X-ray Clinic Laboratory Pvt Ltd, New Delhi. He is also a visiting Consultant Radiologist in Kalra Hospital, Kirti Nagar, and Janta Diagnostic Centre, Sunder Vihar and Paschim Vihar, New Delhi.

Available at all medical bookstores
or buy online at www.jaypeebrothers.com

JAYPEE BROTHERS
Medical Publishers (P) Ltd.
www.jaypeebrothers.com

Join us on facebook.com/JaypeeMedicalPublishers

Shelving Recommendation
RADIOLOGY

ISBN 978-93-5250-123-6