n oncology books, visit our website www.jaypeebrothers.com, for detailed information on oncology books

Step by Step®

Radiation Therapy

Treatment and Planning

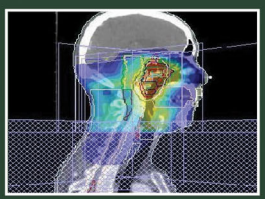

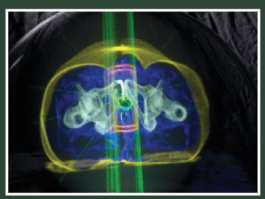

Step by Step®

Arun Kumar Rathi

JAYPEE

Contents

1. Basics of Radiation Therapy Planning **1**

Gautam Saran

Aim of Radiotherapy *1*
Steps in Radiotherapy Planning *1*
Steps in Preplanning *2*
Planning Radiotherapy Treatment *3*
Steps in Treatment Delivery *10*

2. Head and Neck Cancer **14**

Vikash Kumar, Ashutosh Mukherji

General Principles and Outline of Management *14*
Prerequisite Investigations for Treatment Planning *16*
Indications for Postoperative Radiotherapy *16*
Oral Cavity *19*
Maxillary Antrum *24*
Nasopharynx *27*
Oropharynx *30*
Larynx *32*
Ear *41*
Minor Salivary Gland Tumors *44*
Unusual Nonepithelial Tumors *44*
Glomus Jugulare *48*

3. Gynecologic Tumors **50**

Kanika Sharma

Uterine Cancer *50*
Carcinoma Cervix *52*
Carcinoma Vagina *55*
Carcinoma Vulva *57*
Carcinoma Ovary *58*
Ovarian Ablation *61*
Malignancy During Pregnancy *62*

4. Carcinoma of Breast 64
Kanika Sharma
Role of Radiation Therapy *64*
Target Delineation *65*

5. Gastrointestinal Tract Tumors 68
Kanika Sharma
Esophagus *68*
Stomach *70*
Rectum *72*
Colon *76*
Anal Canal *77*
Pancreas *79*
Hepatobiliary *82*
Hepatocellular Carcinoma *82*
Gallbladder *83*
Cholangiocarcinoma *84*

6. Thoracic Tumors 86
Vikash Kumar
Lung Cancer *86*
Superior Sulcus Tumor *91*
Mesothelioma *93*
Thymoma *95*

7. Central Nervous System 96
Vikash Kumar
Supportive Care *96*
General Guidelines for Radiation Therapy *97*
Follow-up Protocol *104*

8. Central Nervous System Tumors in Children 105
Ashutosh Mukherji
Astrocytomas *106*
Ependymomas *111*

Choroid Plexus Tumors *112*
Craniopharyngiomas/Sellar Tumors *112*
Pineal Tumors *113*
Medulloblastomas *113*
Supratentorial Primitive Neuroectodermal Tumors *115*
Germ Cell Tumors *115*
Radiotherapy Technique (Brain Tumors) *116*

9. Non-CNS Solid Tumors in Children 122
Ashutosh Mukherji
Retinoblastoma *122*
Wilms' Tumor *127*
Neuroblastoma *130*
Ewing's Sarcoma *131*
Rhabdomyosarcoma *133*
Childhood Lymphomas *134*
Leukemias *135*
Hepatoblastomas *137*
Langerhans Cell Histiocytosis *138*

10. Genitourinary Cancer 139
Vikash Kumar, Ashutosh Mukherji
Prostate *139*
Renal Cell Carcinoma *143*
Urinary Bladder Cancers *144*
Urethral Cancers *149*
Penile Carcinomas *153*

11. Thyroid Malignancies 159
Kanika Sharma
Role of Radiotherapy *159*
Assessment of Tumor *159*
Target Delineation *159*
Tumor Extending to Superior Mediastinum *160*

12. Irradiation of Blood Products and Spleen 162
Ashutosh Mukherji
Rationale of Irradiation of Blood Products *162*
Dose Recommendations and Technique *163*
Effect of Irradiation on Blood Components *164*
Splenic Irradiation *165*

13. Palliative Radiotherapy 166
Vikash Kumar
Bone Metastasis *166*
Brain Metastasis *167*
Lung Metastasis *168*

14. Reirradiation 171
Ashutosh Mukherji
Head and Neck Cancers *172*
Breast Cancer *174*
Lung Cancer *175*
Brain Tumors and Metastases to Brain and Spinal Cord *176*
Bone Metastases *178*
Rectal Cancers *178*
Gynecological Cancers *179*
Soft Tissue Sarcomas *180*

15. Magna Field Radiotherapy 182
Ashutosh Mukherji
Total Body Irradiation *182*
Hemibody Irradiation *192*
Total Scalp Irradiation *193*
Total Limb Irradiation *194*
Total Skin Irradiation *195*

16. Bone and Soft Tissue Tumors **197**
Kanika Sharma
Bone Tumors *197*
Soft Tissue Sarcomas *199*

17. Radiotherapy of Nonmalignant Diseases **202**
Ashutosh Mukherji
Meningiomas *202*
Pituitary Adenomas *203*
Juvenile Nasopharyngeal Angiofibroma *205*
Choroidal Hemangioma *206*
Endocrine Orbitopathy (Graves' Disease) *207*
Diseases of Tendons and Joints *208*
Morbus Peyronie *210*

18. Emergency Radiotherapy **212**
Kanika Sharma
Superior Vena Cava Obstruction *212*
Malignant Spinal Cord Compression *213*
Bone Metastases *216*
Brain Metastases *218*
Bleeding or Pain from Advanced Malignancies *219*

19. Radiation Therapy: Accompaniments and their Management **221**
Indu Bansal
Radiation Dermatitis *222*
Mucositis *223*
Esophagitis *225*
Xerostomia (Dry Mouth) *226*
Nausea and Vomiting *227*

Changes in Smell or Taste *228*
Anorexia *228*
Diarrhea *229*
Urinary and Bladder Changes *230*
Hair Loss *231*
Fatigue *232*
Sexual and Fertility Changes *233*
Low Blood Counts (Myelosuppression) *234*
Radiation Pneumonitis *234*
Late Side Effects *235*

20. Teletherapy Machines and Other Instruments 243
Kanika Sharma
Linear Accelerator *243*
CyberKnife *249*
Gamma Knife *249*
Telecobalt Machine *250*
Cyclotron *253*
Synchrocyclotron/Synchrotron *254*
Betatron *254*
Transformer Units *255*
Van de Graaff Generator *255*
Radioisotopes *257*
Instruments *261*

Index *275*

Introduction

Nearly all cancer patients receive radiation therapy as definitive therapy, for palliation or as adjunct to surgery or chemotherapy.

The aim of radiation therapy is to deliver a precisely measured dose of radiation to a defined tumor volume with minimal damage to surrounding healthy tissues.

Resulting in

- Eradication of tumor
- A high and improved quality of life
- Prolongation of survival
- Effective palliation of symptoms of cancer
- With minimal morbidity.

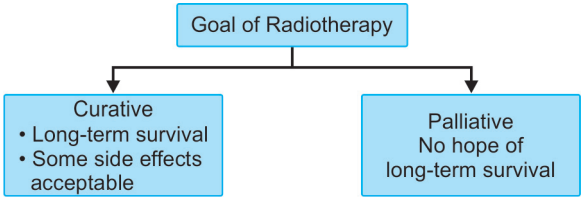

Simpler treatment techniques that yield an acceptable dose distribution are to be preferred over costly and complex ones, which have a greater margin of error in day-to-day treatment.

IMPORTANT POINTS OF ANATOMY FOR RADIATION ONCOLOGISTS

Surface anatomy is the study of deeper parts in relation to the skin surface. A mental picture of surface anatomy is needed by every

doctor during the physical examination of a case and radiotherapy planning. Radiological anatomy is the study of deeper organs by plain or contrast radiography.

Breast

- Breasts vary in size.
- Normally between ribs 2 and 6, overlie the pectoralis major muscle.
- Axillary tail—superolaterally around the lower margin of pectoralis major muscle.

Thoracic Level 4/5

- Costal cartilage of rib 2 articulate with the sternum.
- Superior mediastinum separated from inferior mediastinum.
- Ascending aorta ends and arch of aorta begins.
- The trachea bifurcates.

Spinal Cord and Subarachnoid Space

Normally in adults, spinal cord terminates at the level of disc between L1 and L2. Subarachnoid space ends at approximately S2 (sacral dimples).

Vertebral Spinous Processes

C2: Most superior bony protuberance in the midline inferior to the skull.

C3-4: Upper margin of thyroid cartilage
Bifurcation of common carotid artery into internal and external carotid arteries.

C6: Transition from pharynx to esophagus
Larynx to trachea
Inferior margin of cricoid cartilage

C7: Prominent eminence in the midline at the base of the neck.

T1: Inferior to C7, visible as midline protuberance, often more prominent than the spinous process of C7.

T3: Root of the spine of scapula.

T7: Inferior angle of scapula.

T12: Mid-point of vertical line between the inferior angle of the scapula and iliac crest.

L2: Renal arteries originate.

L4: Aorta bifurcates into the right and left common iliac arteries.

L4: Horizontal line between the highest point of the iliac crest.

S2: Sacral dimples mark the position of the posterior superior iliac spine are level with the S2.

Coccyx: Tip is palpable at the base of vertebral column between the gluteal masses.

Transpyloric Plane

- Body of L1
- Midway between jugular notch and pubic symphysis
- Duodenum
- Hila of kidneys
- Neck of pancreas
- Origin of superior mesenteric artery from aorta
- Celiac trunk
- Fundus of gallbladder.

Kidney: T12 to L3-4.

Spleen: Follows - rib10.

Pituitary fossa: Lies on the straight line joining the nasion with the inion at a depth of 6–7 cm from the nasion.

DR RATHI'S 17 IMPORTANT POINTS

1. X-rays were discovered by Wilhelm Conrad Roentgen in 1895.
2. Radioactivity was discovered by Henri Becquerel in 1896.
3. Radium was discovered by Marie and Pierre Curie in 1898.
4. One could achieve the same tumor response with less injury to normal tissue by fractionating the dose was proposed by Henri Coutard and Claude Regaud.
5. The Roentgen was internationally accepted as a unit of measurement for X-rays and gamma rays in 1928.
6. Rad as a unit of absorbed dose was recommended by the International Commission on Radiation Units (ICRU) in 1953.
7. The point of maximum electron equilibrium is referred to as D_{max}.
8. Percentage depth dose is dependent on field size, distance and energy.
9. The width of the penumbra increases with increased source-surface distance (SSD), decreased source-collimator distance, increased source size.
10. Required MeV is determined by multiplying the maximum tumor depth in centimeters by three.
11. The percentage depth dose at a given depth increases with higher beam energies.
12. The amount of back scatter increases with lower beam energies.
13. The most serious late consequence of high dose total body irradiation is radiation pneumonitis.
14. The exposure rate constant for radium is defined as the exposure rate at a point 1 cm away from 1 mg of radium filtered by 0.5 mm of platinum.
15. A beam spoiler is a sheet of lucite placed in the beam to reduce the depth of D_{max}.
16. To estimate the needed wedge angle in oblique fields subtract the hinge angle from 180 and divide by 2.
17. In an isocentric treatment technique, it is routine to normalize dose at isocenter.

CHAPTER 4

Carcinoma of Breast

Kanika Sharma

ROLE OF RADIATION THERAPY

Indications of Chest Wall Radiation

- Positive resection margin or gross residual disease
- T3 tumors and T4 tumor
- Four or more positive nodes in axilla
- Close surgical margins
- Lymphovascular invasion
- 1–3 lymph node in presence of other risk factors.

Indications of Axillary Irradiation

- Four or more axillary lymph node positive
- Perinodal disease
- Inadequate surgical dissection (less than 10 lymph nodes dissected)
- Unknown axillary status
- Posterior axillary boost needed in obese patients where anterior field is unable to deliver adequate dose to axillary nodes as in patients with separation >12 cm and where axilla is heavily involved.

Assessment of Primary Tumor

Clinical examination and diagrammatic documentation of primary tumor and nodal areas.

- Mammography
- MRI breast
- Grossing of surgical specimen for size, site and extent
- Histology for size, type, grade, margin receptor status and lymph node status
- Extent of surgical scar.

TARGET DELINEATION

Target Volume

- *In intact breast:* Entire breast with chest wall with one cm margin and a small portion of underlying lung
- *In operated cases:* Radiopaque surgical clips placed per-operatively at margins of tumor bed assist in defining target volume. After modified radical mastectomy—chest wall and small portion of underlying lung.

Radiotherapy Technique

Planning is individualized to accommodate topographic features:

- Whole breast technique (as after BCT and for LABC after neoadjuvant chemotherapy showing good regression of disease)
- Locoregional RT technique chest wall, axilla and SCF.

Patient Positioning

Supine with arm abducted at 90°. Immobilization devices such as alpha cradle and plastic molds may be used. Slope of the chest wall can be corrected with triangular wedge or incline under head and shoulders.

Field Placements

Whole Breast Technique

Medial and lateral tangential portals:

- *Upper border:* Lower margin of clavicle or intercostal space
- *Medial border:* At or over 1 cm over midline

- *Lateral border:* 2 cm beyond all palpable breast tissue (Midaxillary line)
- *Inferior border:* 2 cm below inframammary fold.

Locoregional RT

- *Upper border:* 2nd intercostal space (angle of Louis)
- *Medial border:* At or 1 cm over midline. Abuts lateral margin of IMN field if used
- *Lateral border:* Midaxillary line
- *Inferior border:* 2 cm below inframammary fold.

Axilla, Supraclavicular and Infraclavicular Field

Direct Field

- *Upper border:* In the neck to cover supraclavicular fossa across curve of shoulder till thyrocricoid groove.
- *Medial border:* 1 cm to contralateral side at level of sternal notch extending upwards following medial border of sterno-cleidomastoid muscle to thyrocricoid groove.
- *Lateral border:* If axilla not heavily infiltrated, at acromioclavicular joint. If axilla heavily infiltrated, at deltopectoral groove.
- *Inferior border:* Abuts upper border of tangential fields. The head of humerus and acromioclavicular joint is shielded.

Internal Mammary Nodal Portal

Not being routinely used. Consideration should be given for tumors of central and medial quadrant, and locally advanced breast cancers.

Direct Fields

Borders

- *Upper border:* Inferior border of SC field.
- Medial border midline (2 cm across midline).

- *Lateral border:* 6 cm from and parallel to medial border (4 cm to ipsilateral side).
- *Inferior border:* Base of xiphoid.

Posterior Axillary Boost Portal

Patient Positioning

Prone with head turned to contralateral side, forearm rotated down shoulder in contact with table top back of hand on pelvic brim.

Borders

- *Medial superior:* Follows spine of scapula.
- *Lateral superior:* Bisects head of humerus.
- *Lower lateral:* Medial to border of latissimus dorsi.
- *Inferior:* Match inferior border of anterior field 1.5–2 cm lung tissue is included medially along concavity of bony thorax.
- *Beam energy:* Cobalt
  6 MV X-rays
  8–15 MeV electrons

Dose Prescription

- *Primary:* 50 Gy/25 fractions/5 weeks at a dose rate of 2 Gy/ day treated 5 days a week. Dose calculated at mid separation 3–3.5 cm within the flap.
- *Regional nodes:* 50 Gy/25 fractions/5 weeks at dose rate of 2 Gy/day treated 5 days a week

Dose calculated at 3 cm depth for IMN field and 0.5 cm for SCF field.

At midplane 2 cm below midportion of clavicle in posterior axillary field.

In patients with breast conservation, boost is given to lumpectomy cavity either by:

- Elecrons or photons 15–18 Gy in 6–7 fractions
- Interstitial brachytherapy 20–25 Gy at 85% isodose in 3–4 days.

for detailed information on oncology books, visit our website www.jaypeebrothers.com, for detailed inform

Step by Step®

Radiation Therapy
Treatment and Planning

This practical guide to radiation therapy planning is aimed at introducing the subject to the postgraduates in radiotherapy. The book is meant as a companion with guidelines to help students during their casework.



Arun Kumar Rathi is Professor of Radiotherapy, Maulana Azad Medical College (MAMC), New Delhi, India. He graduated from University College of Medical Sciences (UCMS) and postgraduated from MAMC, New Delhi. He has been intensively trained at Institute Rotary Cancer Hospital (IRCH), All India Institute of Medical Sciences (AIIMS), India; City of Hope and Long Beach Memorial, USA. He has received Fellowship of the World Health Organization and the Association of Radiation Oncologists of India (AROI). He is currently the President of North Zone AROI.

Available at all medical bookstores
or buy online at www.jaypeebrothers.com

JAYPEE BROTHERS
Medical Publishers (P) Ltd.
www.jaypeebrothers.com

Join us on facebook.com/JaypeeMedicalPublishers

Shelving
Recommendation
ONCOLOGY

ISBN 978-93-5250-124-3