brothers.com, for detailed information on medicine books, visit our website www.jaypeebrothers.com, for detailed information on medicine book

Manual of
Nephrology



Editors
Pranaw Kumar Jha • Vijay Kher

JAYPEE

CONTENTS

1. Renal Anatomy and Physiology: A Clinical Perspective 1
Pranaw Kumar Jha, Vijay Kher

Section A: Renal Anatomy *1*
- Microscopic Anatomy: The Nephron *3*

Section B: Renal Physiology and Urine Formation *7*
- Glomerular Filtration Rate and Pressure *7*
- Transport Mechanisms *8*
- Tubular Transports *8*
- Autoregulation *13*
- Sympathetic Nervous System *13*
- Renin-Angiotensin-Aldosterone System (RAAS) *13*
- Endocrine Function of Kidneys *15*

2. Basics of Renal Histopathology 18
Ritambhra Nada, Rajan Duggal

- Renal Biopsy Fixation and Processing *18*
- Specimen Adequacy *19*
- Light Microscopic Examination of Renal Biopsy *19*

3. An Approach to Patient with Kidney Disease 43
Vijay Kher

- Signs and Symptoms of Kidney Disease *44*
- Asymptomatic Urinary Abnormality *44*
- Urinary Tract Infection *45*
- Hypertension *46*
- Acute Kidney Injury *47*
- Rapidly Progressive Renal Failure *47*
- Acute Nephritic Syndrome *47*
- Nephrotic Syndrome *47*
- Congenital/Genetic Syndromes *50*

4. Investigations in Renal Diseases 54

Biochemical Investigations in Renal Diseases *54*
Ratan Jha, Kiran Chandra Patro

- Urine Analysis *54*
- Proteinuria *54*
- Blood and Urine Biochemistry *55*

Urinalysis *68*
Sishir Gang

- Method of Collection of Urine Sample *68*
- Urine Appearance *68*
- Urine Odour *69*
- Specific Gravity *69*
- Chemical Composition of Urine *70*

- Urine Microscopy *71*
- Hematuria *76*
- Proteinuria *76*

Radiological Examination of Kidneys *80*
Ashish Nandwani, Pranaw Kumar Jha

- Recommended Imaging Modalities for Kidney Diseases *80*
- Plain Film of the Abdomen *81*
- Intravenous Urography *81*
- Retrograde or Antegrade Pyelography *81*
- Cystography *82*
- Ultrasound *82*
- Doppler Ultrasonography *87*
- Computed Tomography *88*
- Magnetic Resonance Imaging *90*

Nuclear Medicine Imaging in Nephrology *95*
Arun Kumar Reddy Gorla, Harbir Singh Kohli, Bhagwant Rai Mittal

5. Acute Kidney Injury 111
Vivekanand Jha

- Definition and Classification *111*
- Clinical Presentation *112*
- Major Causes and Classification of AKI *114*
- Evaluation *114*
- Management *119*
- Prognosis *123*
- Biomarkers in Acute Kidney Injury *124*

6. Chronic Kidney Disease 128
H Sudarshan Ballal, Rohan Augustine, Vishwanath S

- Definition of Chronic Kidney Disease *128*
- Staging/Estimation of Glomerular Filtration Rate in Chronic Kidney Disease *128*
- Etiology of Chronic Kidney Disease *129*
- Progression of Chronic Kidney Disease *130*
- Manifestations of Chronic Kidney Disease *132*
- Management of Chronic Kidney Disease *134*
- Principles of Management of Chronic Kidney Disease *134*
- Pre End-stage Interventions *142*

7. Electrolyte Disorders 148

Hyponatremia and Hypernatremia *149*
Gokulnath, Ram R, Vinod Kumar K

- Regulation of Sodium and Water Balance *149*
- Hyponatremia *149*
- Etiology and Classification *150*
- Clinical Manifestations of Hyponatremia *151*
- Diagnostic Approach in Hyponatremia *151*
- Treatment of Hyponatremia *157*

- Hypernatremia *159*
- Etiology and Classification *160*
- Diabetes Insipidus *160*
- Clinical Manifestation of Hypernatremia *162*
- Treatment of Hypernatremia *163*

Hypokalemia and Hyperkalemia *165*
Satish D, Gokulnath

- Hypokalemia *165*
- Pathophysiology *166*
- Etiology *167*
- Treatment *169*
- Hyperkalemia *171*
- Approach to Hyperkalemia *172*
- Clinical Manifestations *174*
- Treatment *174*

Hypocalcemia and Hypercalcemia *178*
Manisha Sahay

- Regulation of Calcium Balance *178*
- Factors Regulating Calcium Homeostasis *180*
- Hypocalcemia *184*
- Definition *184*
- Etiology *184*
- Symptoms and Signs *184*
- Diagnosis *184*
- Management *187*
- Hypercalcemia *189*
- Definition *189*
- Etiology *189*
- Symptoms and Signs *190*
- Laboratory Diagnosis *191*
- Treatment *192*

Hypophosphatemia and Hyperphosphatemia *197*
Manisha Sahay

- Phosphorus Metabolism *197*
- Phosphate Homeostasis *198*
- Hypophosphatemia *200*
- Signs and Symptoms of Hypophosphatemia *200*
- Causes of Hypophosphatemia *201*
- Diagnosis and Treatment *201*
- Treatment *205*
- Hyperphosphatemia *206*
- Epidemiology *206*
- Etiology *206*
- Signs and Symptoms *208*
- Laboratory Studies *208*
- Treatment *209*

8. Acid-base Disorders **214**
Mysore Keshavmurthy Phanish

- Acid Handling by the Kidney and the Role of Kidney in the Regulation of Plasma pH *215*
- Compensatory Mechanisms *216*
- Practical Interpretation of ABG: A Step-wise Approach *217*
- Management of Metabolic Acidosis *221*
- Renal Tubular Acidosis *221*

9. Urinary Tract Infection **226**
KC Prakash, V Ramasubramanian

- UTI Terminology *226*
- UTI Classification *227*
- Epidemiology *227*
- Etiology *227*
- Pathogenesis *228*
- Clinical Presentation *228*
- Diagnosis *230*
- Management *232*

10. Contrast-Induced Nephropathy **237**
Pranaw Kumar Jha

- Contrast Media *237*
- Pathophysiology *237*
- Risk Factors *238*
- Clinical Features and Diagnosis *240*
- Preventing Contrast-induced Nephropathy *241*

11. Urology for Nephrologist **248**
Sohrab Arora, Rajesh Ahlawat

- Terms Used for Lower Urinary Tract Symptoms *248*
- Common Investigations in the Evaluation of LUTS *248*
- Benign Prostatic Hyperplasia *253*
- Acute and Chronic Retention *255*
- Urinary Tract Obstruction: Obstructive Uropathy *256*
- Stone Disease *259*

12. Hypertension **264**
Vinay Sakhuja, Indranil Ghosh

- Definition *264*
- Epidemiology *265*
- Pathogenesis *267*
- Diagnostic Evaluation of Hypertension *270*
- Treatment *275*

13. Nutrition in Renal Diseases **288**
Anita Saxena, Amit Gupta

- Protein Energy Wasting *288*
- Management of Nutritional Status *291*

14. Drug Dosing in Renal Diseases **309**
R Kasi Viswesaran

- Vulnerability of Kidneys *310*
- Age-Related Decline in Renal Function and Importance of Glomerular Filtration Rate *312*
- Glomerular Filtration Rate in Renal Diseases *312*
- Mechanisms of Drug-Induced Renal Damage *313*

15. Renal Replacement Therapy in Chronic Kidney Disease Patients **325**
Georgi Abraham, Tarun K George

- Renal Replacement Therapy *325*

Index *339*

CHAPTER

2

Basics of Renal Histopathology

Ritambhra Nada, Rajan Duggal

INTRODUCTION

The renal biopsy is a safe medical procedure and should be undertaken only after consideration of possible morbidity and rare mortality that can occur with this invasive procedure.

The renal biopsy sample needs to be examined with optimal methods for a complete evaluation, including light microscopy (LM), immunofluorescence (IF), immunohistochemistry (wherever required) and electron microscopy (EM). The correct diagnosis requires a well-trained nephropathologist with thorough knowledge of not only renal pathology but also clinical nephrology in order to correlate intricate tissue derived information with clinical data in order to provide the best possible clinicopathologic diagnosis.

RENAL BIOPSY FIXATION AND PROCESSING

The renal biopsy tissue delivered to histopathology laboratory should be accompanied by adequate clinical information to enable proper interpretation of findings. Majority of the laboratories provide a special clinical information form to the physician to ease the recording of the overall renal syndrome, symptoms and laboratory data. Although this does not replace direct communication with the submitting nephrologist/physician. This basic medical information provides a good initial background for overall interpretation of the renal biopsy tissue. The use of a dissecting microscope can be of help in assessing sample adequacy.

Another option is the use of a standard light microscope. The renal tissue is placed on a glass slide with normal saline and examined with or without a coverslip producing a wet mount. Knowledge of the glomerular content of the sample can help in correct division of tissue for the various histologic modalities. If no glomerulus is visualized then the standard protocol for dividing the tissue obtained at each 'pass' should be used to avoid inadequate glomerular sampling for LM, IF or EM **(Fig. 2.1)**. The standard approach is to first procure tissue for electron microscopy from each core by removing 1 mm cubes from the ends and placing them in glutaraldehyde or other fixative suitable for EM. Some clinicians prefer that the pathology laboratory obtain tissue for EM from the ends of the formalin fixed tissue. Electron microscopic examination can also be performed on formalin fixed paraffin embedded tissue, however fresh tissue is always preferred.

JAYPEE BROTHERS

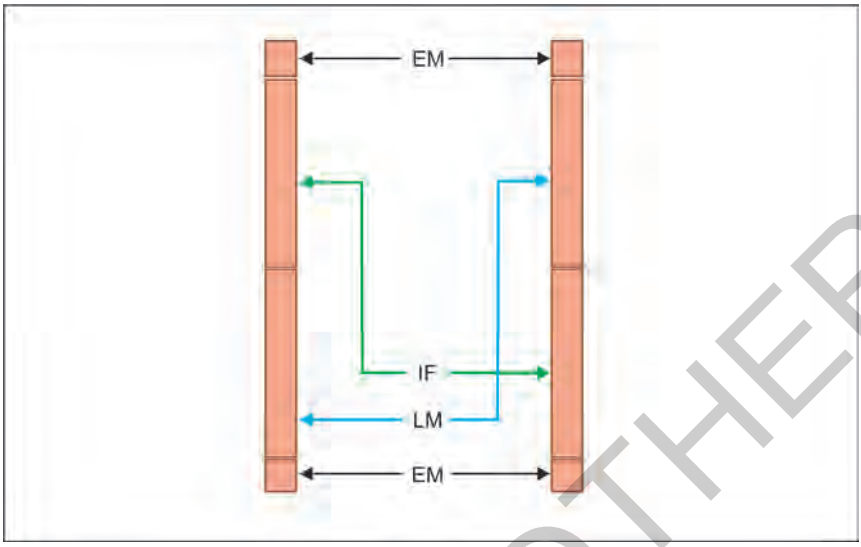

Figure 2.1 Division of renal biopsy cores in the absence of a dissecting microscope for laboratories using immunofluorescence (IF). The ends from all cores are taken for electron microscopy (EM) with the remainder divided for light microscopy (LM) and IF.
Source: Modern Pathology. 2004;17:1555-63.

SPECIMEN ADEQUACY

How much renal biopsy tissue is necessary for a definite pathologic diagnosis is a difficult question, and the answer depends on the indication for biopsy. If the differential diagnosis includes renal diseases defined by electron microscopy or immunohistology, then tissue must be processed for these studies as well as for light microscopy. A single glomerulus may be sufficient for the diagnosis of diffusely distributed glomerular diseases, such as amyloidosis or membranous glomerulopathy. In many cases, specimen adequacy is a statistical consideration of the number of glomeruli required to definitely exclude a focal pathology and to know what proportion of the glomeruli is involved.

LIGHT MICROSCOPIC EXAMINATION OF RENAL BIOPSY

The complex microscopic anatomy of the kidney requires an examination of all the histologic elements (glomeruli, tubules, interstitium, and blood vessels) in multiple serial sections to avoid missing pathologic lesions.

When confronted with a renal biopsy specimen, an initial task is to decide what renal compartment is the primary or initial site of injury, i.e. glomeruli, tubules, and interstitium, or extraglomerular vessels. In some instances, multiple compartments will be affected simultaneously by the primary pathogenic process, for example, glomeruli and vessels in certain form of vasculitis, and tubules and interstitium in tubulointerstitial nephritis. Once a particular renal compartment is injured, secondary injury often develops in other compartments, especially if there is chronic progression of renal disease. For example, primary glomerular injury results in secondary interstitial, tubular and vascular disease

JAYPEE BROTHERS

through multiple mechanisms. As chronic renal disease approaches end stage, injury to all compartments may be so severe that the primary site of disease is completely obscured.

Evaluation of Glomerular Compartment

Primary glomerular diseases have many patterns of injury, including but not limited to glomerular inflammation, necrosis, thrombosis, scarring (sclerosis), capillary wall thickening by light microscopy (LM), immune deposits by electron microscopy (EM) or immunofluorescence (IF), and glomerular basement membrane abnormalities by EM. Soon after the onset of glomerular diseases, secondary tubulointerstitial changes appear, such as interstitial edema or fibrosis, interstitial inflammation, and tubular simplification or atrophy.

Table 2.1 lists some of the terms that are used to describe the pathologic features that characterize glomerular injury. The presence and sometimes the absence of these features are used to resolve the differential diagnosis and to describe the glomerular injury in the renal biopsy report. **Table 2.2** and **Figs 2.2A and B** lists some general patterns of glomerular lesions seen by light microscopy and the diseases that most often cause them alongwith their clinical manifestations. **Figures 2.3A to D** illustrate several LM patterns of glomerular injury.

Some glomerular diseases that have overt clinical manifestations and unequivocal lesions by EM or IF may have no detectable abnormalities by LM, such as minimal change glomerulopathy, thin basement membrane nephropathy, early immune complex disease (e.g. class I lupus nephritis, mild IgA nephropathy, stage I membranous glomerulopathy). The thickness and texture of glomerular capillary walls must be assessed. Special stains, such as periodic acid-Schiff (PAS), Jones silver and Masson trichrome stains, are helpful in determining whether capillary wall thickening is most consistent with membranous glomerulopathy, thrombotic microangiopathy, or some infiltrative process such as fibrillary glomerulonephritis or amyloidosis. However, EM and/or IF are helpful in the diagnosis of most glomerular diseases both by ruling in and ruling out disease and are essential for the pathologic diagnosis of some glomerular diseases. For example, immunofluorescence (IF) is required for a definite pathologic diagnosis of anti-GBM disease, IgA nephropathy, C1q nephropathy, and monoclonal immunoglobulin deposition disease; and EM is required for a definite pathologic diagnosis of thin basement membrane nephropathy, dense deposit disease, fibrillary glomerulonephritis, and immunotactoid glomerulonephritis. In addition, there are many early or mild expressions of disease that cannot be detected or will be overlooked by LM that are readily apparent by EM, such as early or mild Fabry's disease, early hereditary nephritis, mild or resolving TMA or eclampsia, and many others.

Electron Microscopic Evaluation of Glomeruli

Renal pathology is the only anatomic pathology subspeciality that uses transmission electron microscopy for routine evaluation of tissue specimens. EM allows detailed evaluation of the cellular and extracellular contents of each glomerular compartment and definite assessment of thickness, contour,

JAYPEE BROTHERS

Table 2.1 Terms used to describe histologic lesions in glomeruli

Term	*Definition*
Focal	Involving less than 50% of glomeruli
Diffuse	Involving all or almost all glomeruli (≥ 50% of glomeruli)
Segmental	Involving portions of individual glomeruli
Global	Involving all of a glomerular tuft
Mesangial hypercellularity **(Figure 2.3)**	Four or more nuclei in the contiguous matrix of a peripheral mesangial segment
Endocapillary hypercellularity **(Figure 2.3)**	Increased cellularity internal to the glomerular basement membrane (GBM) composed of leukocytes, endothelial cells and mesangial cells
Lobular **(Figure 2.3)**	Consolidated expansion of the glomerular segments representing major anatomic subunits (lobules) of the glomerular tuft formed by dichotomous branching of the afferent arteriole (hypersegmentation of the glomerular tuft)
Extracapillary hypercellularity **(Figure 2.3)**	Increased cellularity in Bowman space or more than one layer of parietal or visceral epithelial cells
Crescent	Extracapillary hypercellularity other than the epithelial hyperplasia of the collapsing variant of focal segmental glomerulosclerosis (FSGS), often accompanied by fibrin extravasation into Bowman space
Fibrinoid necrosis	Lytic destruction of cells and matrix with deposition of acidophilic fibrin-rich material and often accompanied by GBM rupture and apoptosis of infiltrating leukocytes
Mesangiolysis	Detachment of the paramesangial GBM from the mesangial matrix resulting in a capillary aneurysm, or lytic dissolution of the mesangial matrix
Sclerosis	Increased collagenous extracellular matrix that is expanding the mesangium, obliterating capillary lumens, or forming adhesions to Bowman capsule. The sclerotic areas stain positively with periodic acid-Schiff (PAS), Masson's trichrome, and periodic acid-silver methenamine (PASM)
Hyaline	Glassy acidophilic extracellular material. Acellular material that stains red with eosin and PAS but is unstained by PASM. Contents include serum proteins, other glycoproteins and lipids.

and integrity of the glomerular basement membrane and mesangial matrix. Abnormal deposits (such as electron-dense immune deposits or organized fibrillary or microtubular deposits), can be detected in subepithelial, intramembranous, subendothelial and mesangial locations. Diagnostically informative ultrastructural abnormalities in the GBMs include thickening, thinning, lamellation, mesangial cell interposition and subendothelial electron-lucent expansion. Glomerular deposits with an organized substructure are pathognomic of some renal/systemic conditions or at least narrow the differential diagnosis substantially. Abnormalities in cells (podocytes/visceral epithelial cells

JAYPEE BROTHERS

Table 2.2 Patterns of glomerular injury observed by light microscopy and some but not all diseases that can cause each pattern of injury

No abnormality by light microscopy
No glomerular disease
Glomerular disease with no light microscopic changes (e.g. minimal change disease, thin basement membrane nephropathy)
Mild or early glomerular disease (e.g. lupus nephritis, IgA nephropathy, C1q nephropathy, membranous glomerulonephritis, amyloidosis, Alport syndrome, etc.)
Thick capillary walls without hypercellularity or mesangial expansion
Membranous glomerulonephritis (primary or secondary) with thick GBM
Thrombotic microangiopathy with expanded subendothelial zone
Pre-eclampsia/eclampsia with endothelial swelling
Fibrillary glomerulonephritis with predominance of capillary wall deposits
Thick capillary walls with mesangial expansion but little or no hypercellularity
Diabetic glomerulosclerosis with diffuse rather than nodular sclerosis
Secondary membranous glomerulonephritis with mesangial immune deposits
Amyloidosis
Monoclonal immunoglobulin deposition disease
Fibrillary glomerulonephritis
Dense-deposit disease
C3 glomerulonephritis
Focal segmental glomerular sclerosis without hypercellularity
Focal segmental glomerulosclerosis
Chronic sclerotic phase of focal glomerulonephritis
Hereditary nephritis (Alport syndrome)
Mesangial or endocapillary hypercellularity
Focal or diffuse mesangioproliferative glomerulonephritis
Focal or diffuse (endocapillary) proliferative glomerulonephritis
Acute diffuse proliferative postinfectious glomerulonephritis
Membranoproliferative glomerulonephritis
Dense-deposit disease
Extracapillary hypercellularity
ANCA crescentic glomerulonephritis (paucity of immunoglobulin by IFM)
Anti-GBM crescentic glomerulonephritis (linear immunoglobulin by IFM)
Immune complex and C3 glomerulopathy crescentic glomerulonephritis (granular immunoglobulin and/ or complement by IFM)
Collapsing variant of FSGS (including HIV nephropathy)
Membranoproliferative, lobular, or nodular pattern
Membranoproliferative glomerulonephritis
Dense-deposit disease
C3 glomerulonephritis
Diabetic glomerulosclerosis with nodular mesangial expansion (KW nodules)
Monoclonal immunoglobulin deposition disease with nodular sclerosis
Thrombotic microangiopathy
Fibrillary glomerulonephritis
Immunotactoid glomerulopathy
Advanced diffuse global glomerular sclerosis
End-stage glomerular disease
End-stage vascular disease
End-stage tubulointerstitial disease

JAYPEE BROTHERS

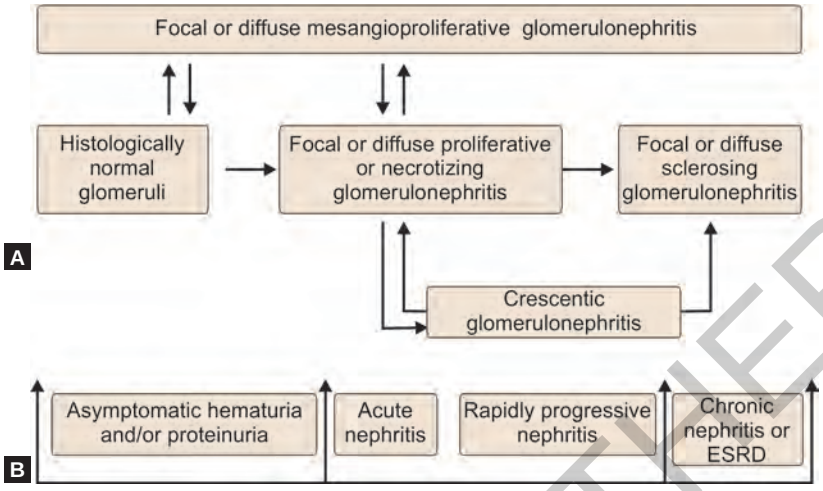

Figures 2.2A and B Correlation of various histopathologic patterns of glomerular response to injury correlated with the usual clinical manifestations of renal injury: (A) Spectrum of light microscopic morphology; (B) Spectrum of clinical manifestations
Source: Med Clin North Am. 1997;81:653.

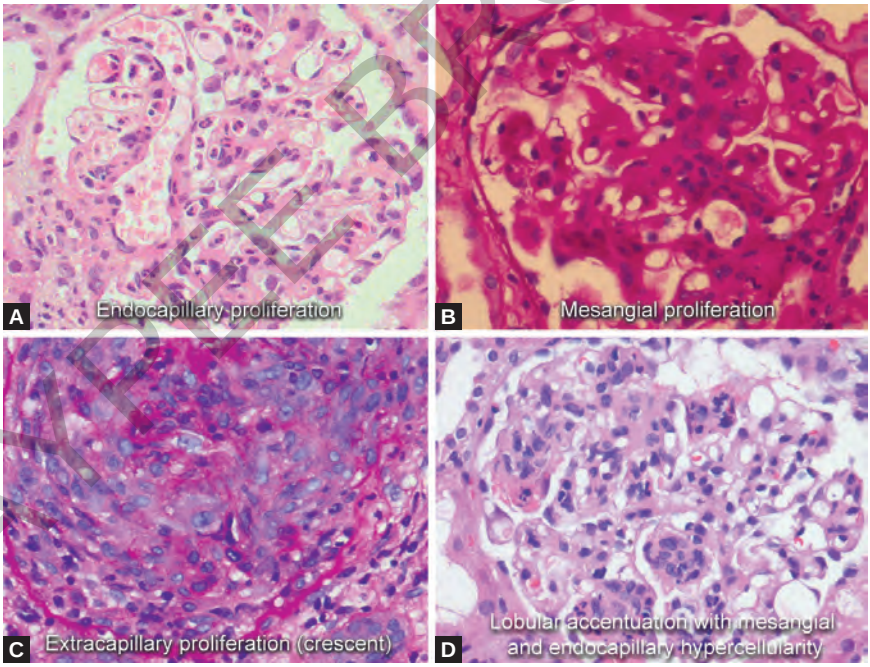

Figures 2.3A to D (A) Panel of photomicrographs show endocapillary proliferation as highlighted by glomerular capillary loops filled with polymorphs; (B) Mesangial proliferation as highlighted by mesangial matrix expansion with presence of 4 and/or more nuclei in the mesangial compartment; (C) Extracapillary proliferation with compressed glomerular tuft; (D) Lobular appearance of glomerulus as highlighted by mild mesangial and segmental endocapillary proliferation with nonuniform thickening of the capillary basement membrane (classical of MPGN)

JAYPEE BROTHERS

and endothelial cells) can be readily detected, such as effacement of podocytic foot processes seen with proteinuria or the swelling of endothelial cells seen with eclampsia/pre-eclampsia and the thrombotic microangiopathies. **Table 2.3** illustrates varied location of immune-complex deposits in electron microscopic examination and is demonstrated in **Figures 2.4A to D**.

Common Glomerular Diseases

Minimal change disease (MCD): Light microscopy of this disease shows no or minimal glomerular abnormality. The glomerular capillaries are patent, with

Table 2.3 Terms related to location of immune-complex deposits

Term	*Definition*
Subepithelial or epimembranous	Located between the glomerular basement membrane and the podocytes
Intramembranous	Within the basement membrane
Subendothelial	Between the glomerular basement membrane and the endothelium
Mesangial	Within the mesangium

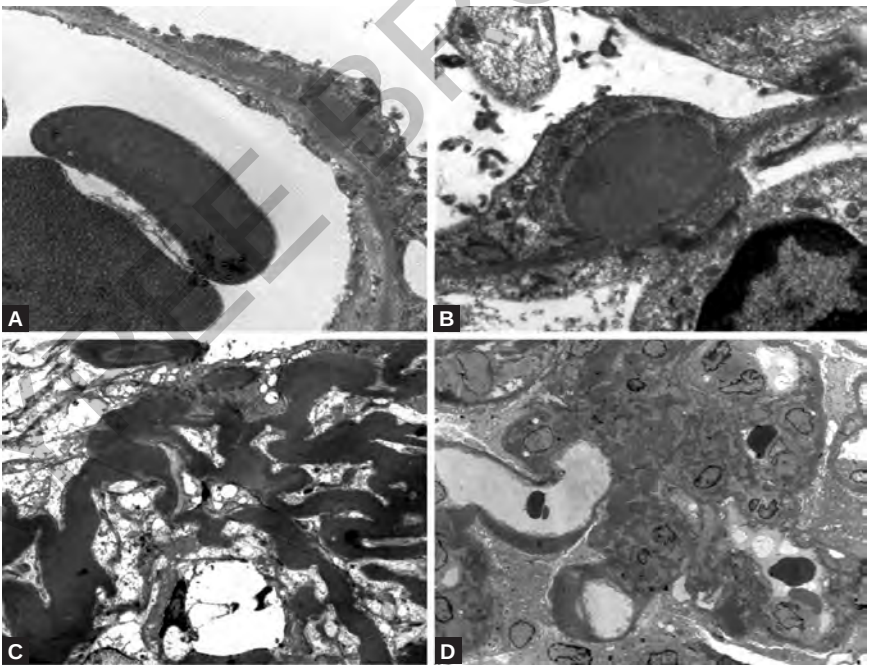

Figures 2.4A to D Panel of electron microscopic photomicrographs show varied location of immune-complex deposits: (A) Uniform sized subepithelial immune-complex like electron dense deposits (classical of Membranous GN); (B) Subepithelial hump (classical of postinfectious GN. Also seen in C3 GN); (C) Dense osmiophilic intramembranous deposits (classical of dense deposit disease); (D) Dominant mesangial deposits (classical of IgA nephropathy)

JAYPEE BROTHERS

neither thickening nor irregularity of the capillary wall. Some specimens show a slight increase in the mesangial matrix or cellularity, the presence of focal segmental glomerular collapse or scarring, endocapillary proliferation, or adhesions is not supportive of the diagnosis of MCD. Immunofluorescence show no staining for immunoglobulins in most cases except for minimal trace staining for IgM and C3. Presence of significant immune deposits excludes a diagnosis of MCD. Electron microscopy show diffuse effacement of podocytic foot processes **(Fig. 2.5)**.

Focal segmental glomerulosclerosis (FSGS): The "classic" lesion of FSGS consists of segmental solidification of the glomerular capillary tuft by an acellular extracellular matrix that is eosinophilic, periodic acid-Schiff (PAS) reactive, and argyrophilic. This may be accompanied by hyalinosis. FSGS lesions are often associated with adhesion to the Bowman capsule and the smallest lesions may consist of a simple synechial attachment, without prominent matrix accumulation in the underlying glomerular tuft. Immunofluorescence show nonspecific trapping for IgM and C3 in areas of segmental sclerosis. Electron microscopy show diffuse effacement of foot processes in primary FSGS and show very focal effacement in secondary FSGS **(Figs 2.6 and 2.7)**. The lack of standardized approach to definition and classification has hindered study of various morphological variants of FSGS (collapsing variant, tip variant, cellular variant, perihilar variant and FSGS NOS) **(Fig. 2.8)**. Collapsing variant is also known as collapsing glomerulopathy is characterized by capillary collapse with accompanied prominent epithelial cell

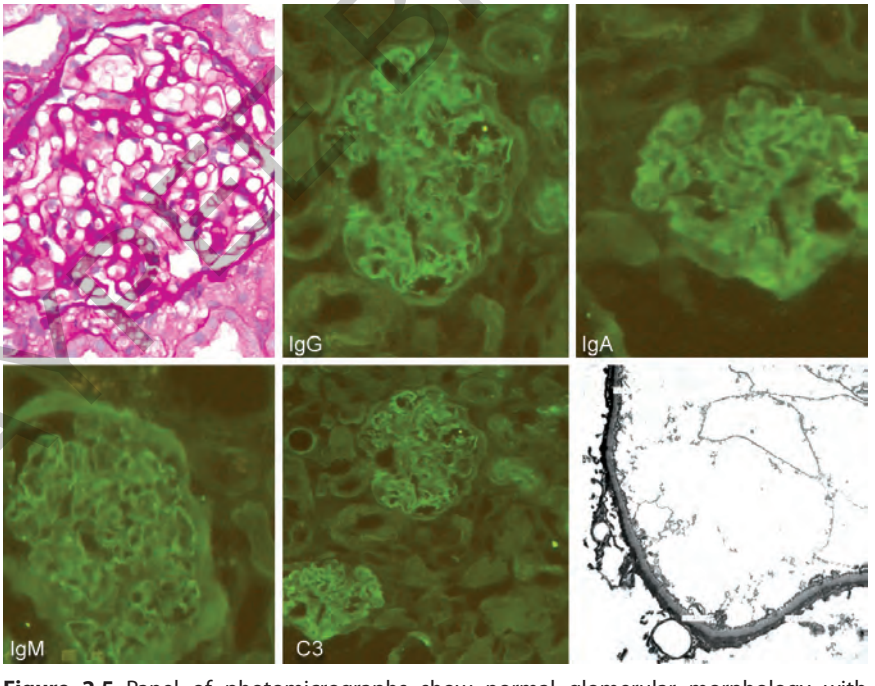

Figure 2.5 Panel of photomicrographs show normal glomerular morphology with completely negative immunofluorescence with diffuse foot process effacement in electron microscopy consistent with minimal change disease

JAYPEE BROTHERS

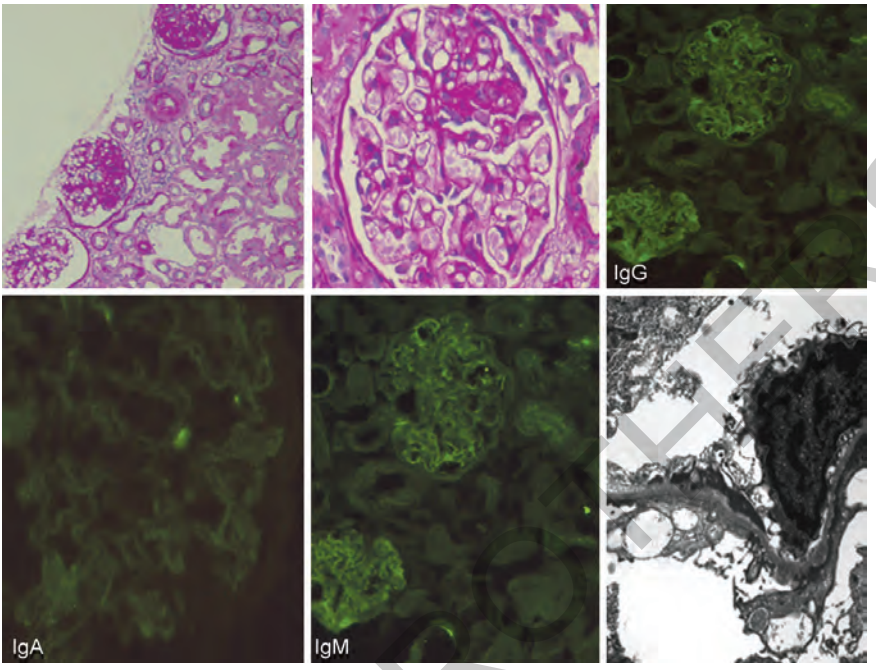

Figure 2.6 Panel of photomicrographs show a lesion of segmental sclerosis with synechiae formation, completely negative immunofluorescence with diffuse foot process effacement in electron microscopy consistent with primary focal segmental glomerulosclerosis

hypertrophy and hyperplasia within Bowman space. The epithelial cells typically line the external surface of the glomerular tuft but may fill the Bowman space, forming a "pseudocrescent". Collapsing FSGS usually presents with severe nephrotic syndrome and renal insufficiency and could be primary or secondary to viruses (HIV), drugs (pamidronate, interferon), and vaso-occlusive disease.

Membranous glomerulonephritis (MGN): The light microscopic findings in MGN may be subtle, especially in early cases, diagnostic changes may not be obvious by light microscopy alone. In these cases, IF and EM readily establish the diagnosis. In later stages there is marked global thickening of the glomerular basement membrane with vacuolization of the GBM. Immunofluorescence show granular deposition of IgG for C3 along capillary wall. Membranous lupus nephritis (secondary MGN) is a close light microscopy differential diagnosis for primary MGN, however secondary membranous lupus nephritis show intense IgA, C3 and C1q staining alongwith IgG in immunofluorescence. Fortunately, staining for the PLA2R has emerged as a far more effective strategy to differentiate primary and secondary forms of disease (PLA2R will be positive in primary MGN and negative in membranous lupus nephritis) **(Figs 2.9 and 2.10)**.

Primary IgA nephropathy: Light microscopy show varied glomerular histopathology in form of mesangial proliferation, segmental sclerosis, necrotizing lesion, endocapillary proliferation and extracapillary proliferation.

JAYPEE BROTHERS

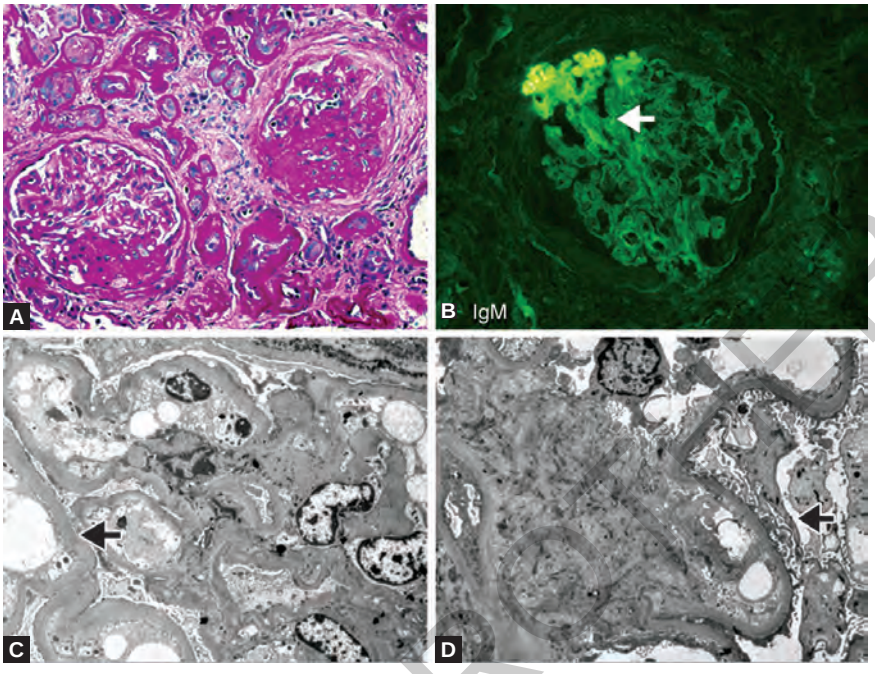

Figures 2.7A to D Panel of photomicrographs show segmental sclerosis with significant tubular atrophy and immunofluorescence show nonspecific segmental IgM trapping in area of sclerosis. The electron microscopy show preserved foot processes in the first EM image, however the second EM image show very focal foot process effacement (as highlighted by arrow head) and GBM thickening (related to underlying diabetic nephropathy) consistent secondary FSGS

Because of highly diverse histologic presentation of IgA nephropathy, a number of histologic classification systems have been devised and tested for their value in predicting clinical outcome. Recently Oxford MEST classification and scoring system has come in which includes four histologic parameters, M, E, S, and T:

- M0 or M1, indicating mesangial hypercellularity in ≤50% versus >50% of glomeruli
- E0 or E1, indicating endocapillary hypercellularity in zero versus one or more glomeruli
- S0 or S1, indicating segmental sclerosis in zero versus one or more glomeruli
- T0, T1, or T2, indicating TA/IF in ≤ 25%, 26% to 50%, or > 50% of renal cortex, respectively.

Immunofluorescence show dominant IgA deposits predominantly in the mesangium and very focally along capillary loops. Electron microscopy confirm electron dense deposits in mesangium **(Figs 2.11A and B)**.

Lupus nephritis: Renal biopsy plays a significant role in the management of patients with SLE. In some patients, it is instrumental in establishing a diagnosis of SLE. This is especially common early in disease and applies most frequently to patients with mesangial proliferative or membranous patterns who lack serologic markers of SLE and may present months or even years before the American

JAYPEE BROTHERS

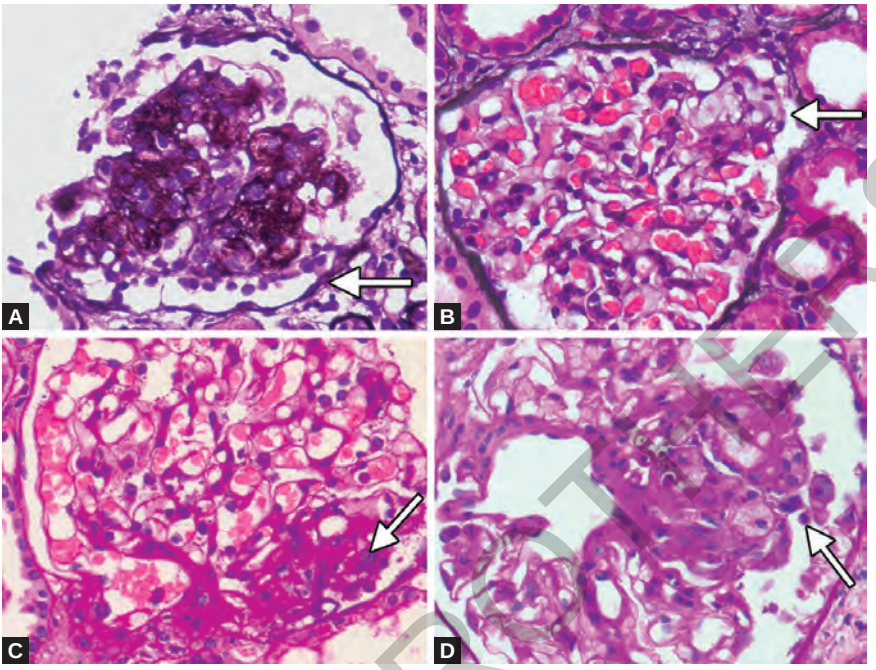

Figures 2.8A to D (A) Panel of photomicrographs show collapse of the glomerular tuft with proliferation of overlying podocytes appearing as crown over collapsed glomerular tuft (collapsing pattern of FSGS; (B) Other image show endocapillary foam cells projecting into the tubular pole (FSGS, tip variant; (C) Segmental sclerosis in perihilar location (FSGS, perihilar variant); (D) A glomerulus with segmental endocapillary hypercellularity occluding lumina, with or without foam cells and karyorrhexis (FSGS, cellular variant)

College of Rheumatology (ACR) criteria for SLE have been met. In cases in which diagnosis of SLE has already been made prior to renal biopsy, the biopsy provide information about the class, severity, activity, and chronicity of the lupus nephritis that cannot be accurately predicted on the basis of clinical manifestations. The major histologic abnormalities of the glomerulus include immune deposits, glomerular proliferation, influx of leukocytes, glomerular necrosis, and scarring. Glomerular proliferation may be mesangial, endocapillary, and extracapillary. Immunofluorescence show full house IF pattern with strong staining of the glomerulus for all immunoglobulins (IgG, IgA, IgM) and complements (C3, C1q). Electron microscopic examination reveals massive immune-complex deposits in subendothelial, subepithelial and mesangial location **(Figs 2.12A and B)**.

Crescentic glomerulonephritis: Light microscopic morphological recognition of crescentic glomerulonephritis is only the beginning of an adequate nephropathologic analysis. A pathologic diagnosis of crescentic glomerulonephritis is incomplete unless the disease is further categorized, which usually requires immunofluorescence and electron microscopy, serology, or both. Accurate and definite categorization of crescentic glomerulonephritis is critical for optimal patient clinical outcome, because one of the major positive

JAYPEE BROTHERS

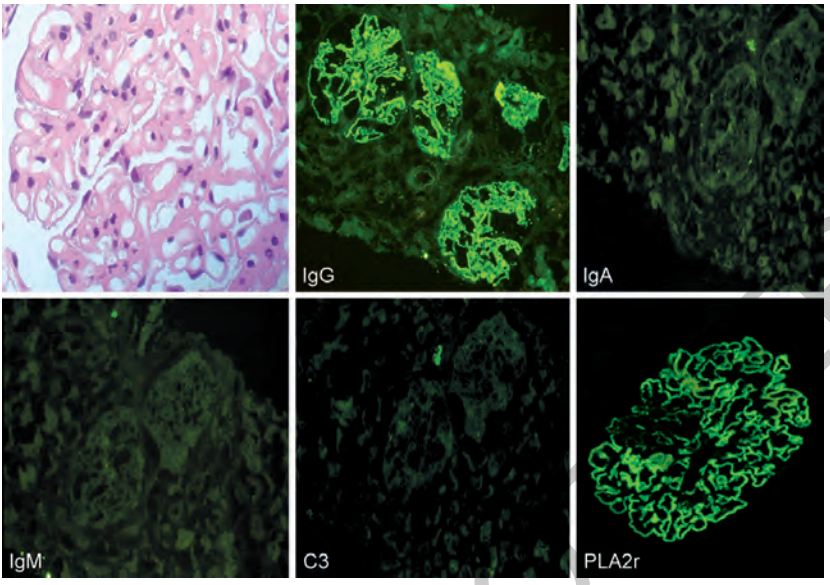

Figure 2.9 Panel of photomicrographs show diffuse thickening of the glomerular capillary wall along with granular deposition of IgG along capillary wall. Other immunoglobulins (IgA, IgM) and complements (C3,C1q) are negative. This immunofluorescence pattern is classical of primary idiopathic membranous glomerulonephritis. In addition, PLA2r staining is seen confirming idiopathic/primary membranous nephropathy

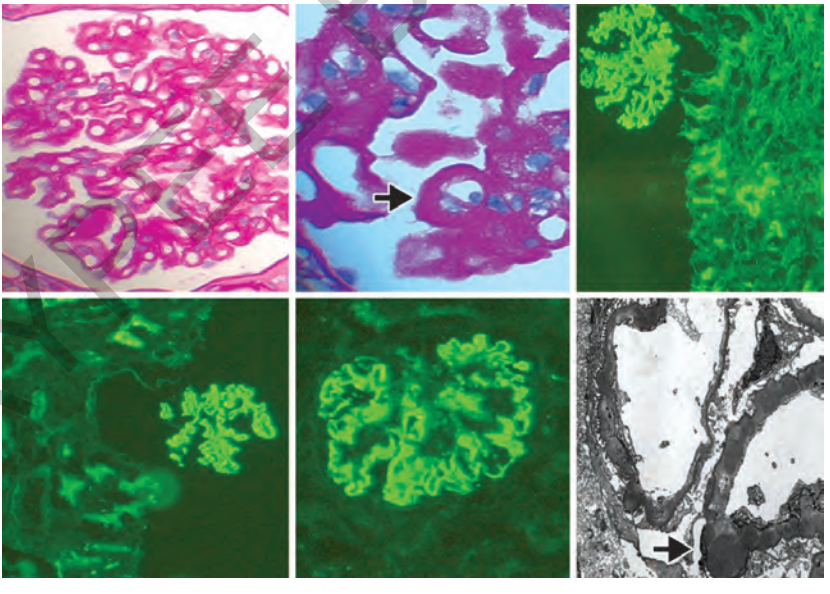

Figure 2.10 Panel of photomicrographs show diffuse thickening of the glomerular capillary wall along with granular deposition of IgG, C3 and C1q consistent with secondary membranous glomerulonephritis (Class V Lupus). In addition, the arrow heads point wire-loop like lesion in light microscopy and electron microscopy reveal immune-complex like electron dense deposits

JAYPEE BROTHERS

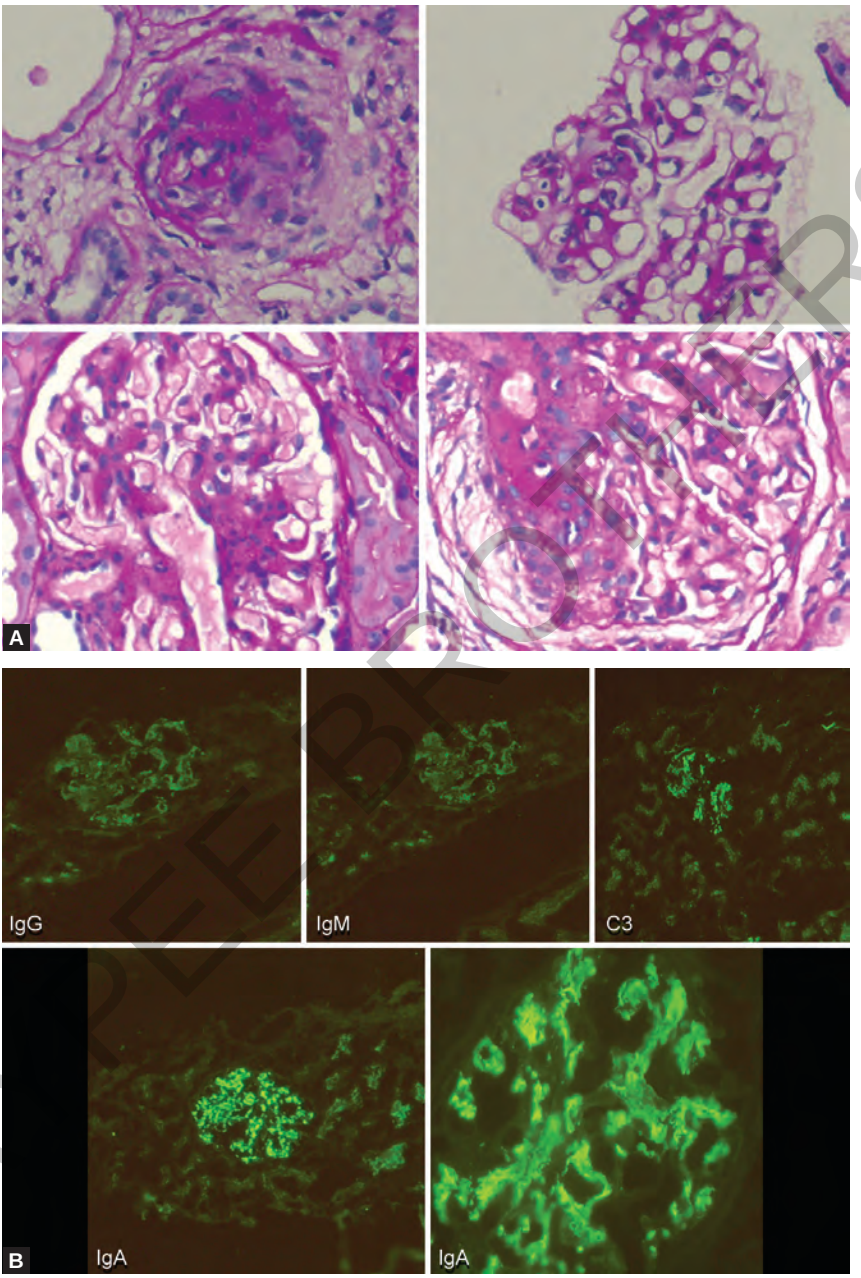

Figures 2.11A and B (A) Panel of photomicrographs show variable glomerular morphology in form of occasional glomerulus with fibrocellular crescent, occasional one with segmental endocapillary proliferation, occasional one with mesangial matrix expansion with mesangial hypercellularity and occasional one with segmental sclerosis. Variable glomerular morphology is commonly seen in IgA nephropathy; (B) Panel of immunofluorescence photomicrographs show dominant granular deposition of IgA in mesangium along with minimal staining for C3. IgG and IgM are negative. This immunofluorescence pattern is classical of IgA nephropathy

JAYPEE BROTHERS

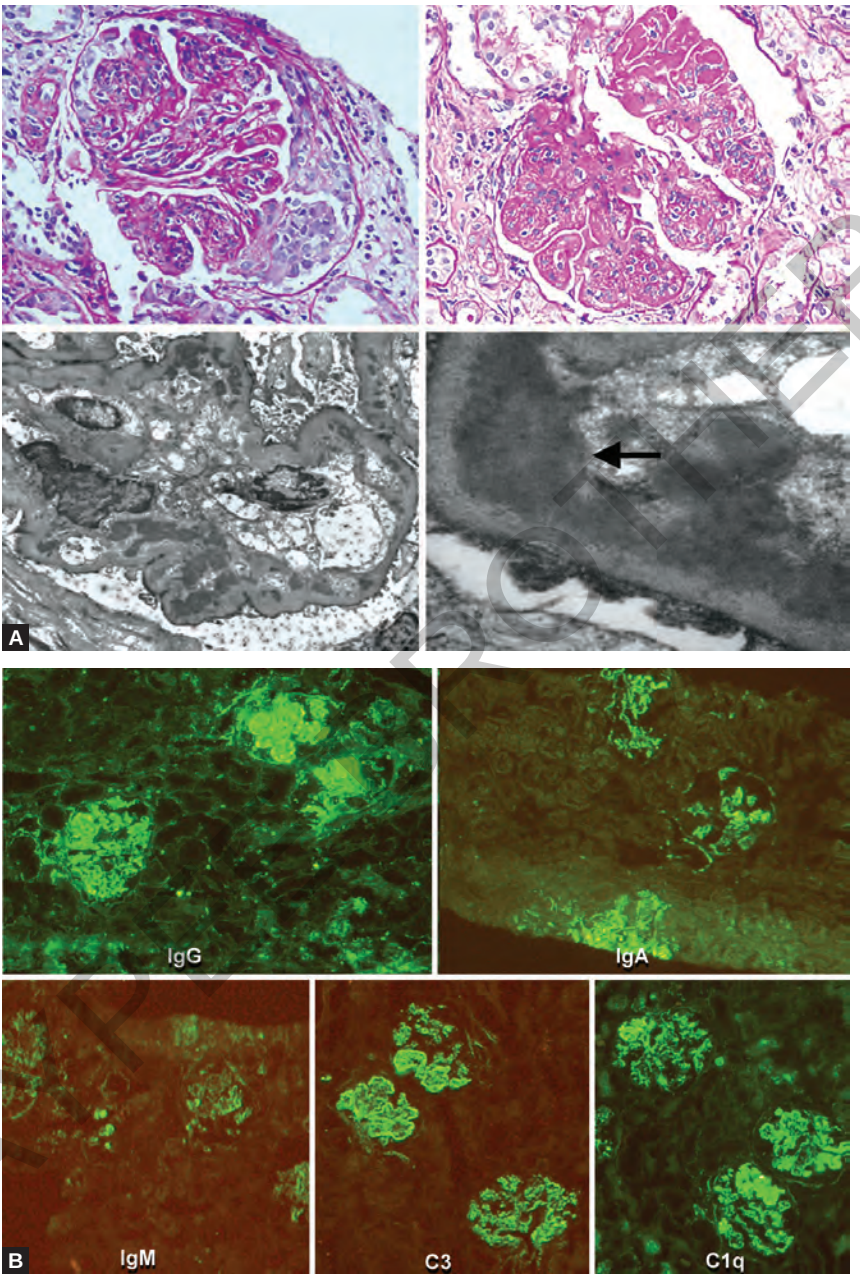

Figures 2.12A and B (A) Panel of photomicrographs show variable glomerular morphology in form of segmental endocapillary proliferation, small cellular crescent and wire-loop lesion with few hyaline thrombi. Electron microscopic photograph show massive immune-complex like electron dense deposits in the subendothelial location. Higher magnification of the immune-complex deposits show finger print impression (shown by an arrow); (B) Panel of immunofluorescence photomicrographs show full house IF pattern seen in diffuse proliferative lupus nephritis (Class IV)

JAYPEE BROTHERS

prognostic factors in the most aggressive forms of crescentic glomerulonephritis is rapid institution of immunosuppressive therapy.

Crescentic glomerulonephritis is categorized by immunofluorescence into *anti-GBM* crescentic glomerulonephritis with linear GBM staining for immunoglobulin IgG, *immune complex* crescentic glomerulonephritis with granular staining of glomeruli for immunoglobulin (IgG, IgA, IgM) or complement (C3, C1q), or crescentic glomerulonephritis with little or no glomerular staining for immunoglobulin (i.e. *pauci-immune* crescentic glomerulonephritis) (**Figs 2.13A to D**). Varying ages of crescent (from cellular to fibrocellular and fibrous crescents) are more commonly seen in pauci-immune GN and in anti-GBM GN crescents are mostly of the same age **(Fig. 2.14)**.

Proliferative glomerulonephritis with isolated C3 deposits in immunofluorescence: Light microscopic morphology of diffuse or focal proliferative GN (with endocapillary, extracapillary or mesangial proliferation) with isolated or dominant C3 deposits is characteristically seen in *postinfectious GN* and

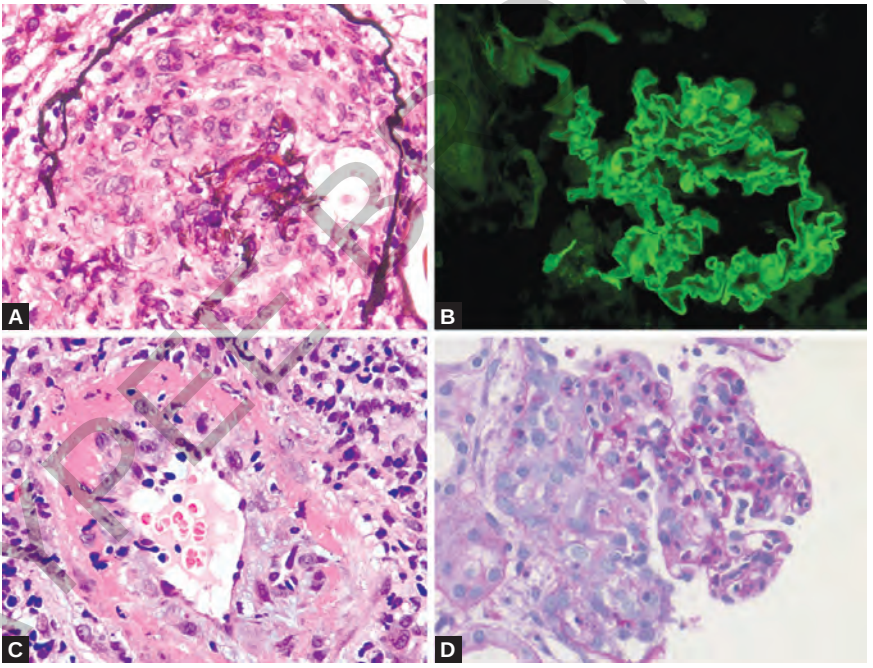

Figures 2.13A to D (A) Highlight presence of global circumferential cellular crescent with compressed underlying glomerular tuft. The present morphology is classical of anti-GBM disease or pauci-immune glomerulonephritis. Presence of linear staining along glomerular basement membrane confirm the diagnosis of anti-GBM disease (B) and its absence along with absence or very minimal staining for other immunoglobulins confirm the diagnosis of pauci-immune glomerulonephritis. In addition, pauci-immune GN biopsy show evidence of vasculitis in form of transmural arteritis or fibrinoid necrosis of the vessel wall (C); (D) small cellular crescent with endocapillary proliferation in the underlying glomerular tuft, feature of immune-complex/compliment mediated glomerulonephritis. The immunofluorescence show presence of dominant C3 deposits (not shown)

JAYPEE BROTHERS

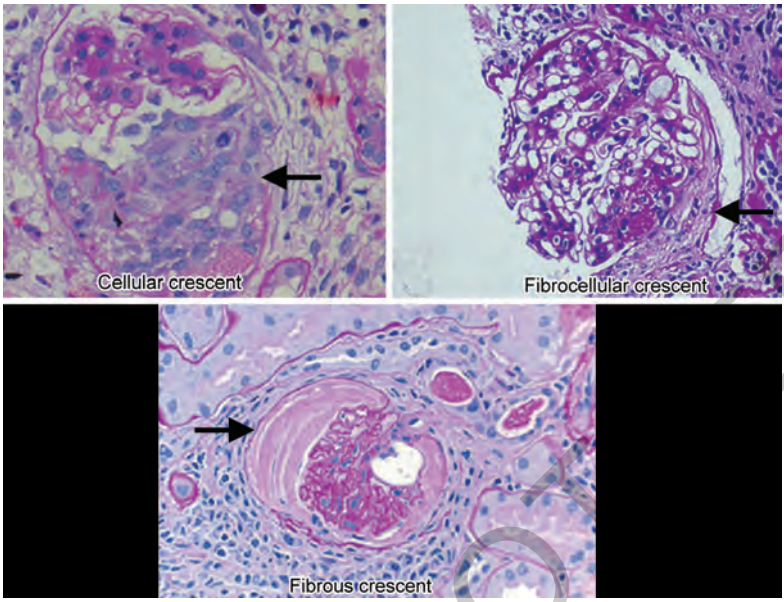

Figure 2.14 Panel of light microscopic photomicrographs show crescents of varying ages ranging from cellular to fibrocellular to fibrous crescent (highlighted by arrow)

C3 glomerulopathy (which includes C3 GN and dense deposit disease). The characteristic features of postinfectious glomerulonephritis on kidney biopsy are a proliferative glomerulonephritis on light microscopy, bright C3 staining with or without immunoglobulins on immunofluorescence microscopy, and subepithelial deposits called 'humps' on electron microscopy **(Figs 2.15A to D)**. In some cases, the diagnosis of postinfectious glomerulonephritis is made on the basis of these biopsy findings even in the absence of any clinical, bacterial, or serological evidence of a preceding infection. If there is persistent low C3 levels along with persistent hematuria/proteinuria then these patients should be evaluated for alternate complement pathway defects and possibility of C3 glomerulopathy remains a strong possibility. Definite categorization of C3 glomerulopathy into *C3 glomerulonephritis* and *dense deposit disease (DDD)* requires electron microscopy as dense deposit disease will show dense osmiophilic intramembranous deposits whereas C3 GN show pale deposits in mesangium, subendothelial, occasionally subepithelial and intramembranous location.

Membranoproliferative glomerulonephritis (MPGN): The definite diagnosis of MPGN is based on renal biopsy. Renal histological features include mesangial widening due to an increase in matrix and cells, and diffuse capillary wall thickening resulting from the presence of subendothelial and/or intramembranous immune deposits and mesangial cell interposition.

Historically, the MPGN was subclassified into MPGN type I (the most common form), type II (dense deposit disease), and type III based on combined features of light, immunofluorescence, and electron microscopy. In recent years, there have been great advances in our understanding of the pathogenesis of

JAYPEE BROTHERS

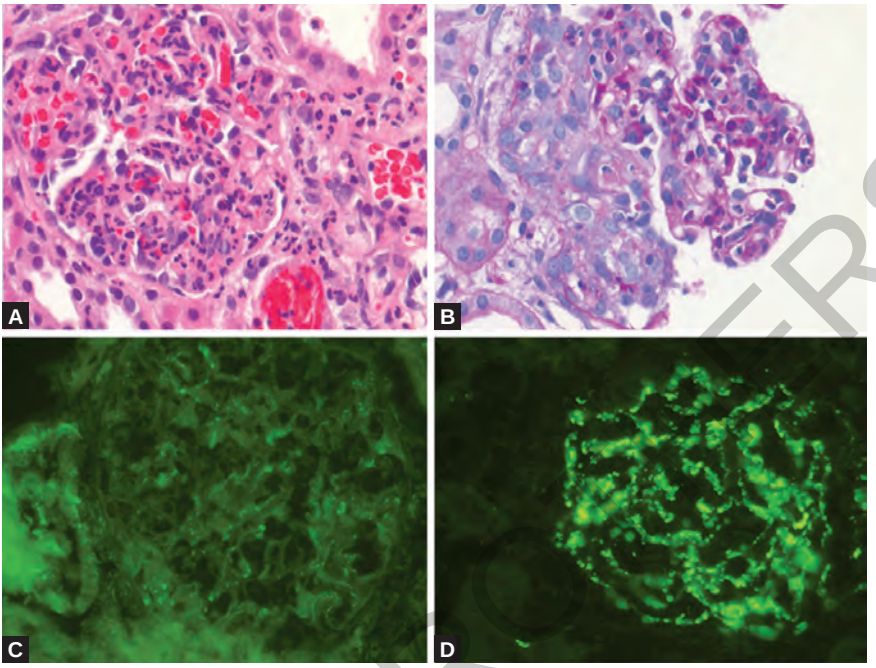

Figures 2.15A to D (A and B) Highlight presence of global endocapillary proliferation rich in polymorphs. An occasional glomerulus show a small cellular crescent and underlying glomerular tuft show endocapillary proliferation. Immunofluorescence show absent to trace IgG staining (C) and strong 3+ coarse granular staining for C3 (D). In view of isolated C3 deposits and diffuse endocapillary proliferation rich in neutrophils and a recent history of infection, case was reported as diffuse proliferative GN consistent with postinfectious GN

MPGN, particularly in the area of complement-mediated C3 glomerulonephritis, including DDD and C3 glomerulonephritis. The current classification recognizes the importance of IF in further subdividing MPGN into immune-complex mediated MPGN with glomerular immunoglobulins and complement deposition and MPGN with abnormalities in alternate complement pathway regulation resulting in isolated C3 deposits with little or no immunoglobulins by IF. MPGN type II is currently designated as DDD and is recognized as a variant of C3 glomerulopathy.

MPGN type I is commonly associated with infections, autoimmune diseases and dysproteinemic state **(Figs 2.16A and B)**.

Diagnostic criteria for C3 glomerulopathy ***(Figs 2.17A to D)***:

- Membranoproliferative glomerulonephritis (MPGN) pattern on light microscopy
- C3-predominant staining with staining ≥2 + (on a 0–3 + scale)
- Electron-dense deposits by electron microscopy that are of the immune complex type.

JAYPEE BROTHERS

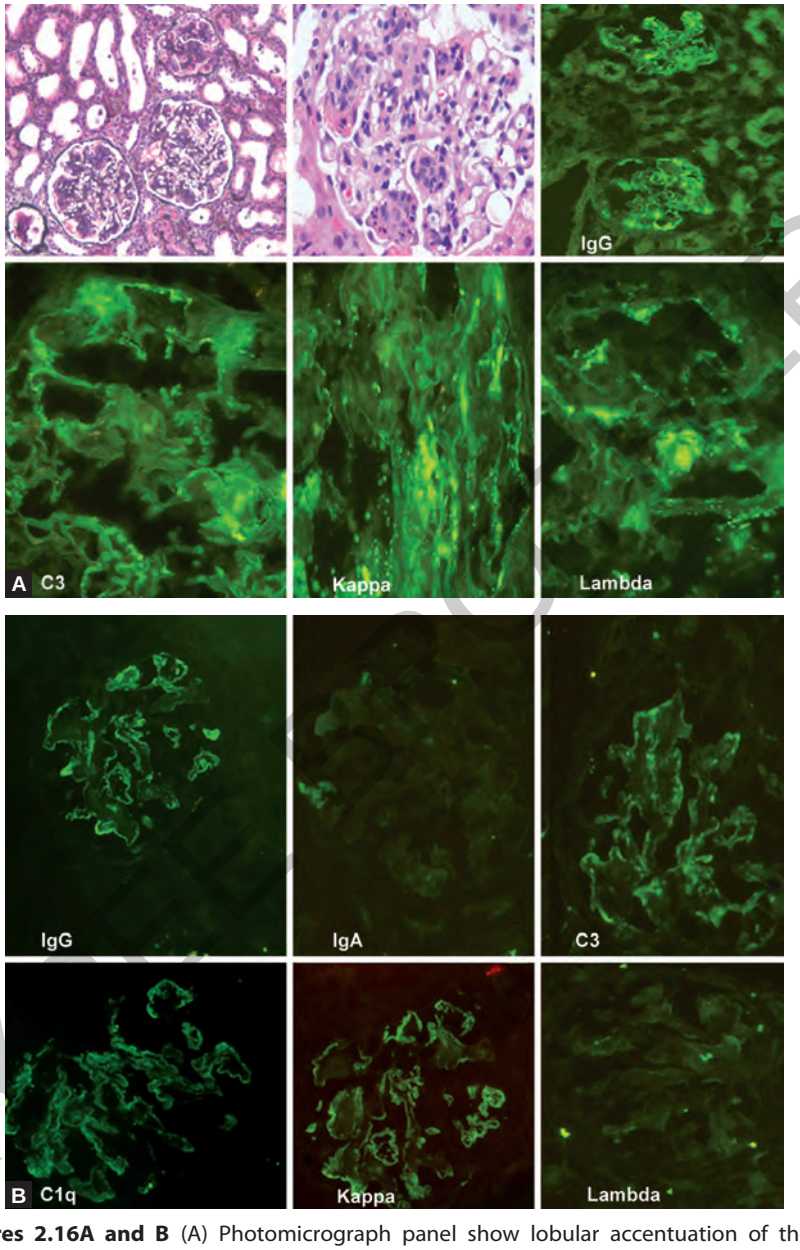

Figures 2.16A and B (A) Photomicrograph panel show lobular accentuation of the glomerulus due to mesangial and segmental endocapillary proliferation (classical of MPGN). Immunofluorescence show both IgG and C3 deposits. Both kappa and lambda show positivity, thereby excluding any monoclonal restriction or a dysproteinemic state. This case was reported as Immune-complex mediated MPGN; (B) Photomicrograph panel show immunofluorescence images in a case of MPGN. IF images show granular deposition of immunoglobulin (IgG) and complements (c3, c1q), however kappa is positive and lambda is negative. The case was reported as MPGN IgG kappa (MPGN with dysproteinemia)

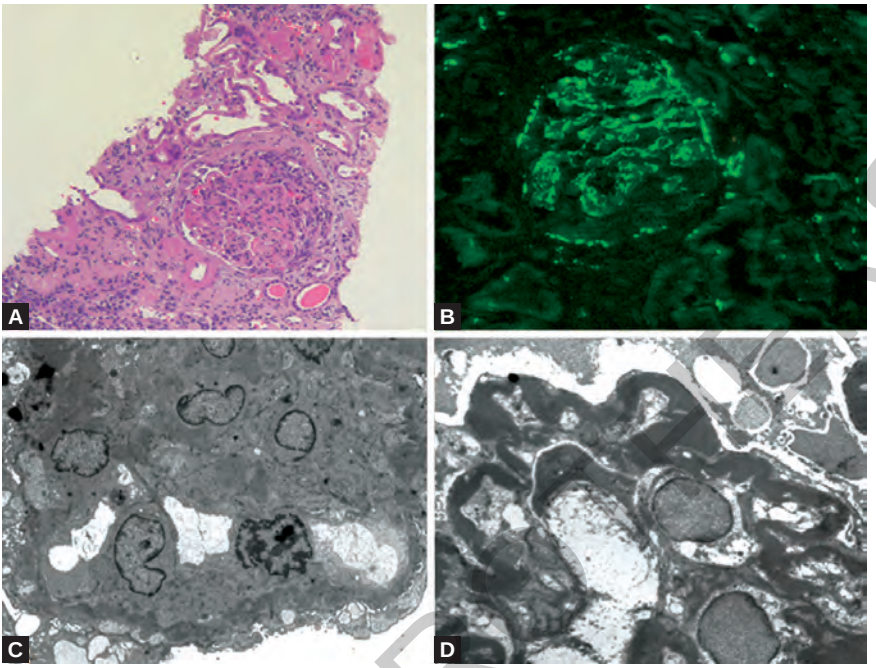

Figures 2.17A to D (A) Photomicrograph panel show immunofluorescence images in a case of C3 glomerulopathy. Light microscopy show lobular accentuation; (B) IF image show granular deposition of C3 only; (C) Immunoglobulins are negative (not shown). Based on light microscopy and isolated C3 deposits, diagnosis is C3 glomerulopathy. If electron microscopy show predominantly less osmiophilic or less electron dense deposits predominantly in the mesangial and subendothelial location than diagnosis of C3 glomerulonephritis is given; (D) However, if there are more dense osmiophilic intramembranous deposits than it is diagnosed as DDD

Diagnostic criteria for C3 glomerulonephritis:

- MPGN pattern (most common); less common patterns include mesangial proliferative, diffuse proliferative, crescentic, or sclerosing.
- C3-dominant staining ≥ 2 + (on a 0–3 + scale), ± Ig trace to 1+.
- Electron-dense deposits, often large mesangial and subendothelial, ± intramembranous and subepithelial deposits. The only C3 deposits appear different from immune deposits as they are lobular, paler, waxy, smooth and not as sharp.

Amyloidosis: The light microscopic features of amyloidosis are always the same, regardless of the type of amyloid. In hematoxylin and eosin-stained sections, amyloid appear as eosinophilic, amorphous, "hyaline" material. In a PAS stain, amyloid is usually weakly positive and in silver stain amyloid is silver negative. A definite diagnosis of amyloid requires examination under polarized light, with the demonstration of apple green birefringence. If there is either of the light chain restriction then amyloid is likely primary in nature, however if no light chain restriction is demonstrated and serum amyloid associated protein is positive in areas of amyloid deposition then it is secondary amyloidosis **(Figs 2.18 and 2.19)**.

JAYPEE BROTHERS

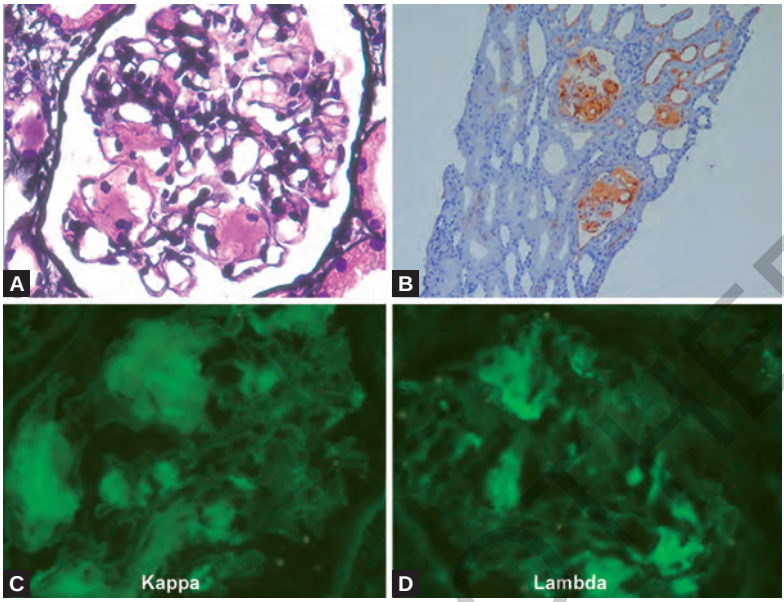

Figures 2.18A to D Photomicrograph panel show images in a case of secondary amyloidosis. Light microscopy show mesangial expansion by silver negative material (A) which show strong staining for serum amyloid associated protein [SAA immunohistochemistry, (B)]. Kappa and lambda immunofluorescence show no monoclonal restriction, thereby excluding primary amyloidosis (C and D)

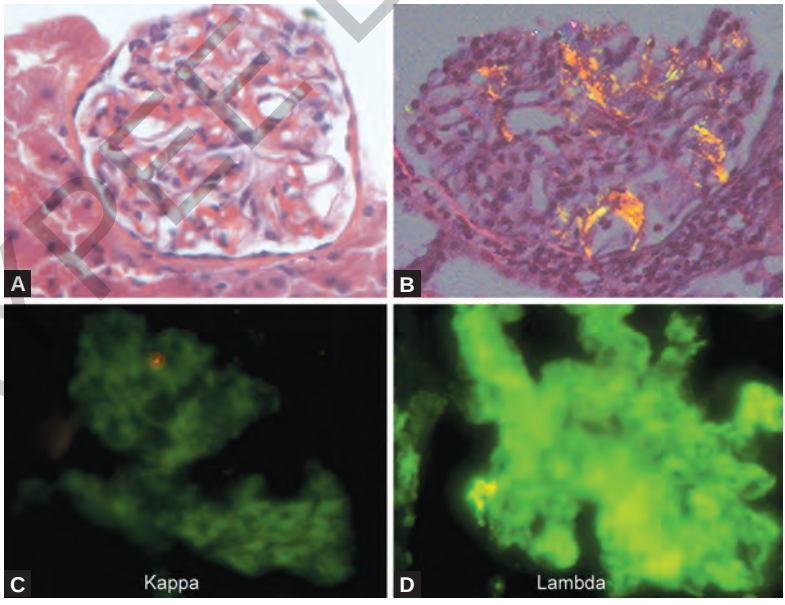

Figures 2.19A to D Photomicrograph panel show images in a case of primary amyloidosis. Light microscopy show mesangial expansion by congophilic material (A) which show apple-green birefringence thereby confirming amyloid deposition (B). Kappa and lambda immunofluorescence show lambda light chain restriction, thereby confirming primary amyloidosis (C and D)

JAYPEE BROTHERS

Evaluation of Tubular Compartment

Diseases primarily affecting the renal tubules can be divided histologically into following headings: acute tubular epithelial injury (including acute tubular necrosis), tubulointerstitial inflammation, tubular casts, tubulitis, and chronic changes (tubular atrophy).

In normal renal cortex, tubules are arranged in back to back manner, virtually without interstitium. The histologic differential diagnosis between primary acute tubular injury (ATI) with secondary interstitial inflammation versus primary acute tubulointerstitial nephritis (TIN) is critical but often difficult. Since most inflammatory diseases affecting the tubules also involve the interstitium and because interstitial inflammation may be accompanied by tubulitis, the term acute or chronic tubulointerstitial nephritis is more appropriate than interstitial nephritis. **Table 2.4** illustrates terms used to describe histopathology lesions in tubules. Light chain (myeloma) cast nephropathy show tubular casts commonly in distal nephrons. In fact, most casts are located in the collecting ducts, and if medulla is not included in the renal biopsy specimen, the diagnosis may be missed **(Figs 2.20A to D)**.

Table 2.4 Terms used to describe histologic lesions of the tubules

Term	*Definition*
Acute tubular injury	Acute simplification with loss of brush border and flattening of cells without necrosis
Acute tubular necrosis	Coagulative necrosis of the tubular epithelium, usually secondary to toxins and/or ischemia
Tubulitis	Presence of lymphocytes/other inflammatory cells infiltrating the tubular epithelium
Tubular atrophy	Wasting of tubules as a result of ischemia, obstruction, or severe cellular injury. The tubular cells are usually simplified, reduced in size, or dilated and filled with casts. The tubular basement membranes are often thickened and wrinkled
Tubular casts	Various coagulated proteins and formed elements in the tubular lumens (e.g. RBC casts, WBC casts, hyaline or pigmented casts).
Myeloma fractured tubular casts	Distal nephron casts with brittle consistency, resuting in fracture planes and associated multinucleated giant cell reaction around cast
Hydropic change	Fine regular vacuolization of the proximal tubules
Hyaline droplet formation	PAS/silver-positive resorption droplets in the proximal tubular epithelium, betraying glomerular permeability to proteins
Hypokalemic changes	Irregular-sized, course vacuoles occupying the renal epithelium
Intranuclear inclusions	Dense inclusions in the nuclei often indicative of viral infection. Need to rule out lead nephropathy, tubular epithelial cell regeneration following ATN

JAYPEE BROTHERS

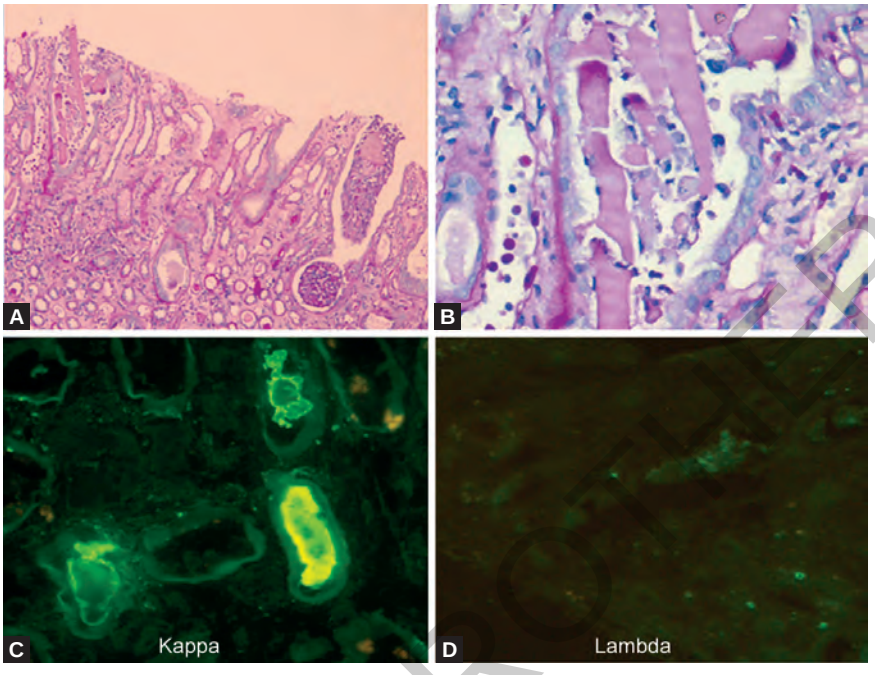

Figures 2.20A to D Photomicrograph panel show images in a case of cast nephropathy. Light microscopy show fractured PAS negative fractured casts with surrounding tubular epithelial cell reaction (A and B). Kappa and lambda immunofluorescence show kappa light chain restriction (C and D)

Evaluation of Interstitial Compartment

The interstitium is that part of renal parenchyma not occupied by glomeruli, tubules, and vessels. It occupies <5% of the cortex and outer medulla but occupies a greater percentage of the inner medulla where the tubules are more widely spaced. Increased interstitial volume due to fibrosis correlates with impaired renal function and is a negative prognostic indicator in diseases of the interstitium as well as in diseases involving the other renal compartments. **Table 2.5** highlights terms used to describe interstitial pathology. **Table 2.6** focuses on the terms that describe vascular disease in renal biopsy and their major features.

Evaluation of Vascular Compartment

Vessels may be damaged by hypertension, inflammation, deposition of material, toxins, and hypercoagulable states. Each of these mechanisms of injury results in different forms of damage that may aid in determination of the cause of injury. Vasculitis has mural infiltration by leukocytes, often with leukocytoclasia. Materials such as amyloid or monoclonal light chain may be deposited in the wall of the vessel, interfering with its normal function.

JAYPEE BROTHERS

Table 2.5 Terms used to describe histologic findings in interstitial disease

Term	*Definition*
Interstitium	Space between the glomeruli, tubules, and blood vessels
Edema	Interstitial expansion by protein—poor, aqueous fluid
Interstitial foam cells	Interstitial macrophages with cytoplasmic lipid-containing vacuoles
Fibrosis	Interstitial expansion by collagen-rich matrix and increased fibroblasts
Granuloma	Inflammatory reaction characterized by coalescence of epithelioid macrophages with or without surrounding lymphocytes, fibroblasts, and giant cells
Primary interstitial disease	Renal injury with primary pathology in the interstitium
Secondary interstitial disease	Secondary pathologic changes in the interstitium caused by primary injury to the glomeruli, tubules, or blood vessels
Tubulointerstitial nephritis	Inflammation of the interstitium and tubules
Acute TIN, pathologic	Interstitial leukocyte infiltrates with or without edema and tubulitis in the absence of interstitial fibrosis and tubular atrophy
Chronic TIN, pathologic	Interstitial inflammation with fibrosis and tubular atrophy
Acute pyelonephritis	Acute TIN caused by bacterial infection of the kidney
Chronic pyelonephritis	Chronic TIN caused by bacterial infection of the kidney

Table 2.6 Terms used to describe vascular disease in renal biopsy and their major pathologic features

Term	*Major pathologic features*
Arterionephrosclerosis, including chronic hypertensive nephrosclerosis and age-related arterionephrosclerosis	Arterial fibrotic intimal thickening, arteriolar hyalinosis, regional (often subcapsular) global glomerular sclerosis with adjacent tubular atrophy, interstitial fibrosis, and chronic inflammation
Malignant hypertensive nephropathy and thrombotic microangiopathies	Arterial edematous and myxoid intimal thickening, arteriolar fibrinoid necrosis, glomerular subendothelial and acute ischemic tubular epithelial injury
Renal artery stenosis with chronic ischemic nephropathy	Renal artery stenosis (e.g. caused by atherosclerosis, arteriosclerosis, arteritis, fibromuscular dysplasia, vasculitis, retroperitoneal fibrosis, etc.), tubular "endocrine" atrophy, and glomerular crowding
Renal atheroembolization (cholesterol crystal embolization)	Cholesterol clefts in vascular lumens with or without adjacent atheromatous debrosi, thrombosis, leukocytes or fibrosis

JAYPEE BROTHERS

CONCLUSION

Renal diagnosis requires a more sophisticated integeration of histology with immunopathology, ultrastructure, clinical information, and laboratory data.

Multiple Choice Questions

1. **PLA2r immunofluorescence is positive in:**
   a. Primary membranous glomerulonephritis
   b. Class V lupus nephritis
   c. MPGN
   d. Secondary membranous glomerulonephritis

2. **Subepithelial hump are seen in:**
   a. Postinfectious glomerulonephritis
   b. C3 glomerulonephritis
   c. Dense deposit disease
   d. Postinfectious and C3 glomerulonephritis

3. **Dense deposit disease show dominant:**
   a. Subepithelial deposits
   b. Subendothelial deposits
   c. Intramembranous deposits
   d. Mesangial deposits

4. **Mesangioproliferative pattern is commonly seen in:**
   a. IgA nephropathy
   b. Membranous GN
   c. Postinfectious GN, resolving phase
   d. IgA nephropathy and resolving phase of postinfectious GN

5. **Dominant C3 deposits are seen in:**
   a. C3 glomerulonephritis
   b. Dense deposit disease
   c. Postinfectious GN
   d. All the above

6. **Myeloma cast nephropathy show one of the following features:**
   a. Tubular hyaline casts
   b. Fractured cast with associated epithelial reaction
   c. More commonly lambda restriction
   d. Always associated with light chain deposition disease

7. **Linear staining along glomerular capillary wall for IgG is seen in:**
   a. Membranous glomerulonephritis
   b. Membranoproliferative glomerulonephritis
   c. Anti-GBM disease
   d. Pauci-immune GN

8. **Pauci-immune GN is characterized by:**
   a. Normal glomerular morphology
   b. Absence of crescents
   c. Absent or trace immunoglobulin staining in immunofluorescence
   d. Massive immunoglobulin deposition in immunofluorescence

JAYPEE BROTHERS

9. C3 glomerulopathy include following entities:
a. Postinfectious GN
b. Pauci-immune GN
c. C3 GN and dense deposit disease
d. Only dense deposit disease

10. Following comment is correct about FSGS:
a. Primary FSGS is characterized by diffuse foot process effacement
b. Secondary FSGS is characterized by diffuse foot process effacement
c. FSGS show massive immune-complex deposits
d. FSGS show true crescents

Answers

1. a 2. d 3. c 4. d 5. d 6. b 7. c 8. c
9. c 10. a

SUGGESTED READING

1. Cattran DC, Coppo R, Cook HT, Feehally J, Roberts IS, Troyanov S, et al. Working Group of the International IgA Nephropathy Network and the Renal Pathology Society: The Oxford classification of IgA nephropathy: Rationale, clinicopathological correlations, and classification. Kidney Int. 2009;76:534-45.
2. Chang A, Gibson IW, Cohen AH, Weening JW, Jennette JC, Fogo AB. Renal Pathology Society: A position paper on standardizing the nonneoplastic kidney biopsy report. Hum Pathol. 2012;43:1192-6.
3. Falk RJ, Nachman PH, Hogan SL, Jennette JC. ANCA glomerulonephritis and vasculitis: A Chapel Hill perspective. Semin Nephrol. 2000;20:233-43.
4. Jennette JC, Olson JL, Silva FG, D' Agati VD. Heptinstall's pathology of the kidney, 7th edn. Wolter Kluwer; 2015.
5. Larsen CP, Walker PD. Redefining C3 glomerulopathy: 'C3 only' is a bridge too far. Kidney International. 2013;83:331-3.
6. Sethi S, Fervenza FC. Membranoproliferative glomerulonephritis—a new look at an old entity. N Engl J Med. 2012;366:1119-31.
7. Weening JJ, D'Agati VD, Schwartz MM, Seshan SV, Alpers CE, Appel GB, et al. The classification of glomerulonephritis in systemic lupus erythematosus revisited. J Am Soc Nephrol. 2004;15:241-50.
8. Zand L, Fervenza FC, Nasr SH, Sethi S. Membranoproliferative glomerulonephritis associated with autoimmune diseases. J Nephrol. 2014;27:165-71.

JAYPEE BROTHERS

for detailed information on medicine books, visit our website www.jaypeebrothers.com, for detailed information on medicine books, visit our web

Manual of Nephrology

Salient Features

- It is a quick-reference guide for diagnosis and management of common renal problems encountered in routine clinical practice
- Covers the various topics in nephrology including basics of anatomy and physiology, important investigations in renal diseases, management of electrolyte disorders, approaches to acute kidney injury (AKI), chronic kidney disease (CKD) and nutritional management of kidney diseases
- Includes a separate chapter on the urological issues encountered in day-to-day practice
- Explains the extensive use of tables, flow charts and figures for easy and quick reference
- Includes clinically oriented multiple choice questions (MCQs) at the end of each chapter
- It is targeted at the interns, residents, postgraduate students, general physicians, nephrology fellows and practitioners, and the manual will become your favorite reference text to enhance your knowledge and help you in your clinical practice.

Pranaw Kumar Jha MD (Internal Medicine) DNB (Nephrology) is Consultant, Division of Nephrology and Transplant Medicine, Medanta Kidney and Urology Institute, Medanta—The Medicity, Gurgaon, Haryana, India. He has keen interest in academics and is actively engaged in teaching nephrology and transplant fellows. He is a Mentor in Young Nephrologist Committee of International Society of Nephrology as well as an Advisor in European Renal Association-European Dialysis and Transplant Association (ERA-EDTA) Young Nephrologist Platform. He has presented papers in various national and international conferences and authored chapters in various books.



Vijay Kher MD (Internal Medicine) DM (Nephrology) FAMS FRCPE is the Chairman, Division of Nephrology and Transplant Medicine, Medanta Kidney and Urology Institute, Medanta—The Medicity, Gurgaon, Haryana, India. He has established academic and clinical departments of nephrology as Sher-i-Kashmir Institute of Medical Sciences, Srinagar, Jammu and Kashmir; Sanjay Gandhi Postgraduate Institute of Medical Sciences (SGPGIMS), Lucknow, Uttar Pradesh; Apollo Hospitals; Fortis Group of Hospitals (NCR and New Delhi). He is the Chair of Indian Society of Nephrology Scientific Committee and South Asia Regional Coordinator for International Society of Nephrology Clinical Research Committee. An astute clinician, a teacher par excellence and a keen researcher, he combines these assets with a friendly and inclusive demeanor to inspire the Nephrology fraternity in India by his professional dedication and academic excellence. He has more than 170 scientific publications in peer-reviewed journals and authored 10 books and many chapters in various books.



Available at all medical bookstores or buy online at www.jaypeebrothers.com

JAYPEE BROTHERS
Medical Publishers (P) Ltd.
www.jaypeebrothers.com

Join us on facebook.com/JaypeeMedicalPublishers

Shelving Recommendation
MEDICINE

ISBN 978-93-5250-162-5