athology books, visit our website **www.jaypeebrothers.com,** for detailed information on pathology books

CASE-BASED APPROACH IN FINE NEEDLE ASPIRATION CYTOLOGY

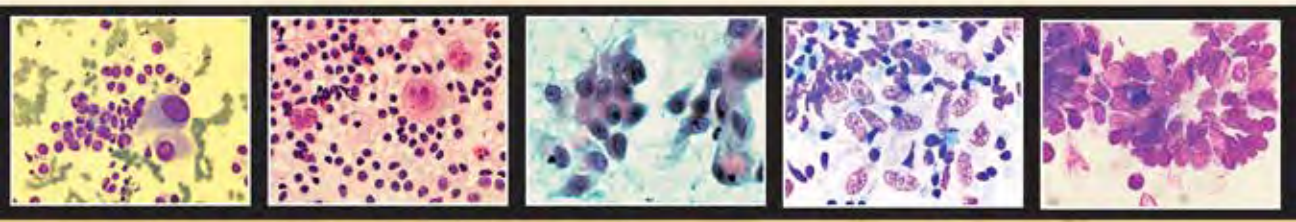

PRANAB DEY

JAYPEE

Contents

1. General Cytology 1
2. Head, Neck and Salivary Gland 18
3. Thyroid 70
4. Breast 99
5. Thorax 138
6. Lymph Node 173
7. Abdomen 206
8. Pelvic Organs, Gonads and Prostate 269
9. Soft Tissue, Bone and Skin 297
10. Miscellaneous 348

CHAPTER

2 Head, Neck and Salivary Gland

QUESTIONS

Problem 2.1

A 26-year-old female presented with 5 cm diameter swelling in the angle of right mandible for 2 months. FNAC yielded drops of fluid. The most likely diagnosis from the Figure 2.1 is:

a. Chronic sialadenitis
b. Warthin tumor
c. Oncocytoma
d. Mucoepidermoid carcinoma

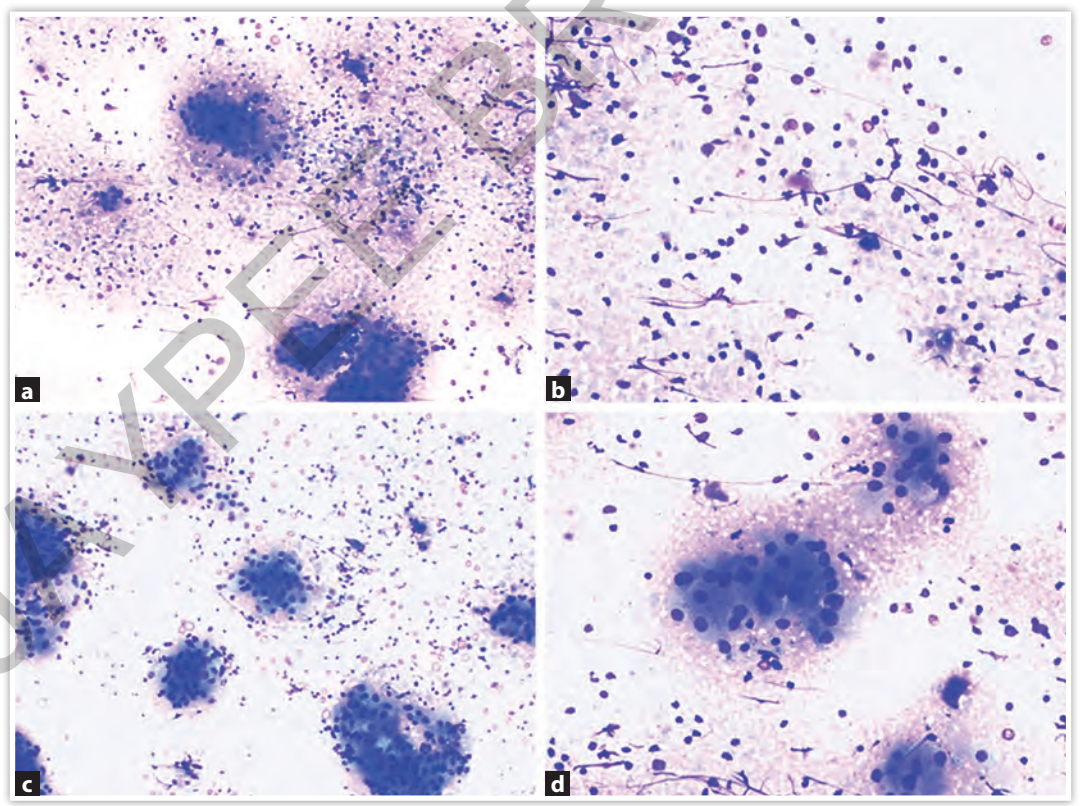

Contd...

JAYPEE BROTHERS

Contd...

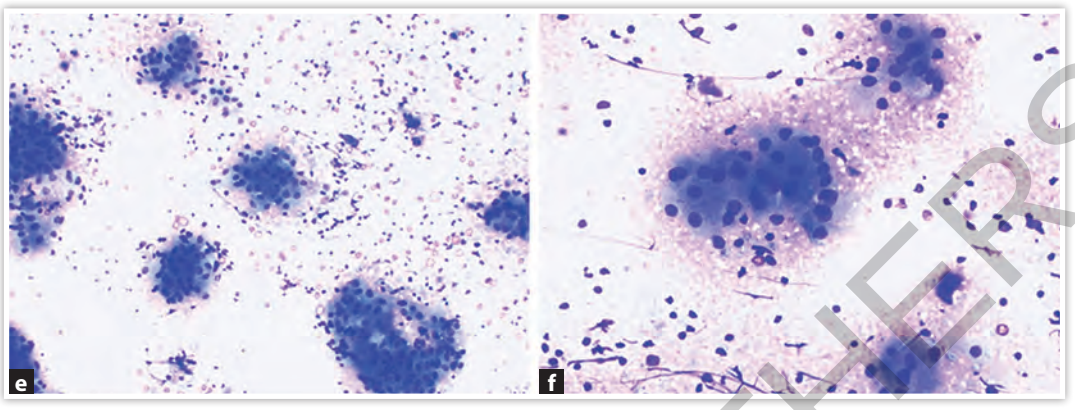

Fig. 2.1

JAYPEE BROTHERS

Problem 2.2

A 37-year-old male with history of chronic alcohol intake presented with an ill-defined 4 cm diameter swelling of both the parotid glands for 6 months. The most likely diagnosis from Figure 2.2 is:

a. Acinic cell carcinoma
b. Warthin tumor
c. Sialadenitis
d. Sialadenosis

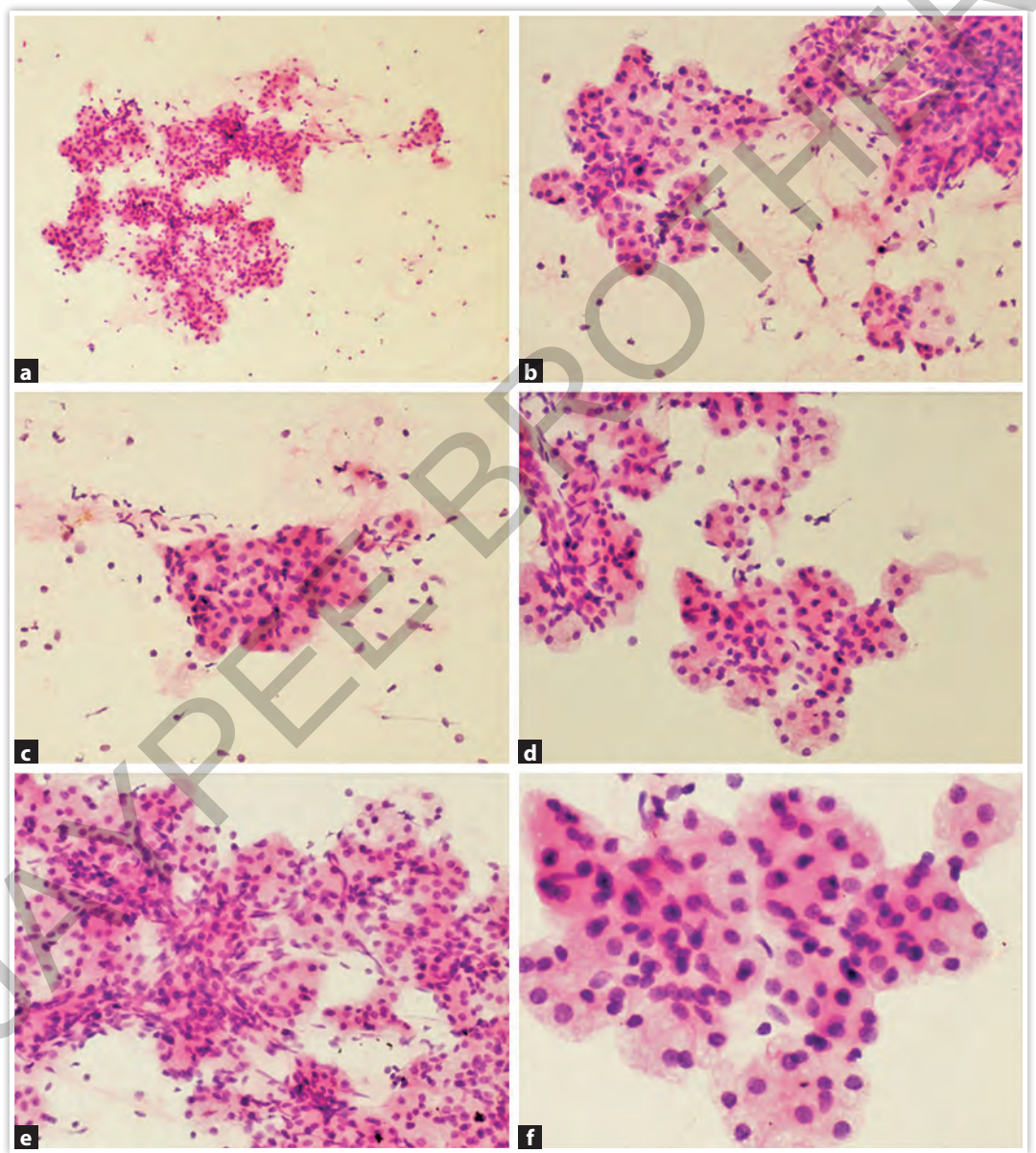

Fig. 2.2

JAYPEE BROTHERS

Problem 2.3

A 35-year-old male had a painless 4 cm diameter swelling in the left parotid gland for 7 months. Figure 2.3 shows the microphotograph of the case. The most likely diagnosis is:

a. Schwannoma of parotid gland
b. Pleomorphic adenoma
c. Myoepithelial tumor
d. Low grade fibrous histiocytoma

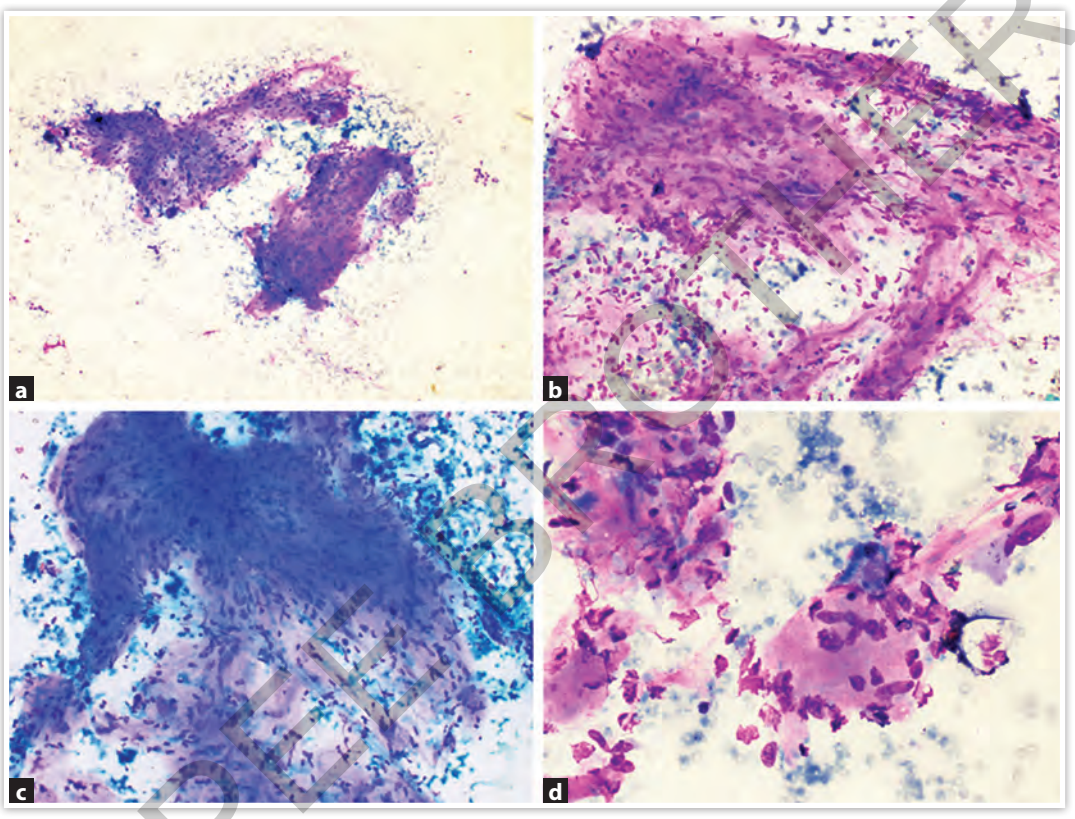

Fig. 2.3

JAYPEE BROTHERS

Problem 2.4

A 31-year-old male presented with 5 cm diameter swelling in the angle of left mandible for 8 months. Figure 2.4 shows the microphotographs of this case.

1. The possible diagnosis is:
   a. Pleomorphic adenoma
   b. Adenoid cystic carcinoma
   c. Polymorphous low grade adenocarcinoma
   d. Basal cell adenoma
2. What are the characteristic cytological features of this lesion?
3. What common changes may occur within this lesion?
4. What are the differential diagnoses?

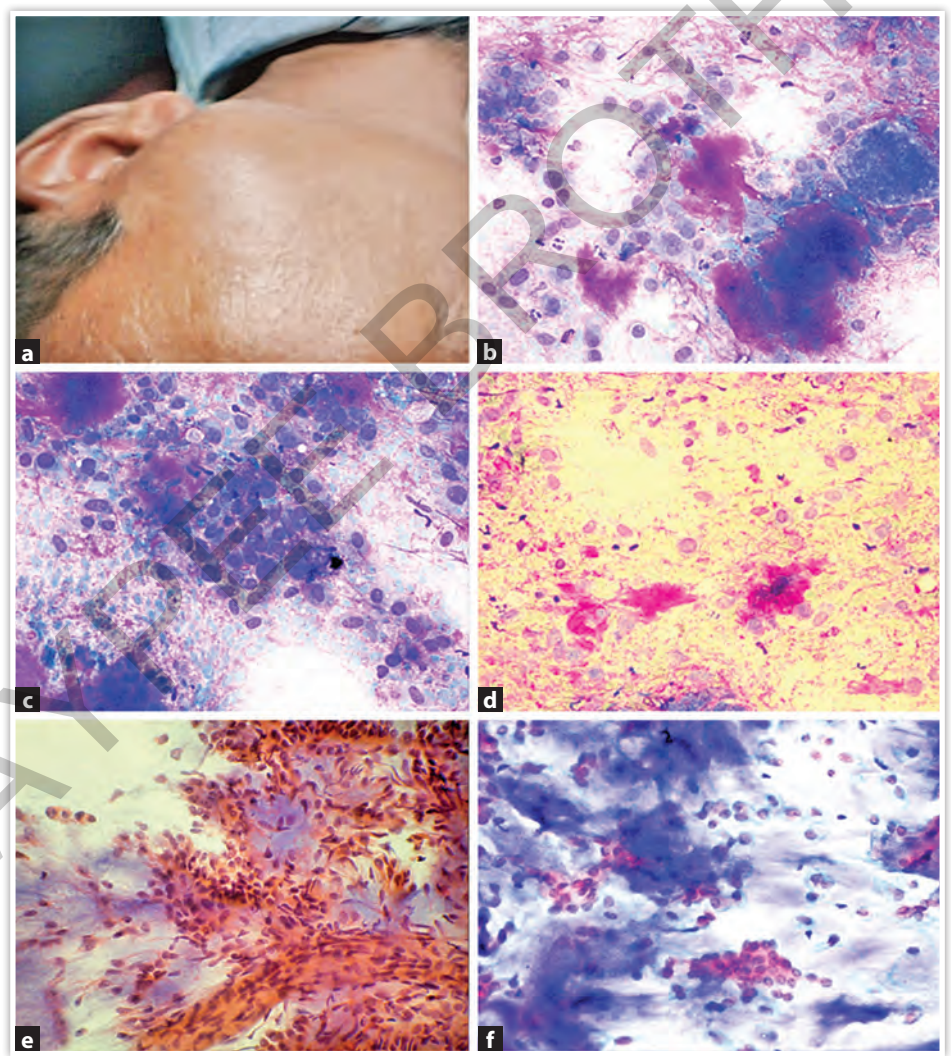

Fig. 2.4

JAYPEE BROTHERS

Problem 2.5

A 40-year-old female had 5 cm × 4 cm × 4 cm enlarged right parotid gland for 6 months. Flow cytometry was done from the aspirated material (Figs 2.5D, E and F). The likely diagnosis from Figure 2.5 is:

a. Chronic sialadenitis
b. Lymphoepithelial sialadenitis
c. Non-Hodgkin lymphoma B cell type
d. Poorly differentiated adenocarcinoma

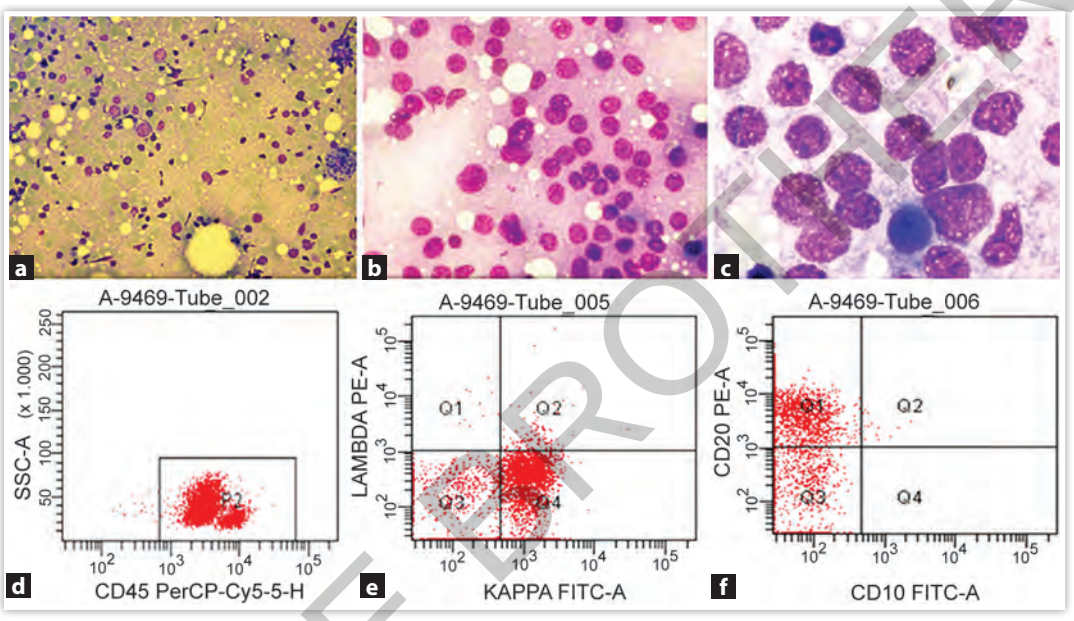

Fig. 2.5

JAYPEE BROTHERS

Problem 2.6

1. A 35-year-old female presented with 5 cm diameter right submandibular swelling for 8 months. The possible diagnosis from Figure 2.6 is:
   a. Pleomorphic adenoma
   b. Myoepithelial neoplasm
   c. Polymorphous low grade adenocarcinoma
   d. Plasmacytoma
2. Provide the characteristic cytological features of this lesion.
3. Mention immunocytochemistry.
4. Mention the differential diagnosis.

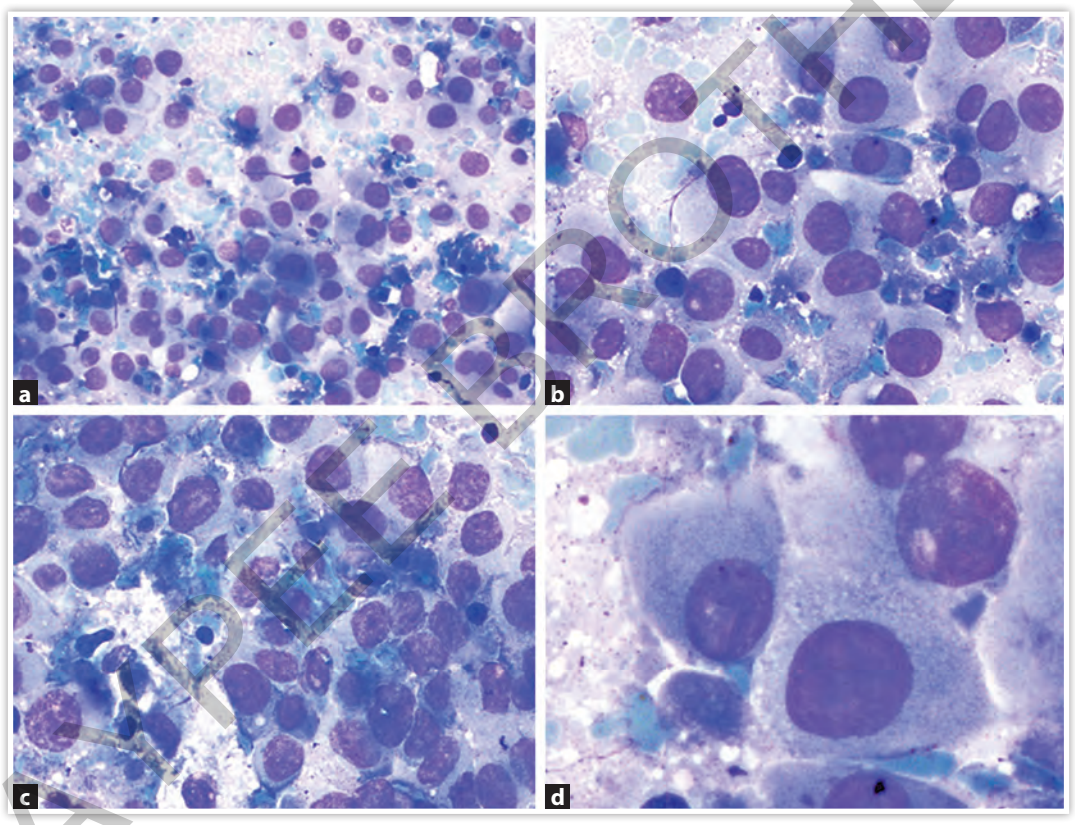

Fig. 2.6

JAYPEE BROTHERS

Problem 2.7

A 26-year-old female presented with 5 cm diameter swelling in the left angle of mandible for 6 months. Probable diagnosis from Figure 2.7 is:

a. Non-Hodgkin lymphoma
b. Chronic sialadenitis
c. Intraparotid reactive lymph node
d. Warthin's tumor

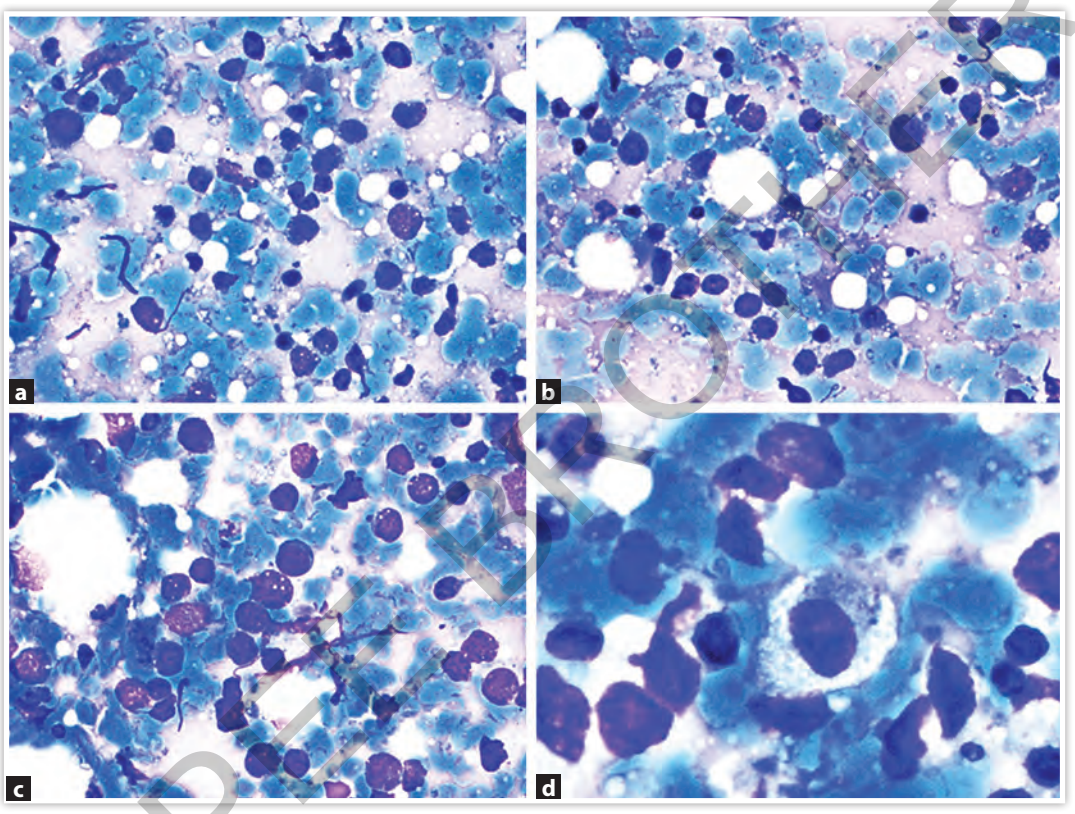

Fig. 2.7

JAYPEE BROTHERS

for detailed information on pathology books, visit our website **www.jaypeebrothers.com,** for detailed in

Case-based Approach in Fine Needle Aspiration Cytology

In this book, the author has collected all classical and interesting 250 real cases (of last two decades) of fine needle aspiration cytology to cover all the systems. Essential clinical history and multiple microphotographs have been provided with every case. The reason of diagnosis of each case and differential diagnosis are discussed at the end of each chapter. Further source of reading is also provided after each case. The book is an excellent source of learning cytology as it describes both classical and difficult cases. It can also be used for self-evaluation as the whole approach is question and answer based. This is an essential book for the learners to learn cytology and also for the experts to enjoy fun in diagnosing interesting cases of cytology.



Pranab Dey MBBS MD MIAC FRCPath is Professor, Department of Cytology and Gynecologic Pathology, Postgraduate Institute of Medical Education and Research, Chandigarh, India. He is engaged in diagnosis, research and teaching cytology and gynecologic pathology for more than 25 years. He is the author of two books: *Fine Needle Aspiration Cytology: Interpretation and Diagnostic Difficulties* and *Diagnostic Cytology.*

Available at all medical bookstores
or buy online at www.jaypeebrothers.com

JAYPEE BROTHERS
Medical Publishers (P) Ltd.
www.jaypeebrothers.com
Join us on facebook.com/JaypeeMedicalPublishers

Shelving Recommendations
CYTOLOGY, PATHOLOGY

ISBN 978-93-5250-180-9