adiology books, visit our website www.jaypeebrothers.com, for detailed information on radiology books

101 CT Abdomen Solutions

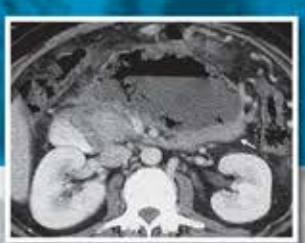



Hariqbal Singh
Yasmeen Khan

JAYPEE

Contents

CT Anatomy: Abdomen and Pelvis 1

SECTION 1 Esophagus

1. Hiatus Hernia 19
2. Esophageal Carcinoma 21
3. Leiomyomatosis of Esophagus 23

SECTION 2 Diaphragm

4. Eventration 27
5. Eventration of Diaphragm with Duplication of Inferior Vena Cava 29

SECTION 3 Stomach

6. Gastrointestinal Stromal Tumor 33
7. Gastric Malignanacy 35

SECTION 4 Duodenum

8. Carcinoma Duodenum 41

SECTION 5 Small Bowel

9. Small Bowel Obstruction 45
10. Ileocecal Lymphoma 47
11. Small Bowel Gastrointestinal Stromal Tumor 49
12. Angiodysplasia of Jejunum 51
13. Ileal Carcinoma 53
14. Pneumatosis Intestinalis 55
15. Midgut Volvulus 57

SECTION 6 Appendix

16. Acute Appendicitis 61
17. Appendicular Abscess 63

SECTION 7 Colon

18. Intussusception 67
19. Nontoxic Megacolon 70

20. Sigmoid Diverticulitis 72
21. Abdominal Koch's 74
22. Carcinoma Sigmoid 77

SECTION 8 Rectum

23. Carcinoma Rectum 81

SECTION 9 Liver

24. Focal Fatty Liver 87
25. Simple Hepatic Cyst 89
26. Budd-Chiari Syndrome 91
27. Liver Laceration 94
28. Hepatic Abscess 97
29. Hepatic Hydatid Cyst 100
30. Hepatic Hemangioma 103
31. Focal Nodular Hyperplasia 106
32. Hepatic Adenoma 108
33. Hepatic Angiomyolipoma 110
34. Hepatocellular Carcinoma 112
35. Hepatic Metastases 115
36. Hepatoblastoma 118
37. Intrahepatic Cholangiocarcinoma 120
38. Extrahepatic Cholangiocarcinoma 123
39. Transient Hepatic Attenuation Difference 125

SECTION 10 Gallbladder

40. Choledochal Cyst 129
41. Acalculus Cholecystitis 131
42. Acute Calculus Cholecystitis 133
43. Emphysematous Cholecystitis 136
44. Choledocholithiasis 138
45. Porcelain Gallbladder 140
46. Carcinoma Gallbladder 142

SECTION 11 Pancreas

47. Acute Pancreatitis 147
48. Pancreatic Pseudocyst 149
49. Necrotizing Pancreatitis 153
50. Periampullary Carcinoma with Metastases 155

SECTION 12 Spleen

51. Splenunculus 161
52. Splenic Trauma 163
53. Splenic Abscess 166

SECTION 13 Vascular

54. Superior Mesenteric Artery Syndrome 171
55. Superior Mesenteric Artery Thrombosis 173
56. Accessory Renal Artery Stenosis 176
57. Aneurysm of Abdominal Aorta 178
58. Inferior Vena Cava Thrombus 180
59. Aortic Thrombus 182
60. Portal Vein Thrombosis 184

SECTION 14 Adrenal

61. Adrenal Adenoma 189
62. Pheochromocytoma 192
63. Adrenal Metastases 194

SECTION 15 Renal

64. Renal Aplasia 199
65. Dysplastic Kidney 201
66. Polycystic Kidneys 203
67. Pelviureteric Junction Obstruction 205
68. Obstructive Uropathy 208
69. Emphysematous Pyelonephritis 215
70. Renal Vein Thrombosis 217
71. Renal Laceration 219
72. Renal Angiomyolipoma 221
73. Wilms' Tumor 223
74. Renal Cell Carcinoma 226

SECTION 16 Urinary Bladder

75. Vesical Calculus 231
76. Urinary Bladder Diverticulum 233
77. Cystitis 235
78. Carcinoma Urinary Bladder 237

SECTION 17 Prostate

79. Carcinoma Prostate 243

SECTION 18 Scrotum

80. Hydrocele 247
81. Testicular Trauma 249
82. Seminoma 251
83. Undescended Testis 253

SECTION 19 Penis

84. Penile Carcinoma 257

SECTION 20 Uterus

85. Broad Ligament Fibroid 261
86. Hydrometrocolpos 263
87. Pyometra 265
88. Endometrial Carcinoma 267
89. Carcinoma Cervix 270
90. Vaginal Carcinoma 272
91. Ureterovaginal Fistula 274
92. Vulval Carcinoma 276

SECTION 21 Ovary

93. Ovarian Vein Thrombosis 281
94. Ovarian Tumor 283

SECTION 22 Abdominal Wall

95. Abdominal Wall Sarcoma 289
96. Abdominal Wall Hernia 291

SECTION 23 Miscellaneous

97. Inguinal Hernia 297
98. Omental Infarction 300
99. Primitive Neuroectodermal Tumor 302
100. Fetus-in-Fetu 304
101. Lymphangioma 306

Index *309*

CASE

2 Esophageal Carcinoma

JAYPEE BROTHERS

CASE

A 65-year-old male presented to the department of radiology with dysphagia.

Radiological Findings on CT Examination

CT scan abdomen shows circumferential wall thickening involving the gastro-esophageal junction extending up to the fundus and lesser curvature of stomach (Figs 1A to C). Fat planes between this lesion and left lobe of liver is lost.

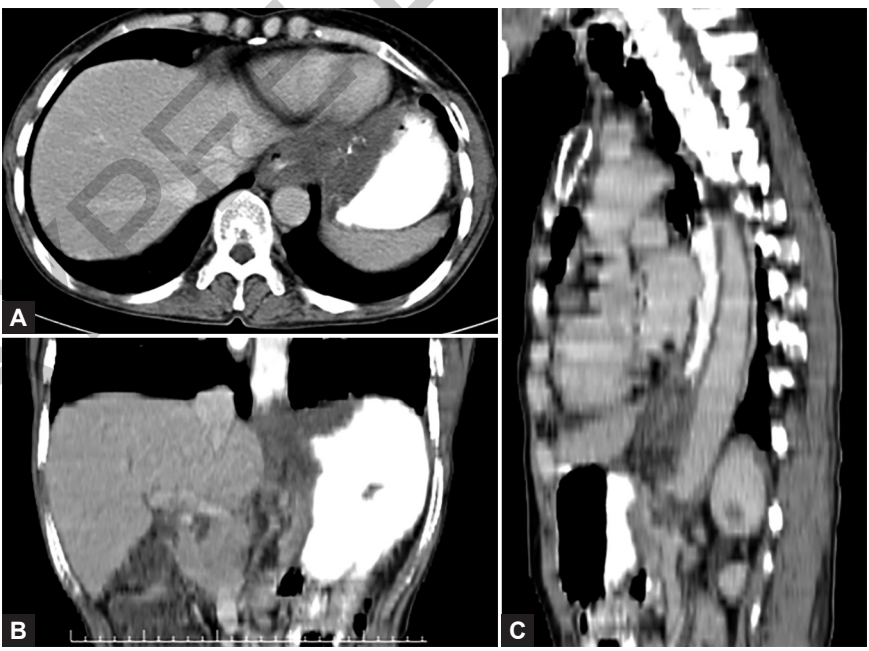

Figs 1A to C

Comments and Explanation

Carcinoma of the esophagus is relatively uncommon. Patients present with increasing dysphagia, initially to solids and progressing to liquids as the tumor increases in size. Barium is the initial study and shows irregular stricture, prestricture hold-up of contrast and ulceration. CT shows eccentric circumferential wall thickening >5 mm, dilated fluid filled esophageal lumen proximal to an obstructing lesion. Contrast-enhanced CT plays an important role in the staging of esophageal carcinoma. CT helps in determining the extent of the local tumor; invasion of mediastinal structures, involvement of supraclavicular, mediastinal, or upper abdominal lymph nodes; and distant metastases. The CT criteria for local invasion include loss of fat planes between the tumor and adjacent structures in the mediastinum, and displacement or indentation of other mediastinal structures. Aortic invasion is suggested if 90° or more of the aorta is in contact with the tumor or if there is obliteration of the triangular fat space between the esophagus, aorta, and spine adjacent to the primary tumor. A tracheobronchial fistula or tumor extension into the airway lumen is a definite sign of tracheobronchial invasion. Displacements of the trachea or bronchus, or indentation of the posterior wall of the trachea or bronchus by the tumor, have also proved accurate in predicting tracheobronchial invasion. Pericardial invasion is suspected if pericardial thickening, pericardial effusion, or indentation of the heart with loss of the pericardial fat plane is seen. Positron emission tomography (PET) has become a standard oncologic imaging modality. PET is useful not only for the primary detection of tumor and metastases but also for the further characterization of abnormalities discovered by using other imaging modalities.

Opinion

Esophageal carcinoma.

Clinical Discussion

Esophageal cancer is the third most common gastrointestinal malignancy. As with all other tumors, the outcome for patients with esophageal cancer is strongly associated with the stage at initial diagnosis. More than 90% of esophageal cancers are either squamous cell carcinomas (SCCs) or adenocarcinomas. SCCs are evenly distributed between the middle and lower esophagus, whereas approximately three-fourths of all adenocarcinomas are found in the distal esophagus. Esophageal cancer is notorious for its aggressive behavior; it may invade local, regional, or distant structures by various pathways, including direct extension, lymphatic spread, and hematogenous metastasis. CT, endoscopic US, and PET all play important roles in the staging of patients with esophageal cancer. CT is a good initial screening modality for determining whether the patient may undergo resection or has distant metastases. The most common sites of metastases include liver, lungs, bones, adrenal glands, kidneys, and brain. PET is useful for assessing distant metastases as well as restaging after neoadjuvant therapy.

JAYPEE BROTHERS

for detailed information on radiology books, visit our website www.jaypeebrothers.com, for detailed infor

101
CT Abdomen Solutions

Salient Features

- Permits acquaintance to normal abdominal CT anatomy of structures and changes in their morphology on pathology with clarity
- Aims at easy, ready and convenient peep in introducing the medical fraternity to the fascinating pathological changes on CT abdomen
- The book will prove to be equally handy manual as earlier publications *101 Chest X-ray Solutions* and *101 MRI Brain Solutions* and provide an access into the beautiful world of CT images
- This assemblage of images will assist as a companion to CT imaging department for their routine day-to-day course of work
- Provides most imaging solutions on CT abdomen routinely required at any imaging establishment and will be a handy reference.

Hariqbal Singh is Professor and Head, Department of Radiology, Shrimati Kashibai Navale Medical College, Pune, Maharashtra, India. He has technical expertise as radiologist in managing equipment, personnel and resources. He is an effective administrator, communicator and team chief. He has a large number of publications in countrywide and global medical journals. He has authored few books on Imaging. He has been a Postgraduate Teacher, Examiner and Guide since 1989 with Pune University, Maharashtra University of Health Sciences, Diplomate National Board and Sumandeep University, Gujarat.



Yasmeen Khan is Consultant Radiology, Shrimati Kashibai Navale Medical College, Pune, Maharashtra, India. She is a keen Radiologist and zealous observer.



Available at all medical bookstores
or buy online at www.jaypeebrothers.com

JAYPEE BROTHERS
Medical Publishers (P) Ltd.
www.jaypeebrothers.com

Join us on facebook.com/JaypeeMedicalPublishers

Shelving
Recommendation
RADIOLOGY

ISBN 978-93-5250-181-6